



An African pygmy hedgehog adenovirus 1 (AhAdV-1) outbreak in an African pygmy hedgehog (*Atelerix albiventris*) colony in Japan

H. Ochiai^a, K. Tamukai^b, Y. Akabane^c, M. Oba^d, T. Omatsu^c, A. Okumura^d, T. Mizutani^c,
H. Madarame^{e,*}

^a Research Institute of Biosciences, Azabu University, Sagami-hara, Kanagawa, 252-5201 Japan

^b Den-en-chofu Animal Hospital, Denenchofu, Ota-ku, Tokyo 145-0071, Japan

^c Research and Education Center for Prevention of Global Infectious Diseases of Animals, Tokyo University of Agriculture and Technology, Fuchu, Tokyo 183-8538, Japan

^d Centre for Infection and Immunity, Mailman School of Public Health, Columbia University, New York, NY 10032, United States

^e Veterinary Teaching Hospital, Azabu University, Sagami-hara, Kanagawa 252-5201, Japan

ARTICLE INFO

Keywords:

African pygmy hedgehog (APH)
African pygmy hedgehog adenovirus 1 (AhAdV-1)
Emerging pathogen
Respiratory disease
Outbreak

ABSTRACT

An African pygmy hedgehog adenovirus 1 (AhAdV-1) outbreak in a colony of 24 African pygmy hedgehogs (APHs) with a case of fatal pneumonia occurred in Japan. Thirteen out of a colony of 15 APHs with respiratory symptoms were diagnosed with AhAdV-1 infection based on the detection of AhAdV-1 genome in throat/nasal swabs and further one APH was diagnosed on isolation of the virus. Five infected APHs died during the outbreak and AhAdV-1 caused severe pneumonia and death in one case. After the outbreak, persistent AhAdV-1 infection was suggested in one surviving APH. AhAdV-1 is a novel adenovirus and is suspected to be an emerging pathogen.

In hedgehogs, viral diseases are rare (Johnson, 2011; Kashuba, Hsu, Krogstad & Franklin, 2005). In African pygmy hedgehogs (APHs), pneumonia is a common disease, although viral causes of respiratory disease are largely unknown (Turner, Brash & Smith, 2018). During the last few years, adenovirus respiratory infections in an APH have been reported in Japan (Madarame, Ogihara, Ochiai, Omatsu & Mizutani, 2016) and in the United States (Needle et al., 2019). We reported here an adenovirus outbreak among APHs and a novel African pygmy hedgehog adenovirus (AhAdV-1) was isolated during the outbreak (Madarame et al., 2019).

An outbreak in a colony consisting of 24 APHs with AhAdV-1 occurred during the autumn of 2017 in Japan. For approximately one and a half months, 15 APHs showed respiratory symptoms that included nasal discharge, sniffing, sneezing, coughing and respiratory distress. During the course of the outbreak, five deaths occurred following episodes of respiratory symptoms.

DNA was extracted from throat/nasal swabs of 15 APHs with respiratory symptoms, for a total of 17 swabs from the colony of 24 APHs, and from formalin fixed paraffin embedded (FFPE) lung sections of the five dead APHs with a NucleoSpin DNA FFPE XS (TakaraBio, Kyoto, Japan). About half a year later, nasal swabs of five asymptomatic APHs, which were detected AhAdV-1 in nasal swabs during the local outbreak of AhAdV-1, were retested.

The virus was isolated from a throat/nasal swab sample was collected from the APH (Case11). It was isolated on a monolayer of MDCK cells cultured in Dulbecco's modified Eagle medium (DMEM) containing 2% fetal calf serum and incubated at 37 °C under a 5% CO₂ atmosphere. DNA extraction from the concentrated virus particles was carried out using a High Pure viral nucleic acid kit (Roche, Mannheim, Germany) (Madarame et al., 2019).

The assessment of adenoviral DNA polymerase sequence for all PCR products found high identification (99.6%) for SkAdV-1 (GeneBank Accession Number: KP238322) and also high identification (100%) for AhAdV-1 (GeneBank Accession Number: MK937781) (unpublished data). Nevertheless, whole-genome sequence of the AhAdV-1 isolate (31,764 bp) shows a four deletion sites compared to that of skunk adenovirus-1 (31,848 bp) (Madarame et al., 2019).

Table 1 showed the detection and isolation of AhAdV-1 from APHs in the colony during and after the outbreak. Thirteen APHs were infected with AhAdV-1 and AhAdV-1 was detected in one surviving APH (Case 11). Additionally, before the outbreak, AhAdV-1 was not detected in throat/nasal swabs of 28 APHs in the same colony on 21 December 2016 (unpublished data).

Five dead APHs were subjected to necropsy. All tissue samples were fixed in 10% neutral buffered formalin, embedded in paraffin wax, sectioned, and stained with hematoxylin and eosin (HE). Mouse

* Correspondence author.

E-mail address: madarame@azabu-u.ac.jp (H. Madarame).

Table 1
Detection and isolation of African pygmy hedgehog 1 (AhAdV-1) from a colony of African pygmy hedgehogs.

Case No	Sex	Date of swab test	Detection of AhAdV-1			Isolation of AhAdV-1	Date of death
			Swab	Lung	Swab retest (6/4/2018)		
1	♀	11/10 and 24/10/2017	+	-	ND	ND	13/11/2017
2	♀	11/10/2017	+	ND	-	ND	NA
3	♀	11/10/2017	++	-	ND	ND	26/10/2017
4	♀	11/10/2017	+	+	ND	ND	12/10/2017
5	♀	11/10 and 24/10/2017	++	ND	ND	ND	NA
6	♂	13/10/2017	+	-	ND	ND	21/10/2017
7	♂	17/10/2017	+	ND	+	ND	NA
8	♀	17/10/2017	-	ND	ND	ND	NA
9	♀	17/10/2017	+	+	ND	ND	26/10/2017
10	♀	17/10/2017	+	ND	ND	ND	NA
11	♀	21/10/2017	+	ND	-	+	29/3/2019
12	♂	21/10/2017	+	ND	-	ND	NA
13	♂	21/10/2017	+	ND	-	ND	NA
14	♂	24/10/2017	+	ND	ND	ND	NA
15	♂	14/11/2017	-	ND	ND	ND	NA
Total			13/15	2/5	1/5		

Swab, Throat/nasal swab; Lung, FFPE lung sections; +, positive; -, negative; ND, not done; NA, not available.
+ *: Both swabs were positive. .

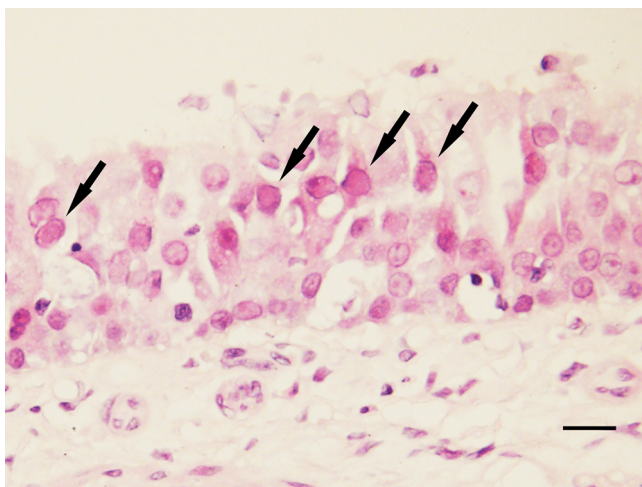


Fig. 1. Nuclear inclusion bodies of nasal epithelial cells (arrows). HE. Bar = 10 µm.

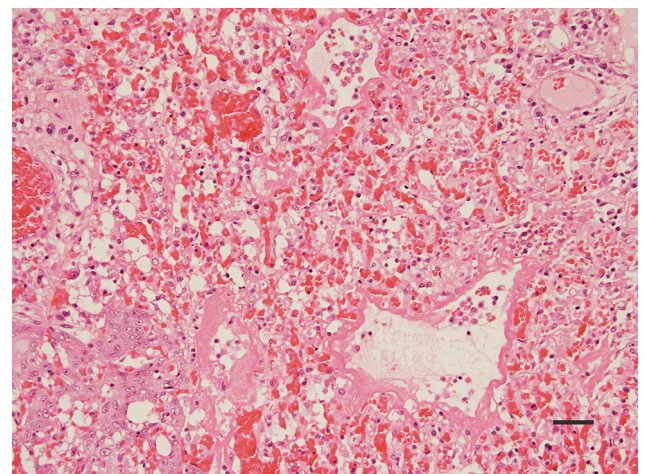


Fig. 3. Congested alveolar septa with type II pneumocyte proliferation. Intra-alveolar oedema with hemorrhage, alveolar macrophages, and hyaline membrane formation. HE. Bar = 50 µm.

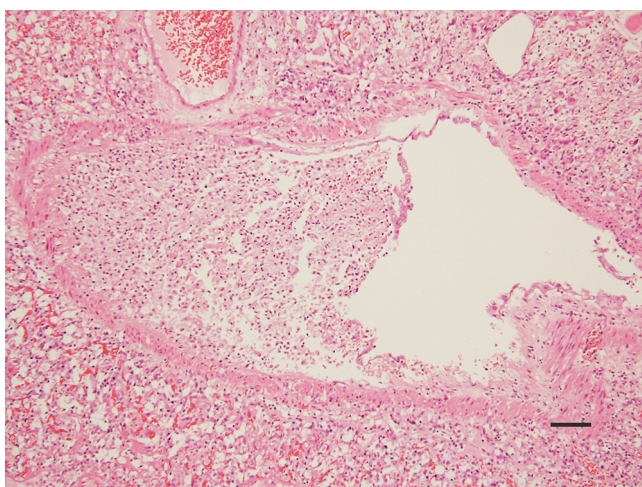


Fig. 2. The bronchi filled with sloughed epithelium and macrophages. HE. Bar = 100 µm.

Table 2
Pathologic diagnoses of the lung in five dead African pygmy hedgehogs.

Case No	Pathological diagnoses	Detection of AhAdV-1
1	Mild chronic focal bronchitis and peribronchitis	-
3	Mild acute pulmonary edema and embolism	-
4	Mild acute pulmonary edema	+
6	Mild acute pulmonary edema and embolism	-
9	Severe acute diffuse bronchointerstitial pneumonia	+

+, positive; -, negative.

monoclonal anti-adenovirus antibody (prediluted, clone 20/11 & 2/6; LifeSpan BioSciences, USA) was applied to selected sections of the nasal cavity (Case 4) for immunohistochemistry (IHC).

Pathological changes of AhAdV-1 infection were restricted to the respiratory tract. The upper respiratory tract had no detectable gross lesions. Histologically, mild to moderate multifocal acute rhinitis characterized by erosion, ulceration or desquamation of the nasal mucosa was common in the five animals that died. Amphophilic nuclear

Table 3
Pathological diagnoses of other organs in 5 dead African pygmy hedgehogs.

Pathological diagnoses	Case 1	Case 3	Case 4	Case 6	Case 9
Cardiomyopathy	+	+	-	+	-
Splenic extramedullary hematopoiesis	+	+	+	-	+
Hepatic lipidosis	+	+	+	+	+
Tumours	Splenic myelolipoma	-	Multiple primary tumours*	-	-
Intraperitoneal hemorrhage**	-	-	+	-	-

+, positive; -, negative.

Three animals (Case 1, 3, and 6) were bred in-house. Case 4 was home-bred.

Case 9 was imported, but the origin was obscure.

* : Multiple primary tumours include pheochromocytoma (Left adrenal gland), osteosarcoma, and myeloid leukaemia.

** : Hemorrhage due to adrenal pheochromocytoma rupture.

inclusion bodies less than 10 µm were seen within the nasal epithelia (Fig. 1), but were negative for anti-adenovirus antibody in one APH (Case 4). Chronic mild tracheitis characterized by focal erosion (Cases 1) or focal squamous metaplasia (Case 9) of the respiratory epithelium was observed.

In the lower respiratory tract, one dead APH (Case 9) had definite gross lesions: almost all lung lobes were edematous, firm, and dark red with a small amount of hemorrhagic pleural effusions (Supplementary Fig. 1). Histologically, severe acute diffuse bronchointerstitial pneumonia was observed to have spread across all lobes. The bronchi had mild to moderate hyperplasia or metaplasia of the epithelium and were filled with a moderate amount of sloughed epithelium and inflammatory cells, mainly of macrophages (Fig. 2). Alveolar septa were diffusely congested with scattered type II pneumocyte proliferation. Diffuse intra-alveolar edema with hemorrhaging, increased numbers of alveolar macrophages, and hyaline membrane formation were evident (Fig. 3). Pathologic diagnoses of the lung and other organs of the five dead APHs are included in Tables 2 and 3, respectively.

Adenoviruses (AdVs) are a ubiquitous group of viruses that have been found in a wide range of hosts. Infection from individual AdV strains has been thought to be highly species-specific and frequent interspecies AdV infections are considered unlikely (Dubovi & Maclachlan, 2017).

Most animal AdVs tend to produce subclinical infections in their respective hosts and are usually isolated from the upper respiratory tract with occasional upper respiratory disease (Dubovi & Maclachlan, 2017). Nevertheless, skunk adenovirus 1 (SkAdV-1) caused a clinically important or fatal disease with different pathological manifestations in two different animal species: a skunk (Kozak et al., 2015) and an APH (Needle et al., 2019).

SkAdV-1 and AhAdV-1 are closely related adenoviruses (Madarame et al., 2019). SkAdV-1 caused fatal bronchopneumonia in one of a group of APHs (Needle et al., 2019). In the present outbreak, AhAdV-1 was found to have caused severe bronchointerstitial pneumonia and death in one APH. Concurrent infections of other pathogens cannot be ruled out in our cases, although sequencing of the amplification product proved AhAdV-1 as the involved pathogen for fatal pneumonia.

Unresolved questions include whether or not AhAdV-1 is a broad host range adenovirus, induces different pathogenicity in different hosts, and can cross species barriers in the same way as SkAdV-1 (Kozak et al., 2015; Needle et al., 2019; Podgorski et al., 2018).

All hedgehogs are Old World species of insectivores widely distributed from Europe, to Africa and Asia (Hutterer, 2005). Among hedgehogs, APH became popular as an exotic pet in North America in the 1980s, although that popularity has waned in recent years. In contrast, its popularity in Asian countries has increased notably recently, including in Japan (Turner et al., 2018).

Even though the route and source of the present AhAdV-1 outbreak in APHs in Japan remains uncertain, more than 25,000 APHs without preceding medical examination or quarantine were imported from Asian countries to Japan in 2017, according to data obtained from the Japanese

government's Import Animal Notification Opening System (IANOS) (<http://www.mhlw.go.jp/stf/seisakunitsuite/bunya/0000069864.html>). AhAdV-1 is suspected to be an emerging pathogen in APHs within exotic pet distribution centers or in breeding colonies in Asia.

In conclusion, this report indicates an AhAdV-1 outbreak with a case of fatal pneumonia in Japan. Further efforts are warranted to clarify the epidemiology, especially the host-pathogen relationship, of AhAdV-1 infection and to fulfill Koch's postulates to link this virus to the pathology. AhAdV-1 should be monitored globally as a potential cause of emerging respiratory infections in APHs.

Ethical statement

Authors must ensure our manuscript has been carried out in accordance with ethics in publishing and ethics guidelines.

Declaration of Competing Interest

None of the authors of this paper has a financial or personal relationship with other people or organizations that could inappropriately influence or bias the content of the paper.

Acknowledgments

The authors thank to Ms K. Satoh, and Ms M. Mori for their expert technical assistance. We also thank Mr. J. Lynch for English proof-reading of the original manuscript.

Supplementary materials

Supplementary Fig. 1. Gross image. Lung. Almost all lung lobes were edematous, firm and dark red. Supplementary material associated with this article can be found, in the online version, at [doi:10.1016/j.vas.2019.100083](https://doi.org/10.1016/j.vas.2019.100083).

References

- Dubovi, E. J., & Maclachlan, J. N. (2017). Adenoviridae. In J. N. Maclachlan, & S. W. Dubovi (Eds.). *Fenner's veterinary virology* (pp. 217–227). (5th ed.). London, UK: Academic Press.
- Hutterer, R. (2005). Order Erinaceomorpha. In D. E. Wilson, & D. M. Reeder (Eds.). *Mammal species of the world: a taxonomic and geographic reference* (pp. 212–217). (3rd ed.). Baltimore, MD: Johns Hopkins University Press.
- Johnson, D. H. (2011). Hedgehogs and sugar gliders: Respiratory anatomy, physiology, and disease. *Veterinary Clinics of North America: Exotic Animal Practice*, 14, 267–285.
- Kashuba, C., Hsu, C., Krogstad, A., & Franklin, C. (2005). Small mammal virology. *Veterinary Clinics of North America: Exotic Animal Practice*, 8, 107–122.
- Kozak, R. A., Ackford, J. G., Slaine, P., Li, A., Carman, S., Campbell, D., et al. (2015). Characterization of a novel adenovirus isolated from a skunk. *Virology*, 485, 16–24.
- Madarame, H., Ogihara, K., Ochiai, H., Omatsu, T., & Mizutani, T. (2016). Detection of skunk adenovirus 1 (SkAdV-1) in an African pygmy hedgehog (*Atelerix albiventris*). *Veterinary Record Case Reports*, 4, e000321. <https://doi.org/10.1136/vetreccr-2016-000321>.
- Madarame, H., Uchiyama, J., Tamukai, K., Katayama, Y., Osawa, N., Suzuki, K., et al. (2019). Complete genome sequence of an adenovirus-1 isolate from an African

- pygmy hedgehog (*Atelerix albiventris*) exhibiting respiratory symptoms in Japan. *Microbiology Resource Announcements*, 8, e00695-19.
- Needle, D. B., Selig, M. K., Jackson, K. A., Delwart, E., Tighe, E., & Leib, S. L. (2019). Fatal bronchopneumonia caused by skunk adenovirus 1 in an African pygmy hedgehog. *Journal of Veterinary Diagnostic Investigation*, 31, 103–106.
- Podgorski, I. I., Pantó, L., Földes, K., de Winter, I., Jánoska, M., Sós, E., et al. (2018). Adenovirus of the most ancient primate lineages supported the theory on virus-host co-evolution. *Acta Veterinaria Hungarica*, 66, 474–487.
- Turner, P. V., Brash, M. L., & Smith, D. A. (2018). *Hedgehogs. Pathology of small mammal pets*. Hoboken, NJ: WILEY Blackwell387–416.