

A Rare Chronic Presentation of Schwannoma with Hemorrhage

Abstract

Spinal schwannomas are slow-growing benign tumors arising from the nerves. In the spinal cord, they arise most commonly from cervical and lumbar levels. They are mostly intradural extramedullary (IDEM) accounting for 30% of intradural tumors showing a female preponderance. They are seen occurring between 25 and 50 years of age. Most of these cases show acute presentation as hemorrhage within the tumor with weakness. This is a rare presentation by itself reported by only 12 cases world over. It is even rarer to see them show chronic presentation. We are reporting one such case of a 61-year-old female who presented to us with chronic low backache for 3 years with radicular symptoms in the bilateral lower limbs following a fall on her back. Magnetic resonance imaging was done which showed a well-defined IDEM lesion from L3 to L5 vertebral level which was isointense on T1 and hyperintense on T2 with a peripheral rim and short inversion time inversion-recovery showed fluid-fluid level within. Gradient-recalled echo showed blooming with no suppression on fat-sat and no diffusion restriction. A computed tomography angiography was done which ruled out vascular malformation. Intraoperatively, a large feeding vessel with a tumor was visualized after laminectomy was done for the corresponding levels. Postoperatively, the patient showed a significant decrease in radicular symptoms and was discharged after 2 weeks with an uneventful postoperative period. HPE of the lesion showed sheets of fascicles of elongated spindle cells arranged in loose myxoid matrix with hyperchromatic nuclei and scanty hemorrhage and lymphocytic infiltrates suggestive of schwannoma with myxoid degeneration. Immunohistochemistry also confirmed a diagnosis of schwannoma. From this case, it is seen that the diagnosis of a spinal schwannoma showing delayed presentation with atypical imaging findings is a challenge and must needs a high index of suspicion and appropriate surgical planning.

Keywords: Chronic, haemorrhage, rare, schwannoma

Introduction

Spinal schwannomas are slow-growing tumors arising from the nerves within the spinal canal.^[1,2] They are the most common intradural extramedullary (IDEM) tumors and account for 30% of all intradural tumors.^[2,3] They often occur between the ages of 25–50 and are most commonly located in cervical and lumbar regions because of higher density of nerve roots in that region.^[4,5] Symptoms depend on the location of the tumor and patients usually present with pain, weakness paresthesias, and numbness. Hemorrhage within a schwannoma is a rare entity with only 12 cases reported in the literature, to the best of our knowledge.^[2,3] These patients usually present in acute emergency acute-onset weakness. We present a rare case of the patient presenting with a long-standing history of back pain occurring due to

lumbar intradural hemorrhage confirmed as schwannoma on histopathology.

Case Report

A 61-year-old female patient with medical history of diabetes presented with symptoms of chronic low back pain for 3 years along with radiation of pain to both lower limbs and tingling numbness in both lower limbs since 21/2 years. She gave a significant history of slipping and falls on the back while walking 3 years ago following which the patient developed these symptoms. The symptoms worsened gradually, and on presentation, the pain had worsened causing difficulty in walking upright due to the pain. Magnetic resonance imaging (MRI) of the lumbosacral spine was done which revealed a well-defined IDEM lesion noted in the spinal canal extending from L3 to L5 vertebral level measuring approximately 74 (CC) × 12 (AP) × 13 (T) mm. It appeared isointense on T1w, hyperintense on T2w

**Sarang Gotecha,
Prashant Punia,
Anil Patil,
Ashish Chugh,
Megha Kotecha,
Vybhav Raghu,
Ali Mubashshir,
Chhabra Shobhit,
Dushyant Kashyap**

*Department of Neurosurgery,
Dr. D. Y. Patil Medical
College and Hospital, Pune,
Maharashtra, India*

Address for correspondence:
*Dr. Sarang Gotecha,
Department of Neurosurgery
and Ophthalmology,
Dr. D. Y. Patil Medical College
and Hospital, Sant Tukaram
Nagar, Pimpri, Pune - 411 018,
Maharashtra, India.
E-mail: dr.sarangsgotecha@
gmail.com*

Access this article online

Website: www.asianjns.org

DOI: 10.4103/ajns.AJNS_277_18

Quick Response Code:



How to cite this article: Gotecha S, Punia P, Patil A, Chugh A, Kotecha M, Raghu V, *et al.* A rare chronic presentation of schwannoma with hemorrhage. Asian J Neurosurg 2019;14:897-900.

This is an open access journal, and articles are distributed under the terms of the Creative Commons Attribution-NonCommercial-ShareAlike 4.0 License, which allows others to remix, tweak, and build upon the work non-commercially, as long as appropriate credit is given and the new creations are licensed under the identical terms.

For reprints contact: reprints@medknow.com

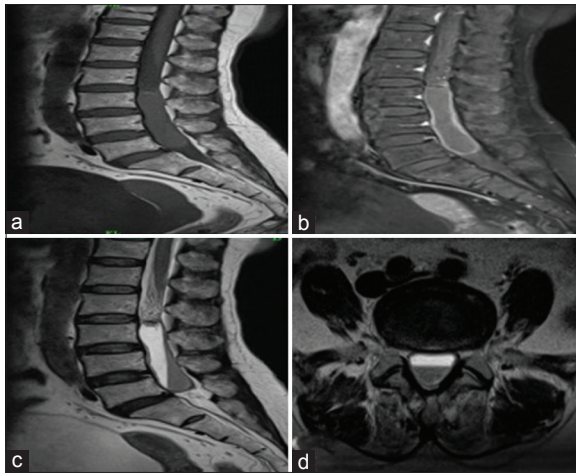


Figure 1: Magnetic resonance imaging L-S spine (Preoperative scans) (a) T1W: Sagittal scan showing a well-defined intradural extramedullary lesion extending from L3 to L5 appearing isointense on T1W. (b): T1W postcontrast: Sagittal scan showing a fluid density lesion at L3–L5 level with peripheral enhancement. (c) T2W: Sagittal scan showing hyperintense lesion and STIR with fluid-fluid level within. (d) T2W: Axial section showing hyperintense lesion

[Figure 1], and short inversion time inversion-recovery a showed fluid-fluid level within. It showed blooming on gradient-recalled echo images with no suppression on fat-sat and no restriction of diffusion. It also showed peripheral rim enhancement. The lesion was causing compression and displacement of traversing and exiting nerve roots at L3–4, L4–5, vertebral levels. Computed tomography (CT) angiogram was also done to rule out any vascular abnormality which was also negative. Hence, with the differential diagnosis of spontaneous hemorrhage, intratumoral bleed, and vascular malformation, surgery was planned. Intraoperatively, lumbar laminectomy (L3–L5) was done. Intraoperative finding showed a large feeding vessel into a lesion extending from L3 to L5 vertebral level. Postoperatively, the patient's pain had decreased significantly and she was discharged 2 weeks after surgery.

Histopathology showed sheets of fascicles of elongated spindle cells arranged in loose myxoid matrix which contained hyperchromatic nuclei and scanty cytoplasm with areas of hemorrhage and lymphocytic infiltrates. These findings were suggestive of schwannoma with myxoid degeneration and hemorrhage. Immunohistochemistry was also suggestive of schwannoma. Postoperative MRI was suggestive of complete excision of the lesion [Figure 2].

Discussion

Schwannomas are benign encapsulated neoplasms of Schwann cells (WHO Grade I) and are confined to the peripheral nerves or spinal nerve roots.^[6] They are typically round-to-oval, lobulated, and encapsulated tumors arising eccentrically from the nerve root sheath^[7] and may have areas of cystic and xanthomatous change. They are most commonly IDEM in location (58%)

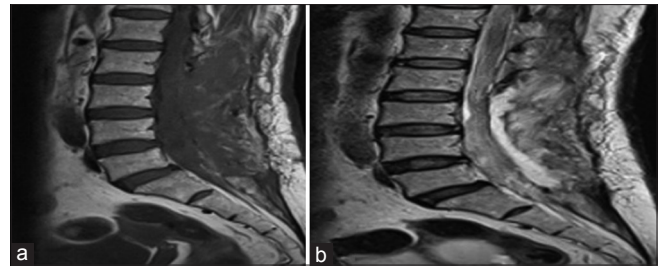


Figure 2: Magnetic resonance imaging L-S spine (postoperative scans): (a) T1W: Sagittal scan showing significant resolution of the preoperative lesion. (b) T2W: Sagittal scan also showing significant resolution of the preoperative lesion

followed by extradural (27%), dumbbell-shaped with both an extradural and intradural component (15%) and rarely intramedullary (<1%).^[8]

These tumors occur mainly in the middle age with a female preponderance (male-female ratio of 1:1.6). They are slow-growing and indolent, hence cannot be diagnosed easily in the early stage.^[9] Clinical presentation depends on the size and location of the tumor. Symptomatic patients commonly present with a dull aching local pain and a radicular pain along the dermatome of the nerve root from where it arises.^[10] Delayed clinical presentation is common in spinal tumors as these tumors are slow-growing and the surrounding anatomic environment is permissive.^[11] Progressively, the patient may present with compressive myelopathy or cauda which develops over months if the lesion is large.^[2,10]

MRI scan is the examination of choice in the diagnosis of spinal tumors. Schwannomas are mostly iso- or hypointense on T1-weighted image, markedly hyperintense on T2-weighted sequence and shows intense homogenous enhancement in the postcontrast study.^[2]

Hemorrhage within schwannomas is very rare. Hemorrhage within vestibular schwannomas has a risk of <1%. The incidence of spinal schwannomas with intratumoral hemorrhage is even rarer with only 12 cases reported within literature to the best of our knowledge [Table 1].^[2,3,10]

The clinical presentation is acute with rapidly progressive neurological deficits seen in most cases. This is usually due to sudden cord compression caused by temporal bleed which is similar to spinal shock. However, in our case, the mode of presentation was atypical, and the first case in the literature where the patient presented with chronic history of back pain which clinically gave an impression of chronic disc disease.^[12]

MRI scan is extremely useful for detecting hemorrhagic change associated with intraspinal tumors.^[9] The signal intensity of hemorrhagic spinal tumor can be influenced by duration after onset and the type of hemorrhage. In our case, the schwannoma displayed atypical MRI findings. MRI was suggestive of intraspinal subarachnoid hematoma at the lumbar region with fluid-fluid level. As the patient

Table 1: Distribution within the spine of subdural/intratumoral hemorrhages from spinal schwannomas

Serial number	Author (citation)	Location within the spine	Type of hemorrhage	Acute/chronic
1	Pamar <i>et al.</i> ^[6]	Thoracolumbar (T11-L1)	SDH (subdural) SAH (subarachnoid)	Acute
2	Ciappetta <i>et al.</i> ^[4]	Craniovertebral junction (C2)	Intratumoral	Acute
3	Vazquez-Barquero A <i>et al.</i> ^[13]	Cervical	SDH	Acute
4	Jenkins AL <i>et al.</i> ^[14]	Lumbar (L2–3)	Intratumoral	Acute
5	Tanaka H <i>et al.</i> ^[15]	Thoracic	SDH	Acute
6	Cohen ZR <i>et al.</i> ^[16]	Thoracic	SDH	Acute
7	Uemura K <i>et al.</i> ^[17]	Thoracic	Intratumoral	Acute
8	Ichinose T <i>et al.</i> ^[18]	Thoracolumbar (T11–L1)	Intratumoral	Acute
9	Ng PY ^[19]	Cervical	Intratumoral	Acute
10	Smith RA ^[20]	Cervical	SDH Intramedullary	Acute
11	Alia Hdeib <i>et al.</i> ^[3]	Thoracic	SDH	Acute
12	Drevelagas <i>et al.</i> ^[2]	Thoracic	SDH	Acute
13	Present case	Lumbar (L3–5)	SDH	Chronic

SDH – Subdural hematoma; SAH – Subarachnoid hemorrhage

presented with a long-standing history, an addition CT angiogram was done to rule out any vascular anomaly which could have caused the resultant bleed which was also negative.

The two main theories have been proposed to explain the occurrence of intratumoral hemorrhage, namely, vascular theory and mechanical theory. According to the vascular theory, spontaneous thrombosis of ectatic and hyalinized vessels of the tumor may occur leading to distal tumor necrosis and hemorrhage. The mechanical theory postulates that movements of the spine induce traction on the tumor vessels resulting in hemorrhage and this occurs usually in the thoracolumbar lesions. Other probable reasons for hemorrhage include central ischemic necrosis due to tumor growth or malignant transformation with neovascularization.^[1,2]

Surgical resection is the treatment of choice and complete removal may prevent recurrence.

This case report illustrates the unexpected occurrence of solitary intratumoral hemorrhage within spinal schwannoma with an atypical clinical and radiological presentation. In all similar studies reported in literature, the patients presented in emergency with acute onset symptoms. In our case, as the patient presented with a long-standing history, additional investigations could be done to rule out vascular anomalies and elective surgical planning was done considering these differential diagnoses.

Conclusion

IDEM schwannoma with intratumoral hemorrhage is a very rare occurrence. This report of schwannoma with intratumoral hemorrhage presenting with a long-standing history and atypical radiological findings illustrates diagnostic difficulty for both neuroradiologists and

neurosurgeons. It also highlights the importance of high clinical suspicion and appropriate surgical planning in such cases.

Declaration of patient consent

The authors certify that they have obtained all appropriate patient consent forms. In the form the patient(s) has/have given his/her/their consent for his/her/their images and other clinical information to be reported in the journal. The patients understand that their names and initials will not be published and due efforts will be made to conceal their identity, but anonymity cannot be guaranteed.

Financial support and sponsorship

Nil.

Conflicts of interest

There are no conflicts of interest.

References

- Nadeem M, Mansoor S, Assad S, Ilyas F, Qavi AH, Saadat S, *et al.* Spinal schwannoma with intradural intramedullary hemorrhage. *Cureus* 2017;9:e1082.
- Drevelagas K, Bangeas P. Intradural extramedullary schwannoma of the thoracic spine with intratumoral hemorrhage. *OMICS J Radiol* 2017;6:272.
- Hdeib A, Goodwin CR, Sciubba D, Bydon A, Wolinsky JP, Witham T, *et al.* Hemorrhagic thoracic schwannoma presenting with intradural hematoma and acute paraplegia after spinal manipulation therapy. *Int J Spine Surg* 2016;10:42.
- Ciappetta P, D'Urso PL, Colamaria A. Giant craniovertebral junction hemorrhagic schwannoma: Case report. *Neurosurgery* 2008;62:E1166.
- Conti P, Pansini G, Mouchaty H, Capuano C, Conti R. Spinal neurinomas: Retrospective analysis and long-term outcome of 179 consecutively operated cases and review of the literature. *Surg Neurol* 2004;61:34-43.

6. Parmar H, Patkar D, Gadani S, Shah J. Cystic lumbar nerve sheath tumours: MRI features in five patients. *Australas Radiol* 2001;45:123-7.
7. Yeh HM, Leung JH, Huang KC, Tung CL, Huang CL, Huang KM. A long segmental hemorrhagic spinal schwannoma with atypical presentation. *J Radiol Sci* 2011;36:191-4.
8. Sahoo RK, Das PB, Sarangi GS, Mohanty S. Acute hemorrhage within intradural extramedullary schwannoma in cervical spine presenting with quadriplegia. *J Craniovertebr Junction Spine* 2015;6:83-5.
9. Zhang HZ, Li Y, Han Y, Wang X, She L, Yan Z, *et al.* Spontaneous acute hemorrhage of intraspinal canal cellular schwannoma with paraplegia: A case report. *Br J Neurosurg* 2015;29:425-7.
10. Vaibhav N, Mahalingam SS, Parthiban JK. Hemorrhage within the schwannoma of thoracic spinal cord presenting as acute rapidly progressive paraplegia: A rare case. *J Spinal Surg* 2016;3:160-2.
11. Jaiswal A, Shetty AP, Rajasekaran S. Giant cystic intradural schwannoma in the lumbosacral region: A case report. *J Orthop Surg (Hong Kong)* 2008;16:102-6.
12. Prasad GL, Kongwad LI, Valiathan MG. Spinal intradural schwannoma with acute intratumoural haemorrhage: Case report and review. *J Clin Diagn Res* 2016;10:PD01-3.
13. Vázquez-Barquero A, Pascual J, Quintana F, Figols J, Izquierdo JM. Cervical schwannoma presenting as a spinal subdural haematoma. *Br J Neurosurg* 1994;8:739-41.
14. Jenkins AL 3rd, Ahuja A, Oliff AH, Sobotka S. Spinal schwannoma presenting due to torsion and hemorrhage: Case report and review of literature. *Spine J* 2015;15:e1-4.
15. Tanaka H, Kondo E, Kawato H, Kikukawa T, Ishihara A, Toyoda N. Spinal intradural hemorrhage due to a neurinoma in an early puerperal woman. *Clinical Neurology and Neurosurgery* 2002;104:303-5.
16. Cohen ZR, Knoller N, Hadani M, Davidson B, Nass D, Ram Z. Traumatic intratumoral hemorrhage as the presenting symptom of a spinal neurinoma. Case report. *Journal of Neurosurgery* 2000;93(2 suppl):327-9.
17. Uemura K, Matsumura A, Kobayashi E, Tomono Y, Nose T. CT and MR presentation of acute hemorrhage in a spinal schwannoma. *Surgical Neurology* 1998;50:219-20.
18. Ichinose T, Takami T, Yamamoto N, Tsuyuguchi N, Ohata K. Intratumoral hemorrhage of spinal schwannoma of the cauda equina manifesting as acute paraparesis—case report. *Neurologia medico-chirurgica (Tokyo)* 2009;49:255-7.
19. Ng PY. Schwannoma of the cervical spine presenting with acute hemorrhage. *Journal of clinical neuroscience* 2001;8:277-8.
20. Smith RA. Spinal subdural hematoma, neurilemmoma, and acute transverse myelopathy. *Surgical Neurology* 1985;23:367-70.