

Hiatal Hernia Repair with Novel Biological Graft Reinforcement

Kent C. Sasse, MD, MPH, David L. Warner, BS, Ellen Ackerman, PA-C, Jared Brandt, PA-C

ABSTRACT

Background and Objectives: Hiatal hernias are repaired laparoscopically with increasing use of reinforcement material. Both synthetic and biologically derived materials reduce the recurrence rate compared to primary crural repair. Synthetic mesh introduces complications, such as mesh erosion, fibrosis, and infection. Urinary bladder matrix (UBM) represents a biologically derived material for use in hiatal hernia repair reinforcement with the potential to improve durability of repair without incurring the risks of other reinforcement materials.

Methods: The 15 cases presented involved hiatal hernia repair with primary crural repair with UBM reinforcement and fundoplication. Patients were followed for an average of 3 years, and were assessed with upper gastrointestinal (GI) series, endoscopy, and assessments of subjective symptoms of gastroesophageal reflux disease (GERD).

Results: Hernia diameters averaged 6 cm. Each repair was successful and completed laparoscopically. UBM exhibited favorable handling characteristics when placed as a horseshoe-type graft sutured to the crura. One patient underwent endoscopic balloon dilatation of a mild post-operative stenosis that resolved. No other complications occurred. In more than 3 years of follow-up, there have been no recurrences or long-term complications. GERD-health-related quality of life (HRQL) scores averaged 6 (range, 0–12, of a possible 50), indicating little reflux symptomatology. Follow-up upper GI series were obtained in 9 cases and showed intact repairs. An upper endoscopy was performed in 8 patients and showed no recurrences.

Conclusion: Surgeons may safely use laparoscopic fundoplication with UBM reinforcement for successful repair

of hiatal hernias. In this series, repairs with UBM grafts have been durable at 3 years of follow-up and may serve as an alternative to synthetic mesh reinforcement of hiatal hernia repairs.

Key Words: Hiatal hernia, Upper GI surgery, Urinary bladder matrix.

INTRODUCTION

Hiatal hernias remain a common disorder with progression to severe symptoms and disability in some cases. Most are managed nonoperatively, but some require surgery because of progressive symptoms of reflux, pain, hemorrhage, aspiration, and obstruction. Synthetic and biologically derived mesh reinforcement result in lower rates of hernia recurrence than native tissue repair alone.^{1–7} Although there is no clear consensus, increasing concerns have been raised in the literature with respect to the complications of synthetic mesh repairs.^{8–11} Biologically derived materials, proposed as an alternative to minimize mesh-related complications of erosion and infection, are increasingly used for hiatal hernia repairs.^{3–7} UBM consists of the epithelial basement membrane and lamina propria of the porcine urinary bladder. After decellularization, it retains biochemical diversity, an architecture that is similar to the normal tissue, and strong mechanical behavior.^{12,13} UBM has shown effectiveness in animal studies and human clinical use for management of complex wounds and reinforcement of surgically repaired soft tissue with connective tissue remodeling in anatomic settings as diverse as esophageal, urinary bladder, pelvic floor, body wall repair, and superficial wound-healing.^{14–18} Use of UBM in hiatal hernia repair has been documented,⁷ but this paper represents the first series with follow-up to assess symptoms as well as radiographic durability over 3 years.

METHODS

Fifteen cases of hiatal hernia repair with fundoplication and UBM graft reinforcement were performed from

University of Nevada School of Medicine, Reno, Nevada, USA (all authors).

Disclosures: Dr. Sasse receives speaking honoraria from ACell Inc. The remaining authors report no disclosures.

Address correspondence to: David L. Warner, BS, University of Nevada School of Medicine, 75 Pringle Way, Suite 804, Reno, NV 89509. Telephone: 775-829-7999, Fax: 775-829-7970, E-mail: dwardner@medicine.nevada.edu

DOI: 10.4293/JSLs.2016.00016

© 2016 by JSLs, *Journal of the Society of Laparoendoscopic Surgeons*. Published by the Society of Laparoendoscopic Surgeons, Inc.

2010 through 2014. Increased pain, reflux, hemorrhage, aspiration, or compressive symptoms were the indications for surgical repair. Nine women and 6 men, with an average age of 53 and an average BMI of 34, underwent surgery. Patient information is presented in **Table 1**. Laparoscopic repair was performed in all 15 cases, using primary crural repair followed by UBM device placement (MatriStem Surgical Matrix PSM ; ACell, Inc., Columbia, Maryland, USA) and fundoplication. The cost of the graft was \$1600. In each case, the gastric and omental contents were fully reduced, and 2–3 cm of distal esophagus was freed below the crura (**Figures 1 and 2**). The crural defect averaged 6 cm in diameter and after primary crural repair using 0-Ethibond sutures, the crural reinforcement was performed with a horseshoe-shaped UBM 10 × 15-cm xenograft reinforcement secured to the crura by absorbable sutures (**Figure 3**). Fundoplication was then performed with either a complete or partial wrap, based on the patient’s esophageal motility (**Figure 4**).

After an average of more than 3 years, each patient provided gastroesophageal reflux–health-related quality of life (GERD-HRQL) score survey responses via telephone or in-person interview.¹⁹ Nine of the patients underwent radiographic upper GI series (UGIS) examinations (**Figures 5 and 6**). Six patients underwent esophagogastroduodenoscopy (EGD) or had records from EGD performed at outside facilities, including 2 of the 9 patients who had undergone UGIS.

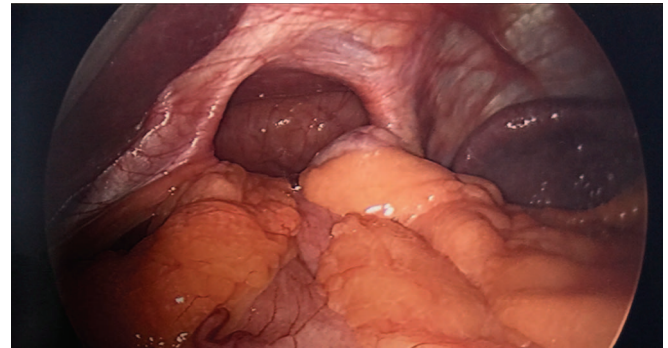


Figure 1. Large hiatal hernia.

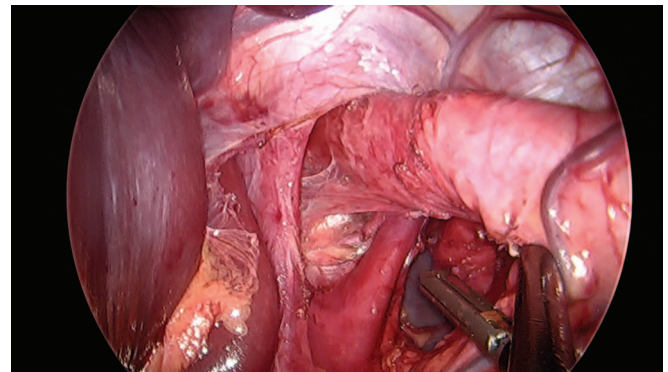


Figure 2. Developing at least 2–3 cm of intra-abdominal esophagus.

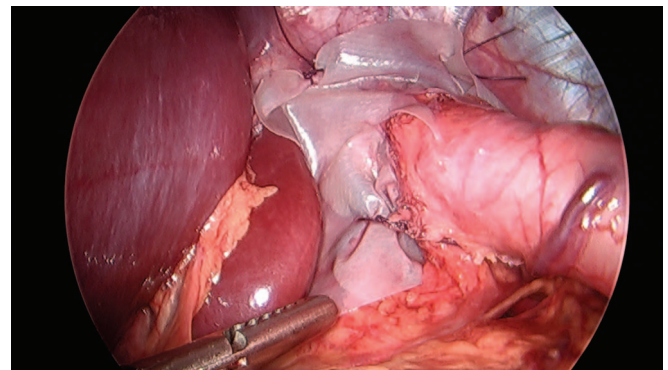


Figure 3. Completed reinforcement of crural repair with horseshoe-shaped UBM graft.

Table 1.	
Patient and Procedure Information	
Patient and Procedure Description	Data
N	15
Age	53 (27–72)
Female/Male, n	9/6
BMI	34 (22–59)
Length of stay (days)	1.6 (1.0–3.2)
Operative time (min)	56 (36–136)
Complication	1 (stenosis, dilated with EGD)
Follow-up (months)	37 (24–56)
Recurrences	0
3-Year GERD-HRQL score (median)	6 (0–12 of a possible 50)

Data are the mean (range) unless otherwise specified.

RESULTS

Each repair was successful. The handling properties of the UBM material was favorable, including ease of insertion via a 12-mm trocar, maneuvering into position, and suturing to the crura. One patient experienced dysphagia after surgery that required endoscopic dilatation 4 weeks after repair and resolved. No other

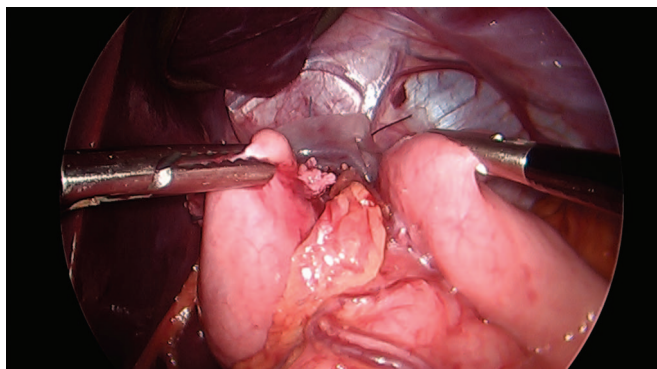


Figure 4. Creating the fundoplication.

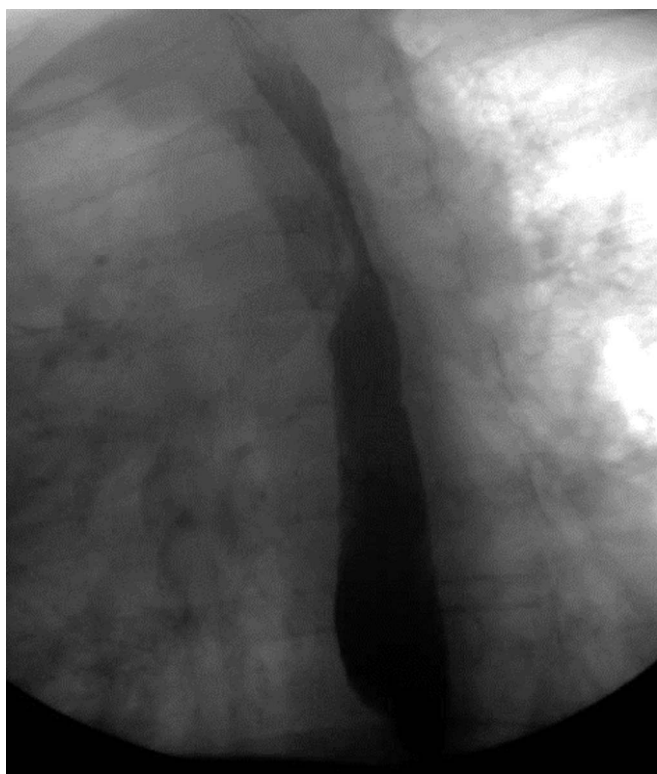


Figure 5. Esophagram after 3 years showing no recurrence.

complications occurred. Each patient had an intact repair at a median of 37 months of follow-up, and no erosions, infections, or late strictures occurred. GERD-HRQL scores in 15 patients ranged from 0 to 12, with 4 patients reporting a score of 0. The median GERD-HRQL score was 6 indicating little reflux symptomatology. (The range of this scoring instrument is 0–50.) Upper GI series radiographs in 9 patients indicated intact repairs at 3 years, without evidence of recurrence

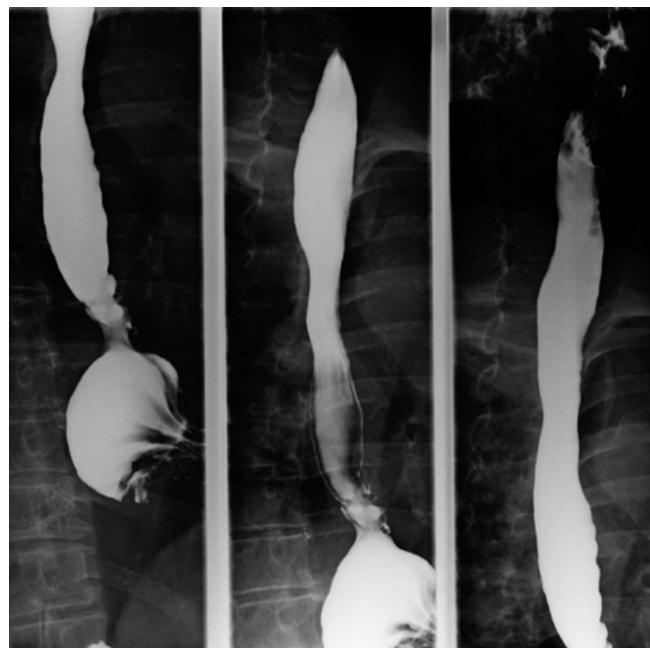

Figure 6. Esophagram after 3 years showing intact fundoplication without recurrence.

(**Figures 5 and 6**). EGD in 6 patients demonstrated no recurrent hiatal hernias.

DISCUSSION

Hiatal hernia is a common problem that can result in significant symptoms and risk if untreated. A minority of such cases progresses to involve increasing pain, hemorrhage, or obstruction, and a few require emergency surgical repair. Recurrence of hiatal hernia is not uncommon. Short-term recurrence rates of 16.7 and 3.7% for suture repair and mesh repair, respectively, have been reported in a review of cases of hiatal hernia repair by Antoniou et al.² There is no consensus on a single best method for hiatal hernia repair.^{1–11} The cases presented in this series represent successful treatment of hiatal hernias with biologically derived graft reinforcement with UBM material, providing satisfactory repairs and durability beyond 3 years.

Repair of hiatal hernias with biologically derived mesh material has been shown to lower recurrence rates when compared to native tissue repair alone.⁴ Reoperations and repairs of recurrent hiatal hernias are challenging cases with higher potential for complications. Some recurrences require emergency surgery, and a large review of the risks of morbidity, mortality, and recurrence after hiatal hernia repairs showed that emer-

gency repairs are associated with higher postoperative complications and mortality risk.²⁰

Mesh erosion or infection remain as late complications in hiatal hernia repair with synthetic mesh, including polytetrafluoroethylene (PTFE).⁶ Synthetic mesh repair has been found to offer superior rates of durability when compared to primary sutured repair, but has not been measured against biologically derived graft repairs. In a randomized, controlled, prospective trial comparing use of mesh with primary repair for hiatal hernia, use of mesh significantly reduced the rate of recurrent hernias over native tissue repair alone.¹ The durability of UBM has not been compared to synthetic mesh, so it is unknown whether a lower potential graft-erosion risk and infection rate of the UBM would be realized and whether a corresponding higher rate of recurrence might result from the widespread use of UBM material to reinforce hiatal hernia repairs. UBM grafts handle favorably in the laparoscopic surgical environment and are easier to suture than some grafts. At a cost of \$1600 per graft, the UBM devices cost considerably more than synthetic grafts and less than many comparable biological grafts, which range from \$1400 to \$3000 at our facility.

The rationale for using biologically derived materials for hiatal hernia repair²⁻⁷ is the potentially lower rate of mesh erosion and mesh infection.³⁻⁷ Few complications are believed to occur with biologically derived mesh repairs, although one complication of dysphagia and a sterile abscess was reported, related to biologically derived mesh, required surgery to resolve.¹¹ The UBM devices include an intact epithelial basement membrane on one surface and a lamina propria layer on the opposite surface; contain multiple types of carbohydrates, collagens, proteins, and other components; and are gradually resorbed after implantation.¹²⁻¹⁵ UBM has been shown to facilitate a constructive remodeling process in numerous areas of the body that reduces scarring and facilitates the restoration of normal site-appropriate tissue.¹³⁻¹⁷ For these reasons, UBM material has been considered potentially advantageous in the reinforcement of the repair of large hiatal hernias.

CONCLUSIONS

At 3 years of follow-up after hiatal hernia repair with UBM reinforcement, were no recurrences, abscesses, stenoses, or erosions. Future investigation and long-term follow-up would determine which devices offer the most cost-effective hernia repair reinforcement that

reduces the risk of erosion, stenosis, and graft infection while providing a durable repair. It is hoped that future studies will compare the advantages and cost effectiveness of a broadening array of reinforcement materials for hiatal hernia repair.

References:

1. Frantzides CT, Madan AK, Carlson MA, Stavropoulos GP. A prospective, randomized trial of laparoscopic polytetrafluoroethylene (PTFE) patch repair vs. simple cruroplasty for large hiatal hernia. *Arch Surg*. 2002;137:649–652.
2. Antoniou SA, Müller-Stich BP, Antoniou GA, et al. Laparoscopic augmentation of the diaphragmatic hiatus with biologic mesh versus suture repair: A systematic review and meta-analysis. *Langenbecks Arch Surg*. 2015;400:577–583.
3. Schmidt E, Shaligram A, Reynoso JF, Kothari V, Oleynikov D. Hiatal hernia repair with biologic mesh reinforcement reduces rate in small hiatal hernias. *Dis Esophagus*. 2014;27:13–17.
4. Oelschlager BK, Pellegrini CA, Hunter J, et al. Biologic prosthesis reduces recurrence after laparoscopic paraesophageal hernia repair: A multicenter, prospective, randomized trial. *Ann Surg*. 2006;244:481–490.
5. Ward KC, Costello KP, Baalman S, et al. Effect of acellular human dermis buttress on laparoscopic hiatal hernia repair. *Surg Endosc*. 2015;29:2291–2297.
6. Diaz DF, Roth JS. Laparoscopic paraesophageal hernia repair with a cellular dermal matrix cruroplasty. *JLS*. 2011;15:355–360.
7. Reznichenko AA. Different biologic grafts for diaphragmatic crura reinforcement during laparoscopic repair of large hiatal hernia: A 6-year single surgeon experience. *J Med Imp Surg*. 2015;1:2–6.
8. Lebenthal A, Waterford SD, Fischella PM. Treatment and controversies in paraesophageal hernia repair. *Front Surg*. 2015; 2:13.
9. Stalhuber RJ, El Sherif A, Mittal SK, et al. Mesh complications after prosthetic reinforcement of hiatal closure: A 28-case series. *Surg Endosc*. 2009;23:1219–1226.
10. Frantzides CT, Carlson MA, Loizides S, et al. Hiatal hernia repair with mesh: A survey of SAGES members. *Surg Endosc*. 2010;24:1017–1024.
11. Furnée EJ, Smith CD, Hazebroek EJ. The use of mesh in laparoscopic large hiatal hernia repair: A survey of European surgeons. *Surg Laparosc Endosc Percutan Tech*. 2015;25:307–311.
12. Brown B, Lindberg K, Reing J, Stolz DB, Badylak SF. The basement membrane component of biologic scaffolds derived from extracellular matrix. *Tissue Eng*. 2006;12:519–526.

13. Gilbert TW, Wognum S, Joyce EM, Freytes DO, Sacks MS, Badylak SF. Collagen fiber architecture and biaxial mechanical behavior of extracellular matrix scaffolds derived from the porcine urinary bladder. *Biomaterials*. 2008;29:4775–4782.
14. Gilbert TW, Nieponice A, Spievack AR, Holcomb CJ, Gilbert S, Badylak SF. Repair of the thoracic wall with an extracellular matrix scaffold in a canine model. *J Surg Res*. 2007;147:61–67.
15. Badylak SF, Vorp DA, Spievack AR, et al. Esophageal reconstruction with ECM and muscle tissue in a dog model. *J Surg Res*. 2005;128:87–97.
16. Nieponice A, Ciotola FF, Nachman F, et al. Patch esophagoplasty: esophageal reconstruction using biological scaffolds. *Ann Thor Surg*. 2014;97:283–288.
17. Sasse KC, Ackerman EM, Brandt JR. Complex wounds treated with MatriStem xenograft material: case series and cost analysis. *OA Surg*. 2013;1:3.
18. Afaneh C, Abelson J, Schattner M, et al. Esophageal reinforcement with an extracellular scaffold during total gastrectomy for gastric cancer. *Ann Surg Oncol*. 2015;22:1252–1257.
19. Velanovich V. The development of the GERD-HRQL symptom severity instrument. *Dis Esophagus*. 2007;20:130–134.
20. Poulouse BK, Gosen C, Marks JM, et al. Inpatient mortality analysis of paraesophageal hernia repair in octogenarians. *J Gastrointest Surg*. 2008;12:1888–1892.