



Fatal Recurrent *Staphylococcus aureus* Infection in a Patient With an Aortic Endostent Under Alirocumab

Claudia Stöllberger¹ , Gerard Mertikian², Dorit Stahl¹ and Josef Finsterer¹

¹Hospital Rudolfstiftung, Vienna, Austria. ²Hospital Hietzing, Vienna, Austria.

Infectious Diseases: Research and Treatment
Volume 12: 1–4
© The Author(s) 2019
Article reuse guidelines:
sagepub.com/journals-permissions
DOI: 10.1177/1178633719885387


ABSTRACT

PURPOSE: Aortic stent-graft infection (SGI) entails a high mortality. Alirocumab is a monoclonal antibody to proprotein convertase subtilisin/kexin type 9 (PCSK9), approved for treatment of therapy-refractory hypercholesterolemia. Proprotein convertase subtilisin/kexin type 9 might play a role in infections.

CASE REPORT: A 68-year-old male suffered from fatigue, fever, and back pain. Twelve months previously, a 4-fold-fenestrated aortic endoprosthesis was implanted because of an aortic aneurysm. Four months later, alirocumab 150 mg was initiated. *Staphylococcus aureus* grew in several blood cultures, and he received cefazolin and fosfomycin. Fludeoxyglucose positron emission tomography computed tomography indicated an infected endoprosthesis. Puncture of the periprosthetic space under antibiotic therapy revealed different strains of *Staphylococcus epidermidis*. The therapy was changed to dalbavancin. The patient died suddenly 11 days later after complaining about back pain for several days. No autopsy was carried out.

CONCLUSIONS: The most probable cause of the patient's recurrent bacteremia with *S aureus* was an infection of the aortic prosthesis. Although this report is very speculative, it can be concluded that data about infections in patients under PCSK9 inhibitors should be collected systematically and more research is needed about the biological consequences of decreasing cholesterol to extreme low levels.

KEYWORDS: Hypercholesterolemia, aortic aneurysm, drug side effect, PCSK9 inhibitor, endovascular prosthesis, infection

RECEIVED: July 15, 2019. **ACCEPTED:** October 3, 2019.

TYPE: Case Report

FUNDING: The author(s) received no financial support for the research, authorship, and/or publication of this article.

DECLARATION OF CONFLICTING INTERESTS: The author(s) declared no potential conflicts of interest with respect to the research, authorship, and/or publication of this article.

CORRESPONDING AUTHOR: Claudia Stöllberger, Hospital Rudolfstiftung, Juchgasse 25, A-1030 Vienna, Austria. Email: claudia.stoellberger@chello.at

Introduction

Aortic stent-graft infection (SGI) is rare but entails a high mortality, especially when not treated surgically.^{1,2} The microorganisms most frequently identified in SGI are *Staphylococci*. Alirocumab is a monoclonal antibody to proprotein convertase subtilisin/kexin type 9 (PCSK9) which was approved in 2015 for the treatment of adults with hypercholesterolemia. In randomized trials comparing alirocumab with either placebo or ezetimibe, alirocumab was associated with a higher incidence of respiratory tract infection signs and symptoms.³ There are indications that PCSK9, a ubiquitously expressed serine proteinase, plays a role in bacterial infections, and up to now, it is unclear whether it protects against or favors infections.⁴⁻⁷

Case Report

A 68-year-old Caucasian male was admitted in July 2018 because of fatigue, fever, and back pain. He had lost 14 kg within the previous month. He had a history of arterial hypertension, paroxysmal atrial fibrillation, coronary artery disease, stroke due occlusion of the left posterior cerebral artery, schizoaffective disorder, chronic sinusitis, sigmoid colon resection because of diverticulitis, diabetes mellitus, hyperlipidemia, and chronic renal failure.

Because of an incidentally detected abdominal aortic aneurysm, an endovascular aortic repair was planned in May 2017. Routinely taken swabs from nose showed growth of

Staphylococcus aureus, why he received a topical therapy with mupirocin for 7 days. Control swabs showed no growth of *S aureus* any more. In July 2017, a 4-fold-fenestrated aortic endoprosthesis (Anaconda™; VASCUTEK Ltd, Inchinnan, Scotland, UK) was placed in the abdominal aorta. As antibiotic prophylaxis, a single dose of cefazolin 2 g intravenously was given immediately before the intervention, according to the standards of the implanting center.

In September 2017, despite statins and ezetimibe, hyperlipidemia persisted with serum cholesterol 227 mg/dL, high-density lipoprotein (HDL) cholesterol 53 mg/dL, and triglycerides 560 mg/dL, why a therapy with alirocumab 150 mg subcutaneously every 2 weeks was initiated. In December 2017, a biopsy of the skin of the penis was taken which revealed acanthosis and hyperkeratosis, classified as penile intraepithelial low-grade neoplasia. In May 2018, he received a subcutaneous vaccination against tick-borne encephalitis.

In June 2018, he was admitted in another hospital because of fever and chest pain. *Staphylococcus aureus* grew in several blood cultures. He received meropenem for 15 days and was discharged with unidentified source of the bacteremia.

One month later he was admitted to our department. He was on a medication with phenprocoumon, risperidone 3 mg/d, aripiprazole 15 mg/d, linagliptin 5 mg/d, pantoprazole 40 mg/d, metoprolol 47.5 mg/d, ezetimibe 10 mg/d, rosuvastatin 20 mg/d, and gliclazide 90 mg/d. He had received the last dose of



Table 1. Results of blood tests.

PARAMETER (REFERENCE VALUE)	DAY 1	DAY 3	DAY 4	DAY 5	DAY 6	DAY 7	DAY 8	DAY 15
BUN, mg/dL (8-23)	24	18	18	19	18	16	18	15
Creatinine, mg/dL (<1.2)	1.85	1.76	1.77	1.58	1.54	1.54	1.81	1.39
Creat. Clear., mL/min (>90)	43	45	45	51	52	52	44	62
CRP, mg/L (<5)	215	199	216	170	150	157	144	50
Leukocytes, g/L (4.0-9.0)	7.9	7.3	6.3	6.5	NM	5.9	5.7	5.1
Hemoglobin, g/dL (14-17)	9.2	8.0	7.5	7.7	NM	10.3	10.1	10.0
Thrombocytes, g/L (150-450)	251	237	220	262	NM	283	301	231
Cholesterol, mg/dL (<200)	NM	56	NM	NM	NM	NM	NM	NM
HDL cholesterol, mg/dL (>55)	NM	32	NM	NM	NM	NM	NM	NM
LDL cholesterol, mg/dL (<130)	NM	7	NM	NM	NM	NM	NM	NM
Triglyceride, mg/dL (>150)	NM	80	NM	NM	NM	NM	NM	NM

Abbreviations: BUN, blood urea nitrogen; Creat. Clear., Creatinine clearance according to the Cockcroft-Gault formula; CRP, C-reactive protein; HDL, high-density lipoprotein; LDL, low-density lipoprotein; NM, not measured.

alirocumab 13 days before admission. Physical examination was without abnormalities, and blood pressure was 140/90 mm Hg. There were no signs of inflammation on the injection sites. The electrocardiogram showed sinus rhythm, Q waves in III and aVF, and negative T waves in V₄-V₆. Laboratory findings showed the already known impaired renal function, elevated C-reactive protein (CRP) level, and an increased blood sedimentation rate of 71 (normal: 2-37) mm/h (Table 1).

An intravenous antibiotic therapy with ampicillin/sulbactam 9 g/d was started and the infection signs decreased. Since the blood cultures showed growth of *S aureus*, the therapy was changed to cefazolin 6 g/d and fosfomycin 8 g/d and the systemic infection signs decreased further. Echocardiography showed no signs of endocarditis. Because of anemia, he received 2 units of packed erythrocytes.

Fludeoxyglucose (¹⁸F) positron emission tomography computed tomography (F-18 FDG PET/CT) was highly suggestive of an infected aortic prosthesis (Figures 1 and 2), why the patient was referred to the department where the prosthesis has been implanted 13 months previously. There, a CT-guided puncture of the periprosthetic space was carried out under antibiotic therapy. The 2 samples that were taken revealed the growth of 2 different strains of *Staphylococcus epidermidis* with different antibiotic resistance pattern, bacteria which have never been found in any blood cultures taken between onset of infection symptoms and discharge. Before discharge, the antibiotic therapy was changed to dalbavancin 1000 mg, scheduled to be given every second week. Eleven days after discharge, the patient died suddenly after having complained about back pain for several days. No autopsy was carried out.

Discussion

Although we have no proof, the most probable cause of our patient's recurrent bacteremia with *S aureus* was an infection of the aortic prosthesis. No other infection site has been found in the F-18 FDG PET/CT. Since no autopsy has been performed, we can only speculate about the cause of his death. Back pain in the days before the patient's demise, however, might be interpreted as a sign that his death was most probably due to aortic rupture in the setting of an infected graft, although pulmonary embolism, or myocardial infarction may be further possible causes of death.

The growth of 2 different strains of *S epidermidis* in 2 different samples, taken by CT-guided puncture under antibiotic therapy, is difficult to interpret. It could be due to contamination, considering that different strains of *S epidermidis* were found in each sample and none had been detected in blood cultures before. However, it cannot be excluded that these less virulent bacteria were part of an underlying late graft infection. At least these bacteria were not likely to be responsible for the acute infection, since infection signs decreased, even one of the coagulase-negative *Staphylococci* was not covered by the given antibiotic treatment. The antibiotic treatment had been changed only after the finding of the biopsy to agents susceptible to all detected bacteria.

Surgical intervention was not considered as an option since the endograft was fenestrated and the involvement of the visceral vessels (ie coeliac trunk, superior mesenteric artery, and the renal arteries) precluded the ligation of the suprarenal aorta, thus a conservative therapy with antibiotic therapy was deemed as the most appropriate therapy.

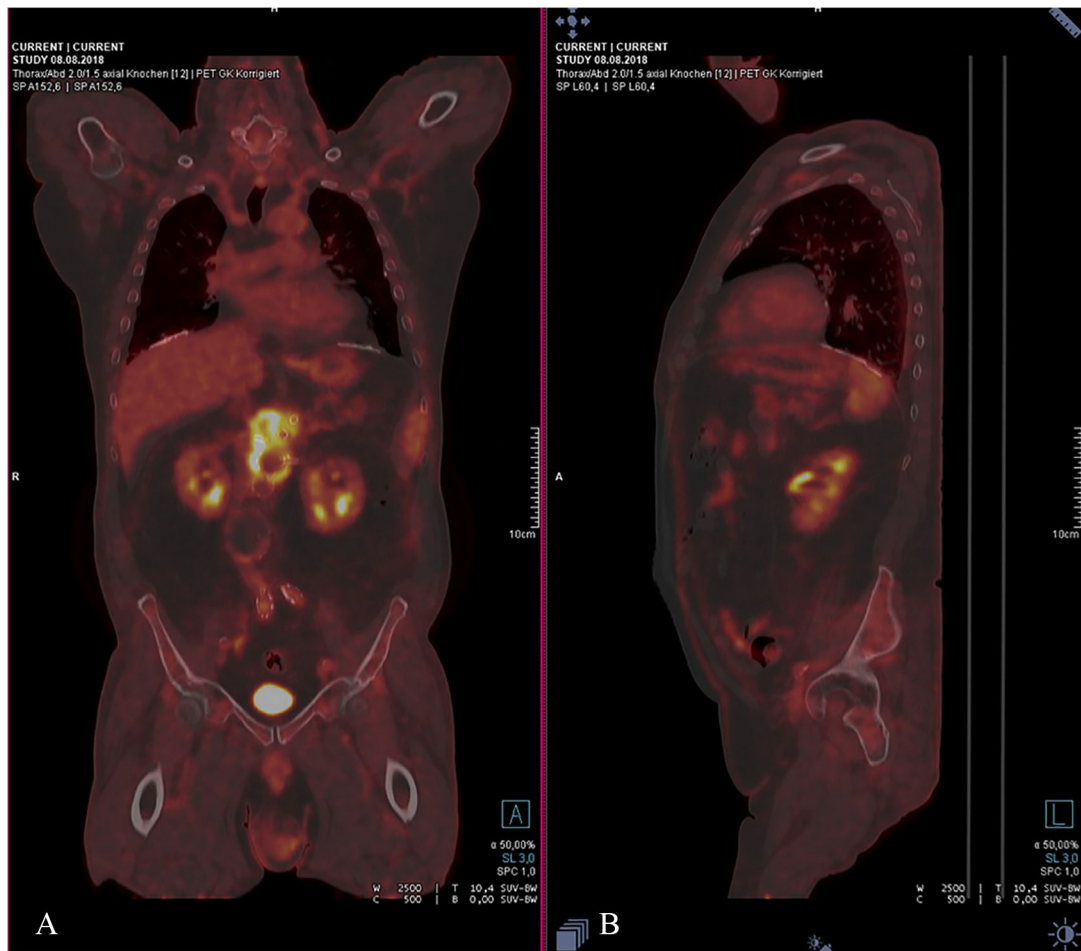


Figure 1. Fludeoxyglucose (^{18}F) positron emission tomography computed tomography shows enhancement of tracer around the graft in the abdominal aorta in the (A) coronal and (B) sagittal plane.

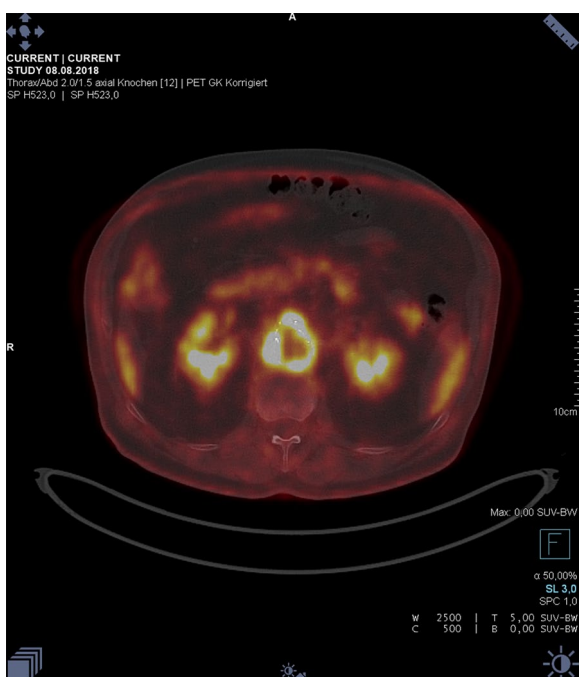


Figure 2. Fludeoxyglucose (^{18}F) positron emission tomography computed tomography shows enhancement of tracer around the graft in the abdominal aorta in the axial plane.

Aortic SGI is a rare complication, occurring in 0.2% to 0.7% of patients after endovascular graft implantation. Stent-graft infection can be classified into early and later presentation, and the timing of presentation is associated with specific causative pathogens.¹ In our patient, it is rather unlikely that SGI was caused by exposure to the virulent *S aureus* at the time of implantation, since the signs of infection with *S aureus* developed only 11 months after implantation. Possible sources for the primary *S aureus* infection of our patient could be the chronic sinusitis and the genital skin disease with biopsy 5 months after implantation of the prosthesis. It is not very likely that the biopsy was the entry site of the *S aureus* considering the time of intervention, the virulence of the microorganism, and the onset of infection signs. Another entry sites for *S aureus* could be the subcutaneous injections with alirocumab every second week or the vaccination against tick-borne encephalitis several weeks before onset of the clinical signs of infection.

Since SGI is a rare complication, the question arises why our patient had developed SGI. His comorbidities—chronic renal failure and diabetes—might have favored the development of an infection. In addition, it should be considered whether the comedication with alirocumab might have

created a state of immunosuppression. So far, it is controversially assessed whether PCSK9 inhibition is immunosuppressive or may protect against infections.^{3,4,5,7} Proprotein convertase subtilisin/kexin type 9 may play a critical role in the innate immune defense against bacterial and/or viral infections.^{4,6} A recently published study about 481 patients with blood-culture-positive infection showed that PCSK9 is upregulated in blood-culture-positive infections. Plasma PCSK9 resembles acute-phase proteins; its expression is induced during an infection, reduced in liver disease, and correlates positively with CRP level.⁷

Unfortunately, infections were not systematically registered as side effects in the randomized trials investigating the PCSK9 inhibitors alirocumab or evolucumab.^{8,9} They concentrated on local injection site reactions, general allergic events, neurological events, hepatic disorders, and ophthalmologic events.^{3,9} Furthermore, it is unknown how often patients, included in PCSK9 inhibitor investigating trials, received endovascular prostheses or other implanted devices, and how often infection of devices and prosthesis occurred during PCSK9 inhibitor therapy.

Our patient had extremely low cholesterol levels, as indicated in Table 1. Very low low-density lipoprotein cholesterol levels (<20 mg/dL) are unusual in healthy persons and develop during PCSK9 inhibition in about 10%.^{10,11} Unfortunately, infections were not assessed and reported as side effects in patients who developed extreme low cholesterol levels during the PCSK9 inhibitor investigating trials, thus we do not know whether these patients are prone to more infections than patients with higher cholesterol levels.^{10,11} There are indications that extreme low cholesterol levels impair the immune system.^{12,13} It is furthermore unknown whether extreme low cholesterol levels affect the permeability barrier of the skin which is mediated primarily by lipid-enriched lamellar membranes of the stratum corneum. These membranes contain approximately 50% ceramides, 25% cholesterol, and 15% free fatty acids.¹⁴ In our patient, however, it cannot be assessed whether low cholesterol was cause or consequence of the infection, since infection and inflammation are known to decrease serum cholesterol levels in humans.¹⁵

Conclusions


Although this report is very speculative, it can be concluded that data about infections in patients under PCSK9 inhibitors should be collected systematically and more research is needed

about the biological consequences of decreasing cholesterol to extreme low levels.

Author Contributions

CS: caring for the patient, literature research, drafting of the manuscript, corresponding author. GM: caring for the patient, drafting of the manuscript. DS: caring for the patient, drafting of the manuscript. JF: literature research, drafting of the manuscript.

ORCID iD

Claudia Stöllberger  <https://orcid.org/0000-0001-7335-3120>

REFERENCES

1. Bianco V, Kilic A, Gleason TG, et al. Management of thoracic aortic graft infections. *J Card Surg.* 2018;33:658-665. doi:10.1111/jocs.13792.
2. Li HL, Chan YC, Cheng SW. Current evidence on management of aortic stent-graft infection: a systematic review and meta-analysis. *Ann Vasc Surg.* 2018;51:306-313. doi:10.1016/j.avsg.2018.02.038.
3. Jones PH, Bays HE, Chaudhari U, et al. Safety of Alirocumab (A PCSK9 monoclonal antibody) from 14 randomized trials. *Am J Cardiol.* 2016;118:1805-1811. doi:10.1016/j.amjcard.2016.08.072.
4. Khademi F, Montazi-Borojeni AA, Reiner Ž, et al. PCSK9 and infection: a potentially useful or dangerous association? *J Cell Physiol.* 2018;233:2920-2927. doi:10.1002/jcp.26040.
5. Paciullo F, Fallarino F, Bianconi V, Mannarino MR, Sahebkar A, Pirro M. PCSK9 at the crossroad of cholesterol metabolism and immune function during infections. *J Cell Physiol.* 2017;232:2330-2338. doi:10.1002/jcp.25767.
6. Liu X, Suo R, Chan CZY, Liu T, Tse G, Li G. The immune functions of PCSK9: local and systemic perspectives. *J Cell Physiol.* 2019;234:19180-19188. doi:10.1002/jcp.28612.
7. Rannikko J, Jacome Sanz D, Ortutay Z, et al. Reduced plasma PCSK9 response in patients with bacteraemia is associated with mortality [published online ahead of print June 5, 2019]. *J Intern Med.* doi:10.1111/joim.12946.
8. Schwartz GG, Bessac L, Berdan LG, et al. Effect of alirocumab, a monoclonal antibody to PCSK9, on long-term cardiovascular outcomes following acute coronary syndromes: rationale and design of the ODYSSEY outcomes trial. *Am Heart J.* 2014;168:682-689. doi:10.1016/j.ahj.2014.07.028.
9. Sabatine MS, Giugliano RP, Keech AC, et al. Evolocumab and clinical outcomes in patients with cardiovascular disease. *N Engl J Med.* 2017;376:1713-1722.
10. Robinson JG, Rosenson RS, Farnier M, et al. Safety of very low low-density lipoprotein cholesterol levels with alirocumab: pooled data from randomized trials. *J Am Coll Cardiol.* 2017;69:471-482. doi:10.1016/j.jacc.2016.11.037.
11. Giugliano RP, Pedersen TR, Park JG, et al. Clinical efficacy and safety of achieving very low LDL-cholesterol concentrations with the PCSK9 inhibitor evolucumab: a prespecified secondary analysis of the FOURIER trial. *Lancet.* 2017;390:1962-1971. doi:10.1016/S0140-6736(17)32290-0.
12. Andersen CJ. Impact of dietary cholesterol on the pathophysiology of infectious and autoimmune disease. *Nutrients.* 2018;10:E764. doi:10.3390/nu10060764.
13. Kaysen GA, Ye X, Raimann JG, et al. Lipid levels are inversely associated with infectious and all-cause mortality: international MONDO study results. *J Lipid Res.* 2018;59:1519-1528. doi:10.1194/jlr.P084277.
14. Feingold KR, Elias PM. Role of lipids in the formation and maintenance of the cutaneous permeability barrier. *Biochim Biophys Acta.* 2014;1841:280-294. doi:10.1016/j.bbali.2013.11.007.
15. Khovidhunkit W, Kim MS, Memon RA, et al. Effects of infection and inflammation on lipid and lipoprotein metabolism: mechanisms and consequences to the host. *J Lipid Res.* 2004;45:1169-1196.