

Case Report

Clinical and Radiographic Success of Selective Caries Removal to Firm Dentin in Primary Teeth: 18-Month Follow-Up

Tássia Carina Stafuzza,¹ Luciana Lourenço Ribeiro Vitor ¹, Daniela Rios ¹,
Thiago Cruvinel Silva ¹, Maria Aparecida Andrade Moreira Machado ^{1,2},
and Thais Marchini Oliveira ^{1,2}

¹Department of Pediatric Dentistry, Orthodontics, Public Health, Bauru School of Dentistry, University of São Paulo, Bauru, SP, Brazil

²Hospital for the Rehabilitation of Craniofacial Anomalies, University of São Paulo, Bauru, SP, Brazil

Correspondence should be addressed to Thais Marchini Oliveira; marchini@usp.br

Received 16 December 2017; Accepted 14 February 2018; Published 26 March 2018

Academic Editor: Ali I. Abdalla

Copyright © 2018 Tássia Carina Stafuzza et al. This is an open access article distributed under the Creative Commons Attribution License, which permits unrestricted use, distribution, and reproduction in any medium, provided the original work is properly cited.

The selective caries removal is increasingly spreading in daily clinical practice because this minimally invasive technique treats deep carious lesion and decreases the risk of pulp exposure. This case report was aimed at describing the selective removal to firm dentin on the primary mandibular left first molar of a girl aged 7 years and 6 months. The Mineral Trioxide Aggregate (MTA Angelus™) was used as liner, and the tooth was definitively restored with resin-modified glass ionomer cement (Vitremer™). The clinical and radiographic following-up was performed at 6, 12, and 18 months after treatment. The treatment showed satisfactory results after 18-month following-up, suggesting that this minimally invasive approach for carious lesion removal can replace the total removal, when properly indicated. Notwithstanding, further randomized clinical trials with longer following-up periods are still necessary.

1. Introduction

Currently the literature reports many studies on selective caries removal [1–6]. The selective removal to firm dentin [7] enables the change in the carious lesion microenvironment, decreases the number and bacterial diversity which stops the carious lesion progression, reduces the risk of pulp exposure [8], and preserves pulp vitality [6]. Although growing evidences indicate that minimally invasive approaches are effective to treat carious lesions [9], selective caries removal success may depend on the appropriate use of liners and restorative materials.

Many bacteriostatic, bactericidal, and remineralizing materials can be applied to the remaining dentin after selective caries removal [1, 10], but no consensus exist on which liner would be the most suitable for teeth undergoing selective caries removal [5, 10]. Randomized clinical trials and systematic reviews are necessary to clarify the persistent doubts.

Faced with this reality, caries tissue management techniques have been widely discussed [5, 9, 11]. Thus, this case report describes the selective removal to firm dentin in the primary mandibular left first molar of a girl aged 7 years and 6 months using the Mineral Trioxide Aggregate (MTA Angelus) as a pulp protective material.

2. Case Report

A girl aged 7 years and 6 months searched treatment at the Pediatric Dentistry Clinic of the Bauru School of Dentistry, University of São Paulo. During the anamnesis, the mother reported no spontaneous pain in the primary mandibular left first molar what was confirmed by the girl during the clinical examination. In the clinical and radiographic examination, the presence of deep occlusal carious lesion close to the pulp was observed (Figures 1(a) and 1(b)).

First, topical anesthesia was performed with benzocaine (Benzotop DFL) applied to the previously dried mucosa with

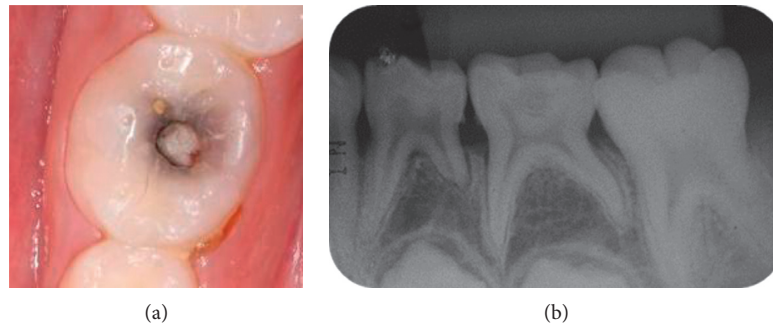


FIGURE 1: (a) Initial clinical aspect of the primary mandibular left first molar. (b) Initial periapical radiograph of the primary mandibular left first molar. Note the proximity of the carious lesion to the pulp.

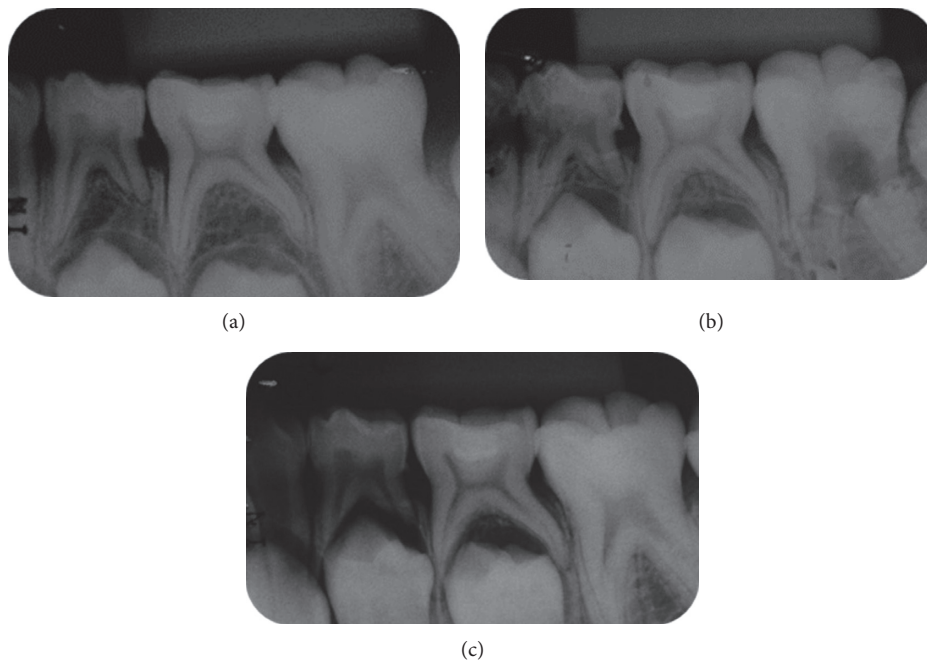


FIGURE 2: Radiographic following-up: (a) 6 months, (b) 12 months, and (c) 18 months.

the aid of a cotton pellet. Local infiltrative anesthesia of inferior alveolar nerve was performed with articaine 4% and epinephrine 1 : 100.000 [12–15]. After rubber dam isolation, the total caries removal was performed on the lateral walls of the cavity with low-speed round burs (sizes 4, 5, and 6, KG Sorensen, São Paulo, Brazil). Selective caries removal was executed on pulpal wall with hand excavators until firm dentin, and it was possible to observe that the remaining dentin had a darker color and leathery consistency. Before applying the protective material, the cavity was cleaned and dried with sterile cotton pellet. The MTA (Angelus, Londrina, PR, Brazil) was mixed according to the manufacturer's instructions on a sterile glass plate and directly placed on the pulpal wall reaching a thickness of 2 mm. The resin-modified glass ionomer cement (RMGIC) (Vitremer, 3M/ESPE, Minnesota, USA) was mixed at 1 : 1 powder/liquid ratio and applied to the cavity with a Centrix syringe (Centrix™, Nova DFL, Taquara, Rio de Janeiro, RJ, Brazil). At the end, the patient's occlusion was checked.

During the 18-month following-up period, no pain, mobility, sensitivity to percussion, abscess/fistula, restoration failure (such as partial fracture or loss of restoration), internal/external resorption, signs of furcal impairment, and advanced rhizolysis stage were observed (Figures 2(a)–Figures 2(c) and 3).

3. Discussion

With the diagnosis of deep caries lesion without pulp involvement, there were two possible treatment options: total or selective caries removal. Total caries removal could lead to pulp exposure. In addition, the removal of all carious dentin from the cavity is no longer necessary to manage the carious lesion [9]. So, for this case, we choose the selective caries removal to avoid greater damage to the tooth [1–3, 9] and to minimize the potential complications of complete excavation of carious dentin close to the pulp by avoiding pulpotomy and a breach in the pulp [1–3].

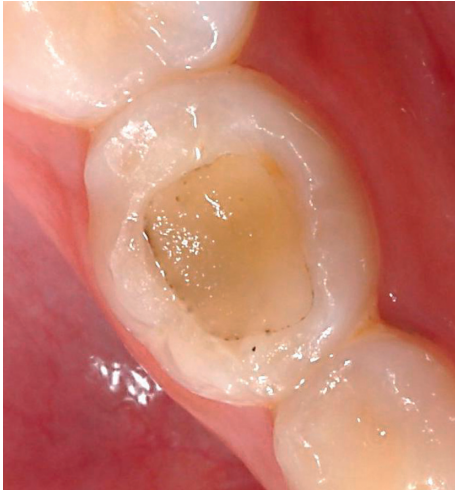

FIGURE 3: Clinical aspect at 18 months of follow-up.

Another advantage of the proposed treatment is the permanence of the primary teeth in the oral cavity until its natural exfoliation period [16], a fact that should be highlighted in the dental treatment of children. In this case report, the patient was seven and a half years old, which suggests that the primary molar will remain for at least 3-4 years in her mouth. With all this preexfoliation time, it has become imperative to perform a minimally invasive treatment that preserves the prognosis of dental longevity.

Scientific evidence reported significant chemical and morphological differences between dentin in permanent and primary teeth. The diameter of the dentinal tubules is larger in the primary teeth. This structural feature suggests that primary teeth may be more susceptible to sensitivity and transmission of harmful substances to pulp [17]. Thus, to ensure a correct indication of the therapy, the first primary molar treated in this case report did not present painful symptomatology, periapical lesion, fistula, or abscess, keys to success in minimally invasive dentistry.

The carious dentin is divided into two parts: the outermost part, infected dentin, which must be removed, and the innermost part, affected dentin, which should be preserved because it can be remineralized [18]. The main difficulty of selective removal to firm dentin is the subjective criteria to evaluate the amount of carious tissue to be removed [3]. To overcome this problem, the literature has determined that the best guide to be given is the operator's tactile feel [7]. In this case report, the dentin was removed until a harder tissue with leather consistency was found based on tactile perception of the operator [3, 7]. No caries detector dye was used.

The ideal liner to be placed on the remaining dentin after selective caries removal is still a subject that raises many doubts. Good results were obtained in studies that used calcium hydroxide as liner material [19–22], but the histological evaluation demonstrated that a lower inflammation and hyperemia of pulp and a thicker dentin bridge with formation of odontoblastic layer are more frequent with the use of MTA [23]. It can maintain the vitality of the remaining pulp, allowing it to continue to exhibit normal physiological functions [24, 25]. Thus, current clinical trials

should evaluate the combined effect of carious tissue removal strategies with restorative procedures, including the use of liners [5]. MTA is a biocompatible material with satisfactory physical and chemical properties [24], and it has been constantly used in indirect pulp treatments of permanent and primary teeth [1, 26, 27, 28].

Currently, the literature lacks scientific evidence on the suitable restorative material for selective removal to firm dentin. Thus, ionomeric cements were chosen because they are less sensitive to the technique and can be placed in the cavity in only one increment [29]. Furthermore, RMGIC enables repair in case of failures in the restorations, assuring the minimally invasive approach [29].

In this case report, we applied a methodology standardized by the literature to evaluate the dentin-pulp complex response [1, 4]. Clinical and radiographic follow-up was performed at 6, 12, and 18 months [15]; however, other studies have follow-up times with longer evaluation periods [2, 3, 6]. In this way, the follow-up of this clinical case will continue to be performed.

The satisfactory outcomes of this case report agree with those reported by the literature evidencing that the sealed dentin is capable of remineralizing due to changes in the microenvironment [2] caused by the lack of substrates for the bacteria [3, 30]. Thus, new strategies for the management of the carious tissue may target alternative approaches in the treatment of the most advanced stages of the carious lesion, especially with benefits for the children.

Consent

Informed consent was obtained from all individual participants included in the study.

Conflicts of Interest

The authors declare that they have no conflicts of interest.

References

- [1] M. A. Petrou, F. A. Alhamoui, A. Welk, M. B. Altarabulsi, M. H. Alkilzy, and C. Splieth, "A randomized clinical trial on the use of medical Portland cement, MTA and calcium hydroxide in indirect pulp treatment," *Clinical Oral Investigations*, vol. 18, no. 5, pp. 1383–1389, 2013.
- [2] D. M. Dalpian, T. M. Ardenghi, F. F. Demarco, F. Garcia-Godoy, F. B. de Araujo, and L. Casagrande, "Clinical and radiographic outcomes of partial caries removal restorations performed in primary teeth," *American Journal of Dentistry*, vol. 27, no. 2, pp. 68–72, 2014.
- [3] R. Franzon, L. F. Guimaraes, C. E. Magalhaes, A. N. Haas, and F. B. Araujo, "Outcomes of one-step incomplete and complete excavation in primary teeth: a 24-month randomized controlled trial," *Caries Research*, vol. 48, no. 5, pp. 376–383, 2014.
- [4] F. Schwendicke, H. Schweigel, M. A. Petrou et al., "Selective or stepwise removal of deep caries in deciduous molars: study protocol for a randomized controlled trial," *Trials*, vol. 16, no. 1, p. 10, 2015.
- [5] F. Schwendicke, J. E. Frencken, L. Bjørndal et al., "Managing carious lesions: consensus recommendations on carious tissue

- removal," *Advances in Dental Research*, vol. 28, no. 2, pp. 58–67, 2016.
- [6] R. Brignardello-Petersen, "Stepwise and partial caries removal probably have high success rates up to 3 years after treatment of deep carious lesions, but partial caries removal is more likely to preserve tooth vitality," *Journal of the American Dental Association*, vol. 148, no. 4, p. e38, 2017.
- [7] N. P. Innes, J. E. Frencken, L. Bjørndal et al., "Managing carious lesions: consensus recommendations on terminology," *Advances in Dental Research*, vol. 28, no. 2, pp. 49–57, 2016.
- [8] D. Ricketts, T. Lamont, N. P. T. Innes, E. Kidd, and J. E. Clarkson, "Operative caries management in adults and children," *Cochrane Database of Systematic Reviews*, vol. 28, no. 3, p. CD003808, 2013.
- [9] F. Schwendicke, "Contemporary concepts in carious tissue removal: a review," *Journal of Esthetic and Restorative Dentistry*, vol. 29, no. 6, pp. 404–408, 2017.
- [10] M. A. Pereira, R. B. D. Santos-Júnior, J. A. Tavares et al., "No additional benefit of using a calcium hydroxide liner during stepwise caries removal: a randomized clinical trial," *Journal of the American Dental Association*, vol. 148, no. 6, pp. 369–376, 2017.
- [11] J. E. Frencken, N. P. Innes, and F. Schwendicke, "Managing carious lesions: why do we need consensus on terminology and clinical recommendations on carious tissue removal?," *Advances in Dental Research*, vol. 28, no. 2, pp. 46–48, 2016.
- [12] A. P. Fernandes, N. Lourenço Neto, N. C. Teixeira Marques et al., "Clinical and radiographic outcomes of the use of Low-Level Laser Therapy in vital pulp of primary teeth," *International Journal of Paediatric Dentistry*, vol. 25, no. 2, pp. 144–150, 2015.
- [13] N. Lourenço Neto, N. C. Marques, A. P. Fernandes et al., "Clinical and radiographic evaluation of Portland cement added to radiopacifying agents in primary molar pulpotomies," *European Archives of Paediatric Dentistry*, vol. 16, no. 5, pp. 377–382, 2015.
- [14] N. C. Marques, N. L. Neto, C. de Oliveira Rodini et al., "Low-level laser therapy as an alternative for pulpotomy in human primary teeth," *Lasers in Medical Science*, vol. 30, no. 7, pp. 1815–1822, 2015.
- [15] B. Z. Mello, T. C. Stafuzza, L. L. Vitor, D. Rios, M. A. Machado, and T. M. Oliveira, "Alternative approach for carious tissue removal in primary teeth," *European Archives of Paediatric Dentistry*, vol. 17, no. 5, pp. 413–417, 2016.
- [16] N. P. Innes and D. J. Evans, "Modern approaches to caries management of the primary dentition," *British Dental Journal*, vol. 214, no. 11, pp. 559–566, 2013.
- [17] D. A. Sumikawa, G. W. Marshall, L. Gee, and S. J. Marshall, "Microstructure of primary tooth dentin," *Pediatric Dentistry*, vol. 21, no. 7, pp. 439–444, 1999.
- [18] T. Fusayama, "Two layers of carious dentin; diagnosis and treatment," *Operative Dentistry*, vol. 4, no. 2, pp. 63–70, 1979.
- [19] A. E. Bressani, A. A. Mariath, A. N. Haas, F. Garcia-Godoy, and F. B. de Araujo, "Incomplete caries removal and indirect pulp capping in primary molars: a randomized controlled trial," *American Journal of Dentistry*, vol. 26, no. 4, pp. 196–200, 2013.
- [20] M. Hayashi, M. Fujitani, C. Yamaki, and Y. Momoi, "Ways of enhancing pulp preservation by stepwise excavation—a systematic review," *Journal of Dentistry*, vol. 39, no. 2, pp. 95–107, 2011.
- [21] A. S. Pinto, F. B. De Araujo, R. Franzon et al., "Clinical and microbiological effect of calcium hydroxide protection in indirect pulp capping in primary teeth," *American Journal of Dentistry*, vol. 19, no. 6, pp. 382–386, 2006.
- [22] M. J. Tuculina, M. Raescu, I. T. Dascalu et al., "Indirect pulp capping in young patients: immunohistological study of pulp-dentin complex," *Romanian Journal of Morphology and Embryology*, vol. 54, no. 4, pp. 1081–1086, 2013.
- [23] M. Aeinehchi, B. Eslami, M. Ghanbariha, and A. S. Saffar, "Mineral trioxide aggregate (MTA) and calcium hydroxide as pulp-capping agents in human teeth: a preliminary report," *International Endodontic Journal*, vol. 36, no. 3, pp. 225–231, 2003.
- [24] T. M. Oliveira, A. B. Moretti, V. T. Sakai et al., "Clinical, radiographic and histologic analysis of the effects of pulp capping materials used in pulpotomies of human primary teeth," *European Archives of Paediatric Dentistry*, vol. 14, no. 2, pp. 65–71, 2013.
- [25] N. Lourenço Neto, N. C. Marques, A. P. Fernandes et al., "Immunolocalization of dentin matrix protein-1 in human primary teeth treated with different pulp capping materials," *Journal of Biomedical Materials Research Part B: Applied Biomaterials*, vol. 104, no. 1, pp. 165–169, 2016.
- [26] F. Leye Benoist, F. Gaye Ndiaye, A. W. Kane, H. M. Benoist, and P. Farge, "Evaluation of mineral trioxide aggregate (MTA) versus calcium hydroxide cement (Dycal®) in the formation of a dentine bridge: a randomised controlled trial," *International Dental Journal*, vol. 62, no. 1, pp. 33–39, 2012.
- [27] V. George, S. K. Janardhanan, B. Varma, P. Kumaran, and A. M. Xavier, "Clinical and radiographic evaluation of indirect pulp treatment with MTA and calcium hydroxide in primary teeth (in-vivo study)," *Journal of Indian Society of Pedodontics and Preventive Dentistry*, vol. 33, no. 2, pp. 104–110, 2015.
- [28] N. P. Menon, B. R. Varma, S. Janardhanan, P. Kumaran, A. M. Xavier, and B. S. Govinda, "Clinical and radiographic comparison of indirect pulp treatment using light-cured calcium silicate and mineral trioxide aggregate in primary molars: a randomized clinical trial," *Contemporary Clinical Dentistry*, vol. 7, no. 4, pp. 475–480, 2016.
- [29] R. Franzon, N. J. Opdam, L. F. Guimaraes et al., "Randomized controlled clinical trial of the 24-months survival of composite resin restorations after one-step incomplete and complete excavation on primary teeth," *Journal of Dentistry*, vol. 43, no. 10, pp. 1235–1241, 2015.
- [30] M. Maltz, L. S. Alves, J. J. Jardim, S. Moura MdoS, and E. F. de Oliveira, "Incomplete caries removal in deep lesions: a 10-year prospective study," *American Journal of Dentistry*, vol. 24, no. 4, pp. 211–214, 2011.