



Remote Intramedullary Hemorrhage in the Thoracic Spinal Cord Secondary to a Perimedullary Arteriovenous Fistula of the Distal End of Conus Medullaris Mimicking Filum Terminale Arteriovenous Fistula: A Case Report

Prasert Iampreechakul¹ Anusak Liengudom¹ Punjama Lertbutsayanukul² Somkiet Siriwimonmas³ Sirintara Pongpech⁴

¹Department of Neurosurgery, Prasat Neurological Institute, Bangkok, Thailand

²Department of Neuroradiology, Prasat Neurological Institute, Bangkok, Thailand

³Department of Radiology, Bumrungrad International Hospital, Bangkok, Thailand

⁴Division of Interventional Neuroradiology, Department of Radiology, Ramathibodi Hospital Medical School, Mahidol University, Bangkok, Thailand

Address for correspondence Prasert Iampreechakul, MD, 312 Rachawithi Road, Khwaeng Thung Phaya Thai, Bangkok, 10400, Thailand (e-mail: Bangruad@hotmail.com).

AJNS 2022;17:88–94.

Abstract

Perimedullary arteriovenous fistulas (PMAVFs) of the conus medullaris are rare and usually manifest with progressive myelopathy secondary to venous congestion resulting from retrograde arterialization of the draining vein into the spinal cord. We present a rare case of conus PMAVF presenting with remote intramedullary spinal cord hemorrhage in the thoracic cord. A 37-year-old woman was transferred to our institute due to sudden severe pain in the left lower leg and weakness of the lower extremities following progressive paresthesia of the lower extremities. Magnetic resonance imaging of the thoracic and lumbosacral spine revealed spinal cord congestion extending from the conus medullaris to the level of T6 with intramedullary hemorrhage at the level of T8–9 on the left side of the spinal cord. There were abnormal serpiginous intradural flow voids along the anterior surface of the spinal cord extending from the level of L2 to the lower cervical with venous varix at the level of T8–9, probably being the source of hemorrhage. Spinal angiography confirmed conus PMAVF at the distal end of the conus medullaris supplied by the sulco-commissural artery arising from the enlarged anterior spinal artery originating from the left T11 intercostal artery with cranial drainage through the dilated anterior spinal vein into the tortuous perimedullary veins up to the lower cervical level. The patient underwent successful endovascular treatment with N-butyl cyanoacrylate and had gradually improved until being able to

Keywords

- ▶ type IV spinal cord arteriovenous malformations
- ▶ perimedullary arteriovenous fistula
- ▶ conus medullaris
- ▶ intramedullary hemorrhage
- ▶ filum terminale arteriovenous fistula

published online
June 1, 2022

DOI <https://doi.org/10.1055/s-0042-1748791>.
ISSN 2248-9614.

© 2022. Asian Congress of Neurological Surgeons. All rights reserved.

This is an open access article published by Thieme under the terms of the Creative Commons Attribution-NonDerivative-NonCommercial-License, permitting copying and reproduction so long as the original work is given appropriate credit. Contents may not be used for commercial purposes, or adapted, remixed, transformed or built upon. (<https://creativecommons.org/licenses/by-nc-nd/4.0/>)

Thieme Medical and Scientific Publishers Pvt. Ltd., A-12, 2nd Floor, Sector 2, Noida-201301 UP, India

walk independently without residual pain of the left lower leg. We speculated that an increased venous flow into a varix may be considered an important risk factor of hemorrhage.

Introduction

Spinal cord arteriovenous malformations have been classified into four subtypes including: type I, spinal dural arteriovenous fistulas (SDAVFs); type II, intramedullary glomus malformations; type III, extensive juvenile malformations; and type IV, intradural perimedullary arteriovenous fistulas (PMAVFs). Type IV spinal cord arteriovenous malformations have been further divided into three subtypes including: type IVa, small or low-flow AVF supplied by single arterial branch of the anterior spinal artery (ASA); type IVb, inter-mediated-sized fistula supplied by multiple arterial feeders; and type IVc, giant high-flow fistula fed by several feeding vessels of the ASA and posterior spinal artery (PSA).¹

Intradural extramedullary AVFs were first described by Djindjian et al² in 1977, and later were classified as type IV PMAVF, direct communication of the intrinsic arterial supply of the spinal cord and a vein without an intervening small vessel network, by Heros et al³ in 1986. Based on modified classification of spinal cord vascular lesions by Spetzler et al,⁴ they classified type IV lesions as intradural ventral AVFs which are located ventrally and in the midline.

PMAVFs at the level of the conus medullaris are rare and classified as type IV lesions and presented with either subarachnoid hemorrhage (SAH) or, more commonly, progressive myelopathy secondary to venous hypertension.^{5,6} We described a case of PMAVF of the conus medullaris with remote intramedullary spinal cord hemorrhage in the thoracic cord. The pathogenesis of thoracic intramedullary hemorrhage caused by conus PMAVF in our case was discussed.

Case Description

A 37-year-old woman complained of progressive paresthesia of the lower extremities for 3 months. She went to the local hospital and was treated with some medicines without improvement. She had no history of any injury. Two weeks later, the patient was hospitalized to the same local hospital with sudden severe pain in the left lower leg and weakness of the lower extremities. She also developed urination incontinence requiring urinary catheterization. Magnetic resonance imaging (MRI) of the spine was performed and showed abnormal T2 signal representing spinal cord congestion extending from the conus medullaris to the level of T6. There were abnormal serpiginous intradural flow voids along the anterior surface of the spinal cord extending from the level of L2 to the lower cervical with suspecting two venous varices at the level of T8–9 and T10. At the level of T8–9, there was abnormal heterogeneous signal intensity on T1- and T2-weighted image on the left side of the spinal cord, represent-

ing intramedullary hemorrhage (►Figs. 1 and 2). The patient was diagnosis of ruptured spinal cord arteriovenous malformations and was transferred to our institute and admitted for further investigation and management. The neurological examination revealed the evidence of spastic paraparesis (muscle strength 4/5), impairment of proprioception, hyperreflexia, and presence of Babinski sign in the lower extremities.

Spinal angiography was obtained which demonstrated a PMAVF of the distal end of the conus medullaris at the level of L2, supplied by the enlarged sulco-commissural feeder arising from the enlarged ASA originating from the left T11 intercostal artery with cranial drainage through the dilated anterior spinal vein (ASV) into the tortuous perimedullary veins up to the lower cervical level. There was a venous dilatation at the proximal draining vein (►Fig. 3). The venous phase of the left T11 intercostal artery angiography disclosed the large venous varix at the level of T8–9 pointing to the left side, probably corresponding with the area of intramedullary hemorrhage (►Fig. 4A). Due to the enlarged ASA, we decided to proceed with endovascular surgery as the first choice. We used Magic microcatheter 1.2 Fr (Balt, Montmorency, France). The microcatheter was navigated through the course of the ASA and the tip of the microcatheter could be wedged stably into the enlarged left sulco-commissural artery just proximal to the fistula. With heparinization, transarterial embolization with N-butyl cyanoacrylate (NBCA) through the ASA was successfully performed with reaching the venous pouch of ASV (►Fig. 4B, C). Mixture of NBCA and an oil-based contrast agent (Lipiodol Ultra Fluid; Guerbet, Aulnay-sous-Bois, France) was prepared in proportions of 1:0.7 ratio of NBCA to Lipiodol. Spinal angiography after embolization confirmed complete obliteration of the fistula and preservation of the ASA. To prevent further venous thrombosis, the patient received the prophylactic anticoagulation after the procedure.

MRI of the thoracic and lumbar spine, obtained 2 months after endovascular treatment, showed the disappearance of intradural flow voids and thrombosed venous aneurysm at the level of T8–9 on the anterolateral cord and above the distal end of the conus medullaris (►Fig. 5). The patient had gradually improved until being able to walk independently without residual pain of the left lower leg 6 months later. Bladder function had completely recovered at 1 year after treatment. MRI and MR angiography of the thoracolumbar spine obtained 2 years after embolization revealed complete obliteration of the fistula and significant resolution of spinal cord congestion. At the T8–9 level on the left anterolateral part of the spinal cord, there was hypointensity on T1-weighted, gradient recalled echo T2*-weighted, and proton density-weighted images, probably corresponding to

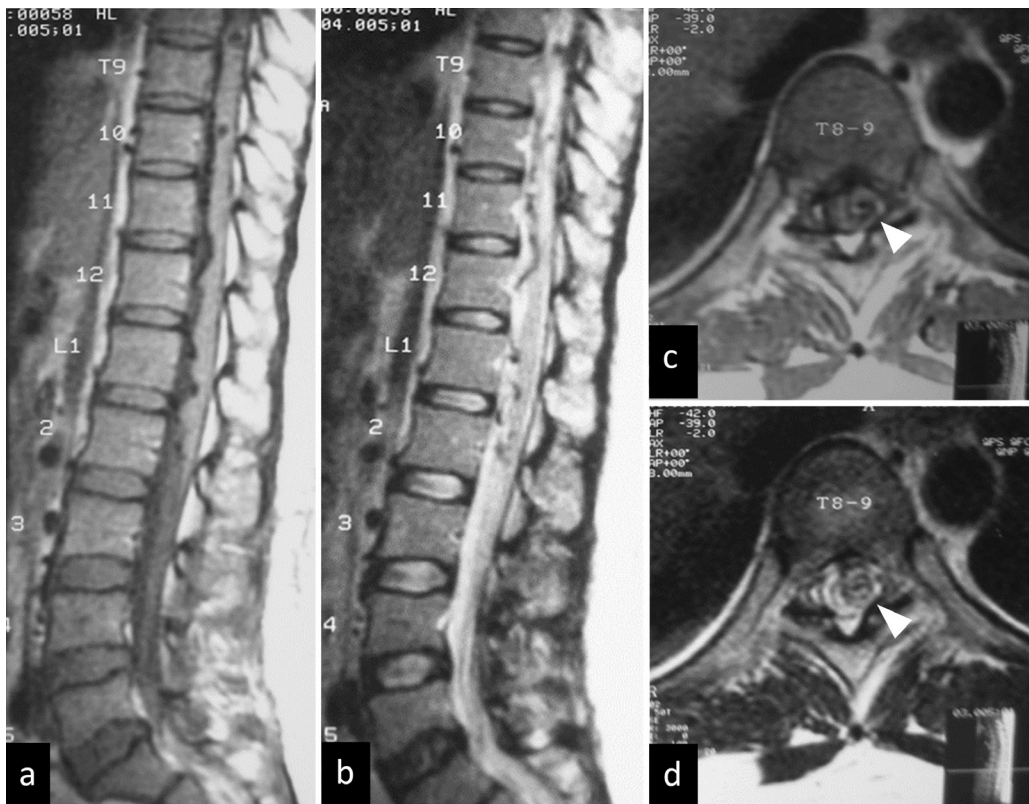


Fig. 1 Sagittal (A) T1-weighted and (B) T2-weighted images of the thoracolumbar spine reveal serpiginous intradural flow voids along the anterior surface of the spinal cord extending from the level of L2 to the mid-thoracic. Axial (C) T1-weighted and (D) T2-weighted images at the level of T8–9 demonstrate abnormal heterogeneous signal intensity (*arrowheads*) on the left side of the spinal cord, probably representing intramedullary hemorrhage.

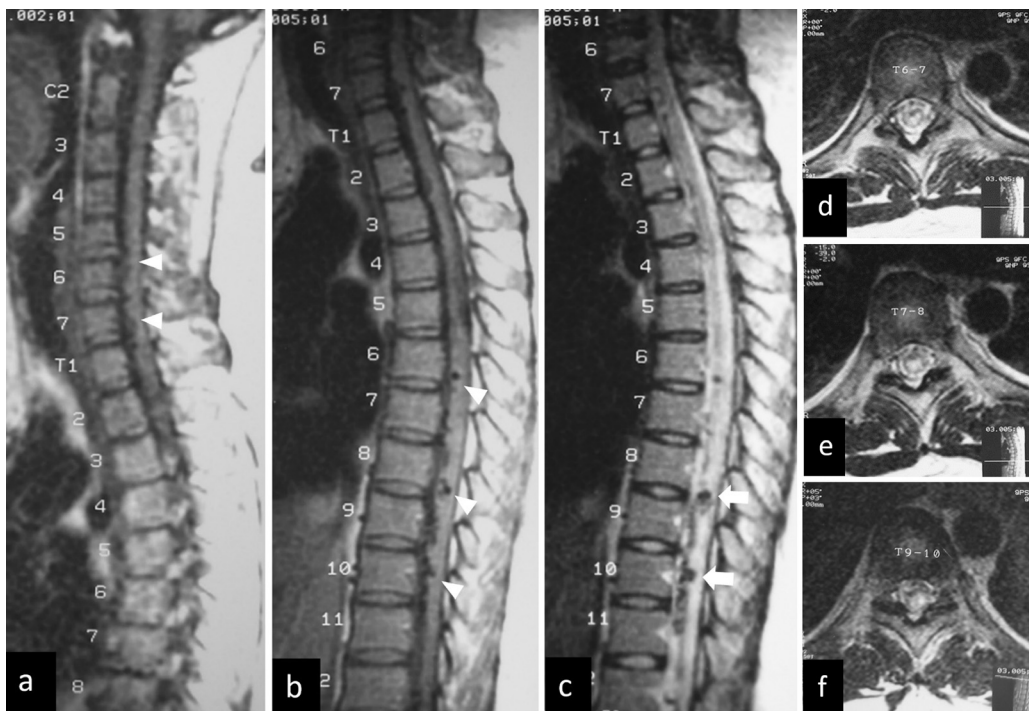


Fig. 2 Sagittal T1-weighted images of (A) the cervical and (B) thoracic spine show intradural flow voids (*arrowheads*) along the anterior surface of the spinal cord extending from the lower thoracic to lower cervical level. (C) Sagittal T2-weighted image of the thoracic spine demonstrate two venous varices (*arrows*) at the level of T8–9 and T10. Axial T2-weighted images at the level of (D) T6–7, (E) T7–8, and (F) T9–10 reveal abnormal hypersignal intensity within the spinal cord, representing spinal venous congestion.

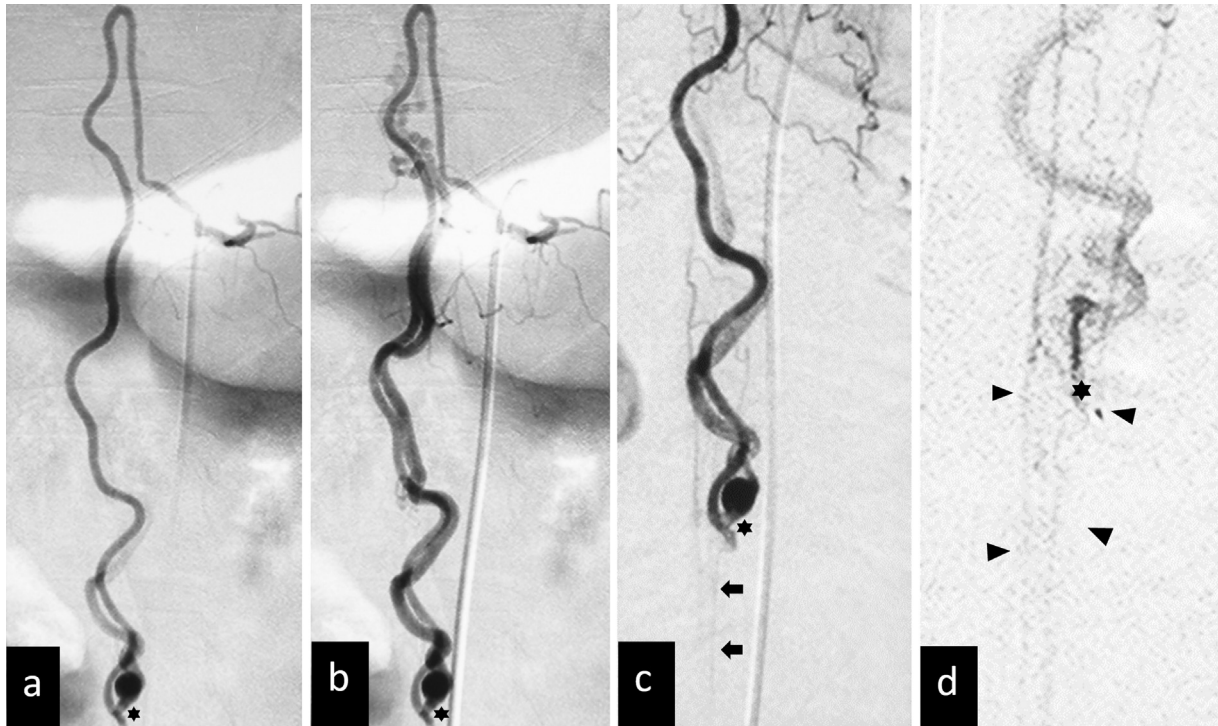


Fig. 3 Anteroposterior views of the left T11 intercostal artery angiography in (A) arterial and (B, C) venous phases reveal a perimedullary arteriovenous fistula (asterisks) of the distal end of the conus medullaris at the level of L2, supplied by the enlarged sulco-commissural feeder arising from the enlarged anterior spinal artery (ASA) with cranial drainage into the dilated anterior spinal vein. There is a venous dilatation (curve arrows) at the proximal draining vein. The normal-sized ASA (arrows) distal to the fistula is noted. (D) Selective angiography with microcatheter through the fistulous point (asterisk) located above the arterial basket of the conus medullaris forming from the ASA and posterior spinal arteries (arrowheads).

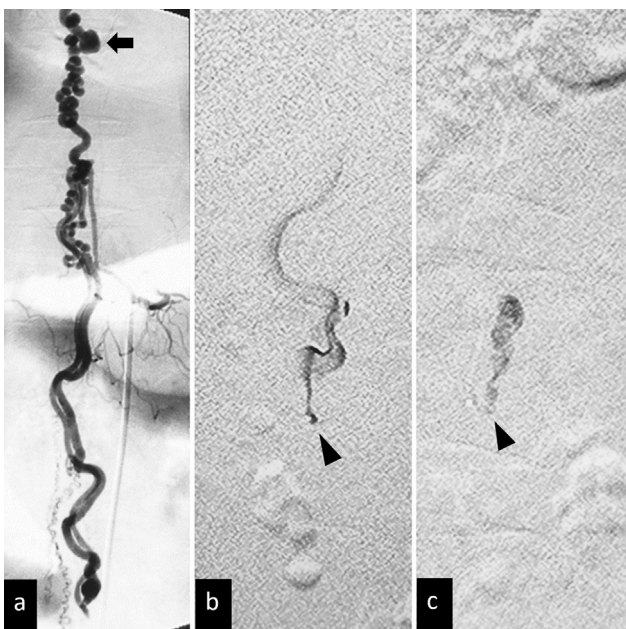


Fig. 4 (A) Anteroposterior view of the left T11 intercostal artery angiography in the venous phase reveal the large venous varix (arrow) at the level of T8-9 pointing to the left side, probably corresponding with the area of intramedullary hemorrhage. (B) Oblique view of selective angiography with the microcatheter through the enlarged left sulco-commissural artery clearly demonstrates the fistulous point (arrowhead) and proximal draining vein. (C) During embolization, the glue cast can occlude the fistula (arrowhead) and the venous pouch of anterior spinal vein.

hemosiderin (► Fig. 6). Spinal angiography, obtained 3 years after endovascular treatment, demonstrated the normal size of the ASA without recurrence of the fistula (► Fig. 7).

Discussion

Type IVa perimedullary fistulas are typically slow-flow lesions and usually located on the ventral surface of the conus medullaris or filum terminale.⁷ At the level of the conus medullaris, the ASA may form an anastomotic basket with the PSAs via anastomotic branches. The arterial basket of the conus medullaris consists of one (unilateral) or two (bilateral) arterial branches circumferentially connecting the ASA and PSAs.⁸ In our case, the fistula was located at the level of L2. Therefore, it is difficult to differentiate between filum terminale arteriovenous fistula (FTAVF) and PMAVF at the distal end of conus medullaris. Angiographic pattern of conus PMAVF in our case was similar to FTAVF, which was located ventrally at the midline and supplied by the ASA with cranial drainage into the perimedullary veins without intervening nidus. Using selective angiography with the microcatheter through the ASA, we can identify the arterial basket of the conus medullaris and found that the fistula was located above the arterial basket of the conus with the presence of the PSAs and normal-sized ASA distal to the fistula. In addition, hemorrhagic events have never been reported from FTAVF.⁹⁻¹¹

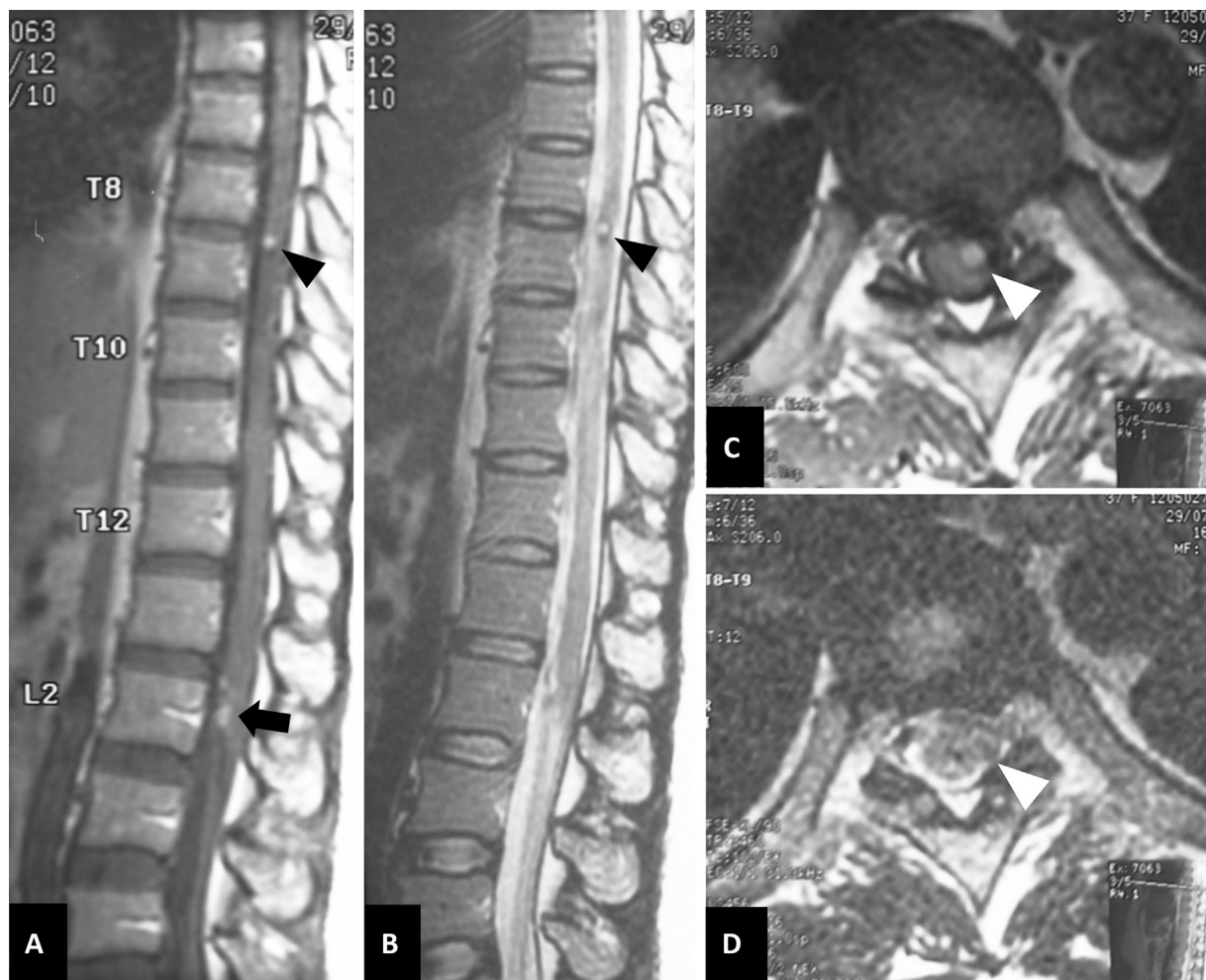

Fig. 5 Magnetic resonance imaging of the thoracic spine obtained 2 months after endovascular treatment. At the level of T8–9 on the anterolateral cord, (A) sagittal and (C) axial T1-weighted images show hypersignal intensity, and (B) sagittal and (D) axial T2-weighted images demonstrate hypersignal intensity surrounding with hyposignal intensity (black and white arrowheads), probably indicating thrombosed venous aneurysm. There are multiple small hypersignal intensity foci (black arrow) at the level of L2 just above the distal end of the conus medullaris, probably representing thrombosed venous pouch.

Conus PMAVFs usually manifest by progressive myelopathy or acute nonhemorrhagic paraplegia.¹² Our case initially presented with progressive paresthesia of the lower extremities secondary to venous congestion and subsequently developed sudden severe pain in the left lower leg from intramedullary hemorrhage. Conus PMAVF in our case was supplied by single feeder from the ASA. Therefore, it should be classified as intradural ventral type IVa AVF which is slow-flow shunt. However, we speculated that this fistula should be considered as a relatively high-flow fistula due to markedly enlarged feeder and draining vein. The high pressure can cause multiple venous varices. Our case clearly revealed rupture of a venous varix, embedded into the spinal cord parenchyma caused hematomyelia by evidence from imaging studies. A high-flow fistula in our case may produce high pressure in the venous varix at the level of T8–9 leading to intramedullary hemorrhage.

Similarly, hemorrhage from SDAVFs is usually rare and may occur as SAH from the fistulas in cervical and craniocervical region.^{13–15} Intramedullary hemorrhage or hemato-

myelia caused by SDAVFs is extremely rare. Previous study was reviewed in the literature of SDAVFs with intramedullary hemorrhage and showed only six cases. All but one of the SDAVFs had venous varices of draining veins, being the source of hematomyelia.¹⁶

Type IVa PMAVFs can be treated by surgery, endovascular treatment, or combined approaches. The goal of treatment is complete obliteration of the fistula with preservation of normal arterial supply to the spinal cord. The key to complete occlusion is obliteration of the proximal vein.⁵ In type IVa PMAVFs located at the level or below the conus medullaris, surgical treatment has been the preferred method of treatment with higher complete obliteration rates and low rate of recurrence.⁶ However, some authors suggested that it was easy to operate the fistula on filum terminale but difficult on conus medullaris.¹⁷ Endovascular treatment should be considered as second-line choice because of the difficulty in navigating a microcatheter through the long and tortuous course of the thin ASA; the possibility of reflux of the liquid embolic material into the ASA; the risk of tearing, dissecting,

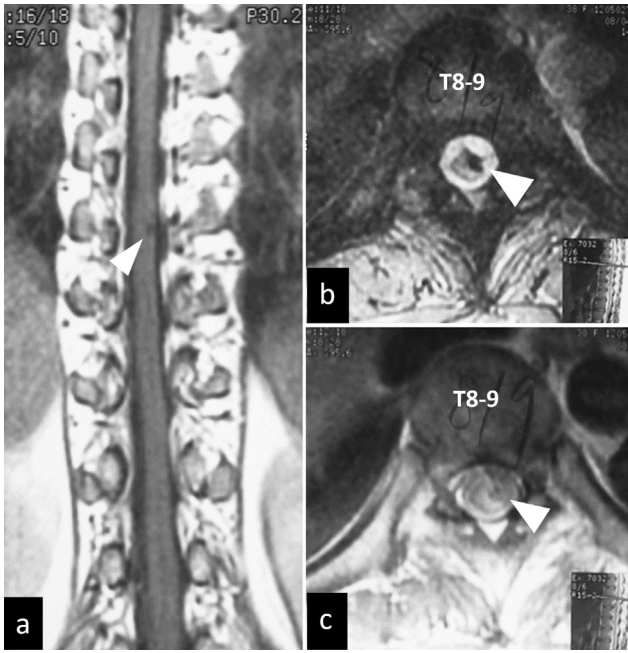


Fig. 6 Magnetic resonance imaging of the thoracic spine obtained 2 years after endovascular treatment. (A) Coronal T1-weighted, axial (B) gradient recalled echo (GRE) T2*-weighted, and (C) proton density (PD)-weighted images demonstrate hypointensity (arrowheads) at the level of T8–9 on the left anterolateral part of the spinal cord, probably corresponding to hemosiderin.

thrombosis, or vasospasm of the ASA during embolization; concerning about recanalization of the fistula; and requiring expertise and experience in neurointerventional procedure.^{9–11} According to review about treatment on spinal cord PMAVFs by Ji et al,¹⁸ they found that endovascular

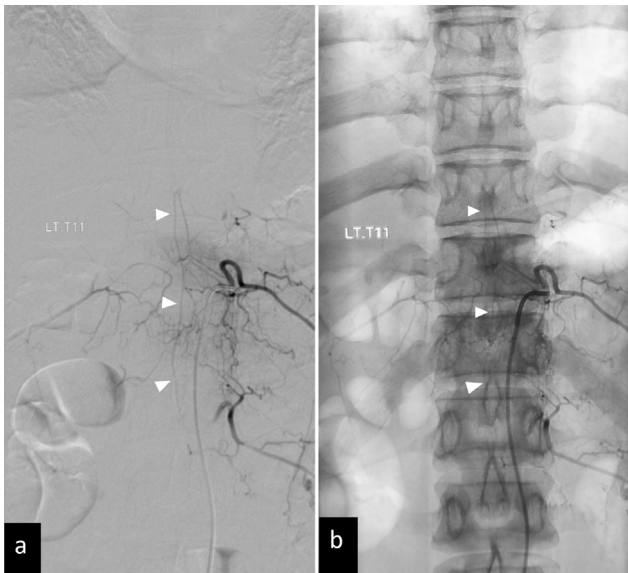


Fig. 7 Spinal angiography obtained 3 years after endovascular treatment. Anteroposterior views of the left T11 intercostal artery angiography (A) with and (B) without subtraction demonstrate the normal size of the anterior spinal artery (white arrowheads) with a characteristic hairpin turn (black arrowhead) without recurrence of the fistula.

treatment is more effective in high-flow PMAVFs, leading to a good outcome.

In the present study, we decided to try endovascular treatment as first choice because there was the accessible dilated ASA and sulco-commissural artery. The important factor for the successful transarterial embolization is an introduction of the tip of microcatheter in a more stable and distal position to the shunt point. During embolization with NBCA, the safety margin for glue reflux was short. The glue should close the fistula without reflux into the ASA. In addition, the glue should be stopped just before the proximal draining vein for avoiding anterograde venous occlusion. The safety margin is related strictly to the anatomy of the ASA and the posterior curve into the sulco-commissural artery that supplies the arteriovenous shunt. We cannot allow any embolic material refluxes more than short segment of this posterior curve which will immediately arrive in the ASA axis.

Even through the NBCA cast occupied only in the localized area (only in the sulco-commissural artery and proximal draining vein), the prophylactic anticoagulation was used in our case because the fistula is quite large and the amount of NBCA injected into the dilated proximal draining vein could further create too extensive thrombosis within the rest of the perimedullary vein and disturb the normal spinal cord drainage.

Conclusion

The authors reported an extremely rare case of conus PMAVF presenting with remote intramedullary hemorrhage secondary to ruptured venous varix, confirmed by imaging studies. This fistula was relatively high-flow due to markedly enlarged feeder and multiple venous pouches. We speculated that an increased venous flow into a varix may be considered an important risk factor of hemorrhage.

Authors' Contribution

P.I. contributed to the concepts, design, literature research, data acquisition, manuscript preparation, and manuscript review. A.L. contributed to the clinical studies and is a guarantor. P.L. contributed to the concepts, clinical studies, and data acquisition. S.S. is a guarantor. S.P. contributed to definition of intellectual content, data analysis, and manuscript editing.

Patient Consent

The patient has given consent to be enrolled and have her data published.

Declaration of Patient Consent

The authors certify that they have obtained all appropriate patient consent forms. In the form, the patient has given her consent for her images and other clinical information to be reported in the journal. The patient understands that name and initials will not be published, and due efforts will be made to conceal identity, but anonymity cannot be guaranteed.

Funding

None.

Conflict of Interest

None declared.

References

- 1 Anson JA, Spetzler RF. Classification of spinal arteriovenous malformations and implications for treatment. *BNI Q* 1992;8:2–8
- 2 Djindjian M, Djindjian R, Rey A, Hurth M, Houdart R. Intradural extramedullary spinal arterio-venous malformations fed by the anterior spinal artery. *Surg Neurol* 1977;8(02):85–93
- 3 Heros RC, Debrun GM, Ojemann RG, Lasjaunias PL, Naessens PJ. Direct spinal arteriovenous fistula: a new type of spinal AVM. Case report. *J Neurosurg* 1986;64(01):134–139
- 4 Spetzler RF, Detwiler PW, Riina HA, Porter RW. Modified classification of spinal cord vascular lesions. *J Neurosurg* 2002;96(2, Suppl):145–156
- 5 Barrow DL, Colohan AR, Dawson R. Intradural perimedullary arteriovenous fistulas (type IV spinal cord arteriovenous malformations). *J Neurosurg* 1994;81(02):221–229
- 6 Cho KT, Lee DY, Chung CK, Han MH, Kim HJ. Treatment of spinal cord perimedullary arteriovenous fistula: embolization versus surgery. *Neurosurgery* 2005;56(02):232–241, discussion 232–241
- 7 Oran I, Parildar M, Derbent A. Treatment of slow-flow (type I) perimedullary spinal arteriovenous fistulas with special reference to embolization. *AJNR Am J Neuroradiol* 2005;26(10):2582–2586
- 8 Martirosyan NL, Kalani MY, Lemole GM Jr, Spetzler RF, Preul MC, Theodore N. Microsurgical anatomy of the arterial basket of the conus medullaris. *J Neurosurg Spine* 2015;22(06):672–676
- 9 Giordan E, Brinjikji W, Ciceri E, Lanzino G. Arteriovenous fistulae of the filum terminale. *J Neurointerv Surg* 2018;10(02):191–197
- 10 Iampreechakul P, Tirakotai W, Wangtanaphat K, Lertbutsayanukul P, Siriwimonmas S. Filum terminale arteriovenous fistula in association with degenerative lumbosacral spinal canal stenosis: report of 3 cases and review of the literature. *World Neurosurg* 2020;138:231–241
- 11 Chanthanaphak E, Pongpech S, Jiarakongmun P, Kobkitsuksakul C, Chi CT, Terbrugge KG. Filum terminale arteriovenous fistulas: the role of endovascular treatment. *J Neurosurg Spine* 2013;19(01):49–56
- 12 Krings T, Lasjaunias PL, Geibprasert S, et al. Classification of spinal vascular malformations. *Neuroradiol J* 2009;22:97–106
- 13 Kinouchi H, Mizoi K, Takahashi A, Nagamine Y, Koshu K, Yoshimoto T. Dural arteriovenous shunts at the craniocervical junction. *J Neurosurg* 1998;89(05):755–761
- 14 Aviv RI, Shad A, Tomlinson G, et al. Cervical dural arteriovenous fistulae manifesting as subarachnoid hemorrhage: report of two cases and literature review. *AJNR Am J Neuroradiol* 2004;25(05):854–858
- 15 Kai Y, Hamada J, Morioka M, Yano S, Mizuno T, Kuratsu J. Arteriovenous fistulas at the cervicomedullary junction presenting with subarachnoid hemorrhage: six case reports with special reference to the angiographic pattern of venous drainage. *AJNR Am J Neuroradiol* 2005;26(08):1949–1954
- 16 Iampreechakul P, Lertbutsayanukul P, Siriwimonmas S, Jittapiromsak P, Tantivatana J, Niruthisard S. Persistent central neuropathic pain caused by intramedullary hemorrhage from spinal dural arteriovenous fistula: a case report and literature review. *Austin J Anesthesia Analgesia* 2019;7:1076
- 17 Mourier KL, Gobin YP, George B, Lot G, Merland JJ. Intradural perimedullary arteriovenous fistulae: results of surgical and endovascular treatment in a series of 35 cases. *Neurosurgery* 1993;32(06):885–891, discussion 891
- 18 Ji T, Guo Y, Shi L, Yu J. Study and therapeutic progress on spinal cord perimedullary arteriovenous fistulas. *Biomed Rep* 2017;7(03):214–220