



OPEN ACCESS

Costal osteochondral graft for a postoperative cartilage defect in a patient with polydactyly

Keisuke Nakagawa,^{1,2} Noriaki Hidaka,³ Toshio Kitano,² Hiroaki Nakamura¹

¹Department of Orthopaedic Surgery, Osaka City University Graduate School of Medicine, Osaka, Japan

²Department of Pediatric Orthopaedics, Osaka City General Hospital, Osaka, Japan

³Department of Orthopaedic Surgery, Osaka City General Hospital, Osaka, Japan

Correspondence to

Dr Keisuke Nakagawa;
k-nakagawa@med.osaka-cu.ac.jp

Accepted 17 December 2020

SUMMARY

We present a case of a postoperative cartilage defect in a patient with polydactyly who was treated with a costal osteochondral graft. Excision of the radial digit and ligamentous periosteal flap with longitudinal osteotomy were performed when the patient was 1 year old. The alignment of the interphalangeal joint was straight after surgery, but the deviation gradually developed. A revision surgery using a costal osteochondral graft was performed when the patient was 3 years old. A satisfactory outcome was obtained at the 3-year follow-up. The authors suggest that a costal osteochondral graft may be a reasonable option for revision surgery for a postoperative cartilage defect.

BACKGROUND

Polydactyly is the most common congenital anomaly of the hand, and such cases are often referred to paediatric hand surgeons. The purpose of the surgery is to reconstruct a straight, stable and mobile thumb. Reconstructive surgery is considered a successful method to improve cosmesis and function.

The most common surgical method for the treatment of preaxial polydactyly is ablation of the radial thumb and reconstruction of the joint. Usually, the results of the surgery are excellent or good, and the reoperation rate is low. However, complications develop in some cases. One possible complication is postoperative cartilage defect. If osteotomy is performed to make a more proportional thumb, excessive cartilage excision can induce inclination and instability of the interphalangeal (IP) joint, which can be managed surgically. However, there are no generally accepted treatment options for a severely deviated postoperative thumb.

Here, we report the use of a costal osteochondral graft for the reconstruction of a postoperative cartilage defect of the IP joint in a patient with polydactyly. To the best of our knowledge, there have been no previous reports of similar cases. The information presented here may be helpful for similar cases encountered in the future.

CASE PRESENTATION

A 1-year-old boy was diagnosed with left preaxial polydactyly. He was otherwise healthy and had no personal or family history of other congenital anomalies. He had duplicated left thumbs of almost equal size and shape. Radiographic evaluation confirmed Wassel type 3 polydactyly (figure 1).

The initial operation was performed under general anaesthesia in the supine position when the

patient was 1 year old. The radial digit was excised, and a ligamentous periosteal flap with longitudinal osteotomy of the lateral condyle of the proximal phalanx was performed to make an appropriately balanced thumb. The major part of the proximal phalanx was retained to stabilise the IP joint. Reconstruction of the radial collateral ligament and coverage of the ulnar digit by the skin flap obtained from the radial digit were used to render stability and proper alignment of the ulnar digit. The alignment of the IP joint was straight immediately after surgery (figure 2). However, the IP joint gradually deviated, and the angulation eventually reached 50° (figure 3).

TREATMENT

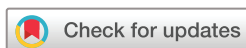A costal osteochondral graft was performed to treat the cartilage defect and resurface the IP joint. The second surgery was performed under general anaesthesia and in the supine position, 1 year and 9 months after the initial surgery. The previous skin incision was used. The periosteum and capsule were elevated together. The graft bed was enlarged by curettage to ensure that the osseous part of the graft was sufficient to achieve firm fixation. A graft was obtained from the osteochondral junction of the right fifth rib, as previously described (figure 4A).¹ The harvested graft was trimmed to fit the shape of the lateral condyle of the proximal phalanx and rigidly fixed with 1.0 mm Kirschner wire and surgical wire to the enlarged graft bed (figure 4B,C). Although the subchondral bone level was not horizontal, the articular surface was adjusted to fit smoothly, so that the joint motion would not be disturbed.

After the surgery, the IP joint was temporarily fixed by Kirschner wires for 8 weeks. A long arm cast was applied for the same duration. The patient started passive range of motion exercises 10 weeks after the surgery and was allowed to return to daily activities at 3 months postoperatively.

OUTCOME AND FOLLOW-UP

Seven months after the second surgery, the implanted wires were removed. A preoperative radiograph demonstrated bone union of the graft (figure 5A,B). Intraoperative arthrography revealed that the articular surface was continuous (figure 5C), and the osteochondral fragment was firmly fused.

At the 3-year follow-up after the costal osteochondral graft surgery, the patient had a straight, stable, mobile and pain-free IP joint. The active range of motion was 0°/60° (figure 6). The clinical result was classified as good according to the



© BMJ Publishing Group Limited 2021. Re-use permitted under CC BY-NC. No commercial re-use. See rights and permissions. Published by BMJ.

To cite: Nakagawa K, Hidaka N, Kitano T, et al. *BMJ Case Rep* 2021;**14**:e237823. doi:10.1136/bcr-2020-237823

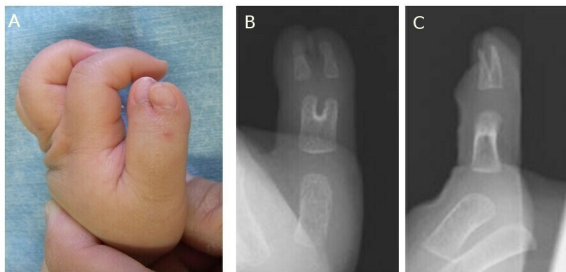


Figure 1 Preoperative findings. (A) Preoperative appearance of the left thumb. (B and C) Preoperative radiograph of the left thumb.

scoring system established by the Japanese Society for Surgery of the Hand. Radiographic examination indicated good alignment of the IP joint. There was neither narrowing of the joint space nor morbidity at the donor site. The patient and his family were satisfied with the results.

DISCUSSION

Preaxial polydactyly reconstruction has been considered as a good treatment option for improving cosmesis and functional status. Usually, the results of the surgery are excellent or good, and the reoperation rate is low. However, complications develop in a limited number of cases.

Wassel type 3 polydactyly can be difficult to treat by reconstruction surgery. If both digits are hypoplastic and equal in size, it is difficult to reconstruct a well-balanced thumb. Generally, two main methods can be adopted. One is a simple ablation of one digit followed by a ligamentous periosteal flap technique,² and the other is the Bilhaut procedure.³ Regardless of the technique, the goal of radial polydactyly reconstruction is to achieve a functional and cosmetically acceptable thumb.

The original Bilhaut procedure can sometimes yield poor results such as nail deformity, stiff joint and recurrence of the deformity. There have been several modifications of the Bilhaut procedure,^{4 5} but the complication risks and learning curve remain. In contrast, Manske's ligamentous periosteal flap technique is technically simple, but it can result in instability and inclination of the narrowed IP joint. Horii *et al*⁶ modified the ligamentous periosteal flap technique to preserve the radial side of the distal articular surface, thereby preserving the stability of the IP joint. Although this technique secures the stability of the IP joint, the cosmetic outcome can be poor due to a size mismatch between the wide proximal phalanx and the hypoplastic distal phalanx. Therefore, the osteotomy is typically performed until a suitable size is obtained. Despite extreme care during osteotomy, cartilage defects of the IP joint may develop.

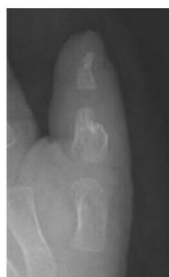

Figure 2 Radiograph 1 month after the initial surgery shows straight alignment of the interphalangeal joint.

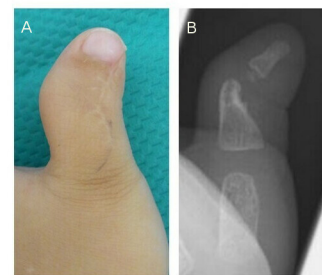


Figure 3 (A) Appearance and (B) radiograph 1 year and 9 months after the initial surgery. The angulation of the interphalangeal joint reached 50°.

A cartilage defect leads to IP joint inclination and instability and is a severe postsurgical complication in a patient with polydactyly. The appropriate extent of osteotomy can be difficult to determine. Inclination and instability of the IP joint is a rare complication, but it can be severe. The goal of treatment for a severely deviated digit is to regain a stable and straight thumb. Some surgical options, such as ligamentoplasty, tendon transfer and arthrodesis, are available. Arthrodesis can ensure stability and good alignment.^{7 8} However, this technique sacrifices the range of motion of the IP joint. Overall, there is still no generally accepted treatment for a severely deviated postoperative thumb.

Autologous or allogenic osteochondral grafts are used to repair various types of joint cartilage defects. Femoral condyle and costal osteochondral junctions are common autologous donor sites. Non-weight-bearing areas of femoral condyle are frequently chosen and are easy to harvest.⁹ However, the harvested graft is cylindrical, and its diameter ranges from 3 mm to 6 mm, making it difficult to shape it to the condyle of paediatric phalanx. Although a costal osteochondral graft involves a slightly more invasive harvesting procedure, osteochondral fragments of 10–15 mm in diameter can be harvested, allowing a high degree of freedom in graft formation. There are possible complications to using a costal osteochondral graft. Donor site pain persists for several days after surgery. Careful elevation of the periosteum and perichondrium is important to reduce the risk of pleural injury and pneumothorax.

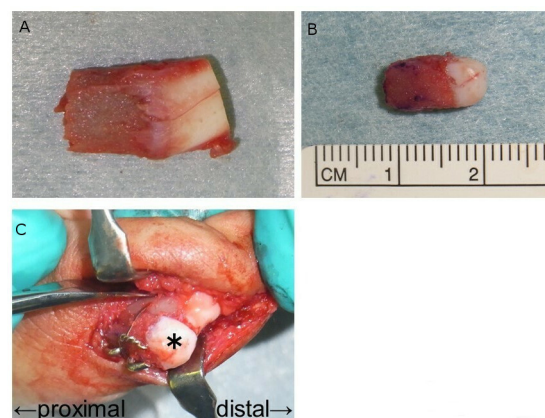


Figure 4 Appearance of the osteochondral graft. (A) Harvested costal osteochondral graft from the osteochondral junction of the right fifth rib. (B) Graft was trimmed by hand to fit the shape of the lateral condyle of the proximal phalanx. (C) Graft was fixed with 1.0 mm Kirschner wire and surgical wire to the enlarged graft bed. The asterisk indicates the fixed graft to form the lateral condyle of the proximal phalanx.

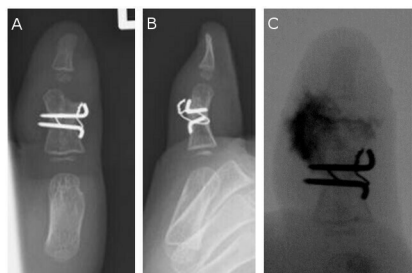


Figure 5 Radiographs 7 months after the costal osteochondral graft. (A and B) Radiographs before the implant removal. The graft is fused with graft bed. (C) Arthrography shows that the articular surface is continuous.

A costal osteochondral graft is a treatment option for restoring an ankylosed or severely damaged finger joint. Munro *et al*¹⁰ reported the viability of osteochondral grafts harvested from the costal osteochondral junction and used them for the temporomandibular joint. To date, many studies have described the use of costal osteochondral grafts for treating cartilaginous defects in various regions with satisfactory outcomes. To the best of our knowledge, however, there have been no reports detailing the use of the costal osteochondral graft for the reconstruction of a postoperative cartilage defect in a patient with polydactyly. This graft allows for resurfacing of the joint with a uniform hyaline cartilaginous articular surface without adversely affecting other joints.¹¹ Although the entire costal osteochondral junction was excised, the defect at the donor site was replaced with hard connective tissue, and no adverse effects were reported.

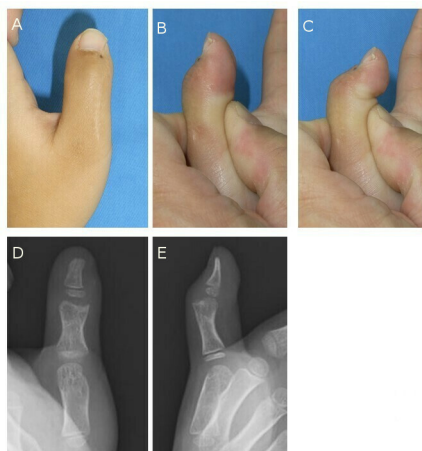


Figure 6 Appearance and radiographs 3 years after the surgery of the costal osteochondral graft. (A) Front view. (B) active extension of the interphalangeal joint. (C) Active flexion of the interphalangeal joint. (D and E) Radiographs showing bone union of the graft without evidence of bone absorption. Joint space was maintained.

In conclusion, we report using a costal osteochondral graft to repair a postoperative cartilage defect in a patient with polydactyly. At the final 3-year follow-up, the patient had a straight, stable, pain-free and mobile IP joint. Even if the orthopaedic surgeon is extremely careful when performing osteotomy in a patient with polydactyly, cartilage defects of the IP joint may develop. A costal osteochondral graft is a reasonable option for the revision surgery.

Learning points

- ▶ A paediatric hand surgeon cannot be too careful when performing an articular cartilage excision in patients with polydactyly.
- ▶ A postoperative cartilage defect is a severe complication of polydactyly.
- ▶ A costal osteochondral graft may be a reasonable option for revision surgery if a postoperative cartilage defect occurs.

Contributors KN wrote the manuscript and conducted this publication. NH reviewed the manuscript and supervised the patient management. TK and HN reviewed the manuscript.

Funding The authors have not declared a specific grant for this research from any funding agency in the public, commercial or not-for-profit sectors.

Competing interests None declared.

Patient consent for publication Parental/guardian consent obtained.

Provenance and peer review Not commissioned; externally peer reviewed.

Open access This is an open access article distributed in accordance with the Creative Commons Attribution Non Commercial (CC BY-NC 4.0) license, which permits others to distribute, remix, adapt, build upon this work non-commercially, and license their derivative works on different terms, provided the original work is properly cited and the use is non-commercial. See: <http://creativecommons.org/licenses/by-nc/4.0/>.

REFERENCES

- 1 Hasegawa T, Yamano Y. Arthroplasty of the proximal interphalangeal joint using costal cartilage grafts. *J Hand Surg Br* 1992;17:583–5.
- 2 Manske PR. Treatment of duplicated thumb using a ligamentous/periosteal flap. *J Hand Surg Am* 1989;14:728–33.
- 3 Bilhaut M. The curing of a bifid thumb by a new operative procedure. *Congr Fr Chir* 1889:576–80.
- 4 Baek GH, Gong HS, Chung MS, *et al*. Modified Bilhaut-Cloquet procedure for Wassel type-II and III polydactyly of the thumb. *J Bone Joint Surg Am* 2007;89:534–41.
- 5 Tonkin MA, Bulstrode NW. The Bilhaut-Cloquet procedure for Wassel types III, IV and VII thumb duplication. *J Hand Surg Eur Vol* 2007;32:684–93.
- 6 Horii E, Hattori T, Koh S, *et al*. Reconstruction for Wassel type III radial polydactyly with two digits equal in size. *J Hand Surg Am* 2009;34:1802–7.
- 7 Pellegrini VD, Burton RI. Osteoarthritis of the proximal interphalangeal joint of the hand: arthroplasty or fusion? *J Hand Surg Am* 1990;15:194–209.
- 8 Vitale MA, Fruth KM, Rizzo M, *et al*. Prosthetic arthroplasty versus arthrodesis for osteoarthritis and posttraumatic arthritis of the index finger proximal interphalangeal joint. *J Hand Surg Am* 2015;40:1937–48.
- 9 Matsusue Y, Yamamoto T, Hama H. Arthroscopic multiple osteochondral transplantation to the chondral defect in the knee associated with anterior cruciate ligament disruption. *Arthroscopy* 1993;9:318–21.
- 10 Munro IR, Phillips JH, Griffin G. Growth after construction of the temporomandibular joint in children with hemifacial microsomia. *Cleft Palate J* 1989;26:303–11.
- 11 Sato K, Sasaki T, Nakamura T, *et al*. Clinical outcome and histologic findings of costal osteochondral grafts for cartilage defects in finger joints. *J Hand Surg Am* 2008;33:511–5.

Copyright 2021 BMJ Publishing Group. All rights reserved. For permission to reuse any of this content visit <https://www.bmj.com/company/products-services/rights-and-licensing/permissions/>
BMJ Case Report Fellows may re-use this article for personal use and teaching without any further permission.

Become a Fellow of BMJ Case Reports today and you can:

- ▶ Submit as many cases as you like
- ▶ Enjoy fast sympathetic peer review and rapid publication of accepted articles
- ▶ Access all the published articles
- ▶ Re-use any of the published material for personal use and teaching without further permission

Customer Service

If you have any further queries about your subscription, please contact our customer services team on +44 (0) 207111 1105 or via email at support@bmj.com.

Visit casereports.bmj.com for more articles like this and to become a Fellow