

# Scleral patch grafting for scleral wound thinning after pars plana phacoemulsification and aspiration

## A case report

Yuya Terubayashi, MD, Seita Morishita, MD, PhD, Masanori Fukumoto, MD, PhD, Takaki Sato, MD, PhD, Teruyo Kida, MD, PhD, Tsunehiko Ikeda, MD, PhD\*

### Abstract

**Rationale:** Here we report the case of a patient who required closure with an autologous scleral patch graft during reoperation after developing marked scleral thinning in the late stage after pars plana phacoemulsification and aspiration (PPPEA). To the best of our knowledge, this is the first reports of the procedure being used for the treatment of a thinned scleral section post PPPEA.

**Patient concerns:** This study involved a 73-year-old woman who had undergone vitreous surgery combined with PPPEA for retinal detachment in her right eye 8 years earlier and subsequently underwent intraocular lens (IOL) ciliary sulcus suture fixation.

**Diagnoses:** She became aware of visual disturbance in her right eye and slit-lamp examination revealed the dislocation of the IOL.

**Interventions:** To remove the dislocated IOL and resuture the nasal loop back onto the ciliary sulcus of the patient's right eye, a 25-gauge trocar was placed on the superior temporal side.

**Outcomes:** Subsequent removal of the trocar from the patient's right eye left an approximately 3-mm-wide oval-shaped gap at the trocar insertion site due to extreme thinning of the sclera in that area; that is, the location where the PPPEA was performed. Since suture fixation failed to stop intraocular fluid leakage, an inferior free half-thickness scleral flap was created to patch the scleral wound. Postsurgery, the leakage in that eye stopped and the intraocular pressure was stable. No complications were observed during the 1-year-postoperative follow-up period.

**Lessons:** Since thermal injuries during PPPEA may lead to postoperative scleral thinning, surgeons should avoid the site of a prior PPPEA when constructing a scleral wound during reoperation.

**Abbreviations:** IOL = intraocular lens, PPPEA = pars plana phacoemulsification and aspiration.

**Keywords:** intraocular lens, pars plana phacoemulsification and aspiration, scleral patch graft, thinning of the sclera

## 1. Introduction

The widespread use of micro-incision vitrectomy surgery has drastically reduced the number of 20-gauge (G) vitreous surgeries

Editor: N/A.

This case study was approved by the Ethics Committee of Osaka Medical College, as was performed in accordance with the tenets set forth in the Declaration of Helsinki.

Informed written consent was obtained from the patient for publication of this case report and the accompanying images.

The authors have no conflicts of interest to disclose.

Department of Ophthalmology, Osaka Medical College, Takatsuki-City, Osaka, Japan.

\* Correspondence: Tsunehiko Ikeda, Department of Ophthalmology, Osaka Medical College, 2-7 Daigaku-machi, Takatsuki-City, Osaka 569-8686, Japan (e-mail: [tikeda@osaka-med.ac.jp](mailto:tikeda@osaka-med.ac.jp)).

Copyright © 2019 the Author(s). Published by Wolters Kluwer Health, Inc. This is an open access article distributed under the terms of the Creative Commons Attribution-Non Commercial-No Derivatives License 4.0 (CCBY-NC-ND), where it is permissible to download and share the work provided it is properly cited. The work cannot be changed in any way or used commercially without permission from the journal.

Medicine (2019) 98:19(e15598)

Received: 15 December 2018 / Received in final form: 4 April 2019 / Accepted: 16 April 2019


<http://dx.doi.org/10.1097/MD.00000000000015598>

now being performed. However, pars plana phacoemulsification and aspiration (PPPEA), which can be carried out under an expanded procedure of the system used for 20-G vitreous surgeries, remains useful for specific cases, such as cases of lens dislocation, a dropped lens nucleus during cataract surgery, and removal of the hard residual lens tissue after congenital cataract surgery.<sup>[1,2]</sup> Scleral thermal injury is reportedly one of the complications of phacoemulsification and aspiration (PEA).<sup>[3,4]</sup>

Here we report the case of a patient with marked scleral thinning in the late stage post PPPEA and opening of the scleral wound in a reoperation that required closure with an autologous scleral patch graft.

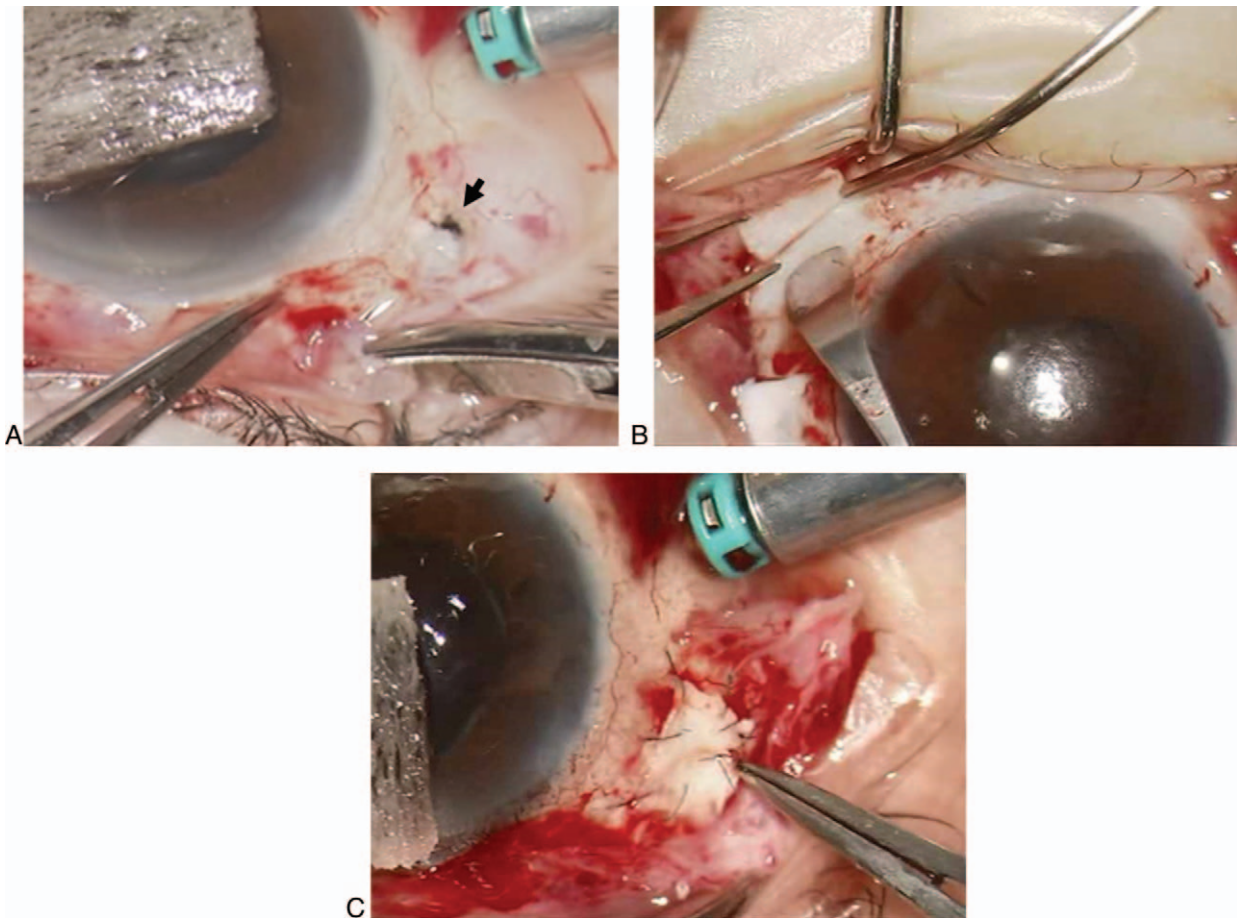
## 2. Case description

This study involved a 73-year-old woman with no systemic complications and no history of treatment with oral steroids who had undergone vitrectomy combined with PPPEA, radial buckling, and gas tamponade for rhegmatogenous retinal detachment in her right eye in our department 8-years earlier and had achieved reattachment. At that time, intraoperative findings included clogging within the tip by lens particles during PPPEA and opening of a scleral wound due to thermal injury. Although subsequent fixation with 8-0 Vicryl (Ethicon Inc., Bridgewater, NJ) suture stopped the leakage of intraocular fluid, it disrupted the surrounding scleral blood vessels. Two years

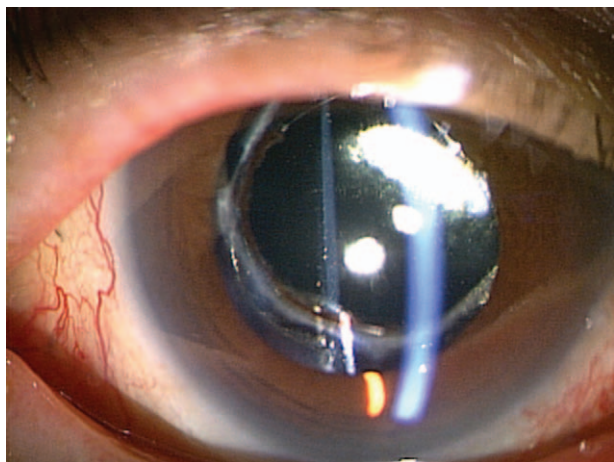


**Figure 1.** Preoperative photograph of the anterior segment of the patient's right eye. The IOL was dislocated to the inferior temporal side. IOL = intraocular lens.

previous, the patient had undergone intraocular lens (IOL) ciliary sulcus suture fixation in her right eye at another hospital. Recently, she presented to a local physician with a perceived decrease of visual acuity in her right eye, and was subsequently referred to our department for IOL dislocation. Upon re-examination at our department, the patient's visual acuity was 0.4 (not correctable) in her right eye and 0.5 ( $1.0 \times S - 3.75D$ ) in her left eye, and her intraocular pressure was 15 mmHg in both eyes. Examination of the anterior ocular segment revealed ruptured sutures on the nasal side of her right eye and IOL dislocation to the inferior temporal side (Fig. 1). Funduscopy examination showed that the retina in her right eye had reattached after the vitreous surgery that was performed for retinal detachment. In order to use the dislocated IOL "as is," the nasal loop of the IOL was sutured back onto the ciliary sulcus and a 25-G vitrectomy trocar was placed on the superior temporal side. There was no detachment of the trocar from the sclera during surgery, thus allowing the IOL ciliary sulcus suture fixation to be completed. However, subsequent removal of the trocar left an approximately 3-mm-wide oval-shaped gap at that site (Fig. 2A). An attempt to close the wound with 8-0 Vicryl (Ethicon Inc.) suture after conjunctival incision failed to stop the leakage of intraocular fluid. Consequently, an inferior, free,



**Figure 2.** Intraoperative images of the patient's right eye. An approximately 3-mm-wide, oval-shaped gap at the site was observed after removal of the trocar (A). An attempt to close the wound with 8-0 Vicryl suture after conjunctival incision failed to stop the leakage of intraocular fluid. Consequently, an inferior, free, half-thickness, 4 mm  $\times$  4 mm-square scleral flap was created to patch the scleral wound (B). The created scleral flap was fixed with 10-0 nylon suture (C).



**Figure 3.** Postoperative photograph of the anterior segment of the patient's right eye. Postsurgery, the IOL stayed in place well, and the intraocular pressure in that eye was stable. IOL=intraocular lens.

half-thickness, 4 mm × 4 mm-square scleral flap was created to patch the scleral wound (Fig. 2B), and was affixed with 10–0 nylon suture (Fig. 2C). Subsequently, the leakage of intraocular fluid stopped, and the surgery was concluded without any further complications. Postoperatively, the IOL stayed in place well, and the intraocular pressure in that eye was stable at 15 mmHg (Fig. 3). The postoperative outcomes were favorable, and no complications were observed during the 1-year follow-up period.

### 3. Discussion

Scleral thermal injury is an intraoperative complication associated with PEA.<sup>[3,4]</sup> In conventional PEA procedures, the tip is cooled with an irrigation solution within the sleeve, thereby minimizing the severity of thermal injury to scleral and corneal wounds. Recent advancements in pulse modality that generate less heat, as well as the development of torsional PEAs that emulsify the nucleus by rotational action, have further reduced the amount of thermal injury to scleral wounds.<sup>[5,6]</sup> In contrast, the exposed tip used in PPPEA is not cooled by an irrigation solution, and consequently leads to higher degrees of thermal injury. In a previous experiment involving pig eyes, we investigated scleral thermal injuries associated with PPPEA under open- and closed-tip conditions based on thermographic data and histological changes of scleral wounds.<sup>[7]</sup> Our findings, as well as those in other reports, have confirmed what many surgeons reportedly experience during PPPEA, that is, a rapid rise in temperature resulting from a blockage created by lens particles within the tip. In the present case, intraoperative findings from the initial surgery, which included PPPEA, indicated that lens particles became clogged in the tip, that the scleral wound opened and contracted markedly, and that the surrounding scleral blood vessels were disrupted.

Collagens have a molecular weight of approximately 300 kDa and a helical structure comprising 3 chains of fibrous protein, each with a molecular weight of approximately 100 kDa. The strong interchain links help tissues maintain structural integrity. Heat collapses such collagen structures, resulting in a random structure through a process called collagen denaturation. The findings in a previous histological study demonstrated that the

heat generated by an ultrasound tip degrades collagen in the sclera.<sup>[8]</sup> As scleral blood vessels around the wound are also disrupted at the same time, the sclera around the wound becomes even more thin and fragile over the long term. In the present case, the area of sclera at the wound probably became very thin over the 8 years since the patient underwent PPPEA. Scleral thinning at the site where the prior PPPEA had been performed was difficult to ascertain, and placement of the 25-G trocar through the conjunctiva ended up at the same site, leaving an approximately 3-mm-wide oval-shaped gap in the sclera that required a scleral patch graft.

The scleral patch graft procedure is intended for cases of scleral thinning, such as in the present case.<sup>[9]</sup> Past case reports have indicated the utility of this method for thinned scleral sections resulting from necrotizing scleritis,<sup>[10]</sup> recurrent pterygium,<sup>[11]</sup> strabismus surgery,<sup>[12]</sup> scleral buckling surgery,<sup>[13]</sup> and glaucoma filtration surgery,<sup>[14]</sup> among other causes. In recent years, the procedure has been used in an increasing number of cases to prevent implant exposure in glaucoma tube shunt surgery.<sup>[15]</sup> However, and to the best of our knowledge, there have been no previous reports of the procedure being used for the treatment of a thinned scleral section after PPPEA. In the present case, to patch the thinned scleral section, we created a half-thickness scleral flap from a healthy part of the sclera located inferior to the section, and the patient subsequently made satisfactory progress without postoperative complications.

Scleral thinning in the present case was attributable to PPPEA, as the patient had no particular disorder that would cause connective tissue abnormalities or scleral thinning. When performing vitreous surgery on a patient who has previously undergone PPPEA, surgeons should cut open the conjunctiva and ascertain the exact site of the previous PPPEA in order to avoid the creation of a new scleral wound at the same site.

### Acknowledgments

The authors wish to thank John Bush for editing the manuscript.

### Author contributions

**Conceptualization:** Yuya Terubayashi, Seita Morishita, Takaki Sato, Teruyo Kida, Tsunehiko Ikeda.

**Data curation:** Yuya Terubayashi, Seita Morishita, Masanori Fukumoto, Takaki Sato, Teruyo Kida, Tsunehiko Ikeda.

**Formal analysis:** Yuya Terubayashi, Tsunehiko Ikeda.

**Funding acquisition:** Yuya Terubayashi, Tsunehiko Ikeda.

**Investigation:** Yuya Terubayashi, Masanori Fukumoto, Takaki Sato, Tsunehiko Ikeda.

**Methodology:** Yuya Terubayashi, Seita Morishita, Masanori Fukumoto, Takaki Sato, Teruyo Kida, Tsunehiko Ikeda.

**Project administration:** Yuya Terubayashi, Tsunehiko Ikeda.

**Resources:** Yuya Terubayashi, Tsunehiko Ikeda.

**Software:** Yuya Terubayashi, Tsunehiko Ikeda.

**Supervision:** Seita Morishita, Masanori Fukumoto, Teruyo Kida, Tsunehiko Ikeda.

**Validation:** Yuya Terubayashi, Tsunehiko Ikeda.

**Visualization:** Yuya Terubayashi, Takaki Sato, Tsunehiko Ikeda.

**Writing – original draft:** Yuya Terubayashi, Tsunehiko Ikeda.

**Writing – review & editing:** Yuya Terubayashi, Seita Morishita, Masanori Fukumoto, Takaki Sato, Teruyo Kida, Tsunehiko Ikeda.

## References

- [1] von Lany H, Mahmood S, James CR, et al. Displacement of nuclear fragments into the vitreous complicating phacoemulsification surgery in the UK: clinical features, outcomes and management. *Br J Ophthalmol* 2008;92:493–5.
- [2] Kongsap P. Combined 20-gauge and 23-gauge pars plana vitrectomy for the management of posteriorly dislocated lens: a case series. *Clin Ophthalmol* 2010;4:625–8.
- [3] Ernest P, Rhem M, McDermott M, et al. Phacoemulsification conditions resulting in thermal wound injury. *J Cataract Refract Surg* 2001;27:1829–39.
- [4] Sippel KC, Pineda RJr. Phacoemulsification and thermal wound injury. *Semin Ophthalmol* 2002;17:102–9.
- [5] Nair S, Nair RU. Wound and surface temperatures in vivo in torsional and longitudinal modalities of ultrasound in coaxial microincisional cataract surgery. *Clin Ophthalmol* 2017;11:249–55.
- [6] Belkin A, Abulafia A, Michaeli A, et al. Wound temperature profiles of coaxial mini-incision versus sleeveless microincision phacoemulsification. *Clin Exp Ophthalmol* 2017;45:247–53.
- [7] Sato T, Yasuhara T, Fukumoto M, et al. Investigation of scleral thermal injuries caused by ultrasonic pars plana phacoemulsification and aspiration using pig eyes. *Int Ophthalmol* 2018;doi: 10.1007/s10792-018-1036-6. [Epub ahead of print].
- [8] Rem AI, Oosterhuis JA, Journée-de Korver HG, et al. Temperature dependence of thermal damage to the sclera: exploring the heat tolerance of the sclera for transscleral thermotherapy. *Exp Eye Res* 2001;72: 153–62.
- [9] Sangwan VS, Jain V, Gupta P. Structural and functional outcome of scleral patch graft. *Eye (Lond)* 2007;21:930–5.
- [10] Nguyen QD, Foster CS. Scleral patch graft in the management of necrotizing scleritis. *Int Ophthalmol Clin* 1999;39:109–31.
- [11] Tsai YY, Lin JM, Shy JD. Acute scleral thinning after pterygium excision with intraoperative mitomycin C: a case report of scleral dellen after bare sclera technique and review of the literature. *Cornea* 2002;21:227–9.
- [12] Gupta SR, Anand R, Diwan S, et al. Salvaging recurrent scleral buckle exposure with autologous periosteal patch graft. *Retin Cases Brief Rep* 2014;8:178–82.
- [13] Dagi L, Alkharashi M. Accidental duplication: pericardial patch graft repair of severe localized scleral thinning encountered during strabismus surgery. *J AAPOS* 2017;pii: S1091-8531(16)30777-7. doi: 10.1016/j.jaapos.2017.01.005. [Epub ahead of print].
- [14] Harizman N, Ben-Cnaan R, Goldenfeld M, et al. Donor scleral patch for treating hypotony due to leaking and/or overfiltering blebs. *J Glaucoma* 2005;14:492–6.
- [15] Wolf A, Hod Y, Buckman G, et al. Use of autologous scleral graft in Ahmed glaucoma valve surgery. *J Glaucoma* 2016;25:365–70.