

Philadelphia chromosome with acute myeloid leukemia and concurrent large B cell lymphoma of different origins: A case report

YANG DAI¹, XIAO SHUAI¹, PU KUANG¹, LIN WANG², TING LIU¹ and TING NIU¹

Departments of ¹Hematology and Research Laboratory of Hematology and ²Pathology, West China Hospital, Sichuan University, Chengdu, Sichuan 610041, P.R. China

Received January 20, 2015; Accepted March 3, 2016

DOI: 10.3892/ol.2017.5578

Abstract. Philadelphia chromosome with *de novo* acute myeloid leukemia (Ph + AML) arising from t(9;22) is an uncommon occurrence. Ph + AML is known to respond poorly to conventional chemotherapy. To the best of our knowledge, simultaneous diagnosis of *de novo* Ph + AML and lymphoma in a single patient has not yet been reported. The present study reports the case of a 37-year-old female patient who presented with bone pain, fever and lymphadenopathy, and was diagnosed as Ph + AML with concurrent diffuse large B cell lymphoma. Combined chemotherapy regimen covering AML and lymphoma was administered, achieving short-term response. However, the therapy soon failed and the patient succumbed to the disease. The present study reports the first case of Ph + AML occurring concurrently with diffuse large B cell lymphoma, and discusses certain differences between Ph + AML and chronic myelogenous leukemia in the myeloid blast crisis phase, as well as the appropriate therapeutic modalities for Ph + AML. In addition, the potential association between Ph + AML and diffuse large B cell lymphoma in this patient was investigated.

Introduction

The Philadelphia chromosome (Ph) or breakpoint cluster region-Abelson (*BCR-ABL*) fusion gene is more common in patients with chronic myelogenous leukemia (CML) (1) than in those with precursor B-acute lymphoblastic leukemia

(ALL) (2); however, Ph + acute myeloid leukemia (AML) has also been reported.

AML has an incidence of 3.7 per 100,000 individuals, with anemia, bleeding, fever and bone pain as its typical symptoms. Currently, the standard therapy for AML consists of chemotherapy, immunotherapy, targeting therapy and hematopoietic stem cell transplantation (3,4).

Although AML secondary to chemotherapy or radiotherapy has been previously reported (5), to the best of our knowledge, there are no reports of concurrent Ph + AML and B cell lymphoma in untreated patients. The current case reports presents a patient who presented with leukocytosis and lymphadenopathy and was diagnosed with Ph + AML concurrent with large B cell lymphoma.

Case report

A 37-year-old Chinese woman complaining of bone pain and fever was admitted to the West China Hospital of Sichuan University (Chengdu, China) in June 2011. The patient was previously healthy, and the complete blood count (CBC) at 3 months prior to admission was normal. Upon pathological examination, multiple bone tenderness and a painless 2x1-cm lymph node in the left axillary fossa were palpable. Laboratory test results suggested mild leukocytosis ($13.6 \times 10^6/\mu\text{l}$; normal range, $3.5\text{--}9.5 \times 10^6/\mu\text{l}$) with 10% white blood cells but normal hemoglobin and platelet counts. Bone marrow smear demonstrated 33.5% myeloid blasts and biopsy revealed diffuse infiltration of AML-like cells. Flow cytometry (FCM) results demonstrated white blood cells co-expressing human leukocyte antigen-D-related, CD34, CD38, CD13, CD33, CD117, cytoplasmic myeloperoxidase and aberrant CD19. Giemsa-banding discovered t(9;22)(q34;q11) in 5/20 metaphases (Fig. 1). Quantitative polymerase chain reaction (PCR) detected P210 type *BCR-ABL* fusion gene and *BCR-ABL/ABL* ratio as 5.45×10^5 copies/ml (5.19%). Bone scan with ^{99m}Tc-methylene diphosphonate revealed multiple abnormalities throughout the body. The *BCR-ABL* fusion gene RT-PCR detection kit was purchased from Shanghai Source Biomedical Technology Co., Ltd. (Shanghai, China). The thermocycling conditions were as follows: 42°C for 30 min, 94°C for 5 min, 94°C for 15 sec and 60°C for 60 sec, for a total of 40 cycles. An

Correspondence to: Dr Yang Dai or Dr Ting Niu, Department of Hematology and Research Laboratory of Hematology, West China Hospital, Sichuan University, 37 Guo Xue Xiang Street, Chengdu, Sichuan 610041, P.R. China
E-mail: danshine77@163.com
E-mail: tingniu1@sina.com

Key words: Philadelphia chromosome + acute myeloid leukemia, large B cell lymphoma, tyrosine kinase inhibitor, therapy

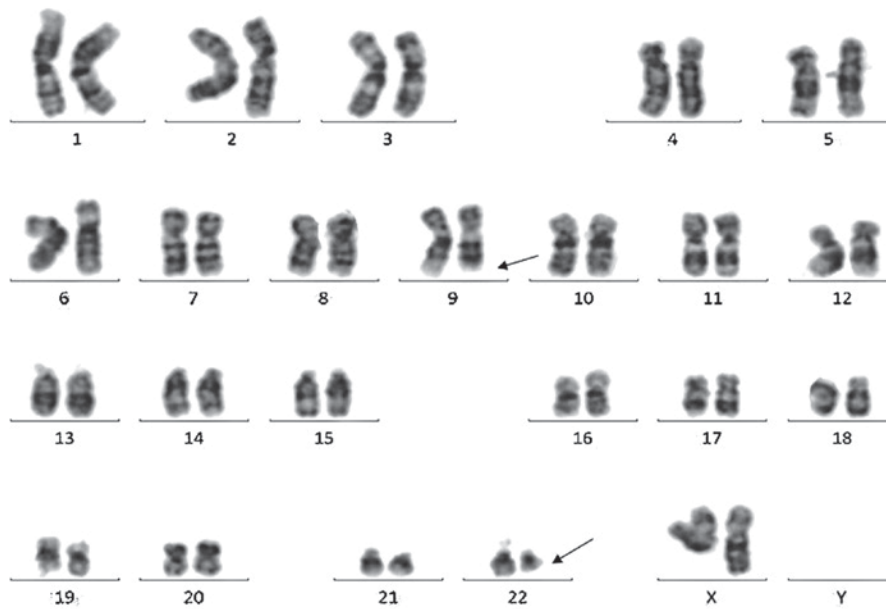


Figure 1. Conventional cytogenetic analysis with Giemsa-banding detected the translocation of $t(9;22)(q34;q11)$ in 5/20 metaphases (arrow).

1.5x1.5-cm lymph node in the left axillary fossa was revealed by computed tomography (CT) scan. Lymph node biopsy was performed and the formalin-fixed, paraffin-embedded tissue was subjected to pathological diagnosis. The results supported the diagnosis of non-Hodgkin lymphoma (diffuse large B cell lymphoma, aggressive, of non-germinal center B cell origin) according to the 2008 World Health Organization Classification (Fig. 2) (4). Considering the leukemic cells harboring the *BCR-ABL* gene, fluorescence *in situ* hybridization (FISH) with *BCR-ABL* probes was performed on the lymph node specimen with no fusion signal detected (Fig. 3). Two days later, the patient developed a headache on the right side of the head, without nausea or vomiting. Head CT scan was normal, while T2-weighted magnetic resonance imaging scan demonstrated a long, contrast agent-intensified signal on multiple sites of the skull, excluding the cerebral parenchyma. The results of routine, biochemical and FCM tests of the cerebrospinal fluid were normal.

Based on the aforementioned findings, Ph + AML with concurrent diffuse large B cell lymphoma was diagnosed. The bone pain and headache were considered to indicate leukemia or lymphoma infiltration, due to no evidence of infection. Treatment with rituximab (600 mg on day 1), adriamycin (70 mg on day 2), cyclophosphamide (1,000 mg on day 2), vincristine (2 mg on day 2), cytarabine (150 mg on days 2-8) and dexamethasone (15 mg on days 2-8) was administered and relieved the symptoms shortly. The lymph node returned to its normal state and complete hematologic remission was obtained; however, *BCR-ABL* transcripts remained positive. Two courses of a similar regimen followed for consolidation. CHR was confirmed prior to each consolidation, while *BCR-ABL* transcripts remained detectable and increased (*BCR-ABL/ABL*, from 0.67 up to 8.8%). Soon after the second consolidation, the patient developed middle grade fever and joint pain in the left knee; leukemia relapse was confirmed by bone marrow smear, FCM and further elevated *BCR-ABL* transcripts (*BCR-ABL/ABL*, 71.73%). Treatment with imatinib

mesylate (IM) (400 mg daily for >2 months) and chemotherapy [10 mg idarubicin (days 1,3 and 5), 2 mg vincristine (day 1), 100 mg cytarabine (days 1-5) and 30 mg prednisone (days 1-5)] was administered, alleviating the symptoms from the following day; however, the reappearing and continuously increasing peripheral blasts suggested leukemia progression. IM was considered ineffective and the bone marrow specimen was sent to confirm the suspected *ABL* kinase mutation, which demonstrated *F395V* mutation. For that purpose, DNA was extracted from the bone marrow specimen, and PCR and DNA sequencing were used to assess the presence of the *F395V* mutation (Fig. 4). In addition, gene mutations common for AML (*CEBPA*, *DNMT3A*, *FLT3-ITD*, *IDH1*, *IDH2*, *KIT*, *KRAS*, *NPM1*, *NRAS*, *TET2* and *WT1*) were investigated in smears at diagnosis and relapse and were all negative. Due to ineffectiveness, IM was switched for dasatinib (75 mg daily), which resulted in a mild decrease in *BCR-ABL* transcripts, but no hematologic response. Twenty days after relapse, the patient suddenly developed an intracranial hemorrhage and succumbed shortly after.

Written informed consent was signed by the husband of the patient and approved by the Ethics Committee of the West China Hospital of Sichuan University (Chengdu, China).

Discussion

The Ph chromosome or *BCR-ABL* fusion gene can be found in >95% of all CML cases, and 5-30% of adult and 2-5% of pediatric ALL cases (2); however, it has also been reported in AML. Keung *et al* (6) conducted a retrospective study of 148 cases of $t(9;22)(q34;q11)$, and identified 84% as CML chronic phase, 13% as *de novo* ALL, 1% as *de novo* AML and 2% as myelodysplastic syndrome (MDS). The estimated incidence of Ph + AML was 0.6%. Ph + AMLs were reported with either major or minor BCR gene rearrangements, similar to those of Ph + ALL, suggesting that Ph + AML is a distinct disease rather than CML-myeloid blast crisis (MBC) phase.

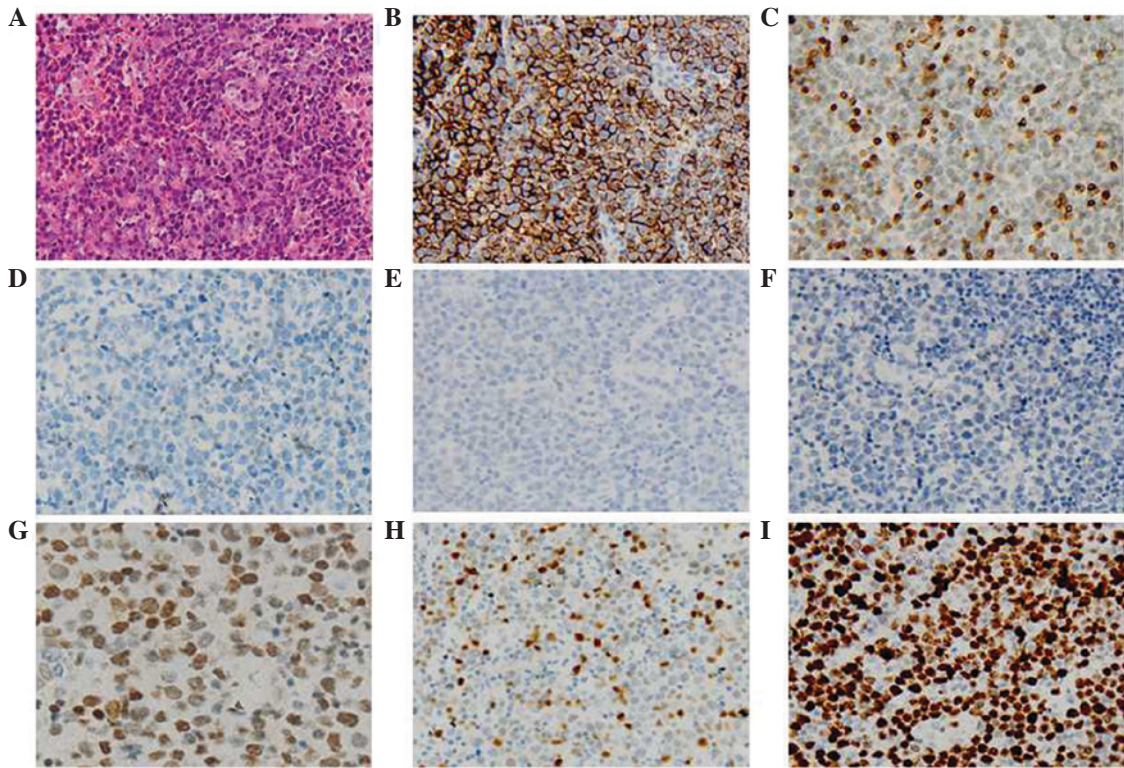


Figure 2. H&E and IHC staining of the specimens from the involved lymph node, supporting the diagnosis of diffuse large B cell lymphoma. (A) H&E staining. IHC staining showing positivity for and negativity for (B) cytomembrane expression of CD20. (C) CD3ε, (D) CD5, (E) ALK-1 and (F) CD30. Cytoplasmic expression of (G) B-cell lymphoma 6 and (H) interferon regulatory factor 4. (I) The percentage of Ki-67-positive cells was ~80%. Magnification, x200. H&E, hematoxylin & eosin; IHC, immunohistochemical.

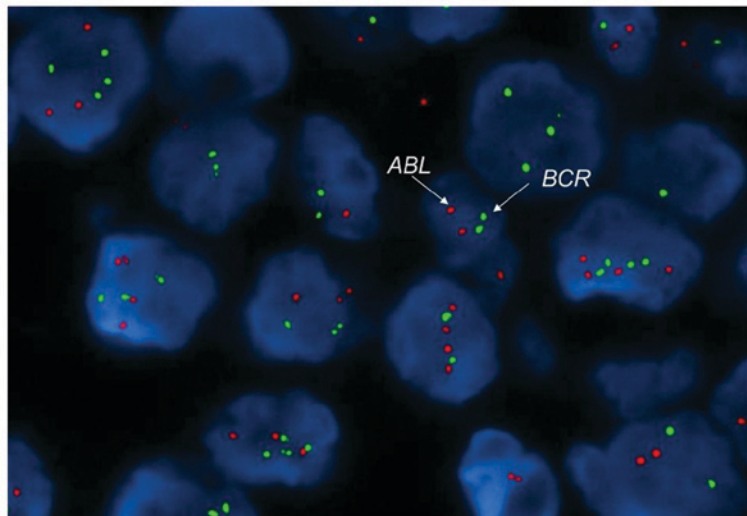


Figure 3. Fluorescence in situ hybridization with BCR-ABL probes was performed on the lymphoma specimen, and no BCR-ABL fusion signal was detected (red, ABL; green, BCR; magnification, x100). BCR, breakpoint cluster region; ABL, Abelson.

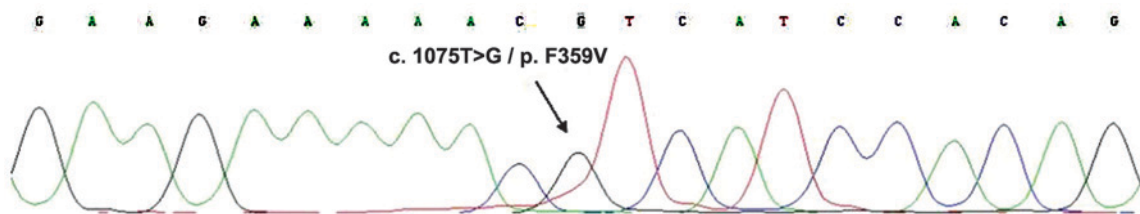


Figure 4. *Abelson* kinase gene mutation analysis during Philadelphia chromosome + acute myeloid leukemia relapse revealed the existence of the *F395V* mutation (arrow).

Furthermore, rare cases of Ph + MDS were also reported, which imply that Ph + AML is a distinct disease entity rather than representing blastic transformation from CML (6). Clinically, Ph + AML presents with less incidence of splenomegaly and significant basophilia (7). Immunophenotypic analysis of Ph + AML disclosed co-expression of CD34 and multiple myeloid markers (such as CD13 and CD33), and a common aberrant expression of lymphoid markers (≥ 2 in 60% of cases) (8); additional cytogenetic abnormalities, such as extra copies of Ph or trisomy 8, were more commonly detected in CML-MBC, compared with Ph + AML (59.9 vs. 25%; $P=0.008$) (9). The coexistence of normal and Ph⁺ metaphases at diagnosis is more characteristic of Ph + AML (5). The induction of chemotherapy usually causes CBC and karyotype normalization in Ph + AML, but chronic or accelerated-phase hemogram and persistence of the Ph chromosome in CML-MBC (7,8). Konoplev *et al* (10) detected *NPM1* and *FLT3-ITD* mutations (frequent in AML) in 2/9 and 1/9 of patients with Ph + AML, respectively, in addition to no mutation in patients with CML-MBC, and no *ABL1* mutation (common in CML-MBC) in any of the 9 Ph + AML patients. Array comparative genomic hybridization was performed in Ph + AML, bilineage leukemia, Ph + ALL and CML (11). Losses of *IGH*, *TRG2*, *VPREB1* and *IGLL1* were detected in Ph + AML, Ph + ALL and CML lymphoid BC but not in CML-chronic phase, CML-MBC or AML with normal karyotype, which further verified the difference between Ph + AML and CML-MBC; however, no single clinical or laboratory test can definitively distinguish the two diseases. The previous CBC of the present patient was normal, and no splenomegaly and basophilia were found at diagnosis. The FCM test result suggested a diagnosis of Ph + AML. Following the induction of chemotherapy, the CBC returned to normal. Taken together, all aforementioned findings suggest that *de novo* Ph + AML may have been a more appropriate diagnosis for this patient.

Due to its rarity, no standard therapies for Ph + AML have been established, and treatment options derive largely from reports of similar cases. In the pre-tyrosine kinase inhibitor (TKI) era, Ph + AML was usually treated by conventional chemotherapy. Cuneo *et al* (9) reported that conventional chemotherapy achieved CR in 4/11 patients (36%), while in the study by Paietta *et al*, none of the 6 patients obtained remission (5). Due to its marked effect on CML, IM was also used in Ph + AML. IM was reported for the treatment of Ph + AML, achieving sustained cytogenetic response and 1 case of molecular remission for 15 months (12-14). In a larger retrospective treatment study, 7/16 patients were treated with IM, among which, 6 achieved HR and 1 achieved CHR, although the response durations were short (median, 2.5 months; range, 1-6 months) (9). IM should therefore be considered front-line therapy (9), but the optimal dosage, timing and duration remain to be determined.

IM is usually administered at a dose of 400 mg daily, when combined with chemotherapy (15,16), or at a dose of 600 mg daily when administered alone (12-14). Sun *et al* (17) reported 2 patients with Ph + AML, who were treated with IM and daunorubicin-based chemotherapy, followed by allo-hematopoietic stem cell transplantation (HSCT) and IM maintenance regimen. Both patients obtained CHR and complete cytogenetic and molecular responses for 44 and

48 months. Another patient receiving unrelated allo-HSCT during CR2, and sustained CHR for 70 months (18); therefore, IM combined with chemotherapy, followed by allo-HSCT and IM maintenance treatment appears to be an effective treatment option for Ph + AML, particularly when IM is used early (17).

IM was not initially administered to the present patient, which may account for the failure of molecular response. Although IM was added following relapse, it failed to bring molecular effect due to the *F395V* mutation. Despite dasatinib treatment theoretically overcoming this mutation, dasatinib may have been used too late and led only to a decrease in transcripts but no HR. This finding implies that the BCR-ABL signal is not the only or not the major pathway to cause Ph + AML. The initial treatment plan for the present patient was treatment with allo-HSCT, but it was hindered by the lack of matched donor. In addition, auto-HSCT could not be considered for a patient without molecular remission.

Despite the fact that secondary AML or MDS has been frequently reported in patients receiving chemotherapy and/or radiotherapy, concomitant lymphoma and AML in previously untreated patients is extremely rare (19). Only a few cases of AML concurrent with lymphoma have been reported (19-23); To the best of our knowledge, this is the first report of simultaneous Ph + AML and diffuse large B cell lymphoma. It is known that leukemia may involve extramedullary sites, including lymph nodes. In the present case, the lymph node biopsy revealed no leukemic cells, excluding AML infiltration of lymph nodes. In addition, lymphoma may disseminate to the bone marrow resembling leukemia; however, no lymphoma cells were detected by FCM in the bone marrow specimen, excluding lymphoma dissemination as well. Since CML may progress to both myeloid and lymphoid leukemia, it has been hypothesized that a single pluripotent stem cell may develop either myeloid or lymphoid neoplasms (24). It was therefore assumed that the leukemia and lymphoma in the present patient may have had the same origin. The leukemic cells were shown to harbor the Ph chromosome, but no *BCR-ABL* fusion signal was observed on the lymph node specimen, indicating that the two diseases were unlikely to share the same origin. One hypothesis is that the single stem cell gained different second hits (mutations) during differentiation and developed distinct neoplasms. Cauwelier *et al* (25) detected monoclonal B lymphocytes in the blood and marrow of a patient with MDS (with trisomy 13), but no evidence of lymphoma. FISH was performed on sorted CD19⁺ and CD34⁺ cells for the detection of trisomy 13. Trisomy 13 was detected in 55% of CD34⁺ cells and 5.5% of CD19⁺ cells, the latter was considered negative. X-chromosome inactivation showed that both CD34⁺ and CD19⁺ cells were monoclonal, while their inactivated chromosomes were different, suggesting that the two populations had different origins.

The etiology of dual tumors such as the one in the present case were obscure. The patient had worked as a nurse in a dental clinic for a long period of time. It was unclear whether the extended exposure to dental repairing materials had played a role in the development and pathogenesis of the disease. Jaalouk *et al* (22) reported a case of concurrent large B cell lymphoma and MDS, whose treatment with steroids caused a rapid augmentation of the myeloid clone and transformation to AML, indicating that the lymphoid clone may downregulate

the myeloid clone. In the present patient, the enlarged lymph node was normalized soon after chemotherapy treatment and remained normal thereafter, while the leukemia deteriorated rapidly, supporting the interclonal inhibition hypothesis.

Ph + AML is a rare disease associated with poor prognosis. It possesses different clinical manifestations and laboratory test results from those of CML-MBC, and should therefore be regarded as a distinct disease. Appropriate treatment options include TKI, combined chemotherapy and treatment with allo-HSCT. Although AML or MDS secondary to chemotherapy, radiotherapy and/or HSCT have previously been reported, Ph + AML concurrent with large B cell lymphoma is considerably more rare, and its underlying pathogenesis remains to be elucidated.

References

- Faderl S, Talpaz M, Estrov Z, O'Brien S, Kurzrock R and Kantarjian HM: The biology of chronic myeloid leukemia. *N Engl J Med* 341: 164-172, 1999.
- Fielding AK: How I treat Philadelphia chromosome-positive acute lymphoblastic leukemia. *Blood* 116: 3409-3417, 2010.
- Deschler B and Lübbert M: Acute myeloid leukemia: Epidemiology and etiology. *Cancer* 107: 2099-2107, 2006.
- Vardiman JW, Thiele J, Arber DA, Brunning RD, Borowitz MJ, Porwit A, Harris NL, Le Beau MM, Hellström-Lindberg E, Tefferi A and Bloomfield CD: The 2008 revision of the World Health Organization (WHO) classification of myeloid neoplasms and acute leukemia: Rationale and important changes. *Blood* 114: 937-951, 2009.
- Paietta E, Racevskis J, Bennett JM, Neuberg D, Cassileth PA, Rowe JM and Wiernik PH: Biologic heterogeneity in Philadelphia chromosome-positive acute leukemia with myeloid morphology: The eastern cooperative oncology group experience. *Leukemia* 12: 1881-1885, 1998.
- Keung YK, Beaty M, Powell BL, Molnar I, Buss D and Pettenati M: Philadelphia chromosome positive myelodysplastic syndrome and acute myeloid leukemia-retrospective study and review of literature. *Leuk Res* 28: 579-586, 2004.
- Berger R: Differences between blastic chronic myeloid leukemia and Ph-positive acute leukemia. *Leuk Lymphoma* 11 (Suppl 1): 235-237, 1993.
- Soupir CP, Vergilio JA, Dal Cin P, Muzikansky A, Kantarjian H, Jones D and Hasserjian RP: Philadelphia chromosome-positive acute myeloid leukemia: A rare aggressive leukemia with clinicopathologic features distinct from chronic myeloid leukemia in myeloid blast crisis. *Am J Clin Pathol* 127: 642-650, 2007.
- Cuneo A, Ferrant A, Michaux JL, Demuyneck H, Boogaerts M, Louwagie A, Doyen C, Stul M, Cassiman JJ, Dal Cin P, *et al*: Philadelphia chromosome-positive acute myeloid leukemia: Cytoimmunologic and cytogenetic features. *Haematologica* 81: 423-427, 1996.
- Konoplev S, Yin CC, Kornblau SM, Kantarjian HM, Konopleva M, Andreeff M, Lu G, Zuo Z, Luthra R, Medeiros LJ and Bueso-Ramos CE: Molecular characterization of De novo Philadelphia chromosome-positive acute myeloid leukemia. *Leuk Lymphoma* 54: 138-144, 2013.
- Nacheva EP, Grace CD, Brazma D, Gancheva K, Howard-Reeves J, Rai L, Gale RE, Linch DC, Hills RK, Russell N, *et al*: Does BCR/ABL1 positive acute myeloid leukaemia exist? *Br J Haematol* 161: 541-550, 2013.
- Ito K, Tominaga K, Suzuki T, Jinnai I and Bessho M: Successful treatment with imatinib mesylate in a case of minor BCR-ABL-positive acute myelogenous leukemia. *Int J Hematol* 81: 242-245, 2005.
- Jentsch-Ullrich K, Pelz AF, Braun H, Koenigsmann M, Mohren M, Wieacker P and Franke A: Complete molecular remission in a patient with Philadelphia-chromosome positive acute myeloid leukemia after conventional therapy and imatinib. *Haematologica* 89: ECR15, 2004.
- Yamaguchi M and Konishi I: Successful treatment with imatinib mesylate for Philadelphia chromosome-positive refractory acute myeloid leukemia. *Rinsho Ketsueki* 44: 254-256, 2003.
- Lazarevici V, Golovleva I, Nygren I and Wahlin A: Induction chemotherapy and post-remission Imatinib therapy for De novo BCR-ABL positive AML. *Am J Hematol* 81: 470-471, 2006.
- Kondo T, Tasaka T, Sano F, Matsuda K, Kubo Y, Matsuhashi Y, Nakanishi H, Sadahira Y, Wada H, Sugihara T and Tohyama K: Philadelphia chromosome-positive acute myeloid leukemia (Ph +AML) treated with imatinib mesylate (IM): A report with IM plasma concentration and bcr-abl transcripts. *Leuk Res* 33: e137-e138, 2009.
- Sun J, Wang Z, Luo Y, Tan Y, Allan DS and Huang H: Prolonged survival with imatinib mesylate combined with chemotherapy and allogeneic stem cell transplantation in De novo Ph+ acute myeloid leukemia. *Acta Haematol* 127: 143-148, 2012.
- Bacher U, Haferlach T, Alpermann T, Zenger M, Hochhaus A, Beelen DW, Uppenkamp M, Rummel M, Kern W, Schnittger S and Haferlach C: Subclones with the t(9;22)/BCR-ABL1 rearrangement occur in AML and seem to cooperate with distinct genetic alterations. *Br J Haematol* 152: 713-720, 2011.
- Kapadia SB and Kaplan SS: Simultaneous occurrence of non-Hodgkin's lymphoma and acute myelomonocytic leukemia. *Cancer* 38: 2557-2560, 1976.
- Youness E, Ahearn MJ and Drewinko B: Simultaneous occurrence of non-Hodgkin's lymphoma and spontaneous acute granulocytic leukemia. *Am J Clin Pathol* 70: 415-420, 1978.
- Ohwada C, Nakaseko C, Tanaka H, Abe D, Oda K, Ozawa S, Takeuchi M, Shimizu N, Cho R, Saito Y and Nishimura M: Successful matched unrelated BMT for secondary AML which developed simultaneously with relapsed Hodgkin's lymphoma. *Bone Marrow Transplant* 39: 569-570, 2007.
- Jaalouk G, Avvisati G, Latagliata R, Pacchiarotti A, Pulsoni A, Mecarocci S and Malagnino F: Simultaneous occurrence of large B-cell non-Hodgkin lymphoma and myelodysplastic syndrome rapidly evolving into acute myeloblastic leukemia. *Leuk Lymphoma* 21: 339-341, 1996.
- Montefusco E, Fazi F, Cordone I, Ariola C, Nanni M, Spadea A, Spiriti MA, Fenu S, Mandelli F and Petti MC: Molecular remission following high-dose hydroxyurea and fludarabine plus cytarabine in a patient with simultaneous acute myeloid leukemia and low-grade lymphoma. *Leuk Lymphoma* 40: 671-674, 2001.
- Janossy G, Woodruff RK, Paxton A, Greaves MF, Capellaro D, Kirk B, Innes EM, Eden OB, Lewis C, Catovsky D and Hoffbrand AV: Membrane marker and cell separation studies in Ph1-positive leukemia. *Blood* 51: 861-877, 1978.
- Cauwelier B, Nollet F, De Laere E, Van Leeuwen M, Billiet J, Criel A and Louwagie A: Simultaneous occurrence of myelodysplastic syndrome and monoclonal B lymphocytes with a different clonal origin. *Leuk Lymphoma* 43: 191-193, 2002.