



Differential Subsampling with Cartesian Ordering Contrast-Enhanced Magnetic Resonance Angiography for the Preoperative Assessment of Anterolateral Thigh Flap

Yunfeng Shen¹, Xiucun Li², Chao Zhang¹, Hai Zhong¹, Weiqiang Dou³

Departments of ¹Radiology and ²Hand and Foot Surgery, The Second Hospital of Shandong University, Cheeloo College of Medicine, Jinan, China; ³MR Research China, GE Healthcare, Beijing, China

Objective: To investigate the clinical application of differential subsampling with Cartesian ordering (DISCO) contrast-enhanced (CE) magnetic resonance angiography for anterolateral thigh (ALT) flap transplantation, using operative findings as a reference.

Materials and Methods: Thirty patients (21 males and nine females; mean age \pm standard deviation, 45.5 \pm 15.6 years) who were scheduled to undergo reconstruction with ALT flaps between June 2020 and June 2021 were included in the prospective study. Before ALT flap transplantation, patients were scanned using CE-DISCO imaging. All acquired DISCO images of the 60 lower limbs (both sides from each patient) were analyzed using maximum intensity projection and volume rendering methods. Two experienced radiologists were employed to examine the patterns of the lateral circumflex femoral artery (LCFA), its branches, and perforators and their skin termini, which were compared with the operative findings.

Results: Using CE-DISCO, the patterns of the LCFA and its branches were clearly identified in all patients. Four different origins of the LCFA were found among the 60 blood vessels: type I (44/60, 73.3%), type II (6/60, 10.0%), type III (8/60, 13.3%), and type IV (2/60, 3.3%). Owing to a lack of perforators entering the skin, two patients did not undergo ALT flap transplantation. For the remaining 28 patients, the ALT flaps in 26 patients were successfully operated without flap reselection during the operation, while the remaining two patients underwent other surgical procedures due to the thin diameter of the perforator or injury of the perforator during the operation. The success rate of flap transplantation was 92.8% (26/28). All transplanted flaps exhibited good blood supply and achieved primary healing without infection or delayed healing.

Conclusion: CE-DISCO imaging can be an effective method for preoperative perforator imaging before ALT flap transplantation.

Keywords: *Differential subsampling with Cartesian ordering (DISCO); Anterolateral thigh flap; Contrast-enhanced magnetic resonance angiography; The lateral circumflex femoral artery*

INTRODUCTION

Anterolateral thigh (ALT) flap surgery uses perforators of the descending branch originating from the lateral

circumflex femoral artery (LCFA) [1] and has been widely used for reconstructive surgery of the head and neck region, as well as the extremities [2]. However, difficulties during flap dissection are often associated with the complex vascular anatomy and frequent intramuscular courses of perforators [3].

Various imaging modalities have been studied to assess relevant vascular anatomic structures, including Doppler ultrasound, computed tomography angiography (CTA), and magnetic resonance angiography (MRA). Doppler ultrasound can provide information about vessel anatomy, but it is time-consuming and requires highly trained technicians with knowledge of the perforator anatomy [4]. In previous studies where perforators were identified using Doppler

Received: September 20, 2021 **Revised:** March 29, 2022

Accepted: April 21, 2022

Corresponding author: Hai Zhong, MD, Department of Radiology, The Second Hospital of Shandong University, Cheeloo College of Medicine, #247 Beiyuan Road, Jinan 250033, China.

• E-mail: zhonghaifriend@126.com

This is an Open Access article distributed under the terms of the Creative Commons Attribution Non-Commercial License (<https://creativecommons.org/licenses/by-nc/4.0>) which permits unrestricted non-commercial use, distribution, and reproduction in any medium, provided the original work is properly cited.

ultrasound, significant limitations were encountered, including low test-retest reliability and high false-positive and false-negative rates [5]. In comparison, CTA is an imaging method that is superior to Doppler ultrasound and can display the blood supply of transplanted skin flaps and accurately evaluate the course of blood vessels, which is crucial for ensuring the success of flap transplantation [6]. However, because of the ionizing radiation from computed tomography (CT) machines, CTA can only be used to perform a single-phase scan, and thus, it is difficult to clearly detect the branch and perforator of the LCFA. Unlike CTA, MRA can also accurately locate perforating vessel branches without the risk of radiation exposure [7]. However, the long scan time of up to several tens of minutes hinders the clinical application of MRA owing to its low temporal resolution.

As a promising alternative, a spoiled gradient echo-based imaging technique, with a differential subsampling with Cartesian ordering (DISCO), which was developed with a pseudo-random variable density κ -space segmentation and κ -space shared reconstruction scheme [8], has been proposed for ultrafast dynamic enhanced MRA with high spatial and temporal resolution. With multi-phase contrast-enhanced (CE)-DISCO imaging, high spatial and temporal resolution and reduced image artifacts have been achieved for malignant focal hepatic lesions, focal enhanced breast lesions, and intracranial aneurysms [9-11]. However, it remains unknown whether DISCO imaging also has such advantages during preoperative assessment of ALT flaps.

Therefore, the main goal of this study was to evaluate the clinical feasibility of DISCO imaging for the preoperative assessment of ALT flaps, using operative findings as a reference.

MATERIALS AND METHODS

Subjects

This prospective study was approved by the Institutional Review Board (IRB No. KYLL-2021[LW]067), and written informed consent was obtained from each patient. Between June 2020 and June 2021, a total of 30 patients who were scheduled to undergo ALT flap transplantation and did not have lower limb vascular diseases, ineligibility for MR imaging, or renal insufficiency were included in the study. Patients' age ranged from 14 to 72 years (mean age \pm standard deviation, 45.5 \pm 15.6 years).

MRI Scanning

All MRI experiments were performed using a 3T MRI (SIGNA Pioneer) with a 28-channel body coil. Coronal DISCO imaging was performed with a field of view of 42 x 42 cm, covering the area of the base of the thigh to the lateral superior border of the patella. The other scan parameters included a repetition time = 3.1 ms, echo time = 1.1 ms, a flip angle = 25°, a slice thickness = 2.6–3.0 mm, and a matrix size = 320 x 256. Before DISCO imaging, gadoteric acid meglumine salt (0.4 mL/kg) was injected as the contrast agent at a rate of 3 mL/s. Coronal DISCO imaging with a total 15–20 arterial phases was performed 10 seconds after the onset of contrast agent administration. Each single-period scan took 5 seconds; therefore, the total scan time was 75–100 seconds.

Image Analysis

The acquired DISCO images were analyzed using maximum intensity projection (MIP) and volume rendering (VR) methods on a GE ADW4.7 workstation. Two experienced radiologists (with 5 years of MRI diagnostic experience, and with 20 years of MRI diagnostic experience) were employed to analyze the CE-DISCO images. After performing full-slab MIP on the original DISCO coronary images, each patient underwent continuous dynamic imaging of the blood vessels (Fig. 1). The best image of the LCFA and its branches without venous interference was selected for the thin-slab MIP and VR processing by two radiologists. The layer thickness of thin-slab MIP was 20–30 mm. The following information was recorded: origin, course, and distribution of the LCFA and the skin terminus of the perforator from the descending branch of the LCFA. The vertical and horizontal distances from the skin terminus of the perforator to the outer upper edge of the patella were considered the primary reference parameters for the surgeons to design the flap. If both radiologists were unsure of the origin of the LCFA or the terminus of the perforator, surgeons for the corresponding operations were consulted until a consensus was reached. In addition, surgeons evaluated whether the DISCO information matched the surgical information.

Surgical Methods

First, the area and shape of the flap were designed according to the size and shape of the wound and the findings provided by the CE-DISCO images, including the course and distribution of the LCFA and the position of the skin terminus of the perforator. Then, the terminus of

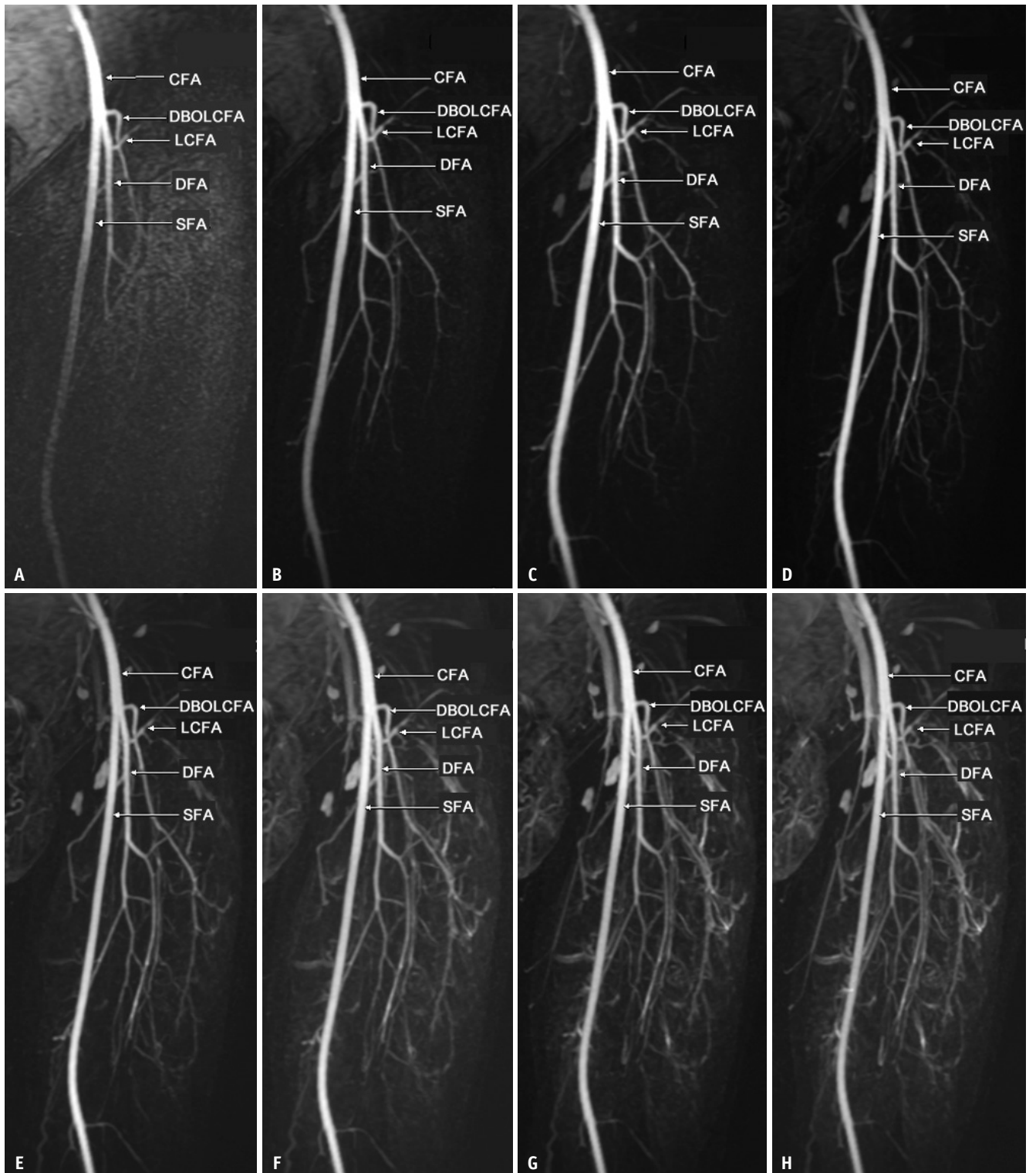


Fig. 1. Images (A-H) were acquired at the 4th–11th phases of the left thigh with DISCO contrast-enhanced magnetic resonance angiography imaging using full-slab maximum intensity projection in a 30-year-old male patient. Image (C) clearly shows the perforators. Image (A) was obtained at the earliest arterial phase. Venous interference began to appear from image (E) and gradually increased. CFA = common femoral artery, DBOLCFA = descending branch of the LCFA, DFA = deep femoral artery, DISCO = differential subsampling with Cartesian ordering, LCFA = lateral circumflex femoral artery, SFA = superficial femoral artery

the perforator was marked on the skin according to the vertical and horizontal distances from the skin terminus of the perforator to the outer upper edge of the patella on CE-DISCO images. The flap was dissociated, and the perforator was carefully explored. Tissues between the rectus femoris and vastus lateralis muscles were dissociated to clarify the origin of the perforator and to assess whether the perforator of the descending branch passed between the rectus femoris and vastus lateralis or passed through the vastus lateralis. After confirming the blood supply, a skin flap was transplanted to the wound edge.

RESULTS

Analysis of the LCFA and Descending Branch

Thirty patients underwent CE-DISCO imaging and 60 blood vessels were measured. The origin of the LCFA and its descending branches were used as the primary classification criteria. Four different origins of the LCFA were identified in this study. Type I (44/60, 73.3%): LCFA originating from the deep femoral artery (DFA); type II (6/60, 10.0%): LCFA originating from the common femoral artery (CFA) with the DFA at the same point; type III (8/60, 13.3%): the descending branches of the LCFA originating from the DFA, CFA, or superficial femoral artery (SFA) as a single trunk; type IV (2/60, 3.3%): LCFA originating from the CFA or SFA. Detailed information for each type is presented in Table 1. Figure 2 illustrates the four types of LCFA and representative DISCO images for the four types. Additionally, all DISCO images of the perforators and their skin termini were visualized well in 30 patients, which is crucial for flap design (Fig. 3).

Surgical Findings and Clinical Follow-Up after Transplantation

The flaps in this study were used in patients with severe

skin damage caused by hand and foot trauma. Owing to a lack of perforators entering the skin, two patients did not undergo ALT flap transplantation. Among the remaining 28 patients, the ALT flaps in 26 patients were successfully operated without flap re-selection during the operation. For the 26 patients, the origins of the descending branches and whether they were septocutaneous perforators obtained from the surgery were consistent with the DISCO findings. Simultaneously, at least one perforator shown in the DISCO images was dissociated and used as the supply artery for flap transplantation in these patients. The remaining two patients underwent other surgical procedures because of the thin diameter of the perforator or injury of the perforator during the operation. The success rate of flap transplantation was 92.8% (26/28). The area and shape of the flaps were designed according to the size and shape of the wounds combined with the course and distribution of the LCFA, and the position of the skin terminus of the perforators provided by the CE-DISCO images was suitable for the 26 patients. All transplanted flaps showed good blood supply and achieved primary healing without infection or delayed healing.

DISCUSSION

A classification system for the origin and ascending and descending branches of the LCFA was established and presented in a meta-analysis of 26 relevant articles [12]. In comparison, the ALT flap reported in our study required only the descending branch of the LCFA and its perforators as the blood supply arteries. Therefore, a modified classification criterion, focusing on the origin of the LCFA and its descending branch, was developed in this study. The major difference between the two classification methods was that type III in this study was based on the descending branches of the LCFA, without the ascending branches of the LCFA, which was also considered in type V in the meta-analysis. In addition, type I was the most common type in both studies, including 76.1% in the meta-analysis and 73.3% in this study. As for the other types of LCFA, the percentages were quite different, which may be due to our small sample size.

ALT flap surgery is based on perforators of the descending branch originating from the LCFA. There are many types of vascular pedicles in the ALT flaps. The pedicle terminates near the knee joint in the vastus lateralis muscle after providing perforators, which can be classified as either

Table 1. Anatomical Classification of the LCFA (n = 60)

Type	n (%)	Definition
I	44 (73.3)	LCFA originating from the DFA
II	6 (10)	LCFA originating from the CFA with the DFA at the same point
III	8 (13.3)	Ld originating from the DFA, CFA, or SFA as a single trunk
IV	2 (3.3)	LCFA originating from the CFA or SFA

CFA = common femoral artery, DFA = deep femoral artery, LCFA = lateral circumflex femoral artery, Ld = descending branches of the LCFA, SFA = superficial femoral artery

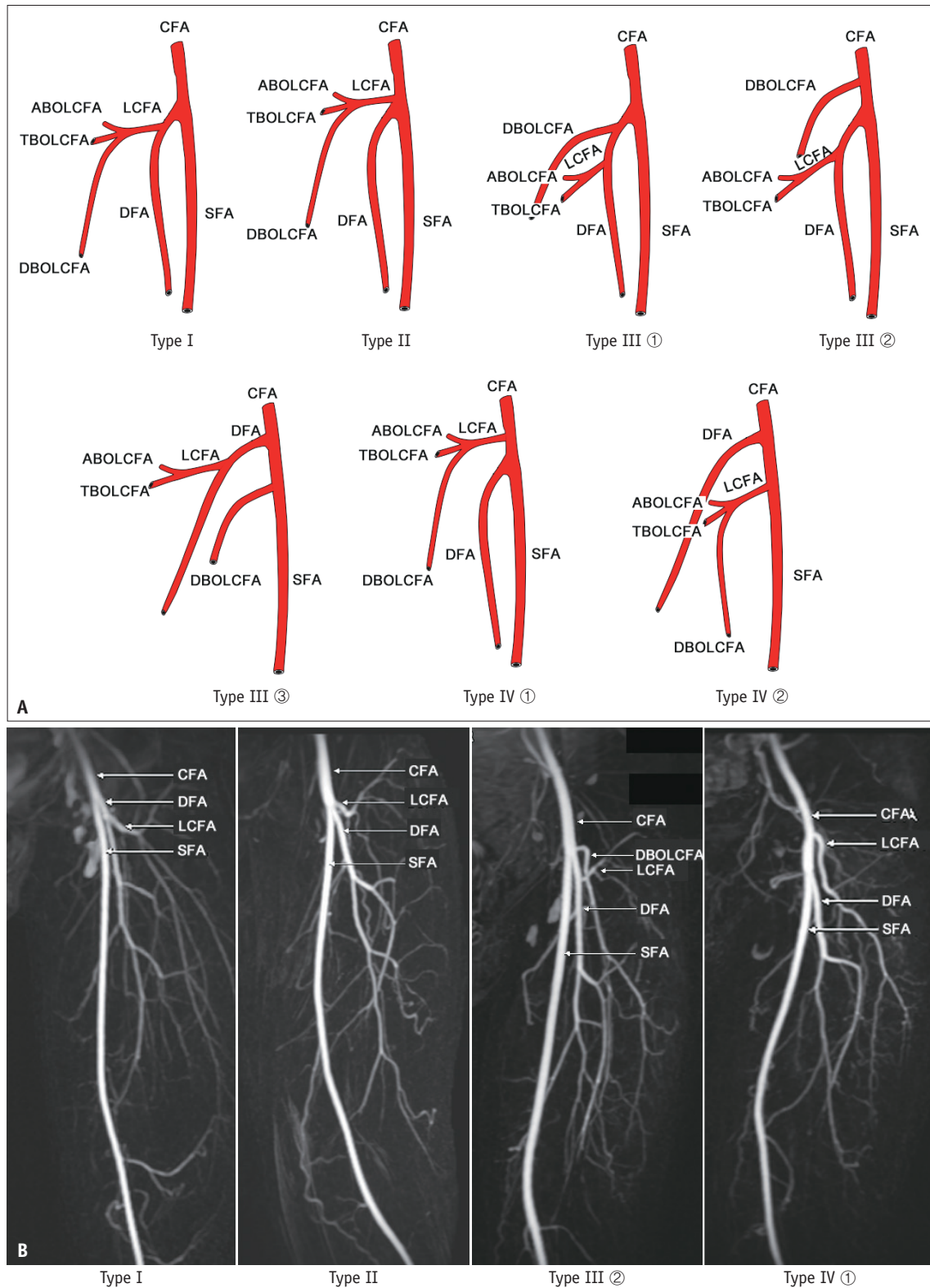


Fig. 2. The illustrations and representative DISCO images of the four types of the LCFA.

A. The illustrations of the four types of the LCFA. **B.** Representative DISCO images using full-slab maximum intensity projection for the four types of the LCFA. ABOLCFA = ascending branch of the LCFA, CFA = common femoral artery, DBOLCFA = descending branch of the LCFA, DFA = deep femoral artery, DISCO = differential subsampling with Cartesian ordering, LCFA = lateral circumflex femoral artery, SFA = superficial femoral artery, TBOLCFA = transverse branch of the LCFA

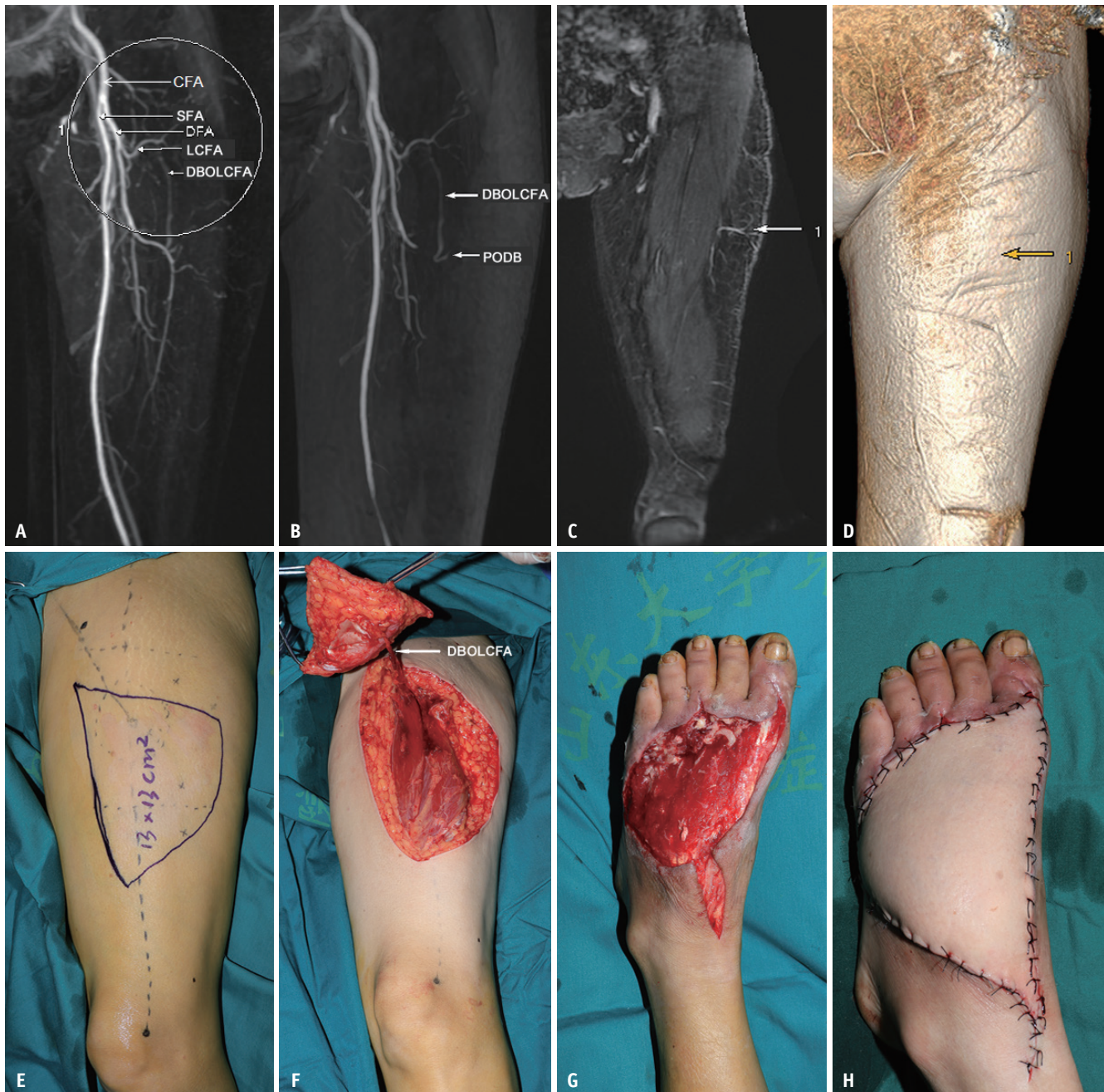


Fig. 3. A 55-year-old female underwent ALT flap transplantation.

A-H. The image using full-slab MIP showed the origin and distribution of the LCFA and its descending branch (A); the image using thin-slab maximum intensity projection showed the distribution of the DBOLCFA and the penetration point at which the perforator entered the skin (B); the original DISCO image and DISCO image with volume rendering analysis showed the clearest identification of the arrow 1 indicates the penetration point at which the perforator entered the skin (C, D); the boundary and shape of the flap designed based on the perforator (E); the DBOLCFA during surgical dissection and the free flap (F); the severely damaged foot before surgery (G); postoperative patient with successful reconstruction with ALT flap (H). ALT = anterolateral thigh, CFA = common femoral artery, DBOLCFA = descending branch of the LCFA, DFA = deep femoral artery, DISCO = differential subsampling with Cartesian ordering, LCFA = lateral circumflex femoral artery, PODB = perforator of descending branch, SFA = superficial femoral artery

septocutaneous (10%) or musculocutaneous (90%) [13]. Septocutaneous perforators pass between the rectus femoris and vastus lateralis, whereas musculocutaneous perforators pass through the vastus lateralis muscle. Compared with the

musculocutaneous perforator, the septocutaneous perforator was easier to separate from the adjacent muscles and fascia and imparted less damage to the surrounding tissues. Ideally, perforators should have optimal diameters and short

intramuscular courses. Therefore, for the preoperative flap design, septocutaneous perforators were always selected as blood supply vessels. In this study, because of the high spatial resolution, the original DISCO images allowed us to determine whether the perforator was septocutaneous or musculocutaneous.

MRA is a widely used method for vessel imaging, which does not require radiation. However, conventional MRA techniques usually require lengthy scanning times. Currently, the commonly used dynamic MR angiography methods mainly include liver acquisition with volume acceleration (LAVA) and time-resolved imaging of contrast kinetics (TRICKS). LAVA is a three-dimensional fast-spoiled gradient-echo sequence that automatically uses a partial K-space filling technique and a segmented SPECIAL technique. Abdominal measurement, particularly liver imaging, is usually performed using LAVA technology. This technique has been widely used for CE dynamic scans. LAVA provides higher-quality multiphase dynamic CE images and requires less time than conventional dynamic CE imaging [14,15]. Compared to LAVA imaging, DISCO can obtain a higher temporal resolution while preserving the spatial resolution [16]. In addition, TRICKS is a modified three-dimensional fast gradient-recalled echo sequence that uses the k-space elliptical-center-filling technique. Vascular measurements, particularly intracranial and spinal vascular anomalies, are usually obtained using TRICKS technology. The TRICKS sequence has superior temporal resolution, but poor spatial resolution [17,18]. Thus, TRICKS imaging cannot detail the relationship between the descending branch of the LCFA and muscle.

DISCO can generate high temporal resolution images with robust fat suppression without compromising spatial resolution or coverage [8]. Thus, DISCO can accommodate multiple arterial phases in a single breath-holding period. In this study, a single-phase scan required 5 seconds, which not only provided detailed information of blood vessels in the grafted skin flap but also accurately assessed the movement of blood vessels in the soft tissue of the flap. Multi-phase dynamic scanning also ensures the clarity of distal blood vessels, but with no radiation hazard, thus greatly facilitating clinical applications.

In addition, determining the location of the skin terminus of the perforator was also essential to increase the success rate of the operation. Owing to the advantages of strong soft tissue contrast, DISCO can accurately display the penetration point of the perforator entering the skin,

which provides a precise position for the operation. When designing a flap, surgeons should choose a flap with perforators entering the skin, which leads to high survival rates. After identifying the skin terminus of the perforator, the boundary and shape of the flap can be further designed, and small perforators should be protected during surgery to reduce the incidence of intraoperative injuries and improve the survival rate.

This study has some limitations. First, the sample size was small, which may have introduced a potential bias in the results. Second, this study did not include a control group for comparison. To address these issues and provide further validation, a large clinical cohort of ALT flap transplantation patients will be investigated using DISCO imaging. A control group with CTA as the reference will also be included to compare the accuracy of CE-DISCO in displaying the origin and course of the LCFA, as well as its main branches.

In conclusion, CE-DISCO imaging accurately showed the location of the origin and course of the LCFA and its main branches. By applying septocutaneous perforators or musculocutaneous perforators with short intramuscular courses as the blood supply, multi-phase dynamic DISCO imaging ensured clear identification of the number of perforators and the location of the skin terminus. This approach is convenient for delineating the ALT flap and greatly improves the surgical success rate.

Availability of Data and Material

The datasets generated or analyzed during the study are available from the corresponding author on reasonable request.

Conflicts of Interest

The authors have no potential conflicts of interest to disclose.

Author Contributions

Conceptualization: Yunfeng Shen, Xiucun Li, Hai Zhong. Data curation: Yunfeng Shen, Chao Zhang, Hai Zhong. Formal analysis: Weiqiang Dou. Funding acquisition: Hai Zhong. Investigation: Yunfeng Shen, Chao Zhang. Methodology: Yunfeng Shen, Xiucun Li, Hai Zhong. Project administration: Hai Zhong. Resources: Xiucun Li, Hai Zhong. Supervision: Hai Zhong. Validation: Xiucun Li. Writing—original draft: Yunfeng Shen. Writing—review & editing: all authors.

ORCID iDs

Yunfeng Shen

<https://orcid.org/0000-0002-0846-792X>

Xiucun Li

<https://orcid.org/0000-0002-3260-6299>

Chao Zhang

<https://orcid.org/0000-0002-8885-7871>

Hai Zhong

<https://orcid.org/0000-0002-5167-2590>

Weiqiang Dou

<https://orcid.org/0000-0003-0056-2014>

Funding Statement

This work was supported by China Health Promotion Foundation (XM_2020_011_0295_01).

REFERENCES

- Song YG, Chen GZ, Song YL. The free thigh flap: a new free flap concept based on the septocutaneous artery. *Br J Plast Surg* 1984;37:149-159
- Wei FC, Jain V, Celik N, Chen HC, Chuang DC, Lin CH. Have we found an ideal soft-tissue flap? An experience with 672 anterolateral thigh flaps. *Plast Reconstr Surg* 2002;109:2219-2226; discussion 2227-2230
- Rozen WM, Ashton MW, Pan WR, Kiil BJ, McClure VK, Grinsell D, et al. Anatomical variations in the harvest of anterolateral thigh flap perforators: a cadaveric and clinical study. *Microsurgery* 2009;29:16-23
- Rozen WM, Phillips TJ, Ashton MW, Stella DL, Gibson RN, Taylor GI. Preoperative imaging for DIEA perforator flaps: a comparative study of computed tomographic angiography and Doppler ultrasound. *Plast Reconstr Surg* 2008;121:9-16
- Hallock GG. Doppler sonography and color duplex imaging for planning a perforator flap. *Clin Plast Surg* 2003;30:347-357, v-vi
- Liu SC, Chiu WK, Chen SY, Lee TP, Wang HW, Chen SG. Comparison of surgical result of anterolateral thigh flap in reconstruction of through-and-through cheek defect with/without CT angiography guidance. *J Craniomaxillofac Surg* 2011;39:633-638
- Kiely J, Kumar M, Wade RG. The accuracy of different modalities of perforator mapping for unilateral DIEP flap breast reconstruction: a systematic review and meta-analysis. *J Plast Reconstr Aesthet Surg* 2021;74:945-956
- Saranathan M, Rettmann DW, Hargreaves BA, Clarke SE, Vasanawala SS. Differential subsampling with Cartesian ordering (DISCO): a high spatio-temporal resolution dixon imaging sequence for multiphase contrast enhanced abdominal imaging. *J Magn Reson Imaging* 2012;35:1484-1492
- Wei Y, Deng L, Yuan Y, Huang Z, He X, Wei X, et al. Gadoxetate acid disodium-enhanced MRI: multiple arterial phases using differential sub-sampling with Cartesian ordering (DISCO) may achieve more optimal late arterial phases than the single arterial phase imaging. *Magn Reson Imaging* 2019;61:116-123
- Morrison CK, Henze Bancroft LC, DeMartini WB, Holmes JH, Wang K, Bosca RJ, et al. Novel high spatiotemporal resolution versus standard-of-care dynamic contrast-enhanced breast MRI: comparison of image quality. *Invest Radiol* 2017;52:198-205
- Nael K, Drummond J, Costa AB, De Leacy RA, Fung MM, Mocco J. Differential subsampling with Cartesian ordering for ultrafast high-resolution MRA in the assessment of intracranial aneurysms. *J Neuroimaging* 2020;30:40-44
- Tomaszewski KA, Vikse J, Henry BM, Roy J, Pękala PA, Svensen M, et al. The variable origin of the lateral circumflex femoral artery: a meta-analysis and proposal for a new classification system. *Folia Morphol (Warsz)* 2017;76:157-167
- Ribuffo D, Atzeni M, Saba L, Milia A, Guerra M, Mallarini G. Angio computed tomography preoperative evaluation for anterolateral thigh flap harvesting. *Ann Plast Surg* 2009;62:368-371
- Li XH, Zhu J, Zhang XM, Ji YF, Chen TW, Huang XH, et al. Abdominal MRI at 3.0 T: LAVA-flex compared with conventional fat suppression T1-weighted images. *J Magn Reson Imaging* 2014;40:58-66
- Cao W, Li F, Gong J, Liu D, Deng Y, Kang L, et al. Liver acquisition with acceleration volume acquisition gadolinium-enhanced magnetic resonance combined with T2 sequences in the diagnosis of local recurrence of rectal cancer. *J Xray Sci Technol* 2016;24:855-863
- Ichikawa S, Motosugi U, Sato K, Shimizu T, Wakayama T, Onishi H. Transient respiratory-motion artifact and scan timing during the arterial phase of gadoxetate disodium-enhanced MR imaging: the benefit of shortened acquisition and multiple arterial phase acquisition. *Magn Reson Med Sci* 2021;20:280-289
- Amarouche M, Hart JL, Siddiqui A, Hampton T, Walsh DC. Time-resolved contrast-enhanced MR angiography of spinal vascular malformations. *AJNR Am J Neuroradiol* 2015;36:417-422
- Romano A, Tavanti F, Rossi Espagnet MC, Terenzi V, Cassoni A, Suma G, et al. The role of time-resolved imaging of contrast kinetics (TRICKS) magnetic resonance angiography (MRA) in the evaluation of head-neck vascular anomalies: a preliminary experience. *Dentomaxillofac Radiol* 2015;44:20140302