

Knee arthrodesis – ultima ratio for the treatment of the infected knee

Kniearthrodese – Ultima Ratio bei der Behandlung des infizierten Kniegelenkes

Abstract

The irretrievable destruction of the knee due to trauma, tumor or infection is the indication for knee arthrodesis. The main reason for knee arthrodesis in terms of infection is the infected total knee arthroplasty. Central problem is the definition of the term “irretrievable”. It is based on the subjective opinion of the attending physician and depends on his expert knowledge of this specific entity. The preservation of a functioning extremity is the main goal.

This article shows the typical indications and contraindications for knee arthrodesis following septic knee diseases. In addition it gives insight into the biomechanical and technical considerations to be kept in mind. Finally the postoperative care and outcome of different techniques are analysed.

Keywords: infected knee, knee arthrodesis, indications, technique

Zusammenfassung

Die unwiderrufliche Zerstörung des Kniegelenkes durch Trauma, Tumor oder Infektion stellt die Indikation zur Kniearthrodese dar. Die Hauptindikation zur Kniearthrodese besteht im Zusammenhang mit irreversibel zerstörten Knieendoprothesen.

Zentrales Problem bei der Indikationsstellung ist der Begriff "unwiederbringliche Zerstörung". Die Einschätzung einer derartigen Situation basiert auf dem subjektiven Empfinden des behandelnden Arztes und seiner Erfahrung auf diesem Gebiet.

Dieser Artikel zeigt die typischen Indikationen und Kontraindikationen zur Kniearthrodese nach infektbedingter Zerstörung des Kniegelenkes auf. Zusätzlich werden biomechanische und operationstechnische Aspekte beleuchtet. Abschließend werden die postoperative Nachbehandlung und die Ergebnisse unterschiedlicher Methoden beschrieben.

Schlüsselwörter: infiziertes Knie, Kniearthrodese, Indikationen, Techniken

Introduction

“Although the surgeon may consider an arthrodesis of the knee to be a poor outcome, a limb with a fusion is more efficient and functional than is one with an above-the-knee amputation” [8].

Despite the loss of a functioning joint knee fusion can provide a functional symptom-free extremity [4]. In certain situations it may be the only alternative to amputation [9], [30].

Today manifest irreparable destruction of the knee without any chance of reconstruction or (re)arthroplasty is the indication for knee arthrodesis [8].

These irreversible condition may be caused by:

- Trauma
- Tumor
- Joint infection.

Indications

The indication for knee arthrodesis underwent a constant modification during the decades. In the beginning, based on the lack of sophisticated other options, it was performed in cases of septic arthritis, articular tuberculosis

Andreas H. H. Tiemann¹

1 Department for Septic and Reconstructive Surgery, Clinic for Trauma- and Reconstructive Surgery, BG-Kliniken Bergmannstrost, Halle, Germany

and poliomyelitis as well as in cases of osteoarthritis and rheumatoid arthritis [7], [6], [8], [10], [23].

Based on the development of new and efficient therapeutic approaches in many of the above mentioned diseases nowadays the main indication for knee arthrodesis is an irreparable knee destruction based on an infected total knee replacement [5], [16], [22], [30]. According to statistical analyses infections of that type appear in 1 to 4% after primary total knee replacement [5]. Due to the rising number of patients who undergo these procedures the problem becomes more and more immanent [1], [25], [27]. After “changing procedures” the infection rate rises up to 20% [14].

Further indications for knee arthrodesis today are [13], [22]:

- Methaphyseal bone loss
- Ligamentous instability
- Multiple failed revisions
- Loss of extensor mechanism
- Infection with highly virulent organisms
- Inadequate soft tissue coverage
- A patient unwilling to consider a revision arthroplasty.

According to Vlasak 1995 and Windsor 1993 in 2006 MacDonald pointed out, that knee arthrodesis might be useful in young patients with unilateral posttraumatic joint destruction in jobs that require heavy manual labour [16], [26], [31]. As early as 1993 Isklar et al. demanded knee arthrodesis to be proceeded as early as possible in order to shorten the course of the disease, calm the infection, lower the use of analgetics and preserve bone and soft tissue [11]. With regard to the patient’s individual “ultima ratio situation” Bierwagen mentioned, that knee arthrodesis in general is the final method in order to preserve the extremity. Failure due to insufficient planning or technique will lead to amputation and subsequently to care dependency [5].

Contraindications

Contraindications for knee arthrodesis include various situations such as [8], [16], [22]:

- Infected contralateral knee arthroplasty
- Infected ipsilateral hip or ankle arthroplasty
- Extended bone defect
- Contralateral leg amputation
- Contralateral hip or knee arthrodesis
- Ipsilateral hip or ankle arthrosis.

Indication and contraindication for knee arthrodesis always have to be individualized to the patient’s specific situation in terms of [16]:

- Individual clinical situation
- Individual expectations
- Individual work area situation
- Individual social situation
- Individual mental situation.

Biomechanical considerations

Knee arthrodesis leads to significant functional changings in the lower extremity. Thus they also lead to significant biomechanical changings of the lower extremity, the pelvis and even the whole body. According to Conway et al. and Sandrone et al. the following may be detectable [8]:

- Increased pelvic inclination
- Increased ipsilateral coxal abduction
- Increased ipsilateral dorsalflexion of the ankle
- Increased energy required for walking (plus 25 to 30%) [22]. Thus knee arthrodesis is contraindicated when contralateral above-knee amputation was proceeded earlier (above-knee amputation increases the strain for walking by 25%). In addition the use of oxygen in patients with knee arthrodesis is 0.16 mL/kg/min compared to 0.20 mL/kg/min following above-knee amputation [8], [29].

Depending on the technique and the local situation knee arthrodesis leads to a leg shortening. If the estimated reduction is more than 5 cm (secondary) leg lengthening may be considered [8].

General principles

Depending on the chosen technique, the local situation and the estimated bone loss one has to differentiate between two general principles of knee arthrodeses (Figure 1):

- Tibio-femoral contact arthrodesis (“tibio-femoral kissing”)
 - This concept implicates the direct contact between femur and tibia. Thus bone fusion is possible and the main goal of this procedure.
- Tibio-femoral non-contact arthrodesis
 - This concept is chosen, if the loss of bone stock is this significant, that direct contact between femur and tibia is impossible or does not make sense. In these cases bone fusion is impossible.

Various techniques have been described in the last decades [22]:

- Long nail
 - Modular nail
 - Non-modular nail
- External fixation
 - Monoplanar fixators
 - Biplanar fixators
 - Circular frames
- Hybrid systems
 - Combination of intramedullar and external techniques
 - Compression plating
 - Vascularized fibular graft.

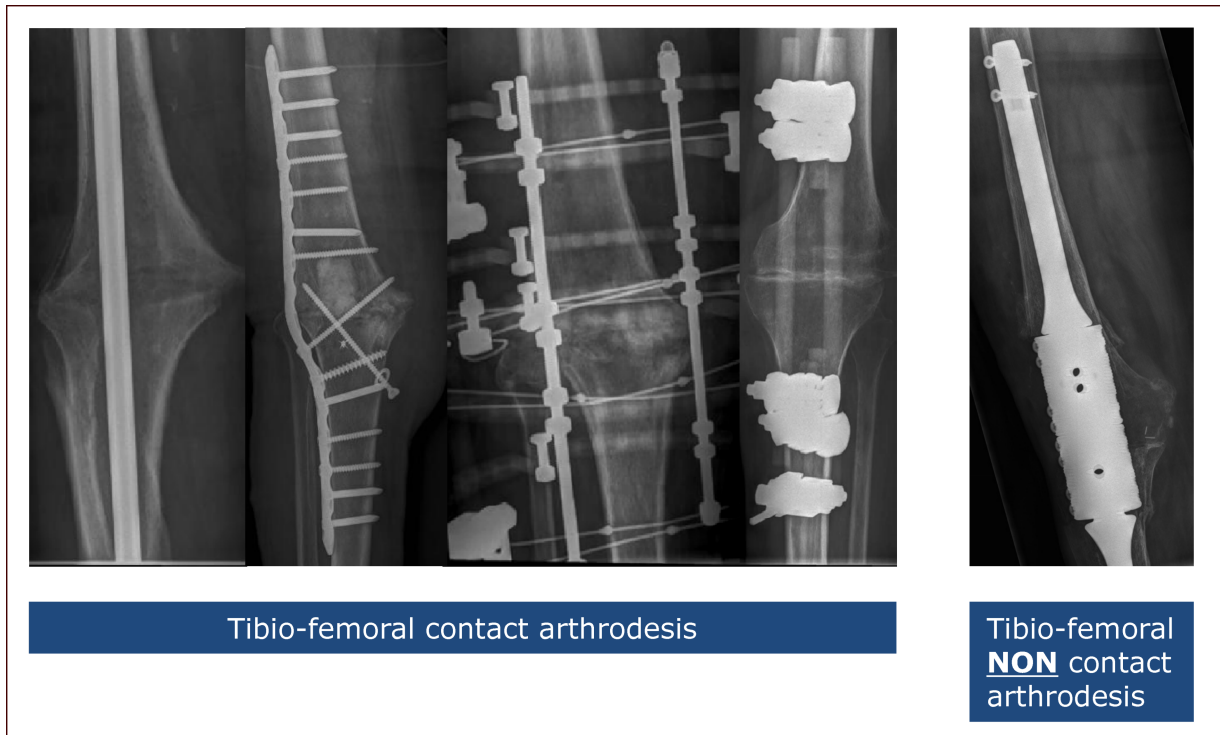


Figure 1: Types of knee arthrodeses

Strategy

In general

Knee arthrodesis needs a proper preoperative planning. The following considerations should be kept in mind:

- Correct tibio – femoral alignment
- External rotation tibia vs. femur: 10°
- Genuflexion: 10°
- Tibio-femoral contact arthrodesis: Removal of all cartilage (tibial cancellous bone meets femoral cancellous bone)
- Tibio-femoral contact arthrodesis: Fixation under compression in order to increase the bone healing
- Slight shortening of the leg in order to ease the "follow-through" of the leg.

Timing of the arthrodesis

According to the literature one may proceed knee arthrodesis in single, two or multi stage strategies [21]. In terms of knee arthrodeses following knee infection the strategy depends on the extent of the infection, its course, previous operations, the patient's general condition and the type and virulence of the infect causative pathogene (Figure 2). This thesis is supported by Waldmann et al. The authors mentioned in 1999 that "following prior surgical procedures resulting in a failed and infected arthroplasty, knee arthrodesis should ideally be attempted as a two stage procedure" [28]. We perform knee arthrodesis mostly in a multy stage regime due to the fact, that the infect situation after one surgical revi-

sion mostly is not sufficient calmed. To achieve this more than one operation is needed.

Temporary stabilisation of the knee (infect sedation period)

Analogous to the infect treatment in other sites of the musculo-skeletal system also in infected knees surgical eradication of the infected area and temporary stabilisation are the basic strategy. Thus the way of a temporary knee arthrodesis during the infection treatment has to be defined. The chosen strategy depends on the extent of the infection and the bone stock (Figure 3).

Choice of the correct method

The choice of the correct method for the definite knee arthrodesis depends on (Figure 4):

- Loss of bone stock
- Type and virulence of the pathogene that caused the infection
- Patient's general health.

We perform compression plate tibio-femoral contact arthrodeses as an exception in cases, where internal stabilisation may be particularly promising but the anatomical shape of femur and/or tibia does not allow an intramedullary system. Nevertheless in some cases supplementing the intramedullary stabilisation by plates (and bone grafts) leads to bone fusion even in difficult cases [20], [24].

As a new method in the last years computer assisted navigation for knee arthrodesis is mentioned in the liter-

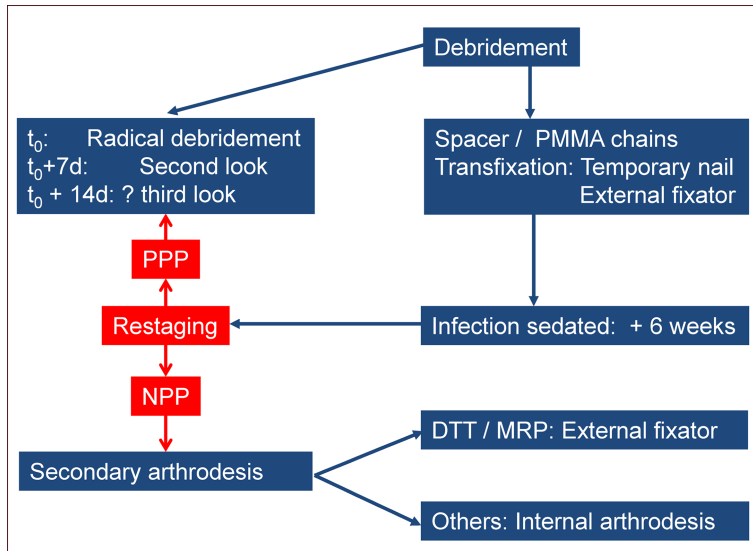


Figure 2: General algorithm for treatment of joint infection

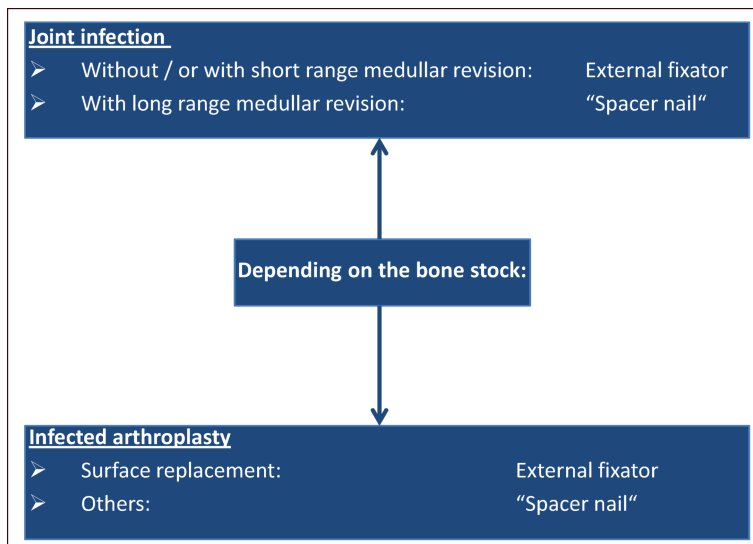


Figure 3: Considerations concerning the temporary knee stabilisation

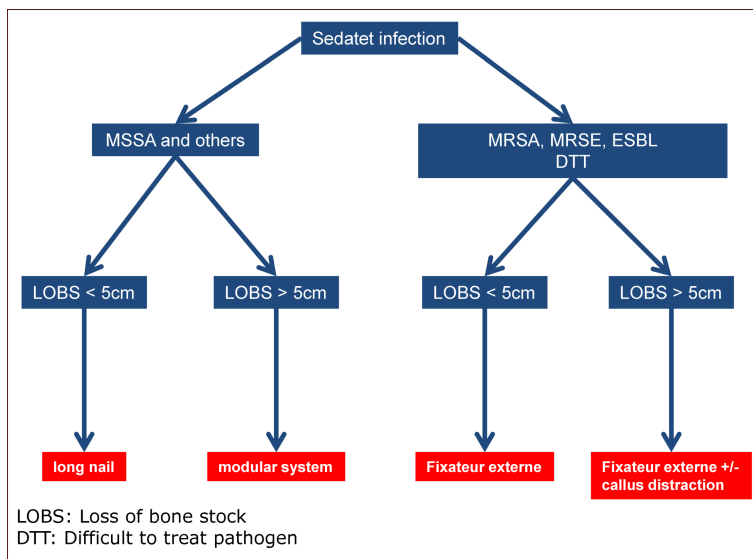


Figure 4: Choice of the correct implant

ature. By analogy with computer assisted implantation of total knee replacements the use of this technique should lead to a perfect three dimensional alignment of tibio-femoral contact arthrodeses. Maniar et al. described the method for the first time in a case of septic arthritis in 2011 [17].

Postoperative care

(Modular) internal stabilisation

- Mobilisation: First postoperative day
- Physiotherapy with full weight-bearing: First postoperative day (intramedullar stabilisation). Tibio-femoral plate arthrodesis: 20 kg for 4 weeks, 1/2 bodyweight till week 8, afterwards gradually rising till full bodyweight (week 12)
- Elasto-compressive wrapping until soft tissue is consolidated
- Low-dose heparin
- Patient visits the outpatient clinic every 2 weeks (month 1–3). Later once a month (month 4–6). Afterwards individual timing.
- X-ray every 4 weeks (month 1–3). Afterwards in month 6. Then individual timing. Additional CT in cases of complicated healing of tibio-femoral contact arthrodeses and in order to prove the bony consolidation of the tibio-femoral contact arthrodesis.

External stabilisation

- Mobilisation: First postoperative day
- Physiotherapy with full weight-bearing: First postoperative day (tibio-femoral contact arthrodesis)
- Elasto-compressive wrapping until soft tissue is consolidated
- Low-dose heparin
- Patient visits the outpatient clinic every 2 weeks (month 1-3). Later once a month (month 4-6). Afterwards individual timing.
- X-ray every 4 weeks (month 1-3). Afterwards in month 6. Then individual timing. Additional CT in cases of complicated healing of tibio-femoral contact arthrodeses and in order to prove the bony consolidation of the tibio-femoral contact arthrodesis.

External fixator “specialties”:

- Patient
 - Practice: Cleaning of the fixator wires and Schanz screws
- Doc
 - Tension of the wires (100N): Check once per week
 - Compression of the arthrodesis: Check every 2 weeks

Fusion rates of tibio-femoral contact arthrodeses

The fusion rates depend on the chosen technique. According to the literature the fusion rates of the intramedullar stabilized arthrodeses are approximately 10 to 15% higher than those achieved by external fixation.

Complications

Due to the fact, that knee arthrodeses are “ultima ratio” procedures, the rate of complications is rather high. According to the literature it ranges between 20 and 84%. Depending on the type of arthrodesis (see below) the following complications may occur [8], [12], [19]:

In general

- Tibio-femoral pseudarthroses
- Tibio-femoral nonunion
- Tibio-femoral malalignment
- Insufficient cancellous bone plastic
- Persistence or recurrence of the infection
Regardless of the chosen method the rate of recurrent infections is mentioned between 0 and approximately 20%.
Intramedullar arthrodesis: 0 to 22% [3], [9], [18], [15]
External fixation: 0 to 18% [9], [19], [26]
- Pain resulting from pseudarthroses or nonunions [2].
- Additional fractures

Depending on the method chosen

External fixation:

- Neurovascular lesions
- Failure of the construction (f.e. breakage of Schanz screws or wires etc.)
- Local infection at the entry points of Schanz screws or wires
- Fractures

Internal fixation:

- Breakage of the osteosynthesis material (intramedullar nail, plate)
- Dislocation of the osteosynthesis material
- Fractures

Résumé

A couple of key-factors may be postulated in order to choose the individual correct technique for knee arthrodesis for each patient:

- Key factor I: Profound knowledge of the correct indication for internal or external stabilisation (intramedullary nail / plate vs. external fixator).
- Key factor II: Profound knowledge of the advantages and disadvantages of the specific methods.
- Key factor III: Profound knowledge in trouble-shooting.
- Key factor IV: Precise individual planning for every patient.

Additionally one should keep in mind, that:

- The risk of recurrent infection is almost similar for internal and fixator based arthrodeses.
- The fusion rate for intramedullary contact arthrodeses is significantly higher than the one found when fixator contact arthrodeses are proceeded.

Notes

Competing interests

The author declares that he has no competing interests.

References

1. Agneskirchner JD, Lobenhoffer P. Endoprothetik des Kniegelenks [Endoprostheses of the knee joint]. *Unfallchirurg*. 2004 Mar;107(3):219-29. DOI: 10.1007/s00113-004-0746-6
2. Arroyo JS, Garvin KL, Neff JR. Arthrodesis of the knee with a modular titanium intramedullary nail. *J Bone Joint Surg Am*. 1997 Jan;79(1):26-35.
3. Bargiotas K, Wohlrab D, Sewecke JJ, Lavinge G, Demeo PJ, Sotereanos NG. Arthrodesis of the knee with a long intramedullary nail following the failure of a total knee arthroplasty as the result of infection. *J Bone Joint Surg Am*. 2006 Mar;88(3):553-8. DOI: 10.2106/JBJS.E.00575
4. Benson ER, Resine ST, Lewis CG. Functional outcome of arthrodesis for failed total knee arthroplasty. *Orthopedics*. 1998 Aug;21(8):875-9.
5. Bierwagen U, Walter G, Hoffmann R. Kniegelenksarthrodese–Lebensqualität und Vergleich der Methoden [Knee arthrodesis–quality of life and comparison of methods]. *Z Orthop Unfall*. 2010 Sep;148(5):566-72. DOI: 10.1055/s-0030-1249852
6. Charnley J, Baker SL. A study of the end-results of compression arthrodesis of the knee. *J Bone Joint Surg Br*. 1958 Nov;40-B(4):633-5.
7. Charnley J, Baker SL. Compression arthrodesis of the knee; a clinical and histological study. *J Bone Joint Surg Br*. 1952 May;34-B(2):187-99.
8. Conway JD, Mont MA, Bezwada HP. Arthrodesis of the knee. *J Bone Joint Surg Am*. 2004 Apr;86-A(4):835-48.
9. Damron TA, McBeath AA. Arthrodesis following failed total knee arthroplasty: comprehensive review and meta-analysis of recent literature. *Orthopedics*. 1995 Apr;18(4):361-8.
10. Hibbs RA. The treatment of tuberculosis of the joints of the lower extremities by operative fusion. *J Bone Joint Surg*. 1930;12:749-53.
11. Isiklar ZU, Landon GC, Tullos HS. Amputation after failed total knee arthroplasty. *Clin Orthop Relat Res*. 1994 Feb;(299):173-8.
12. Jerosch J, Fuchs S, Heisel J. Knieendoprothetik - eine Standortbestimmung. *Dtsch Arztebl*. 1997;94(8):449-55.
13. Kinik H. Knee arthrodesis with Ilizarov's bone transport method for large infected periarticular defects: a report of three cases. *J Trauma*. 2009 Dec;67(6):E213-9. DOI: 10.1097/TA.0b013e3180a02f01
14. Leone JM, Hanssen AD. Management of infection at the site of a total knee arthroplasty. *Instr Course Lect*. 2006;55:449-61.
15. Mabry TM, Jacofsky DJ, Haidukewych GJ, Hanssen AD. Comparison of intramedullary nailing and external fixation knee arthrodesis for the infected knee replacement. *Clin Orthop Relat Res*. 2007 Nov;464:11-5. DOI: 10.1097/BLO.0b013e31806a9191
16. MacDonald JH, Agarwal S, Lorei MP, Johanson NA, Freiberg AA. Knee arthrodesis. *J Am Acad Orthop Surg*. 2006 Mar;14(3):154-63.
17. Maniar RN, Baviskar JV. Computer assisted knee arthrodesis in a primary case of septic arthritis: a case report. *Knee*. 2011 Dec;18(6):480-2. DOI: 10.1016/j.knee.2010.07.009
18. McQueen DA, Cooke FW, Hahn DL. Knee arthrodesis with the Wichita Fusion Nail: an outcome comparison. *Clin Orthop Relat Res*. 2006 May;446:132-9. DOI: 10.1097/01.blo.0000214429.41904.82
19. Oostenbroek HJ, van Roermund PM. Arthrodesis of the knee after an infected arthroplasty using the Ilizarov method. *J Bone Joint Surg Br*. 2001 Jan;83(1):50-4. DOI: 10.1302/0301-620X.83B1.10572
20. Rasmussen MR, Bishop AT, Wood MB. Arthrodesis of the knee with a vascularized fibular rotatory graft. *J Bone Joint Surg Am*. 1995 May;77(5):751-9.
21. Schnettler R, Steinau HU. Septische Knochenchirurgie. Stuttgart, New York: Georg Thieme Verlag; 2004. ISBN 3-13-116981-8.
22. Somayaji HS, Tsaggerides P, Ware HE, Dowd GS. Knee arthrodesis—a review. *Knee*. 2008 Aug;15(4):247-54. DOI: 10.1016/j.knee.2008.03.005
23. Soto-Hall R. Fusion in charcots disease of the knee: new technique for arthrodesis. *Ann Surg*. 1938 Jul;108(1):124-6. DOI: 10.1097/0000658-193807000-00008
24. Stiehl JB, Hanel DP. Knee arthrodesis using combined intramedullary rod and plate fixation. *Clin Orthop Relat Res*. 1993 Sep;(294):238-41.
25. Stuby FM, Weise K. Kniegelenksarthrodese. *Op-Journal*. 2006;22:190-3. DOI: 10.1055/s-2007-979272
26. Vlasak R, Gearen PF, Petty W. Knee arthrodesis in the treatment of failed total knee replacement. *Clin Orthop Relat Res*. 1995 Dec;(321):138-44.
27. von Stein T, Gollwitzer H, Kruis C, Bühren V. Arthrodesis nach Knieendoprothetik am Beispiel der septischen Lockerung. *Orthopäde*. 2006;35:946-55. DOI 10.1007/s00132-006-0980-4
28. Waldman BJ, Mont MA, Payman KR, Freiberg AA, Windsor RE, Sculco TP, Hungerford DS. Infected total knee arthroplasty treated with arthrodesis using a modular nail. *Clin Orthop Relat Res*. 1999 Oct;(367):230-7. DOI: 10.1097/00003086-199910000-00029
29. Waters RL, Perry J, Antonelli D, Hislop H. Energy cost of walking of amputees: the influence of level of amputation. *J Bone Joint Surg Am*. 1976 Jan;58(1):42-6.
30. Wiedel JD. Salvage of infected total knee fusion: the last option. *Clin Orthop Relat Res*. 2002 Nov;(404):139-42. DOI: 10.1097/00003086-200211000-00024

31. Windsor RE. Knee arthrodesis. In: Insall JN, Windsor RE, Scott WN, Kelly MA, Aglietti P, eds. Surgery of the Knee. 2nd ed. New York: Churchill Livingstone; 1993. p. 1103-16.

Please cite as

Tiemann AH. Knee arthrodesis – ultima ratio for the treatment of the infected knee. *GMS Interdiscip Plast Reconstr Surg DGPW*. 2013;2:Doc07.
DOI: 10.3205/iprs000027, URN: urn:nbn:de:0183-iprs0000279

Corresponding author:

Prof. Dr. med. Andreas H. H. Tiemann
Department for Septic and Reconstructive Surgery, Clinic for Trauma- and Reconstructive Surgery, BG-Kliniken Bergmannstrost, Merseburgerstr. 165, 06112 Halle, Germany, Phone: +49/(0)345-1326632
andreas.tiemann@bergmannstrost.com

This article is freely available from

<http://www.egms.de/en/journals/iprs/2013-2/iprs000027.shtml>

Published: 2013-04-25

Copyright

©2013 Tiemann. This is an Open Access article distributed under the terms of the Creative Commons Attribution License (<http://creativecommons.org/licenses/by-nc-nd/3.0/deed.en>). You are free: to Share – to copy, distribute and transmit the work, provided the original author and source are credited.