

Case Report

Two Cases of Cranial Nerve Metastasis Treated with Radiotherapy and Chemotherapy in Patients with Lung Adenocarcinoma

Erika Kobayashi^a Takeshi Masuda^a Satoshi Nakao^b
Kakuhiro Yamaguchi^a Shinjiro Sakamoto^a Yasushi Horimasu^a
Shintaro Miyamoto^a Taku Nakashima^a Hiroshi Iwamoto^b
Kazunori Fujitaka^b Hironobu Hamada^c Noboru Hattori^b

^aDepartment of Respiratory Internal Medicine, Hiroshima University Hospital, Hiroshima, Japan; ^bDepartment of Molecular and Internal Medicine, Graduate School of Biomedical and Health Sciences, Hiroshima University, Hiroshima, Japan; ^cDepartment of Physical Analysis and Therapeutic Sciences, Hiroshima University, Hiroshima, Japan

Keywords

Cranial nerve metastasis · Lung adenocarcinoma · Chemotherapy · Radiotherapy · Non-small cell lung cancer

Abstract

The incidence of central nervous system metastasis is known to be high among patients with lung cancer. The frequency of brain metastasis and carcinomatous meningitis during the entire clinical course of non-small cell lung cancer is reported to be about 40% and 5%, respectively. In contrast, the incidence of cranial nerve metastasis is extremely rare, and detailed reports of its clinical course remain limited. Herein, we report 2 patients diagnosed with cranial nerve metastasis of lung adenocarcinoma and treated with radiotherapy and systemic chemotherapy. Both patients had cranial nerve symptoms, and brain magnetic resonance imaging showed cranial nerve enhancement. However, no evidence of carcinomatous meningitis was noted on magnetic resonance imaging and cerebrospinal fluid cytology. Based on these observations, these patients were diagnosed with cranial nerve metastasis of lung adenocarcinoma. Radiotherapy and chemotherapy were performed in both cases. In both cases, neurological symptoms had not worsened and imaging findings did not indicate any deteriorations. Therefore, radiotherapy and systemic chemotherapy should be considered when treating cranial nerve metastasis of lung adenocarcinoma. Early therapeutic intervention may lead to attenuation of the cranial nerve dysfunction resulting from cranial nerve metastasis.

© 2020 The Author(s).
Published by S. Karger AG, Basel

Takeshi Masuda
Department of Respiratory Internal Medicine, Hiroshima University Hospital
1-2-3 Kasumi, Minami-ku
Hiroshima 734-8551 (Japan)
ta-masuda@hiroshima-u.ac.jp

Introduction

Lung cancer is the most common cause of cancer-related deaths worldwide [1]. The incidence of central nervous system metastasis is known to be high among patients with lung cancer [2]. In fact, the frequency of brain metastasis and carcinomatous meningitis during an entire clinical course of non-small cell lung cancer (NSCLC) is reported to be about 40% and 5%, respectively [2]. In contrast, cranial nerve metastasis is extremely rare, and its frequency among lung cancer patients has not been reported. Moreover, as the clinical course of cranial nerve metastasis is relatively unknown, a standard treatment has yet to be established.

Here, we detail the clinical course of 2 cases of cranial nerve metastasis, treated by radiotherapy and chemotherapy, in lung adenocarcinoma patients.

Case Report

Case 1

A 63-year-old woman presented with cold-like symptoms in April 2014. She had a history of heavy smoking (40 cigarettes/day \times 40 years) but had no major previous medical history. Chest computed tomography (CT) revealed tumors in the right upper lobe of the lung. After a detailed examination, she was diagnosed with lung adenocarcinoma, clinical T4N2M0 stage IIIB without active mutation. Chemoradiotherapy was initiated, and a partial response was achieved in February 2015; however, in November 2017, she noticed the onset of deafness in her left ear and was admitted to the hospital. Upon admission, the patient's Eastern Cooperative Oncology Group (ECOG) performance status (PS) was 0 and the vital signs were normal. Although there were no symptoms of meningeal irritation, hearing in the left ear was impaired. In addition, an abnormal gait indicated that her balance was impaired. Head contrast-enhanced magnetic resonance imaging (MRI) showed a contrast effect on the left vestibulocochlear nerve (Fig. 1a), but no new brain metastasis was observed. Cerebrospinal fluid examination showed no abnormal appearance or malignant cells, and the spinal fluid pressure was normal. Based on these observations, the patient was diagnosed with left vestibulocochlear nerve metastasis. CT showed no recurrence of the tumors in the body trunk treated by chemoradiotherapy; therefore, stereotactic radiotherapy and chemotherapy (carboplatin [AUC = 5] + pemetrexed 500 mg/m²) were initiated. MRI showed a reduction in the nerve contrast enhancement after radiotherapy and 2 cycles of chemotherapy (Fig. 1b), followed by 6 cycles of chemotherapy (Fig. 1c). At a follow-up assessment 20 months later, the neuro-

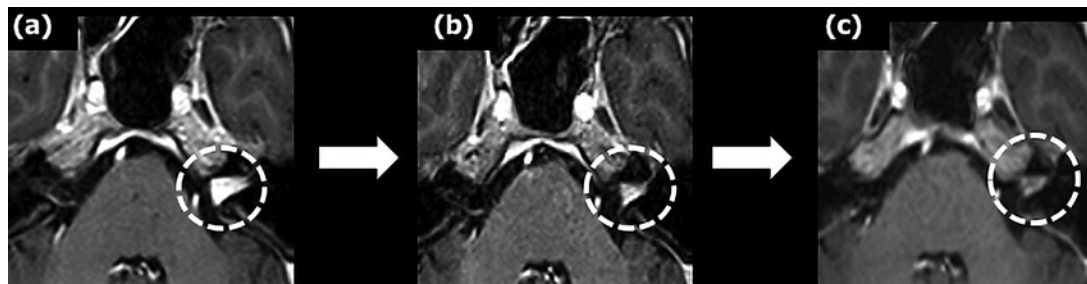


Fig. 1. Changes in head contrast-enhanced magnetic resonance imaging (MRI) findings. **a** Contrast-enhanced MRI scan obtained at diagnosis. The left vestibulocochlear nerve showed a contrast effect (dashed circle), and no brain metastasis could be observed. **b** Contrast-enhanced MRI scan obtained following 2 cycles of chemotherapy. **c** Contrast-enhanced MRI scan obtained following 6 cycles of chemotherapy, demonstrating a reduction in the contrast enhancement of the left vestibulocochlear nerve.

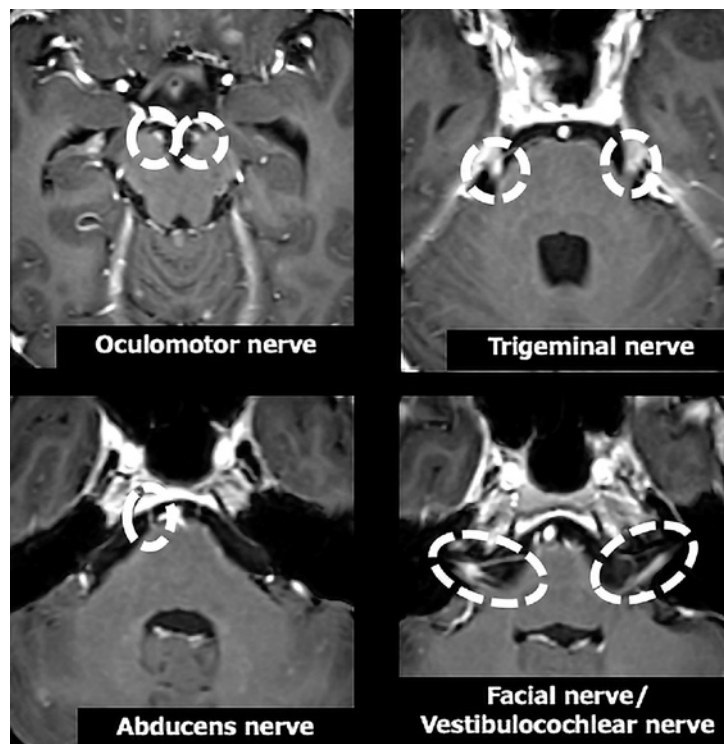


Fig. 2. Head contrast-enhanced magnetic resonance imaging findings. The oculomotor, trigeminal, abducens, facial, and vestibulocochlear nerves showed contrast enhancement (dashed circles). The previously treated brain metastases appeared to have shrunk, and no new brain metastases could be observed.

logical symptoms had not worsened, and the imaging findings did not indicate any deterioration either.

Case 2

A 41-year-old woman presented with a cough and chest pain in June 2018. Chest CT revealed tumors in the left upper lobe of the lung. After a detailed examination, she was diagnosed with lung adenocarcinoma, clinical T4N3M1c stage IVB, brain metastases, and EGFR (epidermal growth factor receptor) mutation (exon 19 deletion). Administration of erlotinib was initiated, which had a partial anti-tumor effect; however, the patient noticed diplopia and facial nerve palsy in January 2019 and was admitted. Upon admission, her ECOG PS was 0 and the vital signs were normal, but she had double vision and bilateral masseter muscle atrophy. In addition, bilateral facial sensory abnormalities and right facial nerve palsy were observed. There were no meningeal irritation symptoms. Head MRI showed contrast enhancement of the right abducens nerve and of the following bilateral nerves: oculomotor, trigeminal, facial, and vestibulocochlear. The brain metastases previously treated with erlotinib appeared to have shrunk (Fig. 2), and lesions outside the central nervous system showed no progression on CT. Cerebrospinal fluid examination showed no abnormal findings or malignant cells. In addition, plasma EGFR T790M mutation was not detected. Based on these observations, the patient was diagnosed with cranial nerve metastases, and whole-brain radiation therapy (WBRT) and chemotherapy (carboplatin [AUC = 5] + pemetrexed 500 mg/m² + bevacizumab [15 mg/kg]) were initiated. After radiotherapy and 2 courses of chemotherapy, the nerve enhancement showed a reduction (Fig. 3), and the patient's symptoms were relieved. At a follow-up assessment 7 months later, the neurological symptoms had not worsened, and no findings indicative of worsening were noted on imaging.

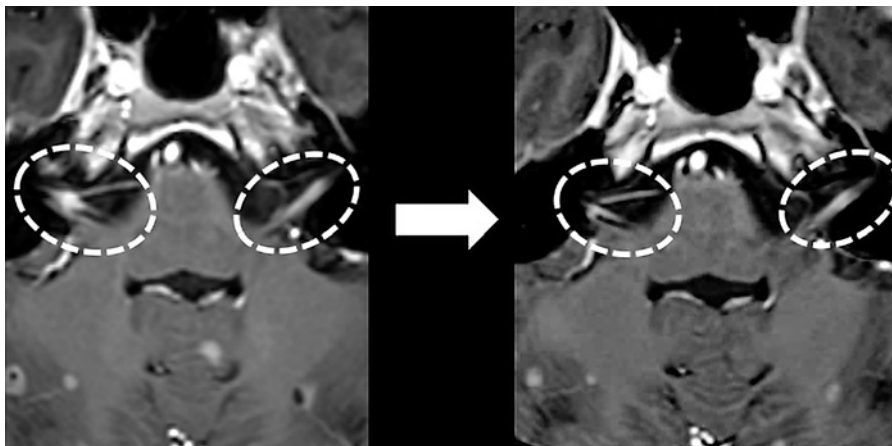


Fig. 3. Changes in head contrast-enhanced magnetic resonance imaging findings. Contrast enhancement of the facial and vestibulocochlear nerves appeared to have reduced (dashed circles) after 2 cycles of chemotherapy.

Discussion

To our knowledge, this is the first report to detail the clinical course of cranial nerve metastasis in 2 lung adenocarcinoma patients treated with radiotherapy and systemic chemotherapy. In these cases, central nervous system metastases were effectively controlled through the treatments.

Approximately 8% of patients with malignant tumors, including lung cancer, experience symptoms that demonstrate cranial nerve involvement. The major cause of symptoms involving cranial nerves is reported to be carcinomatous meningitis [3]; therefore, we suspected carcinomatous meningitis to be the cause of the similar symptoms in our 2 cases. For the diagnosis of carcinomatous meningitis, contrast-enhanced MRI and cerebrospinal fluid cytology are essential. For carcinomatous meningitis, the sensitivity of contrast-enhanced MRI and cerebrospinal fluid cytology is approximately 70% and 71%, respectively [4, 5]. The sensitivity of cytology is reported to increase with each repetition: 86% when repeated 2 times, 90% when repeated 3 times, and 98% when repeated 4 or more times [4]. In addition, the standard treatment for carcinomatous meningitis is WBRT and chemotherapy. However, the prognosis for patients with carcinomatous meningitis is very poor, and the average survival time is reported to be about 3 months [5]. In both of our cases, typical MRI and cerebrospinal fluid examination findings, as well as progressive clinical courses of carcinomatous meningitis, were not observed. Therefore, we diagnosed both patients with cranial nerve metastases.

To the best of our knowledge, only 1 case of cranial nerve metastasis due to NSCLC has been reported previously [6]. In that case, resection of the left inner ear nerve tumor was performed to diagnose and preserve nerve function, and the tumor was diagnosed as squamous cell lung cancer. Chemotherapy was administered, but the patient died about 12 months later. Therefore, the present report appears to be the first to show the clinical course of cranial nerve metastases in patients treated with radiotherapy and systemic chemotherapy. No standard treatment for cranial nerve metastasis has been established, and treatment strategies would be according to brain metastasis. The standard treatment options for brain metastasis are surgery and radiotherapy (WBRT or stereotactic radiation therapy). Treatment selection depends on the number of brain metastases and whether they are symptomatic [7].

In addition, systemic chemotherapy is also performed because of its effectiveness in cases of brain metastasis. In one study, the administration of cisplatin plus pemetrexed in NSCLC patients resulted in intra- and extracranial lesion response rates of 41.9% and 34.9%, respectively [8]. Therefore, radiotherapy and systemic chemotherapy should be considered when treating patients with cranial nerve metastasis.

Early therapeutic intervention may lead to attenuation of the cranial nerve dysfunction resulting from cranial nerve metastasis. In case 1, the duration from symptom onset to treatment outset was 4 months, and no symptom improvement was observed. In contrast, in case 2, the duration was 1 month, and the symptoms showed improvement. This is consistent with a previous prospective study of metastatic spinal cord compression, which showed that early therapeutic intervention leads to prevention of neurological dysfunction [9].

Based on our findings from 2 cases of cranial nerve metastases in lung adenocarcinoma patients, we conclude that to improve symptoms and reduce the loss of function resulting from metastasis, radiotherapy and chemotherapy should be started as soon as possible.

Statement of Ethics

Informed consent was obtained from the patient or the family of the deceased patient for publication of this case report and accompanying images.

Conflict of Interest Statement

The authors have no conflicts of interest to declare.

Funding Sources

There authors received no funding from any organization.

Author Contributions

Conceptualization: Erika Kobayashi, Takeshi Masuda, Kazunori Fujitaka, and Noboru Hattori. Writing of the initial draft: Erika Kobayashi and Takeshi Masuda. Review or revision: Satoshi Nakao, Kakuhiro Yamaguchi, Shinjiro Sakamoto, Yasushi Horimasu, Shintaro Miyamoto, Taku Nakashima, Hiroshi Iwamoto, Kazunori Fujitaka, Hironobu Hamada, and Noboru Hattori. Data collection: Erika Kobayashi, Takeshi Masuda, Satoshi Nakao, Kakuhiro Yamaguchi, Shinjiro Sakamoto, Hiroshi Iwamoto, Kazunori Fujitaka, and Noboru Hattori. Supervision: Noboru Hattori.

References

- 1 Torre LA, Bray F, Siegel RL, Ferlay J, Lortet-Tieulent J, Jemal A. Global cancer statistics, 2012. *CA Cancer J Clin*. 2015 Mar;65(2):87–108.
- 2 Turkaj A, Morelli AM, Vavalà T, Novello S. Management of leptomeningeal metastases in non-oncogene addicted non-small cell lung cancer. *Front Oncol*. 2018 Jul;8:278.
- 3 Gokce M. Analysis of isolated cranial nerve manifestations in patients with cancer. *J Clin Neurosci*. 2005 Nov;12(8):882–5.

- 4 Glantz MJ, Cole BF, Glantz LK, Cobb J, Mills P, Lekos A, et al. Cerebrospinal fluid cytology in patients with cancer: minimizing false-negative results. *Cancer*. 1998 Feb;82(4):733–9.
- 5 Pavlidis N. The diagnostic and therapeutic management of leptomeningeal carcinomatosis. *Ann Oncol*. 2004; 15 Suppl 4(Suppl 4):iv285–91.
- 6 Schrock A, Laffers W, Bootz F. Solitary metastasis of lung carcinoma to the internal auditory canal. *Am J Otolaryngol*. 2006 May–Jun;27(3):214–6.
- 7 NCCN. [NCCN clinical practice guideline in oncology \(NCCN Guidelines®\). Non-small cell lung cancer. Version 2. 2018.](#) December 19, 2017.
- 8 Barlesi F, Gervais R, Lena H, Hureaux J, Berard H, Paillot D, et al. Pemetrexed and cisplatin as first-line chemotherapy for advanced non-small-cell lung cancer (NSCLC) with asymptomatic inoperable brain metastases: a multicenter phase II trial (GFPC 07-01). *Ann Oncol*. 2011 Nov;22(11):2466–70.
- 9 Husband DJ. Malignant spinal cord compression: prospective study of delays in referral and treatment. *BMJ*. 1998 Jul;317(7150):18–21.