

## TRANSBRONCHIAL BIOPSY IN CHRONIC HYPERSENSITIVITY PNEUMONITIS

*Andre B. Botelho, Rimarcs G. Ferreira, Ester N. A. M. Coletta, Milena T. Cerezoli, Rafaela B. Martins, Paula S. Gomes, A. Gimenez, Luiz H. Ota, Maria Raquel Soares, Carlos Alberto C. Pereira*

Federal University of São Paulo

**ABSTRACT. Introduction:** The diagnosis of chronic hypersensitivity pneumonitis (CHP) is based on relevant exposure, tomographic findings and, in some cases, pathological data. The role of bronchoscopy is uncertain, especially in the fibrotic form of CHP. **Aim:** To analyze the yield of transbronchial biopsy (TBBx) in patients with CHP according to tomographic findings and to evaluate the importance of bronchoalveolar lavage (BAL) in the diagnostic approach. **Methods:** This retrospective study analyzed patients with CHP who underwent TBBx in São Paulo, Brazil. The TBBx findings were classified as characteristic (granulomas and/or multinucleated giant cells, associated or not with peribronchiolar infiltration of lymphocytes and plasma cells and bronchiolocentric distribution) and supportive (data indicative of small airway injury: peribronchiolar metaplasia, organizing pneumonia, and intra-alveolar foamy macrophages). **RESULTS:** One hundred nine patients were included. The presence of characteristic findings of HP was seen in 16 patients (14.7%), and supportive findings were seen in 32 patients (29.4%), with a total yield of 44%. Pathological characteristic findings were more common in cases without fibrosis on high-resolution computed tomography (HRCT) (27.3% vs. 9.2%,  $p=0.014$ ), whereas the presence of supportive findings was more common in fibrotic HP (38.1% vs. 9.1%,  $p=0.002$ ). Fifty-two patients had differential cytology in BAL fluid. Lymphocytosis ( $\geq 20\%$ ) was present in 51.9% of the patients. There was no difference in the median lymphocyte count according to nonfibrotic and fibrotic tomographic findings on HRCT. **Conclusion:** TBBx and BAL fluid cytology have a role in CHP diagnosis.

**KEY WORD:** Hypersensitivity Pneumonitis; Transbronchial Biopsy; Bronchoalveolar Lavage

Received: 30 October 2019

Accepted after revision: 13 April 2021

Correspondence: ????

### INTRODUCTION

Hypersensitivity pneumonitis (HP) is a common interstitial lung disease (ILD) in Brazil (1). HP is better characterized as a syndrome with variable clinical presentation, natural history, and severity caused by a wide range of inhaled antigens (2). A precise diagno-

sis is essential since the avoidance of the causal factor is the most important intervention in managing this condition (3). In the last few years, some diagnostic algorithms have been proposed for HP diagnosis; however, they are discordant and are not widely accepted (4,5,6). In all models, however, the presence of a well-characterized causal factor is critical, and in association with suggestive tomographic pattern, it can be sufficient for the diagnosis. HP can be classified as acute or chronic, and the latter is subdivided into nonfibrotic and fibrotic HP. The presence of fibrosis portends a worse prognosis (7).

The diagnosis of HP can be suggested on a transbronchial biopsy (TBBx) in an appropriate clinical context. TBBx is considered suggestive of HP if it displays loose granulomas or giant cells and inflamma-

tory bronchiolitis or a peribronchiolar mononuclear cellular interstitial infiltrate. The results from TBBx and cell differential count in bronchoalveolar lavage (BAL) fluid were first described in series involving patients with farmer's lung, an acute presentation of the disease. High lymphocyte counts were seen in these cases (8). In chronic HP (CHP), increased lymphocytes can be absent in BAL fluid (9). In chronic disease, especially in the fibrotic form, granulomas or giant cells can be absent, and bronchiolocentric interstitial pneumonia is found in many cases in specimens of surgical lung biopsy (SLB) (10). In TBBx, indirect findings indicative of bronchiolar injury and obstruction (peribronchiolar metaplasia and alveolar foamy macrophage accumulation, respectively) can be supportive of the diagnosis (11).

The yield of TBBx in CHP specimens was evaluated in a large series only recently (12). TBBx revealed characteristic findings in 40.2% of the cases, with no difference between patients with inflammatory and fibrotic disease. The addition of TBBx significantly increased the diagnostic yield of the BAL fluid lymphocyte count.

We aimed to evaluate, in a large retrospective series of CHP cases, the yield of TBBx, classified as showing characteristic and supportive findings, according to the high-resolution computed tomography (HRCT) findings. The additional values of BAL fluid lymphocyte count were also reviewed in a subset of the sample.

## METHODS

This retrospective study included patients with CHP who underwent TBBx, evaluated between January 1999 and December 2017, in a tertiary center of ILD in São Paulo, Brazil. CHP was characterized by findings indicative of fibrosis on HRCT (fibrotic HP) or, in its absence, by symptom duration greater than 6 months (nonfibrotic HP). The diagnosis of CHP was made by retrospective application of diagnostic criteria proposed by Salisbury et al (4). By these criteria, HP is divided into probable and possible HP, considering relevant exposure, compatible tomographic findings and greater than 20% to 30% of lymphocytes in BAL fluid. After this evaluation, if cases remain indeterminate, a surgical lung biopsy (SLB) is recommended.

The clinical data extracted from the medical records included gender, age, the duration of symp-

toms, smoking history, respiratory symptoms, possible causative antigens for HP determined by a systematic questionnaire, the results of pulmonary function testing, BAL fluid lymphocyte percentage, and TBBx results. Patients with incomplete medical records, patients not undergoing TBBx, and patients with biopsies not containing alveoli were excluded from the analyses.

Thoracic radiologists and pulmonologists with extensive experience in ILD described the HRCT findings. Special attention was given to findings indicative of fibrosis (traction bronchiectasis or bronchiolectasis, reticulations, and honeycombing). Cases with ground glass opacity but with findings indicative of fibrosis were classified in the fibrotic category. HRCT findings suggestive of HP include one or more of the following: upper lung predominance, peribronchovascular distribution, extensive ground glass opacity larger than reticulations, centrilobular nodules, and mosaic attenuation in three or more lobes (4,6,13,14).

The BAL fluid was collected according to European Respiratory Society (ERS) recommendations, and the differential cytology count was determined in a subset of cases (15). Several cutoffs were calculated for the characterization of increased lymphocytes. Bronchoscopists with extensive experience performed the TBBx. The samples were evaluated by two thoracic pathologists (RGF, ENAMC) with long-term experience in ILD.

The pathological findings in TBBx for diagnostic purposes were classified into:

- Characteristic: The presence of loose granulomas or giant cells, associated or not with peribronchiolar lymphoplasmacytic infiltrate and bronchiolocentric distribution.
- Supportive: Peribronchiolar metaplasia, alveolar foamy macrophage accumulation, and foci of organizing pneumonia. The inclusion of these findings as supportive of HP was made considering the presence of these findings in TBBx in the present series (19.2%) in comparison to 4.8% of 63 patients ( $\chi^2=5.84$ ,  $p=0.016$ ) from our center with other types of ILD (connective tissue diseases in 39 patients, undetermined etiology in 15, idiopathic pulmonary fibrosis (IPF) in 5, and idiopathic nonspecific interstitial pneumonia in 1 patient). When SLB was performed, the findings were classified as the following: 1) typical in the presence of chronic cellular bronchiolitis, chronic cellular interstitial pneumonia, and

small loose non-necrotizing granulomas or giant cells, and 2) bronchiolocentric interstitial pneumonia without granulomas or giant cells (10).

The study was approved by the internal review boards of the authors' institutions. Because of the retrospective nature of the study, informed consent was not required.

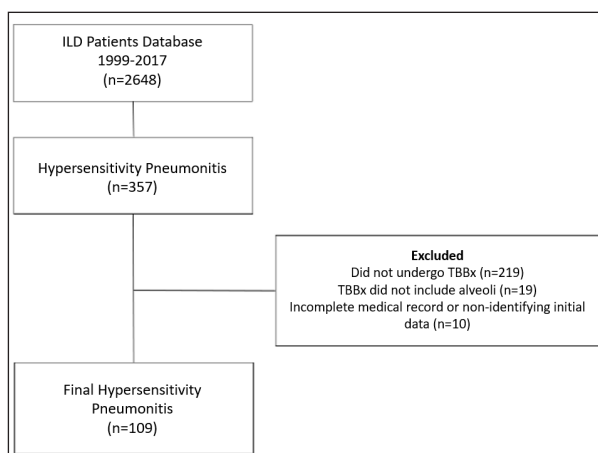
## STATISTICAL ANALYSIS

The baseline characteristics are reported by descriptive statistics using frequencies, means, standard deviations, medians, and interquartile ranges. The normal distribution of variables was tested by the Shapiro-Wilk test and by visual inspection of distribution curves of data. Comparisons between selected groups were performed using Fisher's exact test or Pearson's chi-squared ( $\chi^2$ ) test for categorical variables, Student's t test for continuous variables with normal distribution, and the Mann-Whitney and Kruskal-Wallis tests for continuous variables with non-normal distribution. Values of  $p < 0.05$  were considered significant. Statistical analyses were performed using version 22.0 of the Statistics Package for Social Sciences (SPSS) software.

## RESULTS

The final sample consisted of 109 patients with CHP. Figure 1 shows a general flowchart of the selection of the sample and reasons for exclusions.

All patients fulfilled selected diagnostic criteria for probable HP. Eighty-eight patients (80.7%)



**Figure 1.** Flowchart of the selection of the final series of 109 patients.

had suggestive HRCT findings associated with well-documented exposure. The remaining 21 patients (19.3%) underwent SLB. In 15 patients, classic histological findings were present, and in 6 patients, bronchiolocentric interstitial pneumonia was diagnosed.

The baseline clinical characteristics are shown in Table 1. There was a predominance of female patients, with a mean age of 61.4 years. The main symptoms were, in decreasing order, dyspnea and cough. Wheezing was present in 25% of the patients. The median time from symptom onset to diagnosis was 12 months, with a wide range. Only two patients were smokers at the time of the first evaluation.

Patients who did not undergo TBBx and were excluded from the present series were younger ( $57.2 \pm 14.3$  years vs  $61.4 \pm 12.4$  years,  $p < 0.05$ ), had lower FVC ( $64.9 \pm 19.2\%$  vs  $72.1 \pm 21.4\%$ ,  $p < 0.05$ ) and displayed fibrosis findings more often in HRCT ( $93.3\%$  vs  $69.7\%$ ,  $p < 0.005$ ), including honeycombing, than those who underwent TBBx ( $33.3\%$  vs  $15.6\%$ ,  $p < 0.05$ ).

The causative agents of CHP were identified by clinical history in 108 patients (99.1%). The main agent found was exposure to mold at home, followed by exposure to birds. Several patients had exposure to more than one agent. In the only patient without relevant exposure, the diagnosis was made by typical

**Table 1.** Baseline characteristics of patients with chronic hypersensitivity pneumonitis (n = 109).

Features	
Gender, female/male, n(%)	77(70.6)/32(29.4)
Age (years), $\pm$ SD	61.4 $\pm$ 12.14
Duration of symptoms, in months, median (Q1-Q3)	12 (9, 36)
Dyspnea, n(%)	95(87.1)
Cough, n(%)	71(65.1)
Wheezing, n(%)	22(24.7)
Tobacco status	
Nonsmoking, n(%)	70(64.2)
Former, n(%)	37(33.9)
Smoking, n(%)	2(1.8)
Exposure	
Mold, n(%)	33 (60.5)
Birds, n(%)	53(48.6)
Feather pillows, n(%)	7(6.4)
Others, n(%)	10(9.2)
Not identified, n(%)	1(0.9)

n: number; %: percentage;  $\pm$ : mean; SD: standard deviation; Q1: lower quartile; Q3: upper quartile.

findings in TBBx associated with diffuse centrilobular nodules on HRCT.

Table 2 shows the main HRCT and functional data. The most common tomographic finding was ground glass opacity, in general associated with findings indicative of fibrosis. The mosaic pattern was the second most common HRCT finding. Findings indicative of fibrosis were identified in 69.7% of the patients. Honeycombing was noted in 15.6%.

A median of three fragments (interquartile range 3.0-6.0) was obtained by TBBx. Characteristic findings were observed in 16 patients (14.7%), and supportive findings were seen in 32 patients (29.4%), with a total diagnostic yield of 44,1%. Comparisons were made between the TBBx patterns and the different tomographic patterns identified. The results are shown in Table 3.

Characteristic findings were significantly more common in patients with an absence of data indicative of fibrosis and in the presence of centrilobular nodules. Unlike the results found with characteristic findings on TBBx, supportive findings were more common in the presence of fibrosis.

When comparing the presence of each specific pathological finding in relation to the presence or absence of fibrosis, it was noted that granulomas were more often seen in the absence of fibrosis on HRCT ( $p=0.032$ ) (Table 4).

Differential cytological analysis of BAL fluid was performed in 52 patients. The median value for lymphocyte percentage was 20.0% (interquartile range 11.5%- 29.5%). Twenty-seven patients (51.9%) had a percentage of lymphocytes greater than or equal to 20%, 13 patients (25.0%) greater than or equal to 30%, and 8 patients (15.4%) greater than or equal to 40%. Figure 2 shows that the median lymphocyte count in the BAL fluid was similar in patients with the presence or absence of fibrosis on HRCT (median 19.0% and 21%, respectively,  $p=0.53$ ). There was also no statistically significant difference between the median lymphocyte count and specific TBBx findings (data not shown).

In the 52 patients who underwent both BAL and TBBx, considering BAL fluid  $Ly >20\%$ , 51.9% showed lymphocytosis; this number increased to 59.6% considering characteristic findings on biopsies and to 73.0% when characteristic and supportive findings of TBB were added. Twenty-five patients had  $Ly <20\%$  in BAL fluid. Of these, 4 (16%) had characteristic TBBx findings.

**Table 2.** Tomographic and functional characteristics of patients with chronic hypersensitivity pneumonitis (n = 109).

Features	
Tomographic findings	
Honeycombing, n(%)	17(15.6)
Fibrosis without honeycombing, n(%)	59(54.1)
Ground glass opacity, n(%)	90(82.6)
Ground glass opacity with fibrosis, n(%)	64(58.7)
Ground glass opacity without fibrosis, n(%)	26(23.9)
Fibrosis, n(%)	76(69.7)
Centrilobular nodules, n(%)	36(33.0)
Mosaic attenuation/air trapping, n(%)	67(61.5)
FVC (% predicted), $\pm$ SD, n=87	72.1 $\pm$ 21.4
DLCO (% predicted), $\pm$ SD, n=36	56.9 $\pm$ 19.9
O <sub>2</sub> saturation (%), $\pm$ SD, n= 103	93.9 $\pm$ 3.5

n: number; %: percentage; : mean; SD: standard deviation.

**Table 3.** Findings in transbronchial biopsy and tomographic patterns in patients with chronic hypersensitivity pneumonitis (n=109).

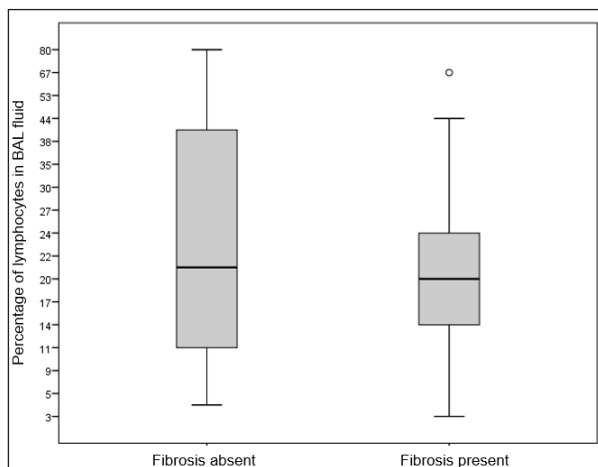
Tomographic pattern	Characteristic findings, n(%)	p value (*)	Supportive findings, n(%)	p value (*)
Honeycombing		0.265		0.996
Present (n= 17)	1(5.9)		5(29.4)	
Absent (n= 92)	15(16.3)		27(29.3)	
Fibrosis without honeycombing		0.467		0.161
Present (n= 59)	6(10.2)		14(23.7)	
Absent (n= 50)	10(20)		18(36.0)	
Any ground glass opacity		0.880		0.153
Present (n= 90)	13(14.4)		29(32.2)	
Absent (n= 19)	3(15.8)		3(15.8)	
Ground glass opacity with fibrosis		<b>0.016</b>		<b>0.002</b>
Present (n= 64)	5(7.8)		26(31.3)	
Absent (n= 45)	11(24.4)		6(13.3)	
Ground glass opacity without fibrosis		<b>0.008</b>		<b>0.022</b>
Present (n= 26)	8(30.7)		3(11.5)	
Absent (n= 83)	8(9.6)		29(10.8)	
Fibrosis		<b>0.014</b>		<b>0.002</b>
Present (n= 76)	7(9.2)		29(38.1)	
Absent (n= 33)	9(27.3)		3(9.1)	
Centrilobular nodules		<b>0.032</b>		0.799
Present (n= 36)	9(25.0)		10(27.8)	
Absent (n= 73)	7(9.6)		22(30.1)	
Mosaic attenuation/air trapping		0.642		0.462
Present (n= 67)	9(13.4)		23(34.3)	
Absent (n= 42)	7(16.6)		9(21.4)	

n: number; %: percentage. \* Pearson's chi-squared test

**Table 4.** Pathological findings in transbronchial biopsy and fibrosis tomographic patterns in patients with chronic hypersensitivity pneumonitis (n=109).

Pathological findings	Present fibrosis, n=7a	Absent fibrosis, n=33	p value (*)
Granulomas, n(%)	4(5.2)	6(18.2)	<b>0.032</b>
Giant cells, n(%)	3(3.9)	3(9.1)	0.279
Peribronchiolar metaplasia, n(%)	12(15.7)	1(3.0)	0.059
Alveolar foamy macrophages, n(%)	9(11.8)	1(3.0)	0.143
Foci of organizing pneumonia, n(%)	9(11.8)	1(3.0)	0.143

n: number; %: percentage. \* Pearson's chi-squared test

**Figure 2.** Box-plot of the distribution of the percentage of bronchoalveolar lavage fluid lymphocytes in patients with chronic hypersensitivity pneumonitis in relation to fibrosis on HRCT (n = 52).

## DISCUSSION

The present retrospective study evaluated the presence of TBBx findings in a series of patients with a final diagnosis of HP. Characteristic findings were significantly more common in the absence of data indicative of fibrosis on HRCT, and supportive findings were more common in the presence of fibrosis.

The population analyzed in this study was predominantly female with a mean age of 61.4 years, with exposure more commonly to molds and birds at home.

The most common tomographic findings were ground glass opacities, findings indicative of fibrosis and mosaic attenuation areas, with a low incidence of honeycombing. These findings were similar to a cohort described by Salisbury et al (16).

The diagnostic yield of TBBx was 44,1%, considering characteristic and supportive findings, but only 14.7% of the cases showed the presence of granulomas or giant cells. These data are lower than those shown in previous studies. Morell et al found granulomas in 7 of 33 patients (21%) with HP secondary to bird exposure (16). A study from the Mayo Clinic found granulomas in more than half of the patients who underwent TBBx; however, 21% of the patients had HP due to hot tub lung, a condition where a higher incidence of granulomas is found (17,18).

The presence of granulomas was more evident in cases without apparent fibrosis on HRCT, which was expected because a granuloma corresponds to an aggregate of inflammatory cells (lymphocytes, plasmocytes and macrophages) (19). With the progression of the inflammatory response, there is a replacement by areas of fibrosis, with a reduction in granuloma burden.

In our study, the presence of data indicative of bronchiolar injury in TBBx was considered to be useful in the diagnosis. One of the pathological findings considered to be supportive was peribronchiolar metaplasia. Fukuoka et al evaluated the presence of peribronchiolar metaplasia as an isolated pathological lesion in idiopathic interstitial pneumonias and showed the presence of diverse tomographic patterns, with an emphasis on mosaic attenuation and air trapping areas, suggesting HP (20). In patients with HP, peribronchiolar metaplasia is common and suggestive of diagnosis (11). In our study, peribronchiolar metaplasia was more evident in patients with signs of fibrosis on HRCT. These data were expected because this finding correlates mainly with signs of fibrosis in tissue samples (11).

In the latest American Thoracic Society (ATS)/ERS guidelines for the diagnosis of IPF, BAL has been recommended in patients with probable, indeterminate or more probable alternative diagnoses of usual interstitial pneumonia on HRCT (21). This recommendation is essential in countries with a high prevalence of HP to evaluate possible increased lymphocytes.

In the present study, percentages of BAL fluid lymphocytes greater than 20% were present in 51.9% of the cases. This value contrasts with older studies in which more intense lymphocytosis was documented; however, in these studies, acute HP, mainly farmer's lung, was included (8). Recent studies, including a meta-analysis, have clearly shown that in CHP, lymphocytes in BAL fluid are in the normal range in a

significant percentage of cases (9, 12). Several cut-offs have been proposed to characterize increased lymphocytes in BAL fluid, with resultant changes in sensitivity for the diagnosis (4,5,6). A study using the cutoff of lymphocytosis of 20% showed that the combination of BAL and TBBx presented a total yield of 58% for the diagnosis of CHP, a similar percentage seen in the present study (12).

We observed no difference in the median percentage of lymphocytes according to the presence or absence of fibrosis on HRCT. Studies are conflicting regarding these data. Sterclova et al. analyzed the BAL fluid of 14 patients with HP and found no difference in lymphocytosis in relation to the type of disease involvement on HRCT (22). Adams et al showed a higher mean BAL fluid lymphocytosis in patients without fibrosis in HRCT (49% vs. 19%) in a series of 53 patients (12).

In contrast to other studies, we identified a possible relevant exposure in almost all cases (6). We ascribe such findings to the use of a systematic protocol for the investigation of ambient and occupational exposures. In Brazil, data have shown that exposure to molds and birds is found in more than 50% of all ILD cases; therefore, the predictive positive value of this finding is low (1).

Several limitations can be identified in our study. Many patients with a final diagnosis of HP were diagnosed without bronchoscopy and were not included in the present series. These patients had more severe disease, as shown by a lower FVC and more fibrosis on HRCT, introducing a selection bias. Because of this, the diagnostic yield of TBBx could be somewhat reduced, but the results would not change significantly.

Due to the long period of inclusion of patients, in several cases, medical notes were lost. Although HRCT was assessed by several specialists by a standardized report, concordance was not estimated, nor were images reviewed. The TBBx samples were evaluated by two independent lung dedicated pathologists of the same institution, with extensive experience in biopsy analysis of ILD, but again, the concordance was not evaluated. Finally, BAL was performed only in a subgroup of patients.

## CONCLUSION

Bronchoscopy has a significant role in the investigation of CHP. TBBx has a greater value in the

nonfibrotic form of disease, but indicative data of bronchiolar injury are common in the fibrotic form of the disease. Increased lymphocytes are not always present, but the combination of increased lymphocytes and TBBx findings increases the possibility of HP diagnosis in a number of patients.

**CONFLICTS OF INTEREST:** Each author declares that he or she has no commercial associations (e.g. consultancies, stock ownership, equity interest, patent/licensing arrangement etc.) that might pose a conflict of interest in connection with the submitted article.

## REFERENCES

- Soares MR, Pereira CAC, Botelho A, Gimenez A, Beraldo B, Ferraz C, et al. Multicenter registry of interstitial lung diseases in Brazil. *ERJ* 2019; 54 (suppl 6); A3634.
- Pereira CA, Gimenez A, Kuranishi L, Storrer K. Chronic hypersensitivity pneumonitis. *J Asthma Allergy*. 2016; 9:171-81.
- De Sadeleer LJ, Hermans F, De Dycker E, Yserbyt J, Verschakelen JA, Verbeke EK, et al. Effects of Corticosteroid Treatment and Antigen Avoidance in a Large Hypersensitivity Pneumonitis Cohort: A Single-Centre Cohort Study. *J Clin Med*. 2018;8(1).
- Salisbury ML, Myers JL, Belloli EA, Kazerooni EA, Martinez FJ, Flaherty KR. Diagnosis and Treatment of Fibrotic Hypersensitivity Pneumonia. Where We Stand and Where We Need to Go. *Am J Respir Crit Care Med*. 2017;196(6):690-9.
- Morisset J, Johannson KA, Jones KD, Wolters PJ, Collard HR, Walsh SLF, et al. Identification of Diagnostic Criteria for Chronic Hypersensitivity Pneumonitis: An International Modified Delphi Survey. *Am J Respir Crit Care Med*. 2017.
- Vasakova M, Morell F, Walsh S, Leslie K, Raghu G. Hypersensitivity Pneumonitis: Perspectives in Diagnosis and Management. *Am J Respir Crit Care Med*. 2017;196(6):680-9.
- Hanak V, Golbin JM, Hartman TE, Ryu JH. High-resolution CT findings of parenchymal fibrosis correlate with prognosis in hypersensitivity pneumonitis. *Chest*. 2008;134(1):133-138.
- Cormier Y, Bélanger J, LeBlanc P, Laviolette M. Bronchoalveolar lavage in farmers' lung disease: diagnostic and physiological significance. *Br J Ind Med*. 1986;43(6):401-5.
- Yang R, Scott J, Moran-Mendoza O. Bronchoalveolar Lavage Differential in Chronic Hypersensitivity Pneumonitis: A Meta-Analysis. *Am J Respir Crit Care Med* 2017;195:A1592.
- Lima MS, Coletta EN, Ferreira RG, Jasinowdolinski D, Arakaki JSO, Rodrigues RC et al. Acute and chronic hypersensitivity pneumonitis: histopathological patterns and survival. *Respir Med*. 2009;103(4):508-515.
- Wright JL, Churg A, Hague CJ, Wong A, Ryerson CJ. Pathologic separation of idiopathic pulmonary fibrosis from fibrotic hypersensitivity pneumonitis. *Mod Pathol*. 2019;10.1038/s41379-019-0389-3. doi:10.1038/s41379-019-0389-3.
- Adams TN, Newton CA, Batra K, Abu-Hijleh M, Barbera T, Torrealba J, et al. Utility of Bronchoalveolar Lavage and Transbronchial Biopsy in Patients with Hypersensitivity Pneumonitis. *Lung*. 2018;196(5):617-22.
- Salisbury ML, Gross BH, Chughtai A, Chughtai A, Sayyoub M, Kazerooni EA, et al. Development and validation of a radiological diagnosis model for hypersensitivity pneumonitis. *Eur Respir J*. 2018;52(2):1800443.
- Silva CI, Müller NL, Lynch DA, et al. Chronic hypersensitivity pneumonitis: differentiation from idiopathic pulmonary fibrosis and non-

- specific interstitial pneumonia by using thin-section CT. *Radiology*. 2008;246(1):288-297.
15. Clinical guidelines and indications for bronchoalveolar lavage (BAL): Report of the European Society of Pneumology Task Group on BAL. *Eur Respir J*. 1990;3(8):937-76.
  16. Morell F, Roger A, Reyes L, Cruz MJ, Murio C, Muñoz X. Bird fancier's lung: a series of 86 patients. *Medicine (Baltimore)*. 2008;87(2):110-30.
  17. Hanak V, Kalra S, Aksamit TR, Hartman TE, Tazelaar HD, Ryu JH. Hot tub lung: presenting features and clinical course of 21 patients. *Respir Med*. 2006;100(4):610-5.
  18. Hanak V, Golbin JM, Ryu JH. Causes and presenting features in 85 consecutive patients with hypersensitivity pneumonitis. *Mayo Clin Proc*. 2007;82(7):812-6.
  19. Barrios RJ. Hypersensitivity pneumonitis: histopathology. *Arch Pathol Lab Med*. 2008;132(2):199-203.
  20. Fukuoka J, Franks TJ, Colby TV, Flaherty KR, Galvin JR, Hayden D, et al. Peribronchiolar metaplasia: a common histologic lesion in diffuse lung disease and a rare cause of interstitial lung disease: clinicopathologic features of 15 cases. *Am J Surg Pathol*. 2005;29(7):948-54.
  21. Raghu G, Remy-Jardin M, Myers JL, Richeldi L, Ryerson CJ, Lederer DJ, et al. Diagnosis of Idiopathic Pulmonary Fibrosis. An Official ATS/ERS/JRS/ALAT Clinical Practice Guideline. *Am J Respir Crit Care Med*. 2018;198(5):e44-e68.
  22. Sterclova M, Vasakova M, Dutka J, Kalanin J. Extrinsic allergic alveolitis: comparative study of the bronchoalveolar lavage profiles and radiological presentation. *Postgrad Med J*. 2006;82(971):598-601.