

The EndoRotor®: endoscopic mucosal resection system for non-thermal and rapid removal of esophageal, gastric, and colonic lesions: initial experience in live animals

Authors

Stephan Hollerbach¹, Axel Wellmann², Peter Meier³, Jeffery Ryan⁴, Ramon Franco⁴, Peter Koehler⁵

Institutions

¹ Department of Gastroenterology, Allgemeines Krankenhaus Celle (AKH), Celle, Germany

² Department of Pathology, Institute of Pathology, Celle, Germany

³ Department of Gastroenterologie, Krankenhaus Henriettenstift, Hannover, Germany

⁴ Interscope Medical, Inc., Worcester, Massachusetts, USA

⁵ Friedrich Loeffler Institut (FLI), Mariensee, Germany

submitted 5. January 2016
accepted after revision
21. February 2016

Bibliography

DOI <http://dx.doi.org/10.1055/s-0042-105207>
Published online: 30.3.2016
Endoscopy International Open 2016; 04: E475–E479
© Georg Thieme Verlag KG
Stuttgart · New York
E-ISSN 2196-9736

Corresponding author Stephan Hollerbach, MD

Department of
Gastroenterology
Allgemeines Krankenhaus Celle
(AKH)
Siemensplatz 4
Celle 29223
Germany
Fax: +49-5141-721209
cshollerbach@t-online.de

Background and study aims: The EndoRotor® is a novel, non-thermal, automated mechanical endoscopic resection system designed to remove benign mucosal neoplastic tissue throughout the gastrointestinal tract. It uses suction pressure to pull in mucosa and rapidly and precisely cut it while automatically transporting the samples to a collection trap for later histologic evaluation.

Patients and methods: To study the technical properties and therapeutic potential of this new tool, we performed multiple upper and lower gastrointestinal endoscopic mucosal resections in three healthy live pigs. Animals were anesthetized and kept artificially ventilated while two physicians performed multiple qualitative mucosal resections on various sites of the pigs' esophagus, stomach, duodenum, and colon.

Results: Rapid resection of flat and slightly elevated mucosa up to several centimeters in size/diameter was performed. No major bleeding occurred

during and after resections. When used properly, no gastrointestinal wall perforations occurred during superficial resections. Perforations in the colon were only observed when the device was deliberately pushed against deeper sub-mucosal layers or when exceptional force was applied to penetrate the gastrointestinal wall. Histologic specimens showed complete mucosal removal at resection sites. The flexible catheter could be moved and directed towards most of the areas of interest in the gastrointestinal tract.

Conclusion: The EndoRotor rapidly and easily resects flat and slightly elevated gastrointestinal mucosa with a short learning curve. Future studies in humans should be performed to prove its ability for large-area mucosal resections in benign conditions such as laterally spreading adenomas in the colon, or Barrett's mucosa in the distal esophagus.

Introduction

Colonoscopy with adenomatous polyp removal has become the standard of care worldwide for the prevention of colon cancer in humans and has been shown to be effective [1]. In addition, interventional endoscopy with tissue removal is also used in other populations with premalignant conditions such as Barrett's esophagus and gastric or duodenal adenomas to avoid further growth and subsequent development of cancer at various sites in the gastrointestinal tract. While various techniques and accessories already exist for the removal of polyps and mucosal lesions, there is a clear need for novel devices that allow for rapid, precise, and safe mucosal resections, particularly in laterally spreading flat adenomas and areas without gross mucosal lesions such as non-dysplastic or dysplastic Barrett's esophagus. The EndoRotor® device (Interscope Medical, Inc., Worcester, Massachusetts, United States) is a no-

vel automated mechanical endoscopic resection system for use in the gastrointestinal tract for removal of benign neoplastic or pre-neoplastic tissue. The EndoRotor® has a fixed outer cannula with a hollow inner cannula that rotates at either 1000 or 1700 revolutions per minute (rpm). Both the outer and inner cannulas have an opening (the orifice) that allows the suction within the inner cannula to pull tissue into the device where the rotating inner cannula cuts it. The suction that is constantly being applied transports the tissue to the tissue collection trap for pathologic evaluation later. The device is depicted in **Fig. 1**. There are several benefits from using an automated mechanical resection device such as the EndoRotor®. Because no heat or ablation of the specimen is necessary, there is no cauterization artifact in the specimen. The entire thickness of mucosa can be removed because of the differential viscoelastic properties of the mucosal layer versus the muscularis layer. When the suction pulls

License terms





Fig. 1 EndoRotor® catheter (close up) deployed in 3.2-mm colonoscope working channel with electric console unit in background

on tissue, it pulls in the mucosa much more easily than muscle, making mucosal resection with preservation of the muscle layer possible. It allows the user to precisely define the area to be removed and allows for very rapid resection because it resects 2–4 mm of tissue per second with each rotation of the inner cannula (1000–1700 rpm).

Methods

The aim of the study was to determine the technical feasibility of multiple mucosal gastrointestinal resections by using the novel EndoRotor® device in healthy live anesthetized pigs. The domestic pig was chosen since it features organ dimensions comparable to human anatomy. Multiple clinical performance parameters of the EndoRotor® device were recorded, namely the rotation speed setting (low or high), the size of resection area, and speed of resection, when used to remove mucosa at various sites during upper endoscopic resections in the esophagus, stomach, and proximal duodenum, as well as lower endoscopic resections in the colon.

Animal preparation and care

In vivo experiments were conducted using porcine specimens under general endotracheal anesthesia. All animals were euthanized to receive necropsy and post-resection histologic review. All interventions were done according to recommended guidelines with regard to animal care [2]. Before the study, animal experiments had been approved by the Lower Saxony State Office for Consumer Protection and Food Safety, Oldenburg, Germany (Animal experiments approval number: 33.14-42502-04-14/1672). All experiments were carried out at animal facilities of the Friedrich-Loeffler-Institute at Mariensee, Germany.

A total of five, 4-month-old female German Landrace pigs with a median live weight of 50 kg were included in the study. The pigs were fed only whole milk (5 L/animal and day) and water (*ad libitum*) for 5 days and then fasted overnight before intervention. Animals received Ketamine 10% (20.0 mg/kg body weight), Stresnil 40 mg (2.0 mg/kg body weight), Xylarium 2% (2.0 mg/kg body weight) and Atropine sulfate 1% (0.10 mg/kg body weight) *i.m.* as a premedication mix. After that, the animals were endotracheally intubated with the use of Lidocaine spray. Intubation anesthesia was maintained with Isoflurane (2.0–3.0%) and oxygen (2.0 L/min). During general anesthesia, the animals received intravenous fluid (Ringer's acetate). In addition, all animals received suf-

ficient analgesia with Novacen 500 mg (30 mg/kg body weight) before the interventions started. Preoperative work-up and bowel preparation were carried out as per standard endoscopic colorectal surgery with a preoperative bowel enema. During endoscopy, the animals were placed in a supine position. After the endoscopic procedures had been completed, the animals were euthanized under anesthesia with 10.0 mL of T 61.

Endoscopic procedures

Mucosal resections were performed in the esophagus, stomach, duodenum, and colon using standard video endoscopes (Karl Storz GmbH & Co. KG, Tuttlingen, Germany) and the through-the-scope EndoRotor® Mucosal Resection System. The dual-cannula system is designed to pass through an endoscope working channel at least 3.2 mm in diameter. The inner concentric cutter rotates and under vacuum power performs a resection of tissue at either 1000 or 1700 rpm.

Under direct visualization, endoscopists inserted a dedicated video endoscope into the animal's rectum and advanced it into the colon for treatments, and/or into the mouth and advanced it into the esophagus, stomach, and duodenum for further treatments. In each case, the test device was used to perform a series of tissue resections.

Because the pigs' gastrointestinal tracts did not contain pathology, the targets of resection were delineated through the use of a submucosal injection with indigo carmine. This caused the area to turn blue and balloon out slightly and allowed the endoscopist to see the target resection area. Unfortunately, the tumescence did not last long, and the fluid escaped away causing the mucosa to lie flat again. Sometimes the endoscopists chose to re-inject the area, but in other cases, they felt that the blue staining was sufficient to know how much more to resect.

Resections were performed using various techniques, but always adhering to the simple rule that once suction is activated, the device must be kept moving and must never stay in one location for more than 1–2 seconds to avoid deep resections. During our initial experiments, we did not systematically analyze any possible outcome differences that may occur between lower or higher rotation speed of the experimental device. The EndoRotor® does not cut tissue when the motor is turned on until the suction pedal is depressed. As a safety measure, the suction is active only as long as the orange foot-pedal is depressed. The endoscopists were able to resect individual spots (approximately 1–2 mm²), straight lines of mucosa ranging from 5 mm to 15 mm, and were able to combine these together to remove even larger patches of mucosa. Another technique was to use the EndoRotor® analogous to a dissecting knife to delineate the area of resection with the EndoRotor® and then remove the mucosa within this perimeter by sweeping from left-to-right and from distal-to-proximal. Care was always taken to not attempt resection in areas that had been denuded of mucosa to prevent perforations.

Physicians were able to determine optimal resection techniques using the system, which varied by tissue morphology and type under the technical guidance of the developers (JR, RF).

Histopathology was performed by an experienced pathologist (AW). Autopsies were performed and the gastrointestinal tract resected. Organs where the mucosa was resected were removed and macroscopically evaluated. Resected areas were formalin-fixed for 24 hours. Paraffin embedded tissue was cut routinely and H&E stained.

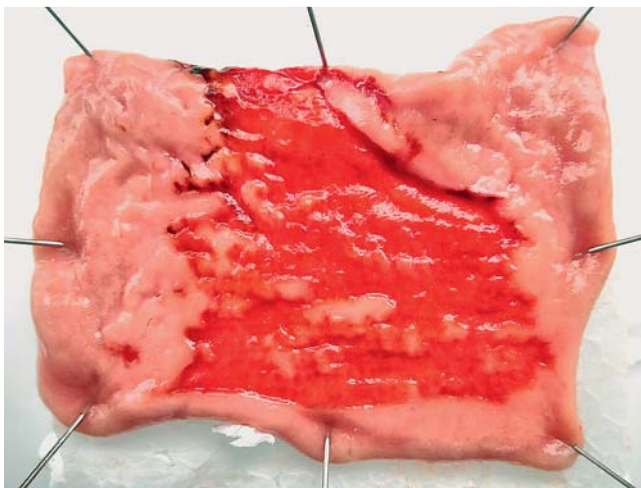


Fig. 2 Colonic resection demonstrating ability to remove large mucosal area while maintaining muscularis and serosa (some short strips of mucosa are still visible on the resection site to demonstrate the difference between fully and partially resected mucosal areas)

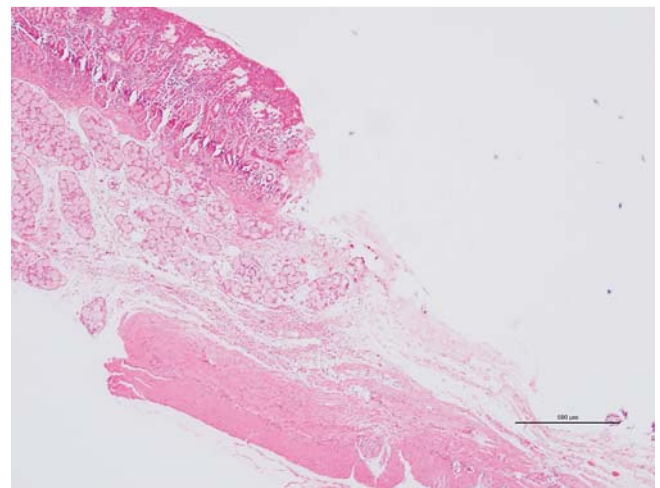


Fig. 3 Histopathologic view of duodenal resection demonstrating intact muscularis and serosa post resection

Additional information

Animal experiment funding was provided by Interscope Medical, Inc. This covered the use of animal facilities, technical supplies, workload of local veterinarians, and equipment purchase or rentals. Participating physicians did not receive any financial compensation, travel compensation, meals, funding, or any other additional provisions.

Results

We performed multiple endoscopic resections in anesthetized animals. For most resections of mucosal tissue, we injected 1.5–8 cc of normal saline 0.9% mixed with droplets of indigo carmine solution and epinephrine (1:100 000) to elevate/lift up some mucosa in the exposed gastrointestinal tract ranging from 1.0 to 5.0 cm in size (approximately ranging from 15 to 70 mm²). In the majority of resections, we were able to resect all of the mucosa that covered the lifted/designated resection area. **Fig. 2** depicts an animal case in which we left some small strips of mucosa to illustrate differences between resected and unresected areas. In the distal esophagus, resections could be performed circumferentially. In the stomach, an angle of inclination of 30–40° achieves optimal resections whereas 90° can present greater challenges to the operator and the system. Stomach antrum and body resections can follow a straight line, that can be expanded. However, due to some limitations, not every region in the stomach was readily accessible for the catheter, at least not when the device had to be held out in a straight line. In the duodenum and colon, resections could be performed when the instrument was

held forward in a straight line and orientated towards the 6 o'clock or 12 o'clock positions of the intestinal lumen. The results of these qualitative resection experiments are summarized in **Table 1**.

Histopathology analysis demonstrated that the mucosal layer covering the dedicated resection site in all intestinal organs examined was almost entirely removed by repeated resections using the EndoRotor device (**Fig. 3**). In most specimens, repeated resections removed the entire mucosal layer and most of the underlying submucosal tissue, as depicted in the figures. In one case (esophagus) without prior injection, the resection was technically difficult and only small tissue fragments could be sampled that did not allow full removal of the target lesion area. Hence, we found that injection with building of small mucosal “blebs” was helpful for this technique at most resection sites.

Regarding the safety of the new device, no interventions were required in the esophagus, the stomach, or the duodenum. There were no serious complications or adverse effects during resections in these organs. Minimal bleeding occurred at resection sites but ceased after 1.5–3 minutes of observation. The highest amount of blood loss did not exceed more than 10–15 cc of blood. No additional endoscopic interventions for bleeding were required.

No perforations occurred during “normal” resections. Two perforations were deliberately created during extended safety experiments; they were both clipped closed immediately. One perforation occurred in an area denuded of mucosa when an attempt to remove the deeper submucosal layers was attempted. The second perforation was performed deliberately since we wanted to find out how much pressure and cutting was required until the proper muscle layer was breached.

| | Esophagus | Stomach | Duodenum | Colon |
|--|-----------|---------|----------|-------|
| Resections per organ | 4 | 9 | 2 | 10 |
| Submucosal injections | 3 | 8 | 2 | 9 |
| Areal range of resections, mm ² | 10–30 | 15–50 | 10–25 | 15–30 |
| Adverse events | 0 | 0 | 0 | 2* |

Table 1 Overview of all EndoRotor resections in the gastrointestinal tract.

* Two perforations occurred—for details, see text. These serious adverse events only occurred during experiments that were performed deliberately to test the limits of the gastrointestinal wall when excessive force was applied.

With respect to speed of resection, the EndoRotor® was significantly faster than current standard techniques, requiring only from several seconds up to 5 minutes to resect the mucosal areas of interest ranging from 5 mm to 70 mm × 70 mm, respectively. Because pathologic samples were simultaneously collected during EndoRotor® operation and automatically transported back to the collection trap, eliminating the need to re-insert instruments to collect samples, this reduced resection time.

We found the submucosal injections were beneficial in all intestinal resection sites to allow us to better define the submucosal space, lift the mucosa, and avoid injury to the deeper muscle layers. While this was helpful, it was not always necessary and the need to inject or not should be further evaluated in humans. Creating a circumferential incision followed by resecting the tissue within its borders allowed the physicians to complete the resection quickly, safely, and effectively. Scope optics was critical to assess resection with each pass and ensure safety.

Discussion

Removal of benign neoplastic and pre-neoplastic mucosal tissue in the upper and lower gastrointestinal tract has emerged as one of the most frequent interventional procedures in clinical gastroenterology and gastrointestinal endoscopy for prevention of cancer [1, 3]. Lesions include flat and laterally spreading colonic, gastric, and duodenal neoplastic polyps. Several previously evaluated techniques exist for treatment of these conditions including snare polypectomy, endoscopic mucosal resection (EMR), and endoscopic submucosal dissection (ESD). For pre-neoplastic lesions such as Barrett's mucosa, other techniques have been adopted such as radiofrequency ablation (RFA), cryoablation, and hybrid argon plasma coagulation (hybrid APC). However, it has been shown recently that EMR is frequently associated with local recurrence of adenomatous polyps of the colon [3], while ESD, as a complex technique, is highly time-consuming, and has quite a cumbersome learning curve. RFA is technically easy to use but expensive and not widely available. Most of these older techniques use thermal energy that is derived from high-frequency electric current, thus harboring a small but significant risk of thermal injury to deeper gastrointestinal wall layers such as the muscularis. Such injuries may result in immediate or delayed gastrointestinal wall perforations or stenosis, as reported in several previous clinical endoscopy studies. To avoid such small, albeit relevant risks, the EndoRotor® mechanically resects mucosa without the need for heating the tissue. It was demonstrated that lack of involvement of resections with the muscularis resulted in minimal bleeding demonstrating a potential further benefit.

Since time is of the essence in clinical endoscopy, there is a clear need to shorten the length of interventions, in particular, during endoscopic resections of flat lesions arising in the colon, the duodenum, and the stomach. Ideally, the resection technique would "normalize" the time it takes to remove lesions of similar size, and close the time gap between what it takes experts and novices to complete the resection. There is a need for novel devices that allow for rapid, precise, and safe mucosal resections, particularly in laterally spreading flat adenomas in the colon and areas without gross mucosal lesions such as non-dysplastic or dysplastic Barrett's esophagus.

In the present study, we tested the novel rotating and cutting EndoRotor® device under experimental conditions in healthy live pigs. To our knowledge, this is the first series published in the

medical literature. Our preliminary qualitative results in healthy animals demonstrate the feasibility, safety, and capability of the novel instrument to quickly remove superficial mucosa while the resected specimens are simultaneously delivered and stored within a dedicated specimen container for subsequent histopathologic analysis. From our present study, we can summarize some important technical aspects.

1. Submucosal injection with dye assists in resection of mucosa. In one esophageal resection without prior injection, the resection was technically difficult and only small tissue fragments were sampled that did not allow for full removal of the target lesion area. Injection with creation of small mucosal "blebs" appears to be helpful for mucosal resection in the esophagus. For future studies, we recommend prior injection with epinephrine to reduce blood flow at the resection site.
2. Circumferential incisions allow complete removal of the target area. Using the EndoRotor® to create peripheral incisions where no natural markers are present helps to improve the approach to the target area. It makes the resection easier and potentially safer by freeing up the attachments of the "mucosal island" from the peripheral mucosa.
3. The speed settings can be altered and offer different results. Using a low rotor speed without injection can be helpful – a finding that should be investigated by further studies. Low speed also offers larger specimens compared to high speed. We felt that high speed sometimes offered more control in the ability to resect a specific portion of mucosa. However, during our initial experiments, we did not systematically analyze any possible outcome differences that may occur between lower or higher rotation speeds of the experimental device. This issue should therefore be systematically assessed during the next set of studies with the EndoRotor® mucosectomy device in the near future.
4. The angle of attack is important. An angle of inclination of 30–40° achieves optimal resections, whereas 90° can present challenges to the operator and the system. Antrum and corpus resections in the stomach can follow a straight line which can be expanded.

Conclusion

We conclude from this experience in healthy animals that the EndoRotor® has the potential to facilitate rapid and safe resections of relatively large mucosal areas in various parts of the gastrointestinal tract. We feel these findings should be assessed in future studies in humans. Systematic studies should be conducted in the near future using the EndoRotor® device in humans including quantitative measurements of resected lesions such as lesion diameter, volume, and head-to-head comparisons with competing techniques (i.e., EMR or ESD). The full technical and clinical potential of the device remains to be evaluated, particularly in laterally spreading flat colon adenomas and other precancerous conditions, as discussed above.

In addition, the device demonstrated some capability to "denude" larger areas of mucosa for possible indications in the future such as laterally spreading flat stomach or duodenal adenomas – and (perhaps) for larger circumferential duodenal mucosal resections including novel interventions such as diabetes therapy.

Competing interests: None

Acknowledgments



The authors would like to express their special gratitude to the specialized and highly skilled animal care team at the Mariensee facility in Hannover, Germany.

References

- 1 Brenner H, Altenhofen L, Kretschmann J et al. Trends in adenoma detection rates during the first 10 years of the German Screening Colonoscopy Program. *Gastroenterology* 2015; 149: 356–366
- 2 United States Code. Animal Welfare Act. Title 7 – Agriculture. Chapter 54 – Transportation, Sale, and Handling of Certain Animals; Sections 2131–2159
- 3 Pohl H, Srivastava A, Bensen SP et al. Incomplete polyp resection during colonoscopy – results of the Complete Adenoma Resection (CARE) study. *Gastroenterology* 2013; 144: 74–80