

Comparison of Roll Stitch Technique and Core Suture Technique for Extensor Tendon Repair at the Metacarpophalangeal Joint level

Hamid Namazi,^{1,*} Kamran Mozaffarian,¹ and Mohammad Reza Golmakani¹

¹Bone and Joint Research Center, Shiraz University of Medical Sciences, Shiraz, IR Iran

*Corresponding author: Hamid Namazi, Bone and Joint Research Center, Shiraz University of Medical Sciences, Shiraz, IR Iran. Tel/Fax: +98-7136246093, E-mail: Namazih@sums.ac.ir

Received 2014 October 18; Revised 2014 December 18; Accepted 2015 January 4.

Abstract

Background: Proper suturing technique is needed to ensure good outcome in extensor tendon surgery. Different techniques have been reported for the repair of extensor tendon injuries at the level of the metacarpophalangeal joint (MCPJ). These reports were in vitro studies on cadaver models. Repair techniques must be clinically tested, to determine results.

Objectives: The purpose of this in vivo study was to compare results of extensor tendon repair, using roll stitch and core suture techniques.

Patients and Methods: Forty two fingers, in 38 patients (aged 15- 45 years), with simple complete extensor tendon injuries in the MCPJ area, were identified and operated by a single surgeon. The patients were divided into two groups, according to the technique used for tendon repair. The first group consisted of 21 digits, in 19 patients, who were repaired with roll stitch technique, while the second group consisted of 21 digits, in 19 patients, who were repaired with core suture technique. The same splint and rehabilitation regimen (early passive range of motion) were given to all patients. The splints were removed at 6 weeks after surgery and range of motion of the operated fingers was measured and compared to uninjured hands, after 12 weeks.

Results: Five patients were lost to follow up or excluded from the study. There was no rupture of the repaired tendons in the groups. There was no statistically significant difference in mean MCPJ flexion, proximal interphalangeal joint (PIPJ) flexion, distal interphalangeal joint (DIPJ) flexion and total range of motion of the fingers, between the two groups. However, extension lag was significantly more common in the second group (11 of 19 digits) compared the first group (four of 17 digits).

Conclusions: Roll stitch technique had superior outcome compared to the modified Kessler technique, when performed in the MCPJ area. Level of evidence: Therapeutic (Level III)

Keywords: Metacarpophalangeal Joint, Sutures, Tendon Injuries

1. Background

Although extensor tendon injuries are common injuries, relatively little attention has been paid to this subject and very little works has undertaken regarding the proper suturing technique and clinical outcome. Treatment of extensor tendon injuries is particularly difficult for surgeons, and inappropriate treatment can cause severe disability for the patient. Often, these injuries are also more difficult to treat than flexor tendon injuries, owing to several issues specific to extensor tendons. Extensor tendons have a thinner and flatter profile, in comparison to flexor tendons, as well as being in very close proximity to bony structures. This leaves them highly susceptible to adhesions and shortening, which can severely decrease the range of motion of the joints and their function. The ideal suturing technique should allow easy tendon gliding, cause minimal adhesion and shortening, and be simple to perform, in addition to be strong enough to allow early motion. Injuries at the level of the metacarpophalangeal joint (MCPJ) can be repaired using core suture; however, it has been suggested that, besides causing tendon shortening, with resultant decrease range

of motion, the retained suture materials also tend to cause more inflammatory reactions, over joints (1, 2).

To our knowledge, there are no prospective randomized trials of repair techniques in the literature, for extensor tendon lacerations in the MCPJ area.

Most published reports in the literature were in vitro in cadaver models (3-5). Nevertheless, making a definite decision about the significance of observed differences between repair techniques, by clinical testing, is required to determine the results.

2. Objectives

This prospective study was designed to evaluate the clinical outcome of the roll stitch technique and core suture technique for extensor lacerations in the MCPJ area.

3. Patients and Methods

Over a 15 month period, the patients with simple complete extensor tendon laceration in the MCPJ area were

studied. The patients were operated by a single surgeon, with one of two randomly assigned repairing techniques: roll stitch or core suture.

3.1. Inclusion Criteria

The patients were selected with ages of 15 - 45 years, who had simple complete extensor tendon lacerations, in the MCPJ area. The injured fingers were normal before injury.

3.2. Exclusion Criteria

The patients with partial laceration, crushed injury, segmental loss of tendon, associated flexor tendon injury, and associated fractures or joints injuries of the wrist and hand were excluded from the study.

3.3. Surgical Techniques

3.3.1. Roll Stitch

In this technique, the suture passes through the skin to the divided tendon and through the proximal segment of the tendon, near its margin, from superficial to deep; then, it passes through the deep surface of the distal segment, to its superficial surface. Afterwards, it passes proximally and through the opposite margin of the proximal cut end and out through the skin, on the opposite side of the tendon, from which it was introduced. Finally, it is stitched to a button (Figures 1 and 2) (1).

3.3.2. Core Suture (Modified Kessler)

The needle passes into the cut surface of one side of the divided tendon and exits on its surface. Then, the suture passes transversely and exits on the opposite side; The needle then passes through the cut surface, into the other side of the divided tendon, and then out and transversely again, with another locking maneuver to allow passage of the suture through the cut surface. The knot is tied after sliding the tendon on the suture, to allow approximation of the cut surfaces (Figure 3) (1).

Forty two fingers (in 38 patients) with extensor tendon injury in the MCPJ area were identified and primary repair was performed, within the first 2 days. The patients were classified into two groups. Group one consisted of 21 digits in 19 patients, which were repaired with roll stitch technique, while group two consisted of 21 digits, in 19 patients, repaired with core suture technique. The patients underwent Bier's block and then tendons were repaired with 4 - 0 nylon. The skin was closed with 3 - 0 nylon, via simple interrupted suturing technique. The study was approved by our institution review board, and all patients gave informed consent to be included in the study. This study had ethical approval.

3.4. Postoperative Treatment

At the end of the surgery a non-removable splint was applied to all patients. The hand was then immobilized with

the wrist, at about 45 degrees extension, fingers in full extension and the MCPJ in about 90 degrees flexed position. The plaster splint was worn continuously, for 6 weeks, during which the patients were advised to exercise within the slab. The splint was removed at 6 weeks after surgery. Afterwards, all patients were started on active unrestricted range of motion exercise of the fingers. Removal of roll stitch suture was done 6 weeks after surgery.

3.5. Patient Assessment

All the patients were assessed by the primary surgeon, at 12 weeks after surgery. Range of motion of the MCP and interphalangeal (IP) joints of the operated fingers were measured, using a goniometer. Also, loss of flexion and extension lag was recorded in degrees. The range of motion of the uninjured hand was also measured, for comparison. Total range of motion for each finger was calculated according to the formula used by Strickland and Glogovac, for the grading of digital function (6):

$$(1) \quad \text{Total range of motion} = \frac{[\text{MCP flexion} + \text{PIP flexion} + \text{DIP flexion}] - [\text{MCP extension lag} + \text{PIP extension lag} + \text{DIP extension lag}]}{\text{the value of uninjured hand} \times 100}$$

Abbreviations: DIP, distal interphalangeal; MCP, metacarpophalangeal; PIP, proximal interphalangeal. Strickland-Glogovac formula for classification of results is detailed in Table 1. Also, Miller's criteria for assessing the result of extensor tendon repair were used (Table 2) (7).

The data were entered using SPSS 15.0 version (SPSS Inc. Chicago, IL, USA). Statistical comparison of the clinical result from two groups was carried out using t-test and chi-square test. P Value < 0.05 was considered to be statistically significant.

4. Results

Totally, 33 patients with 36 tendon injuries were treated. Group one consisted of 17 digits in 15 patients, and all the patients were male, with an average age of 23.8 years (range 15 - 37), who were treated with roll stitch technique. Group two consisted of 19 digits, in 18 patients. Sixteen patients were male (89%) and two females (11%), with an average age of 22.1 years (range 15 - 41) who had been treated with core suture technique. In both groups, no local wound complications including deep or superficial infection or skin irritation, were seen.

In the first group, full extension was achieved in 13 of 17 digits (76.5%), with an extension lag present in four digits (23.5%). There was an extension lag of five degrees in two digits and 10 degrees in two other digits. In the second group, full extension was achieved in eight of 19 digits (42%). Extension lag occurred in 11 digits (58%).

Extension lag was more common in the second group and was statistically significant (chi square test, P < 0.05). The mean for MCP flexion, PIP flexion, DIP flexion and total range of motion were not statistically significant, between the two groups. The results are summarized in Table 3.

The overall results, according to Miller's rating system, are listed in Table 4. However, functional evaluation using Strickland-Glogovac's classification yielded excellent results, in both group. There was no rupture of the repaired extensor tendons in both groups.

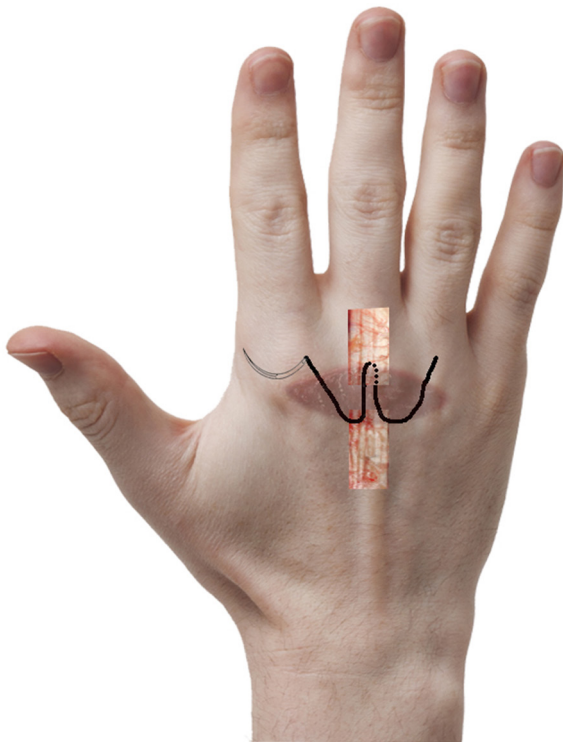


Figure 1. Roll Stitch Suture

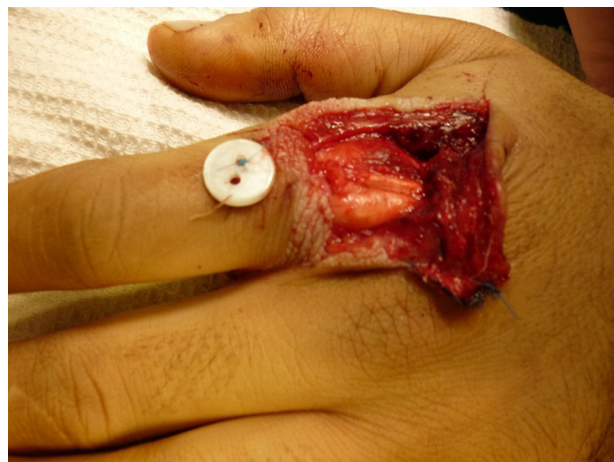

Figure 2. Intraoperative Photography of Roll Stitch Suture

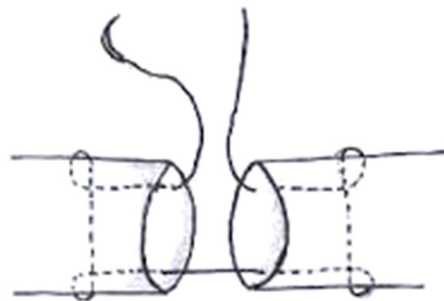


Figure 3. Core Suture

Table 1. Strickland-Glogovac Classification

Grade	Normal Total Range of Motion ^a
Excellent	85 - 100
Good	70 - 84
Fair	50 - 69
Poor	0 - 49

^aValues units are %.

Table 2. Miller's Criteria

Results	Total Extension lag ^a	Total Flexion Loss ^a
Excellent	0	0
Good	≤ 10	≤ 20
Fair	11 - 45	21 - 45
Poor	≥ 45	≥ 45

^aValues units are degree.

Table 3. Summary of Results

Results	Group 1 (Roll Stitch)	Group 2 (Core Suture)	P
Number of digits	17	19	NA
Age, y ^a	23.8 (15 - 37)	22.1 (15 - 41)	NA
Male/female	15/0	16/2	NA
Extension lag, cases ^b	4 (23.5%)	11 (58%)	< .05
flexion loss, deg ^a	11 (0 - 30)	13.5 (0 - 22)	> .05
total range of motion, % ^a	95 (87 - 100)	93 (87 - 98)	> .05

Abbreviation: NA: not available.

^aValues are presented as mean (range).

^bValues are presented as No. (%).

Table 4. Results According to Miller's Classification^a

Results	Group 1 (roll stitch)	Group 2 (core suture)
Excellent	1 (6)	NA
Good	15 (88)	17 (89.5)
Fair	1 (6)	2 (10.5)
Poor	NA	NA

Abbreviation: NA: not available.

^aValues are presented as No. (%).

5. Discussion

Although extensor tendons are easy to expose, they can be difficult to handle and suture well, because of their thin, flat morphology, which also cause marked tendency to constriction during repair resulting in shortening. This shortening results in restriction of MCP and PIP joints motion. Tendon shortening and resultant loss of MCP and PIP flexion were also accompanied by an increase in the force required to obtain maximum flexion, which may contribute to scar elongation and resultant extensor lag. Also, adhesion formation and suturing technique weakness, with resultant tendency to gap formation, can lead to extension lag (8, 9).

There is little information available, relative to extensor tendon repair, especially those involving MCPJ area. There has not been any report comparing roll stitch and core suture techniques. Most published reports, in the literature, were in vitro studies that evaluated the biomechanical properties of other different suturing techniques, in cadaver models. Although biomechanical measurements are an initial way of assessing a tendon repair, they do not take into account the healing of the tendon, as a factor in ultimate strength, in each technique, and do not address the effect of each technique on adhesion formation and ultimate range of motion, with other elements resulting in the overall clinical acceptance or rejection of the respective technique. Therefore, we designed this clinical study to evaluate extensor suturing techniques, in a physiologic state.

We have tried to maximize the specificity and quality of this study, by including only cases with extensor tendon cut, at the level of the MCPJ area, without associated inju-

ries. In addition, all repairs and final examinations were performed by one surgeon and the same post-operative rehabilitation was used for patients to exclude interobserver error.

With the exception of several patients (one in group one and two in group two), with fair outcome, all the repairs had achieved good outcome, according to Miller's rating system and there was no rerupture of repaired tendons, in both groups. The incidence of extension lag was significantly higher in the second group, who had been treated with a modified Kessler technique. The best explanation is retention of suture material in the modified Kessler technique. Retained suture material may cause irritation of adjacent joint capsule and soft tissue, which results in formation of adhesion that restricts finger motion, leading to loss of flexion and extension lag. Also, intratendinous knotting increases the bulk of tendon that may reduce tendon gliding, predisposing to adhesion formation. In addition, it had technical difficulty because of thin flat shape of extensor tendon, with small cross sectional area that may not preclude placing suture in the tendon core. Therefore, besides insufficient grasp of tendon material, to gain resistance against gaping, during early range of motion, core suture technique can also cause tendon constriction, with resultant shortening.

Tendon shortening and resultant flexion loss, leads to increase of the required force for flexion that may produce scar elongation and subsequent extension lag.

The superior results of roll stitch technique may also be partially attributable to the fixing of tendon ends to the

skin, by knot suture ends over a button, on the overlying skin, that can prevent tendon repair from gaping and rupture, with a mechanism similar to tenodesis. In addition, roll stitch technique had the advantages of being simple, minimal handling of tendon and shorter operation time. Its special design permits total removal of suture material later which prevents irritation and adhesion formation.

The results of our study reinforced several findings, demonstrated in biomechanical cadaveric reports. Newport and Williams (10) showed that extensor tendon suturing with modified Kessler technique can produce an average 6 mm shortening, which corresponded to an 18 degree loss of flexion at the MCPJ. Besides resulting in flexion loss, tendon shortening, leads to increase in the force required to obtain maximum flexion that may contribute to scar elongation and resultant extension lag. Also, Woo et al. (11), in a biomechanical study revealed that modified Kessler technique can cause 1.9 to 2.4 millimeter tendon shortening.

Several conclusions can be drawn from our study:

1- Roll stitch technique had clinical and practical advantages compared to modified Kessler technique, and is recommended for extensor tendon injury in MCPJ area and can be considered safe and reliable.

2- Extensor tendon repair with modified Kessler technique, had a significant problem with respect to extension lag, when performed in the MCPJ area. Although previous studies have shown that this technique had adequate strength, when performed on flexor tendon or other zone of extensor tendon, it should not be used for MCPJ area depending only on these results.

3- Uncomplicated simple MCPJ area extensor tendon injury can achieved good results in most cases following surgical repair. However, patients should be advised that a slight extensor lag may persist and full flexion may not be achieved despite seemingly successful treatment.

It is believed that this attempt will provide a new insight into extensor suturing technique and stimulate a multiplicity of later investigations on the utility of roll stitch technique in MCPJ area, leading to provision of better treatment for patients suffering from this condition.

Acknowledgments

The present article was extracted from the thesis writ-

ten by Mohammad Reza Golmakani and was financially supported by Shiraz university of medical sciences, Shiraz, Iran. This work has been accomplished in collaboration with the bone and joint research center, Shiraz university of medical sciences, Shiraz, Iran.

Footnotes

Authors' Contribution:The authors are responsible for the entire study.

Funding/Support:This work was financially supported by Shiraz university of medical sciences, Shiraz, Iran.

References

1. Wright P. Flexor and extensor tendon injuries . In: Canale ST, editor. *Campbell's Operative Orthopaedics*. 12th ed. St. Louis: Mosby; 2013.
2. Strauch RJ. Extensor tendon injuries . In: Kozin SH, Pederson WC, Hotchkiss RN, Wolf SW editors. *Green's Operative Hand surgery*. 6th ed. Churchill: Livingstone; 2011. pp. 159-88.
3. Chung KC, Jun BJ, McGarry MH, Lee TQ. The effect of the number of cross-stitches on the biomechanical properties of the modified becker extensor tendon repair. *J Hand Surg Am*. 2012;**37**(2):231-6. doi: 10.1016/j.jhsa.2011.10.004. [PubMed: 22119602]
4. Lee SK, Dubey A, Kim BH, Zingman A, Landa J, Paksima N. A biomechanical study of extensor tendon repair methods: introduction to the running-interlocking horizontal mattress extensor tendon repair technique. *J Hand Surg Am*. 2010;**35**(1):19-23. doi: 10.1016/j.jhsa.2009.09.011. [PubMed: 20117304]
5. Kochevar A, Rayan G, Angel M. Extensor tendon reconstruction for zones II and IV using local tendon flap: a cadaver study. *J Hand Surg Am*. 2009;**34**(7):1269-75. doi: 10.1016/j.jhsa.2009.04.009. [PubMed: 19501475]
6. Bunata RE. Primary pulley enlargement in zone 2 by incision and repair with an extensor retinaculum graft. *J Hand Surg Am*. 2010;**35**(5):785-90. doi: 10.1016/j.jhsa.2010.01.032. [PubMed: 20378274]
7. Karabeg R, Arslanagic S, Jakirlic M, Dujso V, Obradovic G. Results of primary repairing of hand extensor tendons injuries using surgical treatment. *Med Arch*. 2013;**67**(3):192-4. [PubMed: 23848041]
8. Dy CJ, Rosenblatt L, Lee SK. Current methods and biomechanics of extensor tendon repairs. *Hand Clin*. 2013;**29**(2):261-8. doi: 10.1016/j.hcl.2013.02.008. [PubMed: 23660062]
9. Griffin M, Hindocha S, Jordan D, Saleh M, Khan W. Management of extensor tendon injuries. *Open Orthop J*. 2012;**6**:36-42. doi: 10.2174/1874325001206010036. [PubMed: 22431949]
10. Newport ML, Williams CD. Biomechanical characteristics of extensor tendon suture techniques. *J Hand Surg Am*. 1992;**17**(6):1117-23. [PubMed: 1430953]
11. Woo SH, Tsai TM, Kleinert HE, Chew WY, Voor MJ. A biomechanical comparison of four extensor tendon repair techniques in zone IV. *Plast Reconstr Surg*. 2005;**115**(6):1674-81. [PubMed: 15861073]