



# Predictive factors of malignancy in dogs with focal liver lesions using clinical data and ultrasonographic features

Rommaneeya LEELA-ARPORN<sup>1)</sup>, Hiroshi OHTA<sup>1)</sup>, Masahiro TAMURA<sup>1)</sup>, Noriyuki NAGATA<sup>1)</sup>, Kazuyoshi SASAOKA<sup>1)</sup>, Angkhana DERMLIM<sup>1)</sup>, Khoirun NISA<sup>1)</sup>, Keitaro MORISHITA<sup>2)</sup>, Noboru SASAKI<sup>1)</sup>, Kensuke NAKAMURA<sup>2,3)</sup>, Satoshi TAKAGI<sup>2,4)</sup>, Kenji HOSOYA<sup>2)</sup> and Mitsuyoshi TAKIGUCHI<sup>1)</sup>\*

<sup>1)</sup>Laboratory of Veterinary Internal Medicine, Department of Veterinary Clinical Sciences, Graduate School of Veterinary Medicine, Hokkaido University, Sapporo, Hokkaido 060-0818, Japan

<sup>2)</sup>Veterinary Teaching Hospital, Graduate School of Veterinary Medicine, Hokkaido University, Sapporo, Hokkaido 060-0818, Japan

<sup>3)</sup>Organization for Promotion of Tenure Track, University of Miyazaki, Miyazaki 889-2192, Japan

<sup>4)</sup>Department of Veterinary Medicine, Azabu University, Kanagawa 252-5201, Japan

**ABSTRACT.** A definitive diagnosis of focal liver lesions (FLLs) requires invasive procedures for histopathologic examination. Thus, a simpler noninvasive diagnostic method, such as conventional ultrasonography combined with clinical data, is needed for the prediction of liver malignancy. The objective of this study was to examine the diagnostic accuracy of clinical data and ultrasonographic (US) features to differentiate benign and malignant liver lesions. Medical records and US images from dogs with FLLs that underwent abdominal US and histopathologic examinations following surgery or liver biopsy were retrospectively reviewed. Clinical data, including signalment, clinical signs and laboratory findings, and the US features of liver lesions that could act as predictive factors were assessed using univariate and multivariate analyses to evaluate the associations between predictive factors and liver malignancy. Based on the histopathologic results, 55 dogs with malignant lesions and 28 dogs with benign lesions were included in the study. The results of univariate analysis showed that several US features and platelet count were significantly associated with liver malignancy. Multivariate analysis revealed that the platelet count (thrombocytosis; odds ratio [OR]: 4.13, 95% confidence intervals [CI]: 1.81–9.41), lesion size (4.1 cm or greater; OR: 23.83, 95% CI: 3.74–151.95) and echotexture of FLLs (heterogenous; OR: 8.44; 95% CI: 1.37–51.91) were independent predictors for differentiating benign and malignant liver lesions, suggesting that a combination of clinical data and US findings of FLLs could predict liver malignancy in dogs.

**KEY WORDS:** canine, classification, liver nodule, malignancy, ultrasonography

*J. Vet. Med. Sci.*  
81(5): 723–729, 2019  
doi: 10.1292/jvms.18-0673

Received: 15 November 2018  
Accepted: 22 March 2019  
Published online in J-STAGE:  
8 April 2019

Recent advances in diagnostic technology, including computed tomography (CT) and ultrasonography (US), have gained increasing popularity as useful imaging modalities worldwide, resulting in an increasing number of incidental findings of focal liver lesions (FLLs) and a need to visit an animal hospital. An FLL that presents as a nodule or mass in dogs can be either a benign or a malignant liver disease. The gold standard for a definitive diagnosis of FLLs is a liver biopsy [24]; however it is expensive and invasive, and it can result in life-threatening complications [4, 16]. Thus, noninvasive diagnostic methods for determining the nature and importance of FLLs are needed.

CT examination is a promising imaging modality for differentiating malignant and benign FLLs in dogs [10, 11, 15]. However, CT might not be easily accessible due to the cost, the need for sedation or anesthesia, and its limited availability in veterinary facilities. Thus, US has been more common in assessing liver lesions since it is widely available in many veterinary clinics and hospitals for daily diagnosis and is less expensive.

A new US technique called contrast-enhanced US, which can provide real-time perfusion imaging of many organs [14], has been mainly used in investigating FLLs in dogs [14, 21] due to its diagnostic capability to differentiate benign and malignant FLLs with high accuracy [21]. However, this technique is only available in a limited number of countries due to local regulations and

\*Correspondence to: Takiguchi, M.: mtaki@vetmed.hokudai.ac.jp

©2019 The Japanese Society of Veterinary Science



This is an open-access article distributed under the terms of the Creative Commons Attribution Non-Commercial No Derivatives (by-nc-nd) License. (CC-BY-NC-ND 4.0: <https://creativecommons.org/licenses/by-nc-nd/4.0/>)

the need for specific equipment, including contrast agent, transducers, and special software for analysis. Therefore, a simpler and noninvasive diagnostic method for distinguishing benign from malignant FLLs is needed.

Conventional B-mode US is a simple diagnostic method commonly used in clinical settings to investigate the liver by evaluating its appearance, including the echogenicity, echotexture, size, shape, and margins, to detect lesions that affect the liver parenchyma [6, 28]. However, it remains diagnostically challenging to determine the nature of FLLs based solely on this method since it is widely known that the US characteristics of FLLs cannot provide a specific diagnosis [8, 9, 23, 26, 31] due to overlap of the US features of malignant and benign liver lesions [28, 31]. Conversely, recent studies have suggested that several US features of FLLs may be related to malignant conditions and liver cytology results [11, 12, 20]. In addition, clinical data, including signalment, clinical signs, and laboratory findings, are generally considered nonspecific findings. The use of this information alone is not sufficiently accurate to determine the causes of FLLs [8, 9, 17, 23, 26, 31]. However, a combination of clinical data and US features of FLLs may have the potential to predict whether a liver lesion is benign or malignant.

The purpose of this study was to determine the clinical relevance of clinical and US data for the prediction of FLL malignancy in dogs. We hypothesized that clinical data, US appearances of FLLs, or the combination of both provides independent predictors for classifying benign and malignant liver lesions.

## MATERIALS AND METHODS

### *Study population*

A retrospective cross-sectional study was conducted using information from dogs with FLLs with histologically confirmed diagnoses between January 2013 and July 2018 at Hokkaido University Veterinary Teaching Hospital. The inclusion criteria of this study were dogs with FLLs that underwent abdominal US and histopathologic examinations following surgery or liver biopsy. All of the histopathologic examinations were performed by a board-certified pathologist.

Dogs were excluded from this study if they did not undergo abdominal US examination, if they had no representative US images of the liver, or if the quality of US images was poor due to the possibility of misinterpretation.

### *Data collection*

Medical records were reviewed for candidate predictive factors, including signalment, clinical signs, laboratory findings, and abdominal US findings. Signalment consisted of age, body weight and sex. Clinical signs consisted of anorexia, weight loss, lethargy, polyuria and polydipsia (PU/PD), vomiting, diarrhea, jaundice, and neurological signs.

Laboratory findings, including a complete blood count, liver enzyme activities, and total bilirubin (T-bil) concentration, were extracted from the medical records of all of the included dogs over a 2-week period of abdominal US examinations. Hematological abnormalities were defined as follows: leukocytosis if the white blood cell (WBC) count was greater than  $17 \times 10^3/\mu\text{l}$ , anemia if the hematocrit (HCT) was less than 37%, and thrombocytosis if the platelet (PLT) count was greater than  $500 \times 10^3/\mu\text{l}$ . The upper limits of the reference ranges for liver enzymes, including serum alkaline phosphatase (ALP), alanine aminotransferase (ALT), aspartate aminotransferase (AST), and gamma-glutamyl transferase (GGT) activities, were 254, 78, 44, and 14 IU/l, respectively. The reference range for the T-bil concentration was less than 0.5 mg/dl.

All of the US images were collected using one of three US scanners (Aplio XG and Aplio 500, Toshiba Medical Systems, Tochigi, Japan; HI VISION Preirus, Hitachi Medical Corp, Chiba, Japan) that are available in our veterinary teaching hospital. The US findings of FLLs included maximum size, number, margin, echotexture, and echogenicity relative to the liver parenchyma. These US findings were compared with histopathologic results as predictors of malignant and benign liver diseases. The size of FLLs was defined as the maximum diameter based on the maximum measurable diameter in each case. The number of FLLs was recorded as single or multiple. The margin of FLLs was categorized as smooth or irregular. Additionally, the echotexture of FLLs was classified by its uniformity as homogeneous or heterogeneous throughout the lesion's parenchyma. The echogenicity of FLLs was categorized as anechoic, hypoechoic, isoechoic, hyperechoic, or mixed echogenicity from the lesion's brightness relative to the surrounding liver parenchyma. The presence or absence of peritoneal fluid, hepatic lymphadenopathy, and calcification was also evaluated. All of the US images were assessed using medical imaging viewer software (OsiriX, Pixmeo SARL, Bernex, Switzerland) as a reference for FLLs by two investigators (RL and MT).

### *Statistical analysis*

Comparisons of all of the predictive factors of benign and malignant liver lesions were conducted with univariate analyses using Fisher's exact test or the  $\chi^2$  test for categorical variables, including sex, the presence of clinical signs, the presence of abnormal laboratory findings, US appearance of FLLs, and the presence of peritoneal fluid, hepatic lymphadenopathy, and calcification. The data are presented as numbers and percentages. Continuous variables, including age, body weight and maximum lesion size, were assessed using the Mann-Whitney *U*-test and are expressed as the medians and ranges. Spearman's correlation analysis was performed to evaluate the possible relationship between the body weights of dogs and the lesion size. The optimal cut-off values of lesion size to predict malignancy were chosen from a receiver operating characteristic (ROC) curve analysis with the criterion variables "maximum lesion size" and "malignant" as condition variables.

A multivariable logistic regression model was used to select predictive factors from univariate analyses via a forward stepwise selection procedure. The selection used a threshold *P* value ( $P < 0.15$  for inclusion,  $P > 0.2$  for exclusion) to identify independent predictors with the strongest associations with liver malignancy. Then, the odds ratio (OR) and 95% confidence interval (CI) of

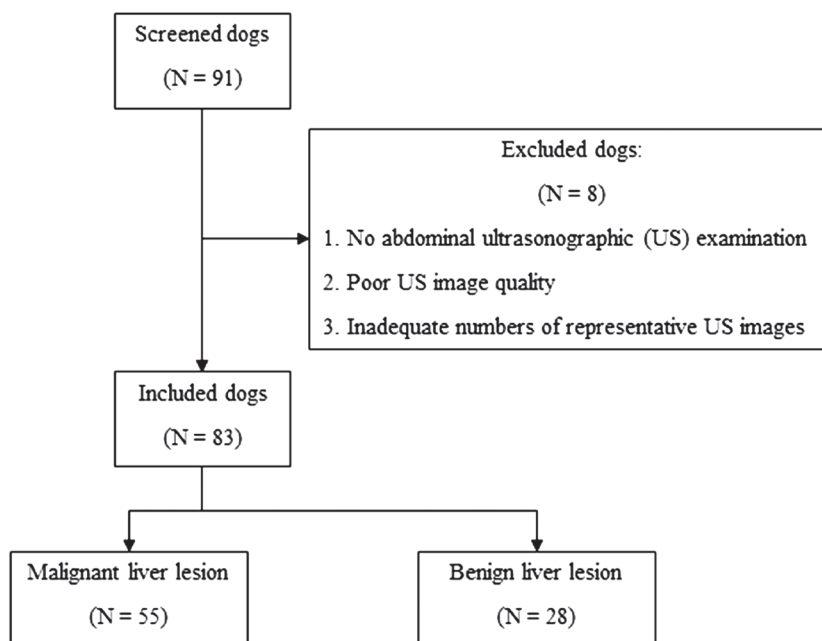


Fig. 1. Diagram of patient selection.

each predictive variable that was included in the multivariate model were calculated. The diagnostic accuracy of the predictive model of independent predictors was assessed by a ROC curve. For all of the statistical analyses, a  $P$  value  $<0.05$  was considered significant. All of the data were analyzed using commercial statistical software (JMP Pro, version 14.0.0, SAS Institute Inc.).

## RESULTS

### Animals

A total of 91 dogs with histopathological diagnoses of FLLs were identified during the study period. A total of 83 dogs met the inclusion criteria. The remaining 8 dogs were excluded due to poor US image quality or inadequately representative US images (Fig. 1).

Of these 83 dogs, the dog breeds included 13 Miniature Dachshunds, eight Chihuahuas, six Beagles, six Welsh Corgis, six Shiba Inus, six Yorkshire Terriers, five Shih Tzus, four Toy Poodles, three Golden Retrievers, three Labrador Retrievers, three mongrels, two American Cocker Spaniels, two Border Collies, two Malteses, two Miniature Schnauzers, two Papillons, and one each of the following: Boston Terrier, Cairn Terrier, French Bulldog, Jack Russel, Lhasa Apso, Pekingese, Pug, Scottish Terrier, Shetland Sheepdog, and Standard Dachshund.

### Histopathologic classification

Histopathologic results revealed that 55 dogs had malignant lesions, and 28 dogs had benign lesions. Of the malignant lesions, there were 37 hepatocellular carcinomas (HCCs), five hemangiosarcomas, four undifferentiated sarcomas, three cholangiocellular carcinomas, three hepatocholangiocellular carcinomas, and three metastatic lesions. Benign lesions included 12 nodular hyperplasias, six glycogen accumulations, three cases of cholangiohepatitis, two normal livers, and one each of hepatitis, amyloidosis, hepatic cyst, biliary cyst, and hematoma.

### Predictive factors of liver malignancy

The evaluation of the predictive factors possibly associated with liver malignancy was performed by univariate analyses of clinical data and US features. The results of all of the predictive factors are summarized in Table 1.

Regarding predictive factors of clinical data, the median ages of dogs with benign and malignant liver lesions were 11 years (range, 6–17 years) and 12 years (range, 7–16 years), respectively, which were not significantly different ( $P=0.896$ ). There was also no significant difference between the body weights of dogs between benign and malignant liver lesions ( $P=0.467$ ), and the median body weights of dogs with benign and malignant lesions were 7.4 kg (range, 2.3–22.9) and 7.5 kg (range, 1.7–37), respectively. Thirteen male and 15 female dogs had benign lesions, and 32 male and 23 female dogs had malignant lesions. The sex distributions were not significantly different between dogs with benign and malignant liver lesions ( $P=0.357$ ). Of these 83 dogs, only 41 dogs, including 13 dogs with benign liver lesions and 28 dogs with malignant liver lesion, presented with clinical signs; however, no significant differences were found regarding the presence of clinical signs, as shown in Table 1. For the complete blood count, data were extracted from the medical records of 83 dogs to obtain HCT data and from 82 dogs to obtain WBC and PLT counts.

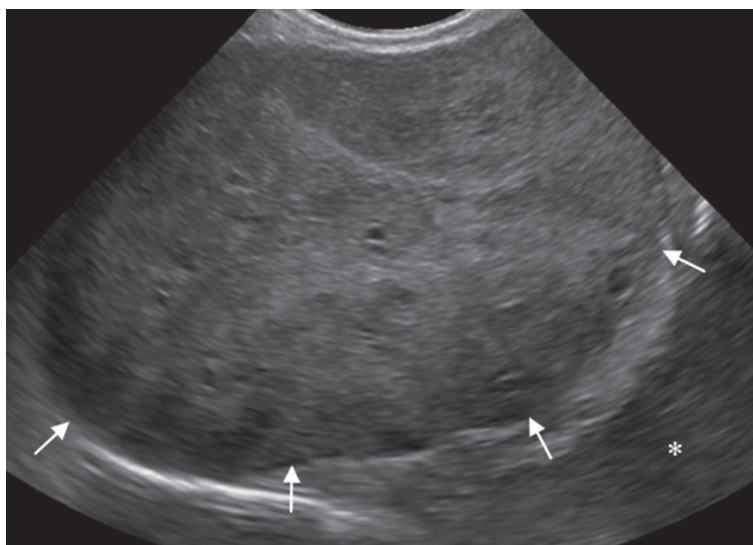
**Table 1.** Comparison of the characteristics of clinical data and ultrasonographic findings between benign and malignant liver lesions in dogs

Variables	Total (n=83)		P value
	Benign (n=28), n (%)	Malignant (n=55), n (%)	
<b>Signalment</b>			
Age in years – median (range)	11 (6–17)	12 (7–16)	0.896
Body weight in kg – median (range)	7.4 (2.3–22.9)	7.5 (1.7–37)	0.467
Sex			0.357
Male	13 (46.4)	32 (58.2)	
Female	15 (53.6)	23 (41.8)	
<b>Clinical signs</b>			
Anorexia	6 (21.4)	12 (21.8)	1.000
Weight loss	2 (7.1)	6 (10.9)	0.711
Lethargy	5 (17.9)	9 (16.4)	1.000
PU/PD	5 (17.9)	8 (14.6)	0.754
Vomiting	3 (10.7)	3 (5.5)	0.400
Diarrhoea	2 (7.1)	4 (7.3)	1.000
Jaundice	2 (7.1)	0 (0)	0.111
Neurological signs	1 (3.6)	0 (0)	0.337
<b>Laboratory test results</b>			
Leucocytosis	6/27 (22.2)	10/55 (18.2)	0.852
Anaemia	5/28 (17.9)	13/55 (23.6)	0.779
Thrombocytosis	6/27 (22.2)	30/55 (54.6)	0.017 <sup>a)</sup>
High ALT level	23/28 (82.1)	44/55 (80.0)	1.000
High AST level	12/21 (57.1)	17/40 (42.5)	0.296
High ALP level	25/28 (89.3)	47/55 (85.5)	0.743
High GGT level	9/18 (50.0)	11/29 (37.9)	0.546
Hyperbilirubinemia	4/25 (16.0)	2/50 (4.0)	0.091
<b>Ultrasound</b>			
Maximum lesion size in cm – median (range)	1.8 (0.4–7.0)	5.1 (0.9–15.3)	<0.001 <sup>a)</sup>
Lesion number			0.229
Single	16 (57.1)	39 (70.9)	
Multiple	12 (42.9)	16 (29.1)	
Lesion margin			0.113
Smooth	24 (85.7)	37 (67.3)	
Irregular	4 (14.3)	18 (32.7)	
Lesion echotexture			<0.001 <sup>a)</sup>
Homogeneous	16 (57.1)	2 (3.6)	
Heterogeneous	12 (42.9)	53 (96.4)	
Lesion echogenicity			<0.001 <sup>a)</sup>
Anechoic	1 (3.6)	0 (0)	
Hypoechoic	7 (25.0)	1 (1.8)	
Hyperechoic	8 (28.6)	1 (8.2)	
Mixed echogenicity	12 (42.9)	53 (96.4)	
Ascites	0 (0)	4 (7.3)	0.295
Hepatic lymphadenopathy	2 (7.1)	4 (7.3)	1.000
Calcification	0 (0)	0 (0)	NA

a) P values <0.05 were statistically significant. NA=Not assessed.

For serum biochemistry, data were extracted from the medical records of 83 dogs to obtain ALP and ALT levels, 61 dogs to obtain AST levels, 47 dogs to obtain GGT levels, and 75 dogs to obtain T-bil levels. Among the clinical data, the results of univariate analyses indicated that the PLT count was the only factor predictive of FLL malignancy in which dogs with malignant liver lesions significantly represented with thrombocytosis ( $P=0.017$ ).

Three US variables were significantly different between benign and malignant liver lesions. The maximum lesion size of malignant liver lesions (median 5.1 cm, range: 0.9–15.3 cm) was significantly larger than that of benign liver lesions (median 1.8 cm, range: 0.4–7.0 cm) ( $P<0.001$ ), and the body weight showed a positive correlation with lesion size ( $r=0.1437$ ,  $P=0.195$ ). The best cut-off value of lesion size to differentiate malignant from benign liver lesions was 4.1 cm. Using the cut-off value of 4.1 cm, the diagnostic performance was as follows: accuracy: 78.3%; sensitivity: 70.9%; specificity: 92.9%; positive predictive value (PPV): 95.1%; and negative predictive value (NPV): 61.9%. In addition, compared with benign liver lesions, malignant liver



**Fig. 2.** Conventional B-mode ultrasonographic (US) image of hepatocellular carcinoma. The lesion has a heterogeneous echotexture and mixed echogenicity ranging from hypoechoic to hyperechoic (arrows), compared with the surrounding normal liver parenchyma (\*).

**Table 2.** Multivariable logistic regression with stepwise model selection to identify independent variables for predicting liver malignancy

Variables	Odds ratio	95% CI	P value
PLT count			
Thrombocytosis	7.17	1.52–33.77	0.013 <sup>a)</sup>
Maximum lesion size			
4.1 cm in diameter or greater	23.83	3.74–151.95	<0.001 <sup>a)</sup>
Lesion echotexture			
Heterogeneous	8.44	1.37–51.91	0.021 <sup>a)</sup>

a) P values <0.05 were statistically significant.

lesions showed significantly heterogeneous echotexture ( $P<0.001$ ) and mixed echogenicity ( $P<0.001$ ) on US (Fig. 2).

In the multivariate analysis, the significant predictive factors in the univariate analyses were selected using a multivariable logistic regression model. The multivariate analysis showed that the PLT count (thrombocytosis; OR: 7.17, 95% CI: 1.52–33.77,  $P=0.013$ ), maximum lesion size (4.1 cm or greater; OR: 23.83, 95% CI: 3.74–151.95,  $P<0.001$ ), and echotexture of FLLs (heterogeneous; OR: 8.44, 95% CI: 1.37–51.91,  $P=0.021$ ) were found to be independent predictive factors of liver malignancy, as shown in Table 2. The predictive performance of this model exhibited 85.4% accuracy, 89.1% sensitivity, 77.8% specificity, 89.1% PPV, and 77.8% NPV, with an area under the curve of 0.92.

## DISCUSSION

The goal of this retrospective study was to determine the predictive performance of clinical data and US features in determining the malignancy of FLLs. Our multivariate analysis results indicated that the PLT count, maximum lesion size, and echotexture of FLLs were independent predictors for differentiating between benign and malignant liver diseases.

The results of this study revealed a heterogeneous echotexture that was significantly associated with malignant liver lesions, and this heterogeneous appearance could result from intratumoral hemorrhage and necrosis [2]. This result is consistent with the results of previous studies that described the presence of target lesions and cavitations inside a mass as signs of liver malignancy [8, 11], since these 2 features also presented as heterogeneous echotexture. Thus, this result suggested that a heterogeneous echotexture of an FLL is a useful US finding for predicting malignant conditions.

However, in the present study, we did not separately classify the presence of cavitations within a mass or target lesions from a heterogeneous echotexture of FLLs on US findings since this study aimed to conduct a simple US evaluation to predict benign and malignant liver lesions for clinicians to use in clinical practice; thus, our results were different from those of previous studies [11, 12, 20, 30] that did not show an association between the echotexture of FLLs and liver malignancies. Among the reasons for this discrepancy are the different US criteria for evaluating the appearances of FLLs [11, 12, 20, 30] and different denominator populations. Furthermore, some predictive factors measured in this study were not included in previous studies [11, 12, 20, 30].



Due to these differences, US classification guidelines for differentiating between benign and malignant liver lesions are needed.

The results of this study also showed that a lesion size of 4.1 cm or greater was significantly associated with malignant liver lesions, consistent with the results of previous studies [12, 20]. However, the cut-off values of maximum lesion size were greater than those of previous studies, perhaps due to the number of included dogs with HCC in this study. HCC mostly presented with large sizes of FLLs, which could have contributed to the prediction of liver malignancy based on lesion size.

The presence of ascites was not independently associated with liver malignancy, conflicting with the results of previous studies [12, 20]. This discrepancy may be due to the limited number of dogs with FLLs in this study. Additionally, ascites are present not only in neoplastic diseases but also in non-neoplastic liver diseases [30], such as chronic hepatitis. In the present study, none of the benign diseases presented with ascites. Thus, the presence of ascites could have been an independent factor for predicting liver malignancy, as indicated in previous studies [12, 20], had the number of dogs with FLLs been greater.

Although the clinical characteristics of dogs with FLLs are usually nonspecific [3, 27], thrombocytosis was overrepresented in the dogs with malignant liver lesions examined here, possibly due to the presence of a large number of dogs with HCC in this study. This result is similar to the results of previous reports of canine HCC [18]. In addition, recent studies have also revealed that reactive or secondary thrombocytosis is commonly associated with neoplasias, especially carcinoma [1, 22, 32]. However, the causes of carcinoma-related thrombocytosis in dogs remain unclear; these conditions may result from paraneoplastic syndrome, as observed in human malignancies, including HCC [7, 13, 19]. In humans, tumors have been linked to the production of granulocyte-macrophage colony-stimulating factor, interleukin-6, and thrombopoietin (TPO) [5, 13, 25, 29], and the liver is a source of TPO. Nevertheless, the role of TPO in liver disease in dogs has not yet been investigated, so there could be mechanisms related to thrombocytosis. Additionally, thrombocytosis can contribute to a thromboembolic event and affect prognosis, as well as survival time, as presented in humans; however, we did not investigate the risk of thromboembolic events, survival time or the outcomes of dogs in this study. Therefore, further investigation is needed to determine the pathophysiologic mechanism of thrombocytosis and its roles as a paraneoplastic phenomenon and prognostic factor.

This study had several limitations. First, the clinical and laboratory findings could not be collected from all of the dogs included in this study. Missing data could have affected the results of the data analyses. In addition, it is possible that the presenting clinical data may not have been related to the malignant liver lesions in the enrolled dogs with multiple disease processes. Second, US assessment is subjective and depends on an observer. The observer variation could result in diagnostic variability. In this study, to minimize the variation associated with observer assessment, all of the examiners used a fixed criterion for assessment.

Third, we used three different ultrasound devices to image FLLs. Despite this limitation, our results indicated that the echotexture of FLLs could independently predict liver malignancy. Therefore, the usefulness of the US echotexture in predicting liver malignancy might not depend on the type of ultrasound device used.

Next, we did not normalize the body size of dogs for the lesion size variable due to the small effect of body weight on the lesion size variables in the present study. Thus, it is possible that there might be an effect of the body size of dogs on the liver lesion diameter. Further study is needed to confirm the effect of body weight on the lesion size of FLLs. In addition, because this study was performed at a referral hospital, there is the possibility that malignant liver lesion might be detected in lesion sizes smaller than 4.1 cm in general hospital situations.

Due to the retrospective nature of this study, another limitation is that interpretation of US appearances was performed using stored images, which might have limited the accuracy for detecting some US appearances. To minimize this limitation, the authors also used video clips of the FLLs to interpret US appearances.

Finally, we used histopathologic results as a reference standard and as inclusion criteria, likely leading to a number of biases since some dogs with FLLs did not undergo surgery or liver biopsy due to either the clinician's decision or the owner's personal reasons. Therefore, the sample size obtained for histopathologic examination could have affected the accuracy of the predictive model. In addition, due to the nature of retrospective studies, we cannot confirm that a lesion detected by ultrasonography was the same lesion from which a sample was collected for histologic examination, which could have affected the accuracy of diagnosis as a limitation of clinical practice. However, we realize that a dog may have multiple disease processes; thus, the histologic results may not have reflected the disease causing an FLL.

In conclusion, a combination of clinical and US data provides independent predictors of FLL malignancy, including thrombocytosis, lesion size of 4.1 cm or greater, and heterogenous echotexture of FLLs, that can differentiate malignant from benign liver lesions in dogs. Prediction of FLL malignancy may help clinicians in clinical decision making for further examination and appropriate treatment.

**ACKNOWLEDGMENTS.** No specific grants were received for this research from funding agencies in the public, commercial, or not-for-profit sectors. The authors wish to thank Dr Yumiko Kagawa, an American College of Veterinary Pathologists board-certified pathologist, for her help with the interpretation of all of the histopathological findings.

## REFERENCES

1. Athanasiou, L. V., Polizopoulou, Z. S., Papavasileiou, E. G., Mpairamoglou, E. L., Kantere, M. C. and Rousou, X. A. 2017. Magnitude of reactive thrombocytosis and associated clinical conditions in dogs. *Vet. Rec.* **181**: 267. [Medline] [CrossRef]
2. Badea, R. and Ioanimescu, S. 2012. Ultrasound imaging of liver tumors –current clinical applications. pp. 75–102. In: *Liver Tumors*, ed. (Julianov, A. ed.), InTech, Croatia. <http://www.intechopen.com/books/liver-tumors/ultrasound-imaging-of-liver-tumors-current-clinical-applications> [assessed

- on September 6, 2017].
3. Bexfield, N. 2017. Neoplasms of the liver. pp. 4065–4074. *In: Textbook of Veterinary Internal Medicine*, 8th ed. (Ettinger, S.J., Feldman, E.C. and Cote E. eds.), Elsevier, St. Louis.
  4. Bigge, L. A., Brown, D. J. and Penninck, D. G. 2001. Correlation between coagulation profile findings and bleeding complications after ultrasound-guided biopsies: 434 cases (1993–1996). *J. Am. Anim. Hosp. Assoc.* **37**: 228–233. [[Medline](#)] [[CrossRef](#)]
  5. Bihari, C., Rastogi, A., Shasthry, S. M., Bajpai, M., Bhadoria, A. S., Rajesh, S., Mukund, A., Kumar, A. and Sarin, S. K. 2016. Platelets contribute to growth and metastasis in hepatocellular carcinoma. *APMIS* **124**: 776–786. [[Medline](#)] [[CrossRef](#)]
  6. Biller, D. S. and Blackwelder, T. 1998. Hepatic ultrasonography: a valuable tool in small animals. *Vet. Med.* **93**: 646–653.
  7. Chang, P. E., Ong, W. C., Lui, H. F. and Tan, C. K. 2013. Epidemiology and prognosis of paraneoplastic syndromes in hepatocellular carcinoma. *ISRN Oncol.* **2013**: 684026. [[Medline](#)]
  8. Cuccovillo, A. and Lamb, C. R. 2002. Cellular features of sonographic target lesions of the liver and spleen in 21 dogs and a cat. *Vet. Radiol. Ultrasound* **43**: 275–278. [[Medline](#)] [[CrossRef](#)]
  9. d’Anjou, M. A. and Penninck, D. 2015. Liver. pp. 183–238. *In: Atlas of Small Animal Ultrasonography*, 2nd ed. (Penninck, D. and d’Anjou, M. A. eds.), Blackwell, Ames.
  10. Fukushima, K., Kanemoto, H., Ohno, K., Takahashi, M., Nakashima, K., Fujino, Y., Uchida, K., Fujiwara, R., Nishimura, R. and Tsujimoto, H. 2012. CT characteristics of primary hepatic mass lesions in dogs. *Vet. Radiol. Ultrasound* **53**: 252–257. [[Medline](#)]
  11. Griebie, E. R., David, F. H., Ober, C. P., Feeney, D. A., Anderson, K. L., Wuenschmann, A. and Jessen, C. R. 2017. Evaluation of canine hepatic masses by use of triphasic computed tomography and B-mode, color flow, power, and pulsed-wave Doppler ultrasonography and correlation with histopathologic classification. *Am. J. Vet. Res.* **78**: 1273–1283. [[Medline](#)] [[CrossRef](#)]
  12. Guillot, M., Danjou, M. A., Alexander, K., Bédard, C., Desnoyers, M., Beaugard, G. and Del Castillo, J. R. 2009. Can sonographic findings predict the results of liver aspirates in dogs with suspected liver disease? *Vet. Radiol. Ultrasound* **50**: 513–518. [[Medline](#)] [[CrossRef](#)]
  13. Hwang, S. J., Luo, J. C., Li, C. P., Chu, C. W., Wu, J. C., Lai, C. R., Chiang, J. H., Chau, G. Y., Lui, W. Y., Lee, C. C., Chang, F. Y. and Lee, S. D. 2004. Thrombocytosis: a paraneoplastic syndrome in patients with hepatocellular carcinoma. *World J. Gastroenterol.* **10**: 2472–2477. [[Medline](#)] [[CrossRef](#)]
  14. Kanemoto, H., Ohno, K., Nakashima, K., Takahashi, M., Fujino, Y., Nishimura, R. and Tsujimoto, H. 2009. Characterization of canine focal liver lesions with contrast-enhanced ultrasound using a novel contrast agent-sonazoid. *Vet. Radiol. Ultrasound* **50**: 188–194. [[Medline](#)] [[CrossRef](#)]
  15. Kutara, K., Seki, M., Ishikawa, C., Sakai, M., Kagawa, Y., Iida, G., Ishigaki, K., Teshima, K., Edamura, K., Nakayama, T. and Asano, K. 2014. Triple-phase helical computed tomography in dogs with hepatic masses. *Vet. Radiol. Ultrasound* **55**: 7–15. [[Medline](#)] [[CrossRef](#)]
  16. Léveillé, R., Partington, B. P., Biller, D. S. and Miyabayashi, T. 1993. Complications after ultrasound-guided biopsy of abdominal structures in dogs and cats: 246 cases (1984–1991). *J. Am. Vet. Med. Assoc.* **203**: 413–415. [[Medline](#)]
  17. Liptak, J. M. 2013. Hepatobiliary tumors. pp. 405–412. *In: Withrow and MacEwen’s Small Animal Clinical Oncology*, 5th ed. (Withrow, S. J., Vail, D. M. and Page, R.L. eds.), Elsevier, St. Louis.
  18. Liptak, J. M., Dernell, W. S., Monnet, E., Powers, B. E., Bachand, A. M., Kenney, J. G. and Withrow, S. J. 2004. Massive hepatocellular carcinoma in dogs: 48 cases (1992–2002). *J. Am. Vet. Med. Assoc.* **225**: 1225–1230. [[Medline](#)] [[CrossRef](#)]
  19. Luo, J. C., Hwang, S. J., Wu, J. C., Li, C. P., Hsiao, L. T., Lai, C. R., Chiang, J. H., Lui, W. Y., Chang, F. Y. and Lee, S. D. 1999. Paraneoplastic syndromes in patients with hepatocellular carcinoma in Taiwan. *Cancer* **86**: 799–804. [[Medline](#)] [[CrossRef](#)]
  20. Murakami, T., Feeney, D. A. and Bahr, K. L. 2012. Analysis of clinical and ultrasonographic data by use of logistic regression models for prediction of malignant versus benign causes of ultrasonographically detected focal liver lesions in dogs. *Am. J. Vet. Res.* **73**: 821–829. [[Medline](#)] [[CrossRef](#)]
  21. Nakamura, K., Takagi, S., Sasaki, N., Bandula Kumara, W. R., Murakami, M., Ohta, H., Yamasaki, M. and Takiguchi, M. 2010. Contrast-enhanced ultrasonography for characterization of canine focal liver lesions. *Vet. Radiol. Ultrasound* **51**: 79–85. [[Medline](#)] [[CrossRef](#)]
  22. Neel, J. A., Snyder, L. and Grindem, C. B. 2012. Thrombocytosis: a retrospective study of 165 dogs. *Vet. Clin. Pathol.* **41**: 216–222. [[Medline](#)] [[CrossRef](#)]
  23. Nyland, T. G., Larson, M. M. and Mattoon, J. S. 2015. Liver. pp. 332–399. *In: Small Animal Diagnostic Ultrasound*, 3rd ed. (Mattoon, J. S. and Nyland, T. G. eds.), Elsevier, St. Louis.
  24. Rothuizen, J. and Twedt, D. C. 2009. Liver biopsy techniques. *Vet. Clin. North Am. Small Anim. Pract.* **39**: 469–480. [[Medline](#)] [[CrossRef](#)]
  25. Sasaki, Y., Takahashi, T., Miyazaki, H., Matsumoto, A., Kato, T., Nakamura, K., Iho, S., Okuno, Y. and Nakao, K. 1999. Production of thrombopoietin by human carcinomas and its novel isoforms. *Blood* **94**: 1952–1960. [[Medline](#)]
  26. Saunders, H. M. 1998. Ultrasonography of abdominal cavity parenchymal lesions. *Vet. Clin. North Am. Small Anim. Pract.* **28**: 755–775. [[Medline](#)] [[CrossRef](#)]
  27. Selmic, L. E. 2017. Hepatobiliary Neoplasia. *Vet. Clin. North Am. Small Anim. Pract.* **47**: 725–735. [[Medline](#)] [[CrossRef](#)]
  28. Stowater, J. L., Lamb, C. R. and Schelling, S. H. 1990. Ultrasonographic features of canine hepatic nodular hyperplasia. *Vet. Radiol. Ultrasound* **31**: 268–272. [[CrossRef](#)]
  29. Suzuki, A., Takahashi, T., Nakamura, K., Tsuyuoaka, R., Okuno, Y., Enomoto, T., Fukumoto, M. and Imura, H. 1992. Thrombocytosis in patients with tumors producing colony-stimulating factor. *Blood* **80**: 2052–2059. [[Medline](#)]
  30. Warren-Smith, C. M. R., Andrew, S., Mantis, P. and Lamb, C. R. 2012. Lack of associations between ultrasonographic appearance of parenchymal lesions of the canine liver and histological diagnosis. *J. Small Anim. Pract.* **53**: 168–173. [[Medline](#)] [[CrossRef](#)]
  31. Whiteley, M. B., Feeney, D. A., Whiteley, L. O. and Hardy, R. M. 1989. Ultrasonographic appearance of primary and metastatic canine hepatic tumors. A review of 48 cases. *J. Ultrasound Med.* **8**: 621–630. [[Medline](#)] [[CrossRef](#)]
  32. Woolcock, A. D., Keenan, A., Cheung, C., Christian, J. A. and Moore, G. E. 2017. Thrombocytosis in 715 Dogs (2011–2015). *J. Vet. Intern. Med.* **31**: 1691–1699. [[Medline](#)] [[CrossRef](#)]