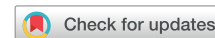

Retrograde crossing and snaring technique to retain access after lead extraction in the setting of venous stenosis: Another tool in the toolbox



Tahmeed Contractor, MD,* Kamal Kotak, MD, FHRS,*
Joshua M. Cooper, MD, FACC, FHRS,† Kyle Cooper, MD‡

From the *Division of Cardiology, Loma Linda University Medical Center, Loma Linda, California, †Section of Electrophysiology, Division of Cardiology, Temple University Hospital, Philadelphia, Pennsylvania, and ‡Department of Radiology, Loma Linda University Medical Center, Loma Linda, California.

Introduction

Venous stenosis presents a common challenge during device upgrade procedures, for which either percutaneous crossing of the occlusion site followed by venoplasty or lead extraction is typically required.^{1–3} While each of these approaches has its advantages, lead extraction can usually achieve venous access, as well as remove redundant leads, and is the preferred approach at many centers.⁴ However, if the extraction sheath is not beyond the site of the stenosis after lead removal, retaining access to the heart can be challenging.

We present a case of planned dual-chamber pacemaker upgrade to a biventricular implantable cardioverter-defibrillator (ICD) where the site of occlusion was distal to the extraction sheath after right ventricular pacemaker lead removal and antegrade access could not be obtained. The site of stenosis was able to be crossed in a retrograde fashion via the femoral approach, and the tip of the crossing wire was snared superiorly from the extraction sheath, allowing successful completion of the upgrade procedure.

Case report

A 72-year-old male patient with a dual-chamber pacemaker implanted 11 years ago for complete heart block presented with worsening symptoms of heart failure and was found to have reduced ejection fraction (30%–35%). He was completely dependent on ventricular pacing and was also a Jehovah's Witness, not willing to accept blood products. Coronary angiography did not reveal any evidence of obstructive

KEY TEACHING POINTS

- Retaining venous access after lead extraction can be a challenge if the extraction sheath has not advanced beyond the site of stenosis.
- Crossing a site of severe venous stenosis in an antegrade fashion can be difficult in many cases based on the morphology of the peripheral cap and antegrade advancement of fibrous tissue in the setting of extraction.
- Retrograde crossing may help in these difficult situations, as the distal aspect of the stenosis can be less resistant to wire advancement.
- After retrograde crossing, the tip of the wire can be pulled superiorly out of the body with a snare, establishing through-and-through access.

coronary arterial disease, making pacing-induced cardiomyopathy a likely contributor to reduced left ventricular function. It was decided to proceed with an upgrade to a biventricular ICD, with the ICD component included for the possibility that another nonischemic cardiomyopathy mechanism was present and might not improve with resynchronization pacing. Lead abandonment (with possible venoplasty in the setting of venous occlusion) or lead extraction for access and removal of the redundant right ventricular pacing lead were discussed as options. The patient preferred the latter, in part to preserve the ability to undergo magnetic resonance imaging scanning, which is not performed at most facilities in the presence of abandoned leads.

We planned to extract the right ventricular lead, which was a bipolar active fixation lead (CapSureFix Novus 4076; Medtronic). As is routine at our institution for extraction of pacing leads greater than 10 years old, bilateral femoral access was obtained, including multiple venous

KEYWORDS Device upgrade; Lead extraction; Retrograde access; Snaring; Venous stenosis
(Heart Rhythm Case Reports 2022;8:36–39)

Funding: This research did not receive any specific grant from funding agencies in the public, commercial, or not-for-profit sectors. **Conflict of interest statement:** Tahmeed Contractor has received speaker's honorarium from Medtronic. **Address reprint requests and correspondence:** Dr Tahmeed Contractor, Loma Linda University Medical Center, 11234 Anderson St, Loma Linda, CA 92354. E-mail address: tahmeedcontractor@gmail.com.

sheaths and a single arterial sheath for blood pressure monitoring and emergency arterial access, if needed. A screw-in temporary pacing lead was advanced via the femoral vein into the right ventricle for stable pacing support during the extraction and upgrade. An additional standard temporary pacemaker wire was also placed in the right ventricle. A Bridge occlusion “rescue” balloon (Philips, Colorado Springs, CO) was advanced to the superior vena cava (SVC) for appropriate sizing with contrast and was then pulled back into the inferior vena cava area, while leaving the access wire in place beyond the SVC. Pre-extraction venogram was not performed, as we planned to retain access using the extraction sheath following lead removal. After the pacemaker generator and leads were freed from the pocket capsule tissue, the right ventricular lead was disconnected from the pacemaker and prepared for extraction using an LLD EZ lead locking stylet (Philips). Since our center did not have access to the laser system, a 13F Tightrail mechanical extraction sheath (Philips) was used to extract the lead. Significant mechanical sheath dissection was required in the subclavian and proximal aspect of the innominate vein owing to vigorous fibrous tissue binding. However, once the lead freed from the right ventricle myocardium, it pulled back almost immediately, well up into the innominate vein, past a site of prominent venous stenosis. As a result, there was no longer a “rail” over which to advance the extraction sheath, and it was not prudent to make attempts to advance the extraction sheath any further (Figure 1A). There was no back-bleeding from the sheath lumen, likely owing to the distal end of the sheath remaining embedded in a tight sleeve of fibrous tissue. Upon attempting to advance a standard Glidewire (Terumo, Tokyo, Japan) through the extraction sheath to regain access to the heart, we encountered significant resistance at the stenosis site in the innominate vein (Figure 1A, red rectangle) and antegrade access through the vacated venous channel was unsuccessful, despite several attempts.

A left-sided peripheral venogram revealed significant venous stenosis at this site (Figure 1B, yellow dotted line). Repeated attempts using a Glidewire Advantage wire (Terumo, Tokyo, Japan) within a 5F multipurpose glide catheter (Terumo, Tokyo, Japan) for steerability were also unsuccessful.

We considered our options at this point: (1) extraction of the atrial lead to retain access (after first snaring the lead from the femoral vein to ensure the extraction sheath was able to be advanced beyond the site of stenosis prior to lead withdrawal); (2) contralateral access with either tunneling of leads or a completely new right-sided biventricular ICD implant; or (3) attempt at retrograde crossing of the stenosis with subsequent snaring of the distal tip of the wire superiorly to regain access. We felt that an attempt at retrograde crossing was the least invasive, especially given that superior and inferior venous access was already present. A Glidewire Advantage wire within a 5F multipurpose sheath was advanced via one of the femoral vein access sites, up through the right atrium and into the SVC. We were able to retrogradely cross the site of stenosis (Figure 2A) and placed the distal tip of the wire close to the extraction sheath in the subclavian vein. Then, using a multiloop snare (Atrieve vascular snare kit; Argon Medical, Frisco, TX) through the extraction sheath, the distal end of the wire was snared (Figure 2B) and pulled superiorly out of the body through the extraction sheath (Figure 2C), establishing through-and-through access, similar to an antegrade technique that was recently described.⁵ The extraction sheath was removed over the wire, and a 9F long sheath was introduced and advanced (Figure 3A) past the stenosis, while maintaining a strong “rail” by applying simultaneous upward and downward traction on both ends of the wire. A second Glidewire was advanced through the sheath after removing the dilator; then, using sequential 9F long peel-away sheaths, the right ventricular ICD lead followed by the coronary sinus lead were implanted successfully (Figure 3B). Venoplasty at the

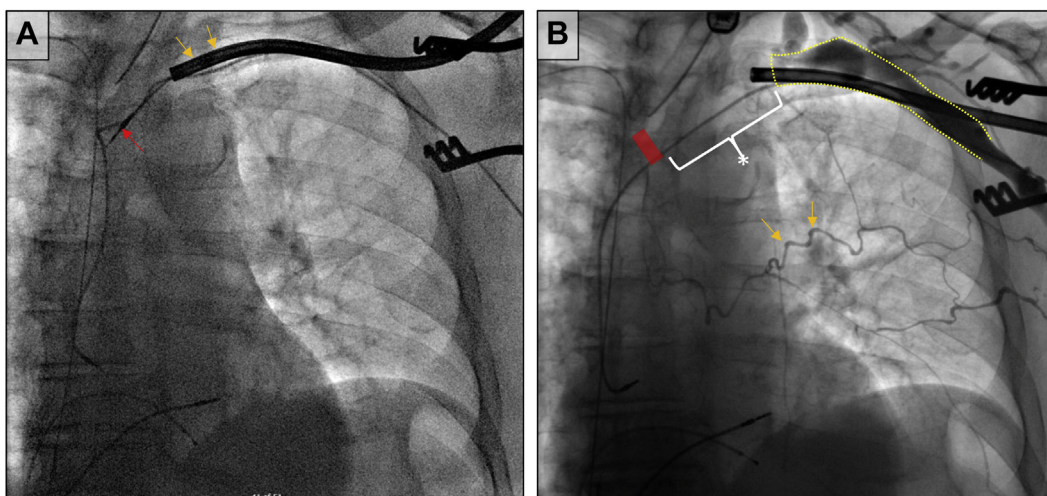


Figure 1 **A:** During extraction, the tip of the lead (red arrow) is pulled back to the innominate vein, not allowing further advancement of the extraction sheath (orange arrows). **B:** Left-sided upper-extremity peripheral venogram showing lack of opacification of the innominate vein, with the yellow dotted line indicating outline of the axillary/subclavian vein. The white asterisk and bracket indicate the zone where the wire could be advanced beyond the sheath despite absence of contrast flow (likely area of dense fibrosis without complete stenosis) and the red bar indicates the zone where the wire could not be advanced antegrade despite multiple strategies and attempts (likely area of complete stenosis). Venous collaterals are seen across the chest wall (orange arrows).

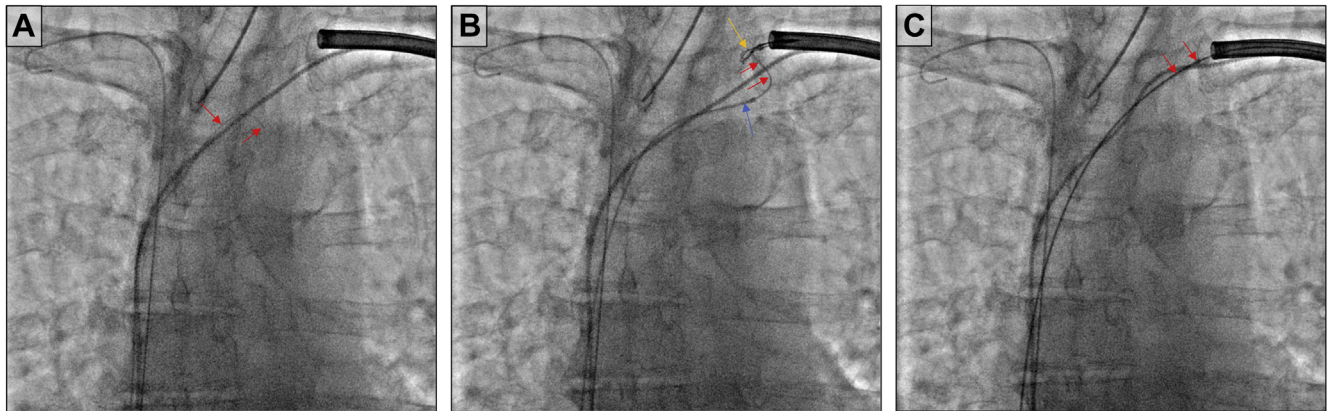


Figure 2 A: Retrograde crossing of the site of stenosis with a Glidewire Advantage (Terumo, Tokyo, Japan; wire tip indicated by *red arrows*). B: Tip of the wire (*red arrows*) extending beyond the multipurpose catheter (*blue arrow*), and snared with the help of a multiloop snare (*orange arrow*) advanced through the extraction sheath. C: Wire (*red arrows*) pulled out of the extraction sheath for through-and-through access.

site of stenosis was not performed after retaining access, given that there were no significant difficulties with advancement of sheaths and placement of the leads. The patient was discharged home the next day and has demonstrated no complications on subsequent follow-up appointments.

Discussion

Retention of access after lead extraction can be a challenge in the setting of venous stenosis. We present a unique solution for this problem that avoids contralateral access or extraction of additional leads, when superior access past a severe venous stenosis is unsuccessful.

Lead extraction is a safe and effective approach to remove redundant leads while also retaining venous access. However, severe venous stenosis beyond the end of the extraction sheath can pose an issue with retaining access if the extracted lead pulls back prematurely. In a recent study by Al-Maisary and colleagues² that evaluated the role of lead extraction in the setting of venous stenosis, access could not be retained in 8 cases (7.6% of the study population) and required contralateral or epicardial lead placement. [Table 1](#) summarizes

strategies to avoid and overcome this problem. Performing a pre-extraction venogram can be helpful to assess the location and length of binding sites and define areas of stenosis or occlusion. Obtaining venous access prior to extraction can also be attempted. However, it may still not be possible to obtain access if there is significant stenosis. If the lead comes free prior to the extraction sheath crossing a site of stenosis, the free end of the lead can often be snared via an inferior approach to reapply countertraction and facilitate further advancement of the sheath. However, owing to the sudden change in traction/countertraction forces at the time of lead release from myocardium, the distal lead end sometimes retracts fully back into the sheath as soon as it comes free, as it did in our case. Up-front femoral snaring in cases where retention of venous access is needed is also an option, but it is not always possible to anticipate the sudden release from myocardial binding with full lead retraction, especially when firm intracardiac binding is anticipated for leads with long dwell times. It may be possible in some cases to remove the distal portion of the lead from the myocardium using traction with a femoral snare, followed by antegrade advancement of the extraction sheath to avoid the sudden pull-back.

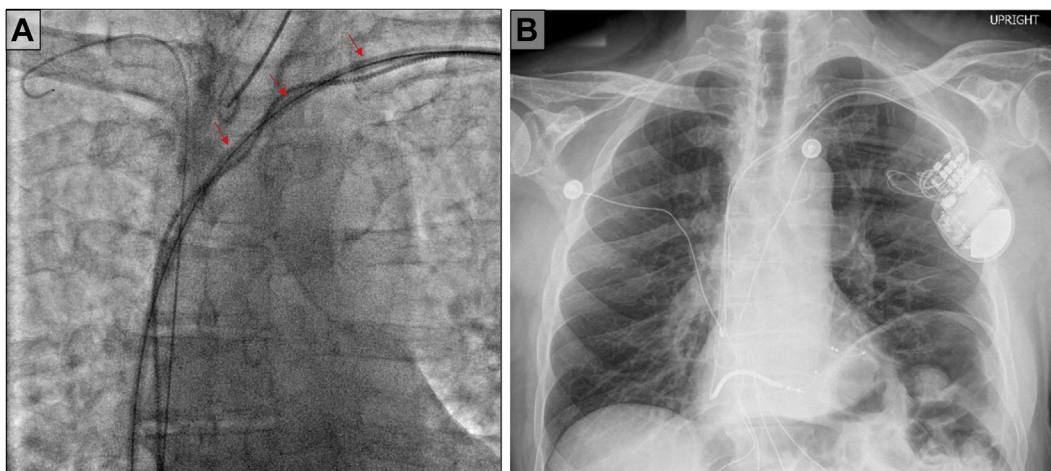


Figure 3 A: Long sheath (*red arrows*) advanced over the Glidewire Advantage (Terumo, Tokyo, Japan) beyond the site of stenosis. B: Postprocedure chest radiograph demonstrating biventricular implantable cardioverter-defibrillator implant.

Table 1 Strategies to retain access during lead extraction in the setting of severe stenosis distal to site of extraction sheath advancement

Strategy	Mechanism	Pitfalls
Snaring tip of lead once after disengaged from heart and freely moving	Allows advancement of extraction sheath beyond site of stenosis	Lead may retract proximal to the site of stenosis when it comes free prior to snaring
Crossing stenosis antegrade	Stenosis can be crossed with the help of special wires (Glidewire; Terumo, Tokyo, Japan) or catheters (KA2; Merit Medical, South Jordan, UT)	May be difficult to cross antegrade based on severity/morphology of stenosis
Crossing stenosis retrograde	Stenosis can be crossed retrograde with help of wires or catheter, and free tip of wire beyond stenosis can be snared from superior access site	May be difficult to cross retrograde based on severity/morphology of stenosis. Snaring may be challenging if long segment of stenosis with high burden of fibrotic material. Pushability and torquability of catheters and wires is diminished over longer distances from access site.
Contralateral access	Access can be obtained from contralateral side and lead can subsequently be tunneled to the ipsilateral side	Both sides are now utilized, impacting superior venous options in the future for lead placement or other needs, such as hemodialysis or chronic venous intravenous access

Strategies for re-crossing a severe vein stenosis include using a Glidewire or KA2 catheter (Merit Medical, South Jordan, UT).⁶ In our case, the KA2 catheter was not available at our institution at the time of the procedure, and multiple attempts with the Glidewire were unsuccessful. When multiple leads are present, another strategy is extraction of a functional lead that was initially planned to be preserved, usually with up-front snaring to avoid the same problem; however, the additional extraction adds to overall procedural risk, as well as adds the cost of replacing this additional lead. Contralateral access and tunneling of leads as a “last resort” strategy is not ideal with respect to using another precious venous access site, and possibly increasing the risk for lead failure. It may also be problematic in patients with pre-existing contralateral venous stenosis, occlusion, or hemodialysis access.

Multiple technical factors must be considered when attempting to cross venous stenoses and occlusions in one direction or the other. Crossing obstructions in the subclavian/innominate veins may be easier antegrade (from peripheral to central), as the operator is able to navigate across venous valves in the anatomically favorable orientation, and catheter and wire manipulation is easier when working over shorter distances and when confined within smaller spaces (ie, without spanning capacious spaces such as the right atrium). However, similar to chronic arterial total occlusions, specific morphologies of the peripheral cap can make engaging and crossing obstruction challenging in an antegrade fashion.⁷ The retrograde approach may help in these difficult situations, as the distal aspect of the stenosis is more likely to be tapered, less fibrocalcific, and hence less resistant to wire advancement.⁸ Retrograde access is also less likely to be affected by antegrade advancement (or “snow ploughing”) of fibrous tissue by the extraction sheath. There is currently no literature that describes characteristics of venous stenosis that would predict requirement of a retrograde approach, and clinical investigation in this area is warranted. Additionally, when intravascular positioning of

the tip of the extraction sheath often cannot be confirmed in the setting of venous occlusion given the lack of blood return, wire advancement may place the wire into the perivascular space; retrograde crossing attempts provide relative certainty that the initial catheter/wire positioning is intravascular prior to engaging the site of suspected stenosis or occlusion.

Conclusion

In conclusion, we present a case where retaining access to the heart proved difficult after lead extraction in the setting of significant venous stenosis. The stenosis was crossed via a retrograde approach and snared superiorly via the extraction sheath to maintain access, thus avoiding extraction of additional leads or contralateral access. Larger studies are required to determine factors that would require retrograde crossing of fibrotic venous stenosis.

References

1. Worley SJ, Gohn DC, Pulliam RW, et al. Subclavian venoplasty by the implanting physicians in 373 patients over 11 years. *Heart Rhythm* 2011;8:526–533.
2. Al-Maisary S, Romano G, Karck M, et al. The use of laser lead extraction sheath in the presence of supra-cardiac occlusion of the central veins for cardiac implantable electronic device lead upgrade or revision. *PLoS One* 2021;16:e0251829.
3. Sohal M, Williams S, Akhtar M, et al. Laser lead extraction to facilitate cardiac implantable electronic device upgrade and revision in the presence of central venous obstruction. *Europace* 2014;16:81–87.
4. Maytin M, Epstein LM. Lead extraction is preferred for lead revisions and system upgrades: when less is more. *Circ Arrhythm Electrophysiol* 2010;3:413–424.
5. Arkles JS, Suryanarayana PG, Sadek M, et al. Wire countertraction for sheath placement through stenotic and tortuous veins: the “body flossing” technique. *Heart Rhythm O2* 2020;1:21–26.
6. Marcial JM, Worley SJ. Venous system interventions for device implantation. *Card Electrophysiol Clin* 2018;10:163–177.
7. Saab F, Jaff MR, Diaz-Sandoval LJ, et al. Chronic Total Occlusion crossing approach based on Plaque cap morphology: the CTOP classification. *J Endovasc Ther* 2018;25:284–291.
8. Megaly M, Ali A, Saad M, et al. Outcomes with retrograde versus antegrade chronic total occlusion revascularization. *Catheter Cardiovasc Interv* 2020; 96:1037–1043.