



Endoscopic submucosal dissection of a large cecal tumor extending into the appendiceal orifice in a patient with intact appendix

Keigo Sato, MD,¹ Toshio Uraoka, MD, PhD,¹ Hirohito Tanaka, MD,¹ Hemchand Rambaran, MD,² Shiko Kuribayashi, MD, PhD¹

Endoscopic resection of cecal tumors extending into the appendiceal orifice in patients with intact appendix is known to be technically difficult, associated with higher risk of perforation and appendicitis. Consequently, surgical resection has been the conventional treatment even for adenomas.^{1,2} Recently, there have been some reports of endoscopic resection for similar tumors as a result of improved devices and accumulated experience with these complex resections. However, reported experience on the safety and effectiveness of endoscopic resection is lacking, and the best management for these lesions is still variable depending on the availability of expertise. Here we present a case of a large laterally spreading

tumor-granular type (LST-G) extending into the appendiceal orifice with an intact appendix, resected successfully by en bloc endoscopic submucosal dissection (ESD).

A 61-year-old woman presented with a 90-mm LST-G in the cecum (Fig. 1A). An appendiceal orifice could not be definitively identified. The tumor was Type 2B and V₁ mildly irregular by the Japan NBI Expert Team and Kudo pit pattern classifications, respectively. Despite the size and location of lesion, the patient requested minimally invasive treatment after detailed discussion about options, and ESD was planned after informed consent was obtained.

ESD was performed with the patient under conscious sedation with midazolam and with use of carbon dioxide

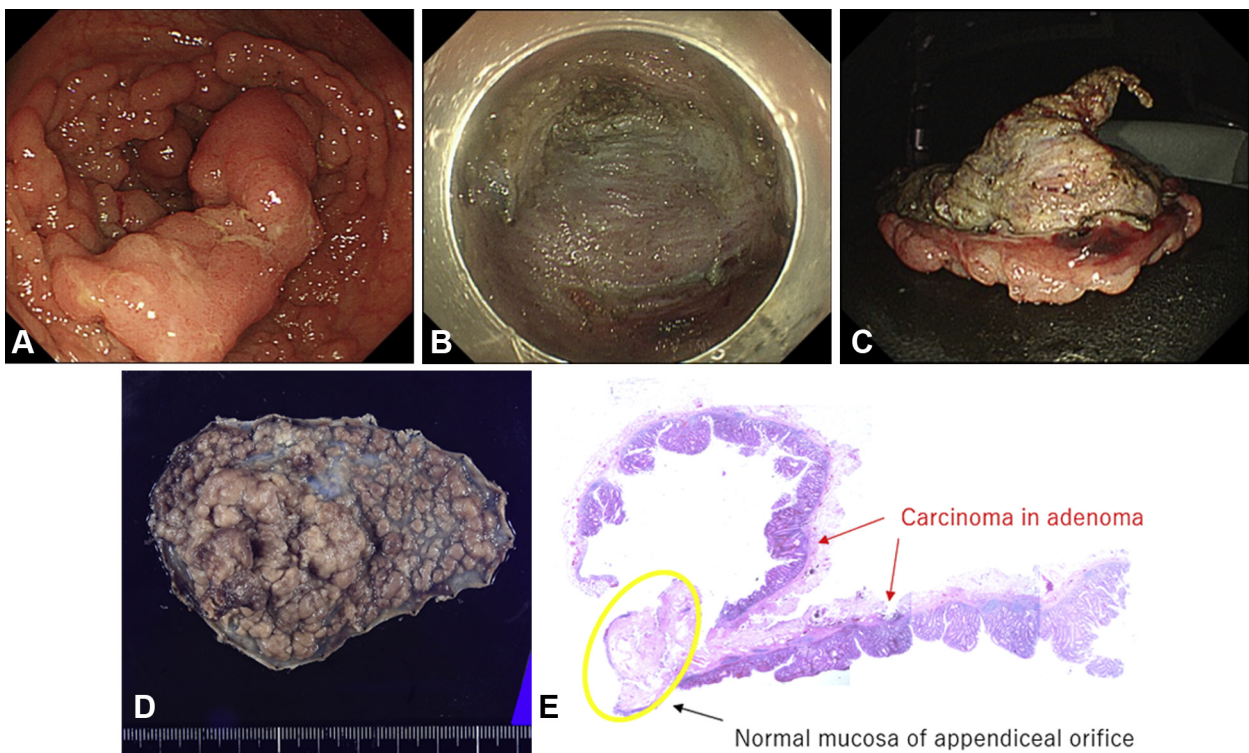


Figure 1. Endoscopic submucosal dissection of a cecal laterally spreading tumor. **A**, A 90-mm-diameter laterally spreading tumor-granular type in the cecum extended into the appendiceal orifice. An appendiceal orifice could not be identified. **B**, Mucosal defect after endoscopic submucosal dissection. **C and D**, The resected specimen. **E**, Histopathology revealed well-differentiated adenocarcinoma, pTis, Ly0, V0, BD1, HM0, VM0.

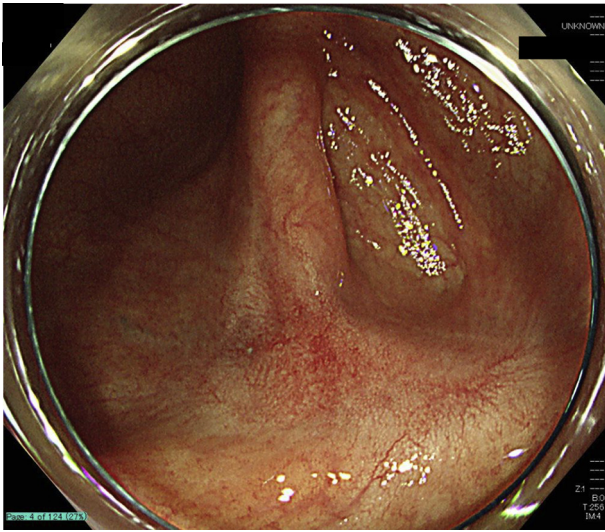


Figure 2. There was no recurrence 6 months after endoscopic submucosal dissection, with a healed scar and no appendiceal orifice.

for insufflation and prophylactic antibiotics. After submucosal injection of Glyceol (Chugai Pharmaceutical Co, Tokyo, Japan) (10% glycerol and 5% fructose in normal saline solution), mucosal incision and submucosal dissection were started from the anal side of the lesion using a DualKnife J (Olympus Co, Tokyo, Japan) with an electro-surgical generator (VIO3, ERBE, Tübingen, Germany, dry cut mode 2.0 and swift coagulation mode 3.5).

Submucosal dissection was performed to the area of the presumed appendiceal orifice, where benign-appearing submucosal fibrosis was noted. The most difficult aspect of submucosal dissection was to the appendiceal orifice. After circumferential submucosal dissection around the appendiceal orifice, and with appropriate patient repositioning, there was partial inversion of the appendix into the cecum aided by the weight and gravity of the mostly dissected tumor.

Because of difficulty dissecting the fibrotic submucosal layer in this narrow space, we injected a combination of Glyceol and sodium hyaluronic acid (MucoUp, Boston Scientific Japan, Tokyo, Japan) into the submucosal layer and switched to a HookKnife J (Olympus). Despite a challenging submucosal dissection into the appendix, at the most distal area of dissection, the mucosa in the appendix was incised from the submucosal layer, revealing normal appendix mucosa. The resection was completed successfully in 3 hours (Video 1, available online at giejournal.org) (Fig. 1B-D). Hemoclips were placed in the appendiceal orifice to prevent a delayed perforation. The patient tolerated the procedure well.

The patient was diagnosed with post-ESD cautery syndrome the day after the procedure and after perforation

and appendicitis were excluded. She managed with bowel rest and antibiotics for a few days, with rapid improvement. There were no other delayed adverse events or long-term adverse events.

Histopathology revealed R0 resection of a well-differentiated adenocarcinoma, pTis, Ly0, V0 (Fig. 1E),³ intramucosal cancer according to Vienna classification,⁴ which has no risk of lymph node metastasis. Additional surgical resection was not indicated. Surveillance colonoscopy at 6 months revealed a completely healed scar, no tumor recurrence, no ileocecal valve stenosis, and no evidence of the appendix orifice (Fig. 2).

In conclusion, we demonstrated successful resection of a large LST-G extending into the appendiceal orifice with an intact appendix via ESD, as well as the usefulness of a HookKnife in an area of challenging dissection. Despite the complexity of this less invasive treatment option, it should be considered as an acceptable organ-preserving option with acceptable risks when expertise is available, even in patients with an intact appendix.

DISCLOSURE

All authors disclosed no financial relationships.

Abbreviations: ESD, endoscopic submucosal dissection; LST-G, laterally spreading tumor-granular type.

REFERENCES

1. Horimatsu T, Fu KI, Sano Y, et al. Acute appendicitis as a rare complication after endoscopic mucosal resection. *Dig Dis Sci* 2007;52:1741-4.
2. Nemoto Y, Tokuhisa J, Shimada N, et al. Acute appendicitis following endoscopic mucosal resection of cecal adenoma. *World J Gastroenterol* 2015;21:8462-6.
3. Japanese Society for Cancer of the Colon and Rectum. Japanese Classification of Colorectal, Appendiceal, and Anal Carcinoma: the 3rd English Edition [Secondary Publication]. *J Anus Rectum Colon* 2019;30:175-95.
4. Schlemper RJ, Riddell RH, Kato Y, et al. The Vienna classification of gastrointestinal epithelial neoplasia. *Gut* 2000;47:251-5.

Department of Gastroenterology and Hepatology, Gunma University Graduate School of Medicine, Maebashi, Japan (1), Program in Endoscopic Oncology and Advanced Endoscopy, Riverside Regional Medical Center, Newport News, Virginia (2).

If you would like to chat with an author of this article, you may contact Dr Uraoka at uraoka@gunma-u.ac.jp.

Copyright © 2021 American Society for Gastrointestinal Endoscopy. Published by Elsevier Inc. This is an open access article under the CC BY-NC-ND license (<http://creativecommons.org/licenses/by-nc-nd/4.0/>).

<https://doi.org/10.1016/j.vgje.2021.07.004>