



Hydrocephalus following Brain Tumor Surgery: Factors Correlating with Occurrence of Postoperative Hydrocephalus and Predictive Scoring Model

Raweenut Beangklang^{1,2} Bunpot Sitthinamsuwan¹ Chottiwat Tansirisithikul¹ Sarun Nunta-aree¹

¹Division of Neurosurgery, Department of Surgery, Faculty of Medicine, Siriraj Hospital, Mahidol University, Bangkok, Thailand

²Department of Surgery, Buriram Hospital, Buriram, Thailand

Address for correspondence Bunpot Sitthinamsuwan, MD, Division of Neurosurgery, Department of Surgery, Faculty of Medicine, Siriraj Hospital, Mahidol University, 2 Wang Lang Road, Siriraj, Bangkok Noi, Bangkok 10700, Thailand (e-mail: bunpotsi@yahoo.com).

Asian J Neurosurg 2024;19:44–51.

Abstract

Hydrocephalus following brain tumor surgery is found, although cause of hydrocephalus is optimally eradicated. This study aimed to investigate factors associated with development of postoperative hydrocephalus that requires shunt procedure and generate predictive scoring model of this condition. Demographic, clinical, radiographic, treatment, laboratory, complication, and postoperative data were collected. Binary logistic regression was used to investigate final model for generating predictive scoring system of postoperative hydrocephalus. A total of 179 patients undergoing brain tumor surgery were included. Forty-five (25.1%) patients had postoperative hydrocephalus that required shunt surgery. In univariate analysis, several factors were found to be associated with postoperative hydrocephalus. Strong predictors of postoperative hydrocephalus revealed in multivariate analysis included tumor recurrence before surgery (odds ratio [OR], 4.38; 95% confidence interval [CI], 1.28–14.98; $p = 0.018$), preoperative hydrocephalus (OR, 6.52; 95% CI, 2.44–17.46; $p < 0.001$), glial tumor (OR, 3.76; 95% CI, 1.14–12.43; $p = 0.030$), metastasis (OR, 5.19; 95% CI, 1.72–15.69; $p = 0.004$), intraventricular hemorrhage (OR, 7.08; 95% CI, 1.80–27.82; $p = 0.005$), and residual tumor volume (OR, 1.05; 95% CI, 1.01–1.09; $p = 0.007$). A cutoff predictive score with the best area under curve and optimum cutoff point was utilized for discriminating patients with high risk from individuals with low risk in occurrence of postoperative hydrocephalus. This study reported predictive factors strongly associated with development of postoperative hydrocephalus. Predictive scoring system is useful for identifying patients with an increased risk of postoperative hydrocephalus. Patients classified in the high-risk group require closed surveillance of the hydrocephalus.

Keywords

- ▶ postoperative hydrocephalus
- ▶ brain tumor surgery
- ▶ incidence
- ▶ predictive factor
- ▶ predictive score

article published online
February 26, 2024

DOI <https://doi.org/10.1055/s-0044-1779345>.
ISSN 2248-9614.

© 2024. Asian Congress of Neurological Surgeons. All rights reserved.

This is an open access article published by Thieme under the terms of the Creative Commons Attribution-NonDerivative-NonCommercial-License, permitting copying and reproduction so long as the original work is given appropriate credit. Contents may not be used for commercial purposes, or adapted, remixed, transformed or built upon. (<https://creativecommons.org/licenses/by-nc-nd/4.0/>)

Thieme Medical and Scientific Publishers Pvt. Ltd., A-12, 2nd Floor, Sector 2, Noida-201301 UP, India

Introduction

Brain tumor is an entity of neurological disorders that causes disability and mortality if appropriate treatment is delayed. Various clinical manifestations are found in patients with brain tumors, including progressive headache, visual impairment, hearing deficit, seizure, behavioral changes, limb weakness, and gait disturbance. Surgical resection of the tumors with mass effect is still the essential treatment. Radiation therapy and chemotherapy are required in necessary cases.

Neurosurgical treatment of brain tumors aims to relieve neurological symptoms caused by intracranial mass lesion, improve quality of life and survival, reduce tumor burden prior to adjuvant therapy, and obtain tissue diagnosis.^{1,2} Even though craniotomy with brain tumor resection is the standard treatment of intracranial tumors, this procedure carries a surgical risk, such as postoperative intracranial hematoma, infection, or neurological deficits. Additionally, the surgery can affect cerebrospinal fluid (CSF) dynamics and cause permanent adverse alteration in CSF circulation which may result in postoperative hydrocephalus.^{1,3}

Hydrocephalus is a common neurological condition characterized by abnormal CSF accumulation in the intracranial cavity, mainly in the ventricular system. Patients with brain tumors often have hydrocephalus related to obstructive mechanism, but some patients suffer from communicating hydrocephalus. Although hydrocephalus in several cases will be resolved after tumor removal, some patients still have chronic persistent ventricular enlargement following appropriate surgical relief of CSF pathway obstruction.⁴

Heterogeneous incidence of hydrocephalus after brain tumor surgery has been reported, ranged from 7.3 to 46%.⁵⁻⁷ Studies on risk factors leading to permanent CSF diversion following intracranial tumor surgery are scarce. Generally, these risk factors include young age, extent of tumor resection, surgical exposure of the ventricle, tumor histopathology, and CSF infection.^{2,5-7}

The aim of this study was to investigate factors associating with postoperative hydrocephalus that needed CSF shunt implantation in patients undergoing brain tumor surgery. Besides, the final model of multivariate analysis was used to generate scoring system for predicting possibility of development of postoperative hydrocephalus.

Materials and Methods

Patient Population

This study included patients with brain tumors who underwent craniotomy and tumor resection at the Division of Neurosurgery, Department of Surgery, Faculty of Medicine Siriraj Hospital, Mahidol University from December 2017 to March 2020. Patients with CSF diversion procedures, such as ventriculoperitoneal (VP) shunting, lumboperitoneal shunting, endoscopic third ventriculostomy prior to the brain tumor surgery; patients who underwent craniotomy for other causes, such as vascular or traumatic cause; and

patients who underwent stereotactic or endoscopic procedures for the treatment of brain tumors were excluded from this study. The protocol for this study was approved by the Siriraj Institutional Review Board, Faculty of Medicine Siriraj Hospital, Mahidol University, Bangkok, Thailand.

Data Collection

The following data were collected, including demographic characteristics (age, gender, history of recurrent brain tumor) and clinical information (duration of presenting symptom, increased intracranial pressure [ICP], neurologic deficit, seizure, impairment of consciousness, cognitive impairment, and ataxia). Preoperative radiographic data obtained from cranial computerized tomography (CT) and/or magnetic resonance image (MRI) consisted of presence of hydrocephalus, ventricular Evans' index, tumor multifocality, tumor volume, tumor location, midline shift, peritumoral vasogenic brain edema, and pattern of tumor enhancement following contrast injection. In this study, hydrocephalus was defined as radiographic evidences of ventricular enlargement, including Evans' index more than 0.3, prominent temporal horns of the lateral ventricle more than or equal to 5 mm in axial images, dilatation of the third ventricle, stretching of the corpus callosum and septum pellucidum, and periventricular hypodensity on cranial CT or periventricular hyperintensity on cranial T2-weighted MRI or fluid-attenuated inversion recovery image.

Intraoperative findings and postoperative cranial radiographic images were reviewed to document the extent of tumor resection. The extent of tumor resection was classified as gross total (100%), subtotal (90–100%), and partial (less than 90%) tumor resection. Ventricular exposure was reviewed by using intraoperative record and postoperative neuroimaging. Data of other postoperative treatment modalities, including chemotherapy and radiation therapy, were also collected.

In patients with insertion of external ventricular drainage (EVD) catheter, intraoperative ICP, postoperative ICP, and the last 24-hour CSF output before removal of EVD catheter or before shunt surgery were recorded. CSF analysis was performed in most patients with EVD. Data of tumor histopathology reported by experienced pathologist were also gathered in statistical analysis.

In terms of postoperative data collection, they included postoperative complication, such as intracranial hemorrhage or meningitis. Data of residual tumor volume and location were obtained from postoperative cranial imaging study.

Outcome Measurement

Outcome of this study included incidence of overall and new-onset postoperative hydrocephalus that obligatorily required CSF shunt procedures. Importantly, factors predicting occurrence of postoperative hydrocephalus with shunt surgery in patients undergoing brain tumor resection were investigated. The new-onset postoperative hydrocephalus was defined as development of hydrocephalus on postoperative neuroimaging in patients without hydrocephalus on preoperative

neuroimaging. The criteria for consideration of shunt implantation in our study included as follows:

1. Presence of radiographic evidence of hydrocephalus on neuroimaging at least 2 weeks after appropriate brain tumor resection.
2. Persistent high CSF pressure more than 20 cmH₂O measured from EVD or lumbar puncture at least 2 weeks following the date of brain tumor surgery.
3. Presence of symptoms of hydrocephalus, such as headache, gait disturbance, impaired memory or cognitive function, during admission or in long-term follow-up.

Statistical Analysis

The collected data were analyzed by using the Statistical Package for the Social Sciences (SPSS) version 24.0. Numerical data were presented as either mean \pm standard deviation or median (range). In univariate analysis of association between the individual variable and occurrence of postoperative hydrocephalus which required shunt surgery, either Pearson's chi-square or Fisher's exact test was used for categorical data, and either independent sample t-test or Mann-Whitney U test was utilized for numerical data. The strength of association was calculated by using odds ratio (OR) and 95% confidence interval (95% CI). A *p*-value of less than 0.05 was signified as statistically significant level.

Regarding multivariate analysis of association between multiple investigated parameters and occurrence of hydrocephalus that required shunt surgery, variables with a *p*-value of less than 0.05 in univariate analysis were chosen. Multiple linear regression analysis was performed to investigate chosen variables with collinearity. Parameters showing collinearity that was defined as tolerance less than 0.2 and variance inflation factor more than 5 were excluded from binary logistic regression analysis. After the exclusion, the remaining parameters were analyzed using binary logistic regression. Backward (Wald) selection predictor criteria were used to determine the predictor in final model. Shrinkage factor and overestimation of the area under

receiver-operating characteristic curve (AuROC) were calculated via bootstrap internal validation. Discrimination and calibration were considered for model performance. The AuROC was used as the measure of model discrimination. The Hosmer-Lemeshow test and calibration curve, agreement between the predicted risk-score probabilities using the final model and the actual observed probabilities, were used to assess the model's calibration. A predictive scoring model was developed based on logistic regression coefficients with adjusted bootstrap internal validation from the final multivariate model.

Finally, the ROC curve was presented to demonstrate the performance of scoring predictive hydrocephalus for the best cutoff point in terms of sensitivity, specificity, positive predictive value (PPV), negative predictive value (NPV), positive likelihood ratio (LR+), negative likelihood ratio (LR-), and AuROC.

Results

The study included one-hundred and seventy-nine patients with brain tumor resection. There were 60 (33.5%) males and 119 (66.5%) females. The median age was 52 years (range: 0.2 to 82 years). Twenty-three (12.8%) patients underwent craniotomy for the treatment of recurrent brain tumor. The most common symptom was neurologic deficit found in 90 (50.3%) cases. Increased ICP was a common clinical manifestation found in 89 (49.7%). The median duration of symptom was 2 months (range: 1 day to 24 months). Tumor pathology included 69 (38.5%) meningiomas, 25 (14%) metastases, 25 (14%) vestibular schwannomas, 14 (7.8%) glioblastomas, and other 46 (25.7%) brain tumors.

On preoperative brain imaging, 81 (62.8%) individuals developed hydrocephalus prior to brain tumor surgery. The median preoperative ventricular Evans' index was 0.27 (range: 0.10–0.57) and the median tumor volume was 19.4 cm³ (range: 0.5–226 cm³). In univariate analysis (**Table 1**), history of recurrent brain tumor prior to the present surgery, duration of symptom, presence of

Table 1 Univariate analysis of association between parameters and postoperative hydrocephalus that required shunt surgery (*n* = 179)

Parameters	Postoperative hydrocephalus with shunt surgery		<i>p</i> -Value	OR (95% CI)
	Absent (<i>n</i> = 134)	Present (<i>n</i> = 45)		
Demographic characteristics (<i>n</i> = 179)				
Tumor recurrence before surgery, <i>n</i> (%)	11 (8.2)	12 (26.7)	0.001 ^a	4.07 (1.65–10.04)
Duration of symptom (months), median (range)	2 (0.03–24)	1 (0.06–12)	0.029 ^a	
Preoperative radiographic findings (<i>n</i> = 179)				
Preoperative hydrocephalus, <i>n</i> (%)	47 (35.1)	34 (75.6)	< 0.001 ^a	5.72 (2.66–12.32)
Preoperative Evans' index, median (range)	0.26 (0.10–0.57)	0.33 (0.14–0.43)	<0.001 ^a	
Intra-axial tumor location, <i>n</i> (%)	37 (27.6)	23 (51.1)	0.004 ^a	2.74 (1.37–5.50)
Subcortical to deep location of tumor, <i>n</i> (%)	28 (20.9)	21 (46.7)	0.001 ^a	3.31 (1.62–6.80)
Midline tumor location, <i>n</i> (%)	31 (23.1)	19 (42.2)	0.014 ^a	2.43 (1.19–4.96)

Table 1 (Continued)

Parameters	Postoperative hydrocephalus with shunt surgery		p-Value	OR (95% CI)
	Absent (n = 134)	Present (n = 45)		
Intraventricular tumor location, n (%)	14 (10.4)	11 (24.4)	0.019 ^a	2.77 (1.15–6.66)
Peritumoral vasogenic brain edema, n (%)	99 (73.9)	43 (95.6)	0.002 ^a	7.60 (1.75–33.03)
Heterogeneous tumor enhancement, n (%)	82 (61.2)	38 (84.4)	0.004 ^a	3.44 (1.43–8.28)
Treatments (n = 179, except for postoperative CSF pressure)				
Partial tumor resection, n (%)	11 (8.2)	11 (24.4)	0.004 ^a	3.62 (1.45–9.06)
Ventricular exposure, n (%)	14 (10.4)	13 (28.9)	0.003 ^a	3.48 (1.49–8.14)
Postoperative CSF pressure (cmH ₂ O), mean + SD (n = 68)	11.7 + 3.5	16.8 + 5	0.017 ^a	
Tumor pathology (n = 179)				
Glial tumor, n (%)	15 (11.2)	12 (26.7)	0.012 ^a	2.89 (1.23–6.76)
Meningioma, n (%)	58 (43.3)	11 (24.4)	0.025 ^a	0.42 (0.20–0.91)
Metastasis, n (%)	16 (11.9)	11 (24.4)	0.043 ^a	2.39 (1.01–5.62)
Postoperative complications (n = 179)				
Intraparenchymal hemorrhage, n (%)	5 (3.7)	7 (15.6)	0.012 ^a	4.75 (1.43–15.83)
Intraventricular hemorrhage, n (%)	6 (44.8)	11 (24.4)	< 0.001 ^a	6.90 (2.38–20.01)
Subdural hygroma, n (%)	12 (9)	0 (0)	0.039 ^a	N/C
Residual tumor (n = 179)				
Residual tumor volume (cm ³), median (range)	0 (0–57.2)	1.3 (0–80)	0.006 ^a	
Residual tumor in intra-axial location, n (%)	13 (9.7)	11 (24.4)	0.012 ^a	3.01 (1.24–7.32)
Residual tumor in subcortical to deep location, n (%)	9 (6.7)	8 (1.78)	0.039 ^a	3.00 (1.08–8.33)

Abbreviations: CI, confidence interval; CSF, cerebrospinal fluid; EVD, external ventricular drainage; n, number; N/C, not calculable; OR, odds ratio; SD, standard deviation.

^ap-Value < 0.05 indicates statistically significant association.

Factors not associated with postoperative hydrocephalus that required shunt surgery including

- Demographic characteristics (n = 179): age (p = 0.448), gender (p = 0.073), symptoms of increased intracranial pressure (p = 0.212), neurologic deficit (p = 0.212), seizure (p = 0.484), impaired consciousness (p = 0.281), cognitive impairment (p = 0.740), and ataxia (p = 0.240).
- Preoperative radiographic findings (n = 179): multifocal tumors (p = 0.061), tumor volume of resected tumor (p = 0.634), supratentorial tumor location (p = 0.129), infratentorial tumor location (p = 0.077), cortical tumor location (p = 1.000), and midline shift (p = 0.115).
- Treatments (n = 179, except for intraoperative CSF pressure and 24-hour CSF output): gross total tumor resection (p = 0.901), intraoperative CSF pressure (n = 51, p = 0.996), chemotherapy (p = 0.160), radiation therapy (p = 0.145), and 24-hour CSF output from EVD (n = 74, p = 0.133).
- CSF analysis (n = 72, except for CSF lactate): CSF red blood cell (p = 0.991), CSF white blood cell (p = 0.073), CSF protein (p = 0.693), CSF sugar (p = 0.501), and CSF lactate (n = 48, p = 0.673). CSF analysis was mostly performed within a week after brain tumor surgery.
- Tumor pathology (n = 179): vestibular schwannoma (p = 0.084) and hemangioblastoma (p = 0.320).
- Postoperative complications (n = 179): subarachnoid hemorrhage (p = 0.573), subdural hemorrhage (p = 1.000), meningitis (p = 0.681), pseudomeningocele (p = 0.357), and CSF leak (p = 0.573).
- Residual tumor (n = 179): presence of residual tumor (p = 0.239), residual tumor in supratentorial location (p = 0.869), residual tumor in infratentorial location (p = 0.080), residual tumor in cortical location (p = 0.370), residual tumor in midline location (p = 0.755), and residual tumor in intraventricular location (p = 0.120).

hydrocephalus on preoperative cranial imaging, greater preoperative ventricular Evans' index, intra-axial tumor, tumor arising in subcortical to deep location, tumor located in midline location, intraventricular tumor, peritumoral vasogenic brain edema, heterogeneous tumor enhancement following intravenous contrast injection, partial tumor resection, ventricular exposure, higher postoperative CSF pressure, glial tumor, tumor excluding meningioma, metastasis, intraparenchymal brain hemorrhage, intraventricular

hemorrhage, absence of subdural hygroma, higher residual tumor volume, residual tumor in intra-axial location, and subcortical to deep location were significantly associated with postoperative hydrocephalus which required shunt surgery.

Regarding hydrocephalus, 45 (25.1%) of 179 patients had postoperative hydrocephalus with shunt surgery. New-onset postoperative hydrocephalus was found in 11 (11.2%) of 98 patients without preoperative hydrocephalus. Of 81 patients

Table 2 Multivariate analysis for factors associated with postoperative hydrocephalus with shunt surgery

Parameters	Crude OR (95% CI)	p-Value	Adjusted OR (95% CI)	p-Value
Tumor recurrence before surgery	4.07 (1.65–10.04)	0.001 ^a	4.38 (1.28–14.98)	0.018 ^a
Preoperative hydrocephalus	5.72 (2.66–12.32)	< 0.001 ^a	6.52 (2.44–17.46)	< 0.001 ^a
Glial tumor	2.89 (1.23–6.76)	0.012 ^a	3.76 (1.14–12.43)	0.030 ^a
Metastasis	2.39 (1.01–5.62)	0.043 ^a	5.19 (1.72–15.69)	0.004 ^a
Intraventricular hemorrhage	6.90 (2.38–20.01)	< 0.001 ^a	7.08 (1.80–27.82)	0.005 ^a
Residual tumor volume	–	0.006 ^a	1.05 (1.01–1.09)	0.007 ^a

Abbreviations: CI, confidence interval; OR, odds ratio.

^ap-Value < 0.05 indicates statistically significant association.

who had preoperative hydrocephalus, 47 (58%) had complete relief of hydrocephalus following brain tumor surgery. Of 45 patients with shunt surgery, 43 (95.6%) and 2 (4.4%) underwent VP and lumboperitoneal shunt procedures, respectively. The median duration between brain tumor surgery and shunt procedure was 26.5 days (range: 7–1,182 days). There was no statistical difference in duration of EVD placement between the groups with and without postoperative hydrocephalus ($p = 0.480$).

In multivariate analysis, three factors, including tumor arising in intra-axial location, subcortical to deep location, and residual tumor in intra-axial location, had collinearity in linear regression analysis. Therefore, they were excluded from binary regression analysis. Binary logistic regression model showed that tumor recurrence before surgery (OR, 4.38; 95% CI, 1.28–14.98; $p = 0.018$), preoperative hydrocephalus (OR, 6.52; 95% CI, 2.44–17.46; $p < 0.001$), glial tumor (OR, 3.76; 95% CI, 1.14–12.43; $p = 0.030$), metastasis (OR, 5.19; 95% CI, 1.72–15.69; $p = 0.004$), intraventricular hemorrhage (OR, 7.08; 95% CI, 1.80–27.82; $p = 0.005$), and residual tumor volume (OR, 1.05; 95% CI, 1.01–1.09; $p = 0.007$) were significantly associated with occurrence of postoperative hydrocephalus which required shunt surgery (►Table 2). The ROC curve of binary logistic regression model is presented in ►Fig. 1 (AuROC, 0.871; 95% CI, 0.81–0.93; $p < 0.001$).

The Hosmer–Lemeshow test and calibration curve are presented in ►Fig. 2. The final model included six factors (5 qualitative factors and 1 quantitative factor). A scoring system for prediction of development of postoperative shunt-dependent hydrocephalus was generated and is demonstrated in ►Table 3. The optimum cutoff score for discriminating a high and low probability of postoperative hydrocephalus was 5. This cutoff score showed the best AuROC (0.78) and the optimum value of sensitivity (73.3%), specificity (82.8%), with a PPV of 58.9, NPV of 90.2, LR+ of 4.27, and LR– of 0.32 (►Table 4).

Discussion

Hydrocephalus is a common neurological condition coexisting with intracranial tumors. It can occur as a result of the tumors or can be encountered as a consequence following surgical treatment of brain tumors. Several brain tumors

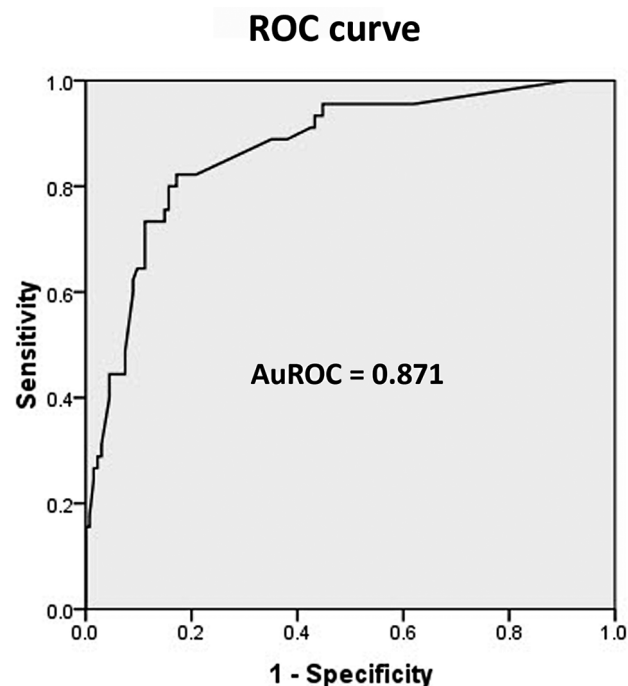


Fig. 1 The receiver-operating characteristic (ROC) curve of binary logistic regression showing area under the ROC curve (AuROC) = 0.871; 95% confidence interval [CI], 0.81–0.93; $p < 0.001$.

bring about significant mass effect, obstruction of intracranial CSF pathway, or elevated ICP. These sequelae negatively impact to cerebral venous outflow and intracranial hemodynamics, and then may result in development of hydrocephalus. Some patients without preoperative hydrocephalus or increased ICP may develop new-onset hydrocephalus after surgery of the tumors, although mass effect caused by the tumors is surgically treated.⁵

Incidence of hydrocephalus in patients with brain tumors varies from study to study. Fischer et al reported that 7.3% of patients with glioblastoma developed postoperative hydrocephalus and required VP shunt implantation.⁶ In regard to meningioma, Tahara et al found higher incidence of hydrocephalus associated with petroclival and posterior cranial fossa meningiomas, accounting for 13.3 and 16.6%, respectively.⁸ Postoperative hydrocephalus following surgery of pediatric posterior cranial fossa tumors was encountered in 28.6 to 46% of patients.^{7,9} Our study showed a relatively

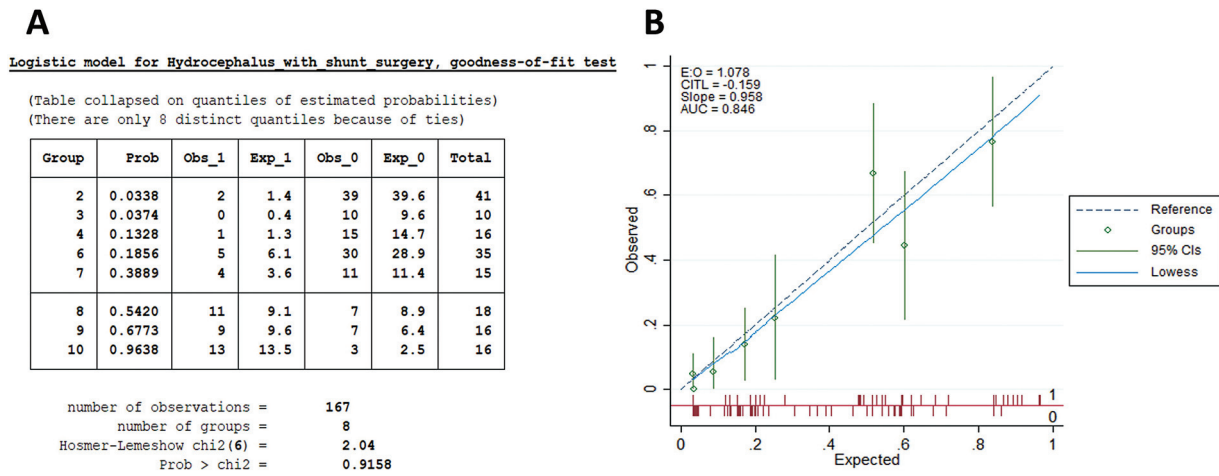


Fig. 2 The Hosmer–Lemeshow test (A) and calibration curve (B) for the assessment of the model’s calibration. AUC, area under the curve; CI, confidence interval.

Table 3 Predictive scores of postoperative hydrocephalus requiring shunt procedure

Parameters	Score
Tumor recurrence before surgery	
Absent	0
Present	2
Preoperative hydrocephalus	
Absent	0
Present	3
Glial tumor	
No	0
Yes	2
Metastasis	
No	0
Yes	3
Intraventricular hemorrhage	
Absent	0
Present	3
Residual tumor volume (cm ³)	Volume (cm ³)/10 × 1

Total predictive score ≥ 5 indicating high probability of postoperative hydrocephalus.

Table 4 ROC curve analysis

Cutoff total predictive score	Sensitivity (%)	Specificity (%)	PPV	NPV	LR+	LR–	AuROC (95% CI)
≥ 3	91.1	53	39.4	94.7	1.94	0.17	0.72 (0.66–0.78)
≥ 4	75.6	81.3	57.6	90.8	4.05	0.30	0.78 (0.71–0.86)
≥ 5	73.3	82.8	58.9	90.2	4.27	0.32	0.78 (0.71–0.85)
≥ 6	60	90.3	67.5	87.1	6.18	0.44	0.75 (0.67–0.83)

Abbreviations: AuROC, area under receiver operating characteristic curve; LR –, negative likelihood ratio; LR +, positive likelihood ratio; NPV, negative predictive value; PPV, positive predictive value.

high incidence of preoperative hydrocephalus (45.3%). Shunt-dependent postoperative hydrocephalus was found in 25.1% of total cases. Preexisting hydrocephalus is likely to be cured with eradication of intracranial mass lesion. In our patients with preoperative hydrocephalus, most of them (58%) gained complete relief of hydrocephalus after brain tumor resection. In the literature review, new-onset postoperative hydrocephalus was found in 5.9 to 8% of patients.^{5,10} This study showed that 11 of 98 patients (11.2%) without preoperative hydrocephalus develop de novo postoperative hydrocephalus. Most of new-onset postoperative hydrocephalus often develops in the acute postoperative period¹¹ we also found the same result and all of them required shunt operations in subsequent period.

Regarding univariate analysis of this study, several variables were associated with occurrence of shunt-dependent postoperative hydrocephalus. Recurrent brain tumor was a significant factor associated with postoperative hydrocephalus. Our result corresponded with a study conducted by Montano et al.³ They reported that all of 45 glioblastoma patients who underwent twice craniotomies or more significantly developed postoperative hydrocephalus ($p = 0.0006$). Patients with recurrent brain tumors carry a greater risk of occurrence of hydrocephalus. Adhesion of the arachnoid mater over the surface of the brain and in the basal cistern likely plays a major role as a cause of hydrocephalus.⁵

Presence of preoperative hydrocephalus represented by ventricular enlargement and high ventricular Evans' index was strongly associated with development of postoperative hydrocephalus in both univariate and multivariate analyses. Patients with preexisting hydrocephalus may have persistent ventricular enlargement although potential causes of hydrocephalus are adequately treated. This phenomenon is possibly caused by chronic disturbance of CSF dynamics and impaired compliance of the ventricular wall.

A study showed a higher risk of postoperative shunting in patients with brain tumors involving the midline structures.¹² We also found the similar outcome in univariate analysis of preoperative brain imaging. Tumor arising in the midline location, intraventricular location, presence of vasogenic brain edema around the tumors, and heterogeneous contrast enhancement of the neoplastic lesions significantly increased risk of postoperative hydrocephalus. Nevertheless, these parameters had no significant association in multivariate analysis.

In terms of treatment of brain tumors, partial tumor resection and greater volume of residual tumor significantly increased risk of postoperative hydrocephalus. Extent of tumor resection was an important factor in prediction of requirement of postoperative shunt implantation as reported in several studies.^{7,9,13} Therefore, an attempt of complete tumor resection is helpful to diminish risk of postoperative hydrocephalus and shunt requirement. Radiation therapy is a major factor influencing development of hydrocephalus following surgical treatment of various types of brain tumor,^{5,6} but not in our study. Function of intracranial structures is changed by radiation effects. Fibrosis of arachnoid granulation and alteration of cerebral vascular tissue subsequently result in progressive hydrocephalus.¹⁴

In some patients undergoing brain tumor resection, the cerebral ventricle can be unintentionally exposed during surgery. When the ventricle is opened, protein and blood precipitate from surgical site enter the ventricular system, and could result in impaired CSF absorption, leading to the onset of communicating hydrocephalus.⁶ Ventricular exposure was a significant variable associating with postoperative hydrocephalus in our univariate analysis, but not in multivariate analysis.

A study of Kazan et al showed a correlation between longer duration of increased ICP symptoms and requirement of postoperative VP shunt implantation. Also, patients with higher postoperative ICP had a higher rate of shunt dependence.⁹ We found similar result in univariate analysis, but not in multivariate analysis. On the other hand, intraoperative ICP, duration of EVD placement, and results of CSF profile study were not associated with postoperative hydrocephalus; these results were consistent with a study of Kumar et al.¹³

This study showed that glial tumor and brain metastasis were major factors predicting occurrence of postoperative hydrocephalus, whereas patients with meningiomas were unlikely to develop the hydrocephalus. Incidence of postoperative hydrocephalus in glioma patients was 7.3% and leptomeningeal dissemination of the tumor is a predictive factor of the hydrocephalus.⁶ The majority of hydrocephalus

in brain metastasis is found to be coincide with leptomeningeal metastasis and the metastatic lesions are usually multiple or located in deep-seated location where surgical removal could be incomplete. Metastatic tumor cells and high protein level in CSF have major role in impairment of CSF absorption and eventual occurrence of hydrocephalus.^{15,16} Furthermore, choroid plexus tumor and craniopharyngioma usually extend into the ventricular compartments, and ventricular approach for removing these tumors has an increased risk of postoperative hydrocephalus.¹¹

Intraventricular hemorrhage after brain tumor resection was a strong predictor of shunt-dependent hydrocephalus in our study. Blood products clog the arachnoid villi, obstruct the CSF pathway, bring about inflammation and scar formation of the CSF cisterns, and eventually result in development of postoperative hydrocephalus.¹⁷ By the way, some studies including ours reported incoherence between CSF infection, CSF leak, and requirement of shunt placement.^{6,9} On the contrary, some authors showed an increased risk of hydrocephalus in patients with postoperative CSF infection. Meningitis causes acutely elevated ICP, scar formation of the CSF cisterns, and arachnoid granulation, leading to functional impairment of CSF circulation, absorption, and development of hydrocephalus.⁵

Finally, the authors created a scoring model for predicting chance of development of postoperative hydrocephalus. The ROC curve was presented to demonstrate the performance of predictive scores for analysis of the most appropriate cutoff score. The predictive scores are useful for investigating patients who have a great risk in occurrence of postoperative hydrocephalus and predicting requirement of CSF shunt procedure in the future. Moreover, the scoring system is helpful to identify patients who need closed clinical and radiographic surveillances of postoperative hydrocephalus. Based on data in this study, the appropriate period of closed surveillance for development of hydrocephalus in the high-risk patients should be at least 1 year after brain tumor surgery.

The strengths and limitations of this study should be mentioned. In terms of the strengths, our study included patients with clear definition of hydrocephalus and certain indications of shunt placement for the treatment of hydrocephalus after brain tumor surgery. In addition, the predictive scoring model showed predictive scores and optimum cutoff point that was helpful for identifying brain tumor patients with high risk for developing postoperative hydrocephalus. On the other hand, the major limitations of the study were heterogeneities in patients' age, tumor location, and pathology. Differences of age, tumor location, and pathology may influence the occurrence of hydrocephalus after brain tumor surgery. Additionally, our study was conducted retrospectively, and some data were unavailable in some patients. For example, CSF analysis was not routinely performed, and its data was available in 72 of 179 patients. However, we tried to collect and verify the data for reducing the bias. Furthermore, in a rare number of patients with hydrocephalus, the duration between brain tumor surgery and shunt placement was more than 2 years. In such cases,

the occurrence of hydrocephalus might be caused by other etiologies, such as normal pressure hydrocephalus in elderly patients.

Conclusions

Incidence of postoperative hydrocephalus was 25.1% of patients undergoing brain tumor surgery. The strong predictors of postoperative hydrocephalus that needed shunt procedure included recurrent tumor before brain tumor surgery, preoperative hydrocephalus, glial tumor, brain metastasis, intraventricular hemorrhage, and residual tumor volume. Predictive scores using optimum cutoff point are useful for detecting patients susceptible to develop postoperative hydrocephalus. Closed surveillance of clinical and radiographic status of hydrocephalus in high-risk patients should be advocated, and CSF shunt procedure is considered when obvious evidence of hydrocephalus is encountered.

Authors' Contributions

R.B. was involved in development or design of methodology, project administration, software, investigation, data collection, formal analysis, visualization, writing—original draft preparation, and approval of the final manuscript. B. S. contributed to conceptualization, development or design of methodology, supervision, formal analysis, writing—reviewing and editing, corresponding author, and approval of the final manuscript. C.T. was involved in writing—reviewing and editing, and approval of the final manuscript. S.N. helped in conceptualization, supervision, writing—reviewing and editing, and approval of the final manuscript.

Ethical Approval

This study was approved by the Ethics Committee of the Faculty of Medicine Siriraj Hospital, Mahidol University, Thailand; Certificate of Approval (COA) number SI 753/2017. All the patients' data retained full confidentiality in compliance with the Declaration of Helsinki.

Conflict of Interest

None declared.

Acknowledgement

The authors thank Orawan Supapueng, of the Clinical Epidemiology Unit, Office for Research and Development, Faculty of Medicine, Siriraj Hospital, Mahidol University, Bangkok, Thailand for her statistical support.

References

- Lassen B, Helseth E, Rønning P, et al. Surgical mortality at 30 days and complications leading to reoperation in 2630 consecutive craniotomies for intracranial tumors. *Neurosurgery* 2011;68(05):1259–1268, discussion 1268–1269
- McGirt MJ, Chaichana KL, Gathinji M, et al. Independent association of extent of resection with survival in patients with malignant brain astrocytoma. *J Neurosurg* 2009;110(01):156–162
- Montano N, D'Alessandris QG, Bianchi F, et al. Communicating hydrocephalus following surgery and adjuvant radiochemotherapy for glioblastoma. *J Neurosurg* 2011;115(06):1126–1130
- Ding J, Guo Y, Tian H. The influence of decompressive craniectomy on the development of hydrocephalus: a review. *Arq Neuropsiquiatr* 2014;72(09):715–720
- Duong DH, O'malley S, Sekhar LN, Wright DG. Postoperative hydrocephalus in cranial base surgery. *Skull Base Surg* 2000;10(04):197–200
- Fischer CM, Neidert MC, Péus D, et al. Hydrocephalus after resection and adjuvant radiochemotherapy in patients with glioblastoma. *Clin Neurol Neurosurg* 2014;120:27–31
- Aljoubour R, Alomari A, Musharbash A. Risk factors for ventriculoperitoneal shunting in children with posterior fossa tumor. *J Royal Med Serv* 2017;24(01):45–49
- Tahara A, de Santana PA Jr, Calfat Maldaun MV, et al. Petroclival meningiomas: surgical management and common complications. *J Clin Neurosci* 2009;16(05):655–659
- Kazan S, Acikbas C, Demirez I, Tuncer R, Saveren M. The factors required for V-P shunting in children with posterior fossa tumors. *Turk Neurosurg* 1998;8:71–75
- Burkhardt JK, Zinn PO, Graenicher M, et al. Predicting postoperative hydrocephalus in 227 patients with skull base meningioma. *Neurosurg Focus* 2011;30(05):E9
- Hosainey SAM, Lassen B, Hald JK, Helseth E, Meling TR. Risk factors for new-onset shunt-dependency after craniotomies for intracranial tumors in adult patients. *Neurosurg Rev* 2018;41(02):465–472
- Culley DJ, Berger MS, Shaw D, Geyer R. An analysis of factors determining the need for ventriculoperitoneal shunts after posterior fossa tumor surgery in children. *Neurosurgery* 1994;34(03):402–407, discussion 407–408
- Kumar V, Phipps K, Harkness W, Hayward RD. Ventriculo-peritoneal shunt requirement in children with posterior fossa tumours: an 11-year audit. *Br J Neurosurg* 1996;10(05):467–470
- Thiessen B, DeAngelis LM. Hydrocephalus in radiation leukoencephalopathy: results of ventriculoperitoneal shunting. *Arch Neurol* 1998;55(05):705–710
- Taillibert S, Laigle-Donadey F, Chodkiewicz C, Sanson M, Hoang-Xuan K, Delattre JY. Leptomeningeal metastases from solid malignancy: a review. *J Neurooncol* 2005;75(01):85–99
- Lee SH, Kong DS, Seol HJ, Nam DH, Lee JI. Ventriculoperitoneal shunt for hydrocephalus caused by central nervous system metastasis. *J Neurooncol* 2011;104(02):545–551
- Fuhrmeister U, Ruether P, Dommasch D, Gaab M. Alterations of CSF hydrodynamics following meningitis and subarachnoid hemorrhage. In: Shulman K, Marmarou A, Miller JD, Becker DP, Hochwald GM, Kasner M, eds. *Intracranial Pressure IV*. New York: Springer-Verlag; 1980:241–244