

ORIGINAL ARTICLE

Atlas for the OMERACT thumb
base osteoarthritis MRI scoring
system (TOMS)

Féline P B Kroon,¹ Charles G Peterfy,² Philip G Conaghan,³ Violaine Foltz,⁴
Frédérique Gandjbakhch,⁴ Iris Eshed,⁵ Harry K Genant,^{6,7} Mikkel Østergaard,^{8,9}
Monique Reijnierse,¹⁰ Johan L Bloem,¹⁰ Ida K Haugen,¹¹ Margreet Kloppenburg^{1,12}

To cite: Kroon FPB, Peterfy CG, Conaghan PG, *et al.* Atlas for the OMERACT thumb base osteoarthritis MRI scoring system (TOMS). *RMD Open* 2018;**4**:e000583. doi:10.1136/rmdopen-2017-000583

► Prepublication history for this paper is available online. To view these files, please visit the journal online (<http://dx.doi.org/10.1136/rmdopen-2017-000583>).

Received 21 September 2017

Revised 28 November 2017

Accepted 1 December 2017

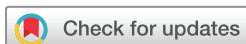ABSTRACT

This paper presents an atlas for the Outcome Measures in Rheumatology Clinical Trials (OMERACT) thumb base osteoarthritis MRI scoring system (TOMS). The atlas includes reference images of each grade of each feature that is assessed in TOMS (synovitis grade 0–3, subchondral bone defects grade 0–3, osteophytes grade 0–3, cartilage assessment grade 0–3, subluxation and bone marrow lesions grade 0–3) in the first carpometacarpal and scapho-trapezio-trapezoid joint. The presented reference images can be used to guide scoring of thumb base MRIs in patients with hand osteoarthritis according to the OMERACT TOMS.

Hand OA affects the interphalangeal and thumb base joints, including the CMC-1 and STT joints. Much is still unknown about the pathophysiology of thumb base OA. Although MRI studies have led to more insights in interphalangeal OA, thumb base MRI studies are still lacking. To facilitate this, recently the first MRI scoring system for thumb base OA was developed

by the OMERACT MRI Working Group, the TOMS.¹

Representative examples of each grade of the different features that are assessed in the TOMS are presented (see [table 1](#) for definitions and scaling of each feature). Images from patients with hand OA were obtained from the Hand Osteoarthritis in Secondary Care (HOSTAS) study at Leiden University Medical Center (Leiden, The Netherlands). Images were acquired on a 1.5 T extremity MRI unit (ONI, GE, Wisconsin, USA). Examples of synovitis evaluated on contrast-enhanced images were obtained from patients with hand OA from the Nor-Hand study at Diakonhjemmet Hospital (Oslo, Norway) and were acquired on a 1.5 T MRI unit (Siemens Aera, Germany) after administration of gadolinium contrast. Example images were selected by a single reader with experience in using the TOMS and subsequently approved by three experienced radiologists (of which one is also experienced in using the score).



For numbered affiliations see end of article.

Correspondence to

Féline P B Kroon;
f.kroon.reum@lumc.nl

Table 1 Definitions and scaling of features in proposed OMERACT TOMS

| MRI feature | Definition | Scaling | Suggested plane and MRI sequence |
|---------------------------|--|--|--|
| Synovitis† | Thickened synovium with enhancement after Gd injection. | 0=normal; 1=mild (1%–33%); 2=moderate (34%–66%); 3=severe (67%–100%). Based on thirds of the presumed maximum thickness of enhancing tissue in the synovial compartment. | Coronal and axial. T1w pre-Gd and post-Gd with fs. In the absence of post-Gd images T2w-fs/STIR/PD-fs can be used. |
| Subchondral bone defects‡ | Subchondral bone loss, including erosions (sharply marginated bone lesions with cortical break), cysts (sharply marginated bone lesions without cortical break) and bone attrition (diffuse loss of bone contour). | 0=no bone defects; 1=mild ($\leq 25\%$ of bone volume or joint surface affected); 2=moderate (26%–50% of bone volume or joint surface affected); 3=severe ($>50\%$ of bone volume or joint surface affected). | Coronal and axial. T1w and T2w-fs/STIR/PD-fs. |
| Osteophytes‡ | Abnormal bone protuberance at joint margins or surfaces. | 0=no osteophytes; 1=mild (1–2 small osteophytes); 2=moderate (≥ 3 small osteophytes and/or ≥ 1 moderate osteophyte(s)); 3=severe (≥ 1 large osteophyte(s)). | Coronal (and sagittal if available). T1w. |
| Cartilage assessment | Loss of cartilage or loss of cartilage space based on the interbone distance¶]. | 0=no loss of cartilage or cartilage space; 1=mild (cartilage loss without complete denuding, or cartilage space loss without bone-to-bone contact); 2=moderate (cartilage loss with denuding $\leq 50\%$ of joint surface or focal complete cartilage space loss with bone-to-bone contact $\leq 50\%$ of the articulating area); 3=severe (cartilage loss with denuding $>50\%$ of joint surface or complete cartilage space loss over $>50\%$ of the articulating area). | Coronal. T1w-fs-3D-GE, otherwise use T1w-fs, T2w-fs or PD-fs. |
| Subluxation§ | Subluxation of the CMC-1 joint in the frontal plane. | 0=MC-1 subluxed 0%–25% of the MC-width; 1=MC-1 subluxed $\geq 26\%$ of the MC-width. | Coronal. T1w. |
| Bone marrow lesions‡ | Lesions within the trabecular bone with signal characteristic consistent with increased water content** and with ill-defined margins. | 0=no bone marrow lesions; 1=mild (1%–33% bone volume); 2=moderate (34%–66% bone volume); 3=severe (67%–100% bone volume). | Coronal and axial. T2w-fs/STIR/PD-fs. |

Table was reprinted with permission from Kroon *et al.*¹ All rights reserved.

†In longitudinal studies, 0.5 increments can be included to indicate within-grade change in synovitis, subchondral bone defects and bone marrow lesions.

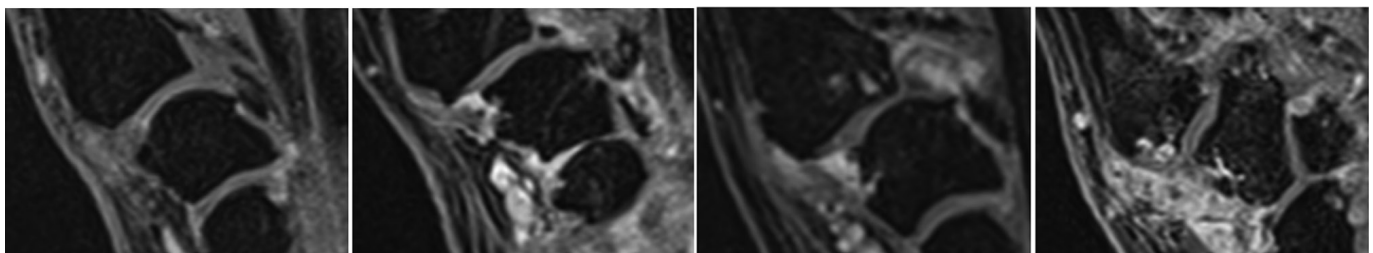
‡Proximal and distal parts of joint are scored separately for subchondral bone defects, osteophytes and bone marrow lesions.

§Only the CMC-1 joint is evaluated for this feature.

¶If assessment of cartilage and cartilage space are in conflict, direct visualisation of the cartilage should be prioritised.

**High signal intensity on STIR/T2w-fs images.

CMC-1, first carpometacarpal; fs, fat saturated; Gd, gadolinium-based contrast agent; GE, gradient echo; MC-1, first metacarpal; PD, proton density; OA, osteoarthritis; OMERACT, Outcome Measures in Rheumatology Clinical Trials; STIR, Short T1 Inversion Recovery; STT, scapho-trapezio-trapezoid; TOMS, thumb base OA MRI scoring system; w, weighted.



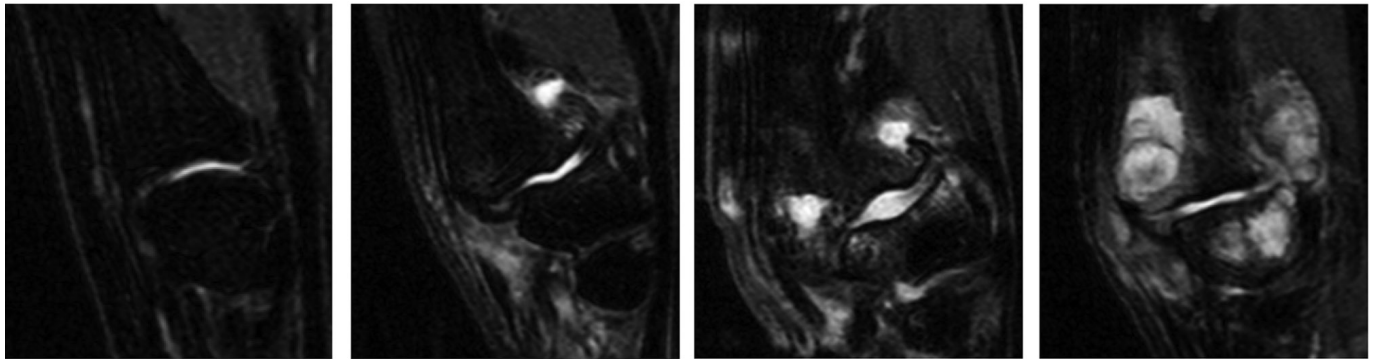
Normal

Grade 1

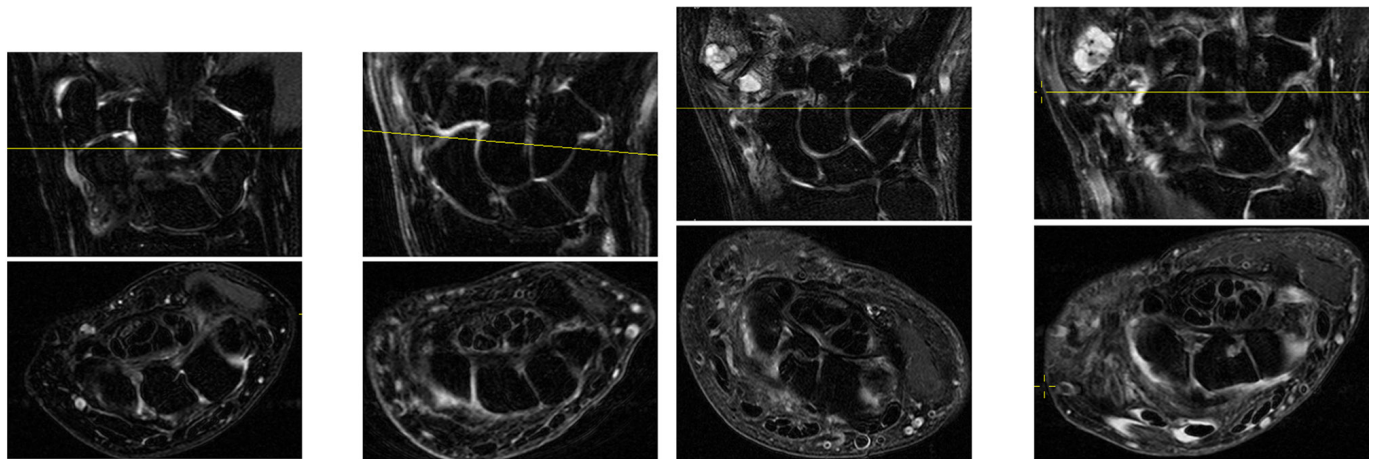
Grade 2

Grade 3

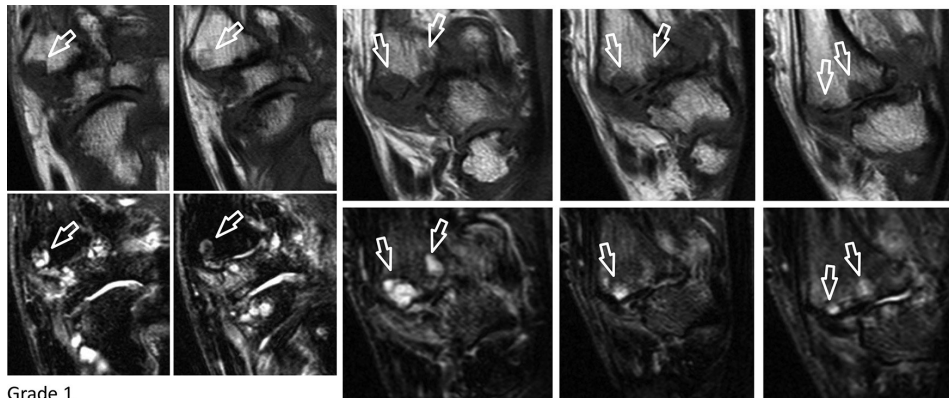
Synovitis first carpometacarpal (T1 weighted-fat saturated postcontrast images).



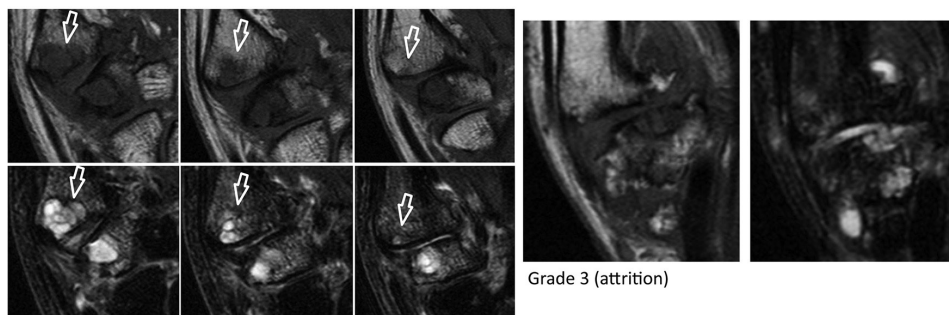
Normal Grade 1 Grade 2 Grade 3
Synovitis first carpometacarpal (T2 weighted-fat saturated images).



Normal Grade 1 Grade 2 Grade 3
Synovitis scapho-trapezio-trapezoid (T2 weighted-fat saturated images).

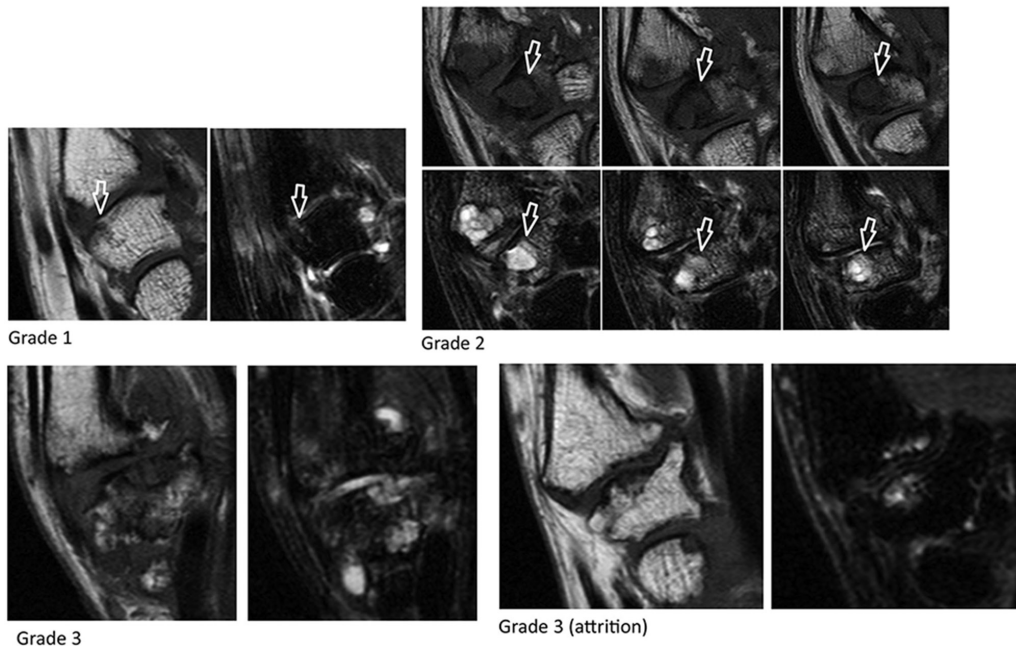


Grade 1 Grade 2

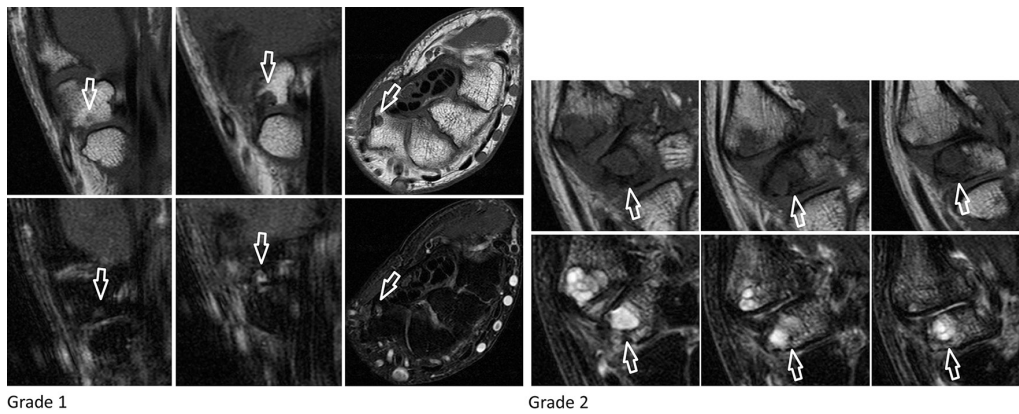


Grade 3 Grade 3 (attrition)

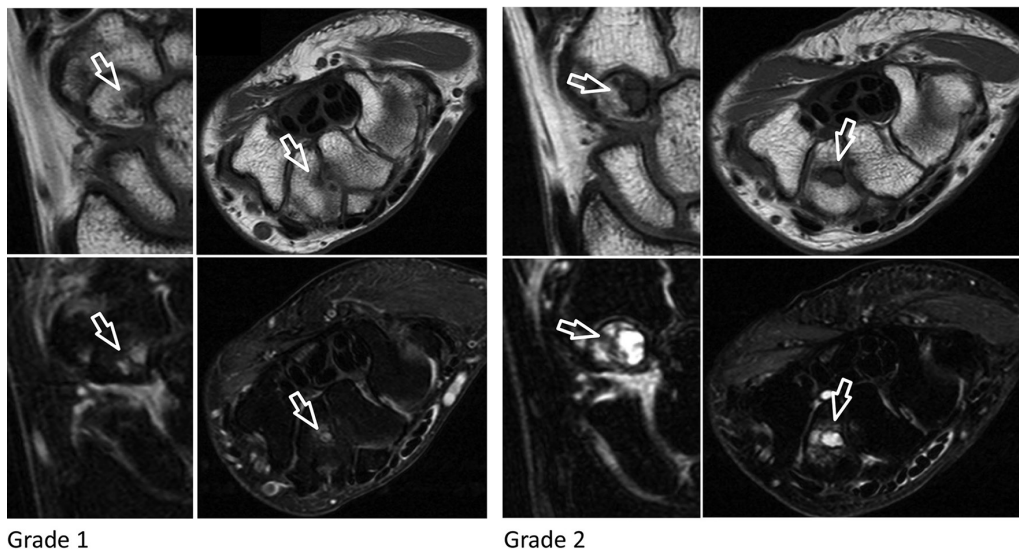
Subchondral bone defects first carpometacarpal: proximal first metacarpal (T1 weighted and T2 weighted-fat saturated images).



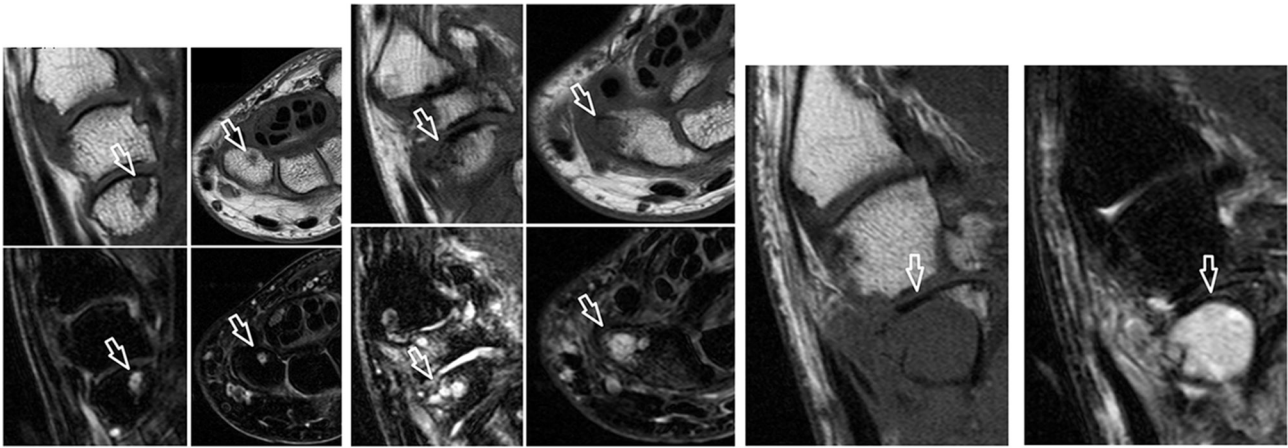
Subchondral bone defects first carpometacarpal: distal trapezium (T1 weighted and T2 weighted-fat saturated images).



Subchondral bone defects scapho-trapezio-trapezoid: proximal trapezium (T1 weighted and T2 weighted-fat saturated images).



Subchondral bone defects scapho-trapezio-trapezoid: proximal trapezoid (T1 weighted and T2 weighted-fat saturated images).

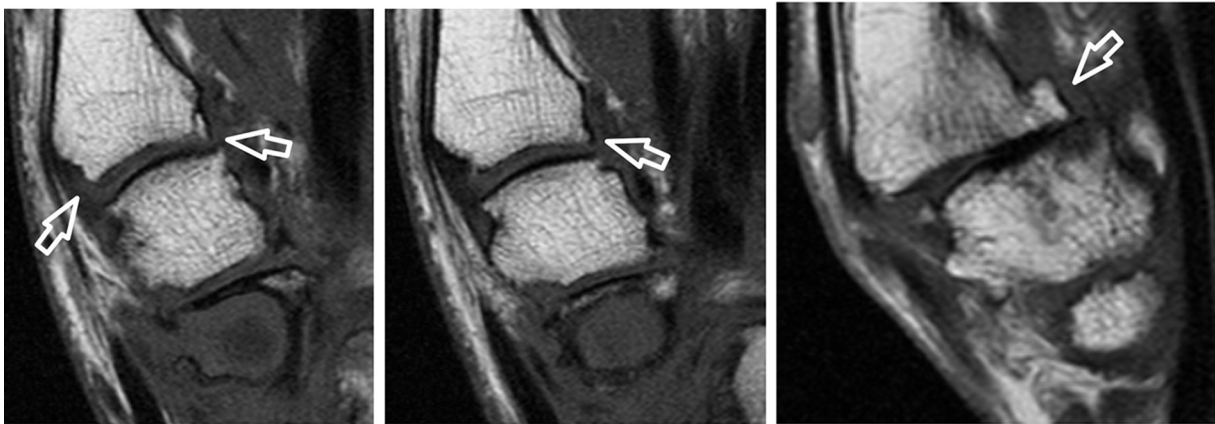


Grade 1

Grade 2

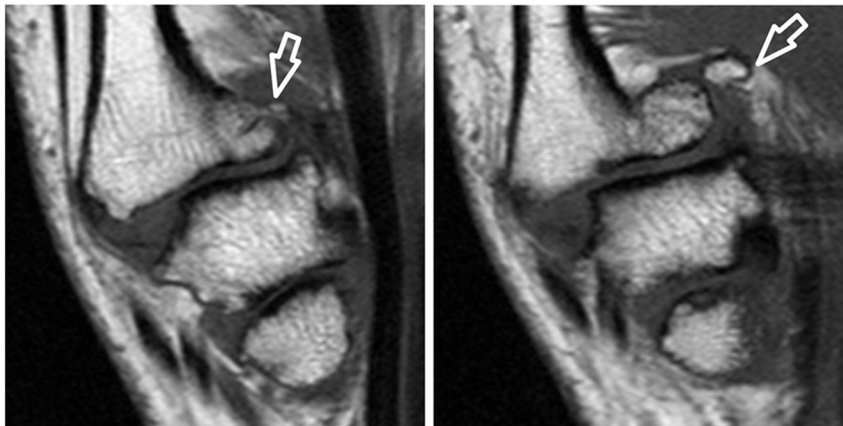
Grade 3

Subchondral bone defects scapho-trapezio-trapezoid: distal scaphoid (T1 weighted and T2 weighted-fat saturated images).



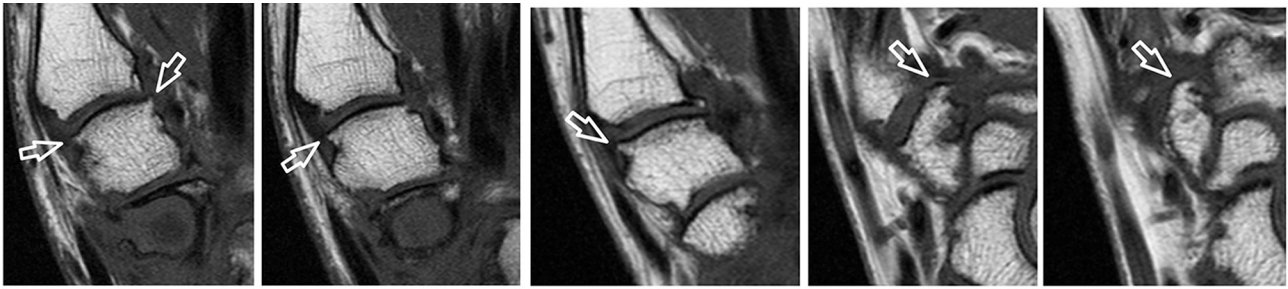
Grade 1

Grade 2



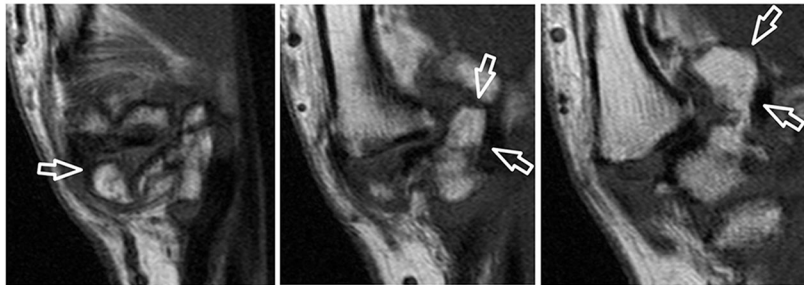
Grade 3

Osteophytes first carpometacarpal: proximal first metacarpal (T1 weighted images).



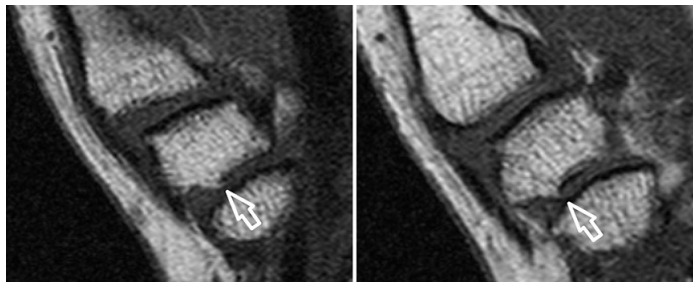
Grade 1

Grade 2

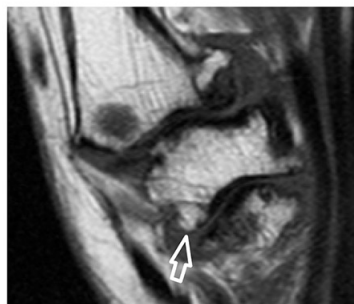

Grade 3

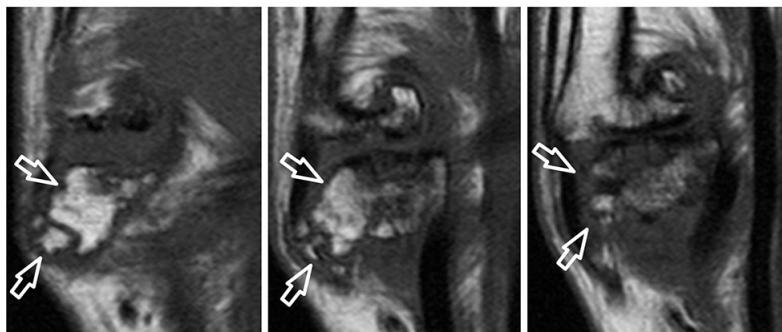
Osteophytes first carpometacarpal: distal trapezium (T1 weighted images).



Grade 1

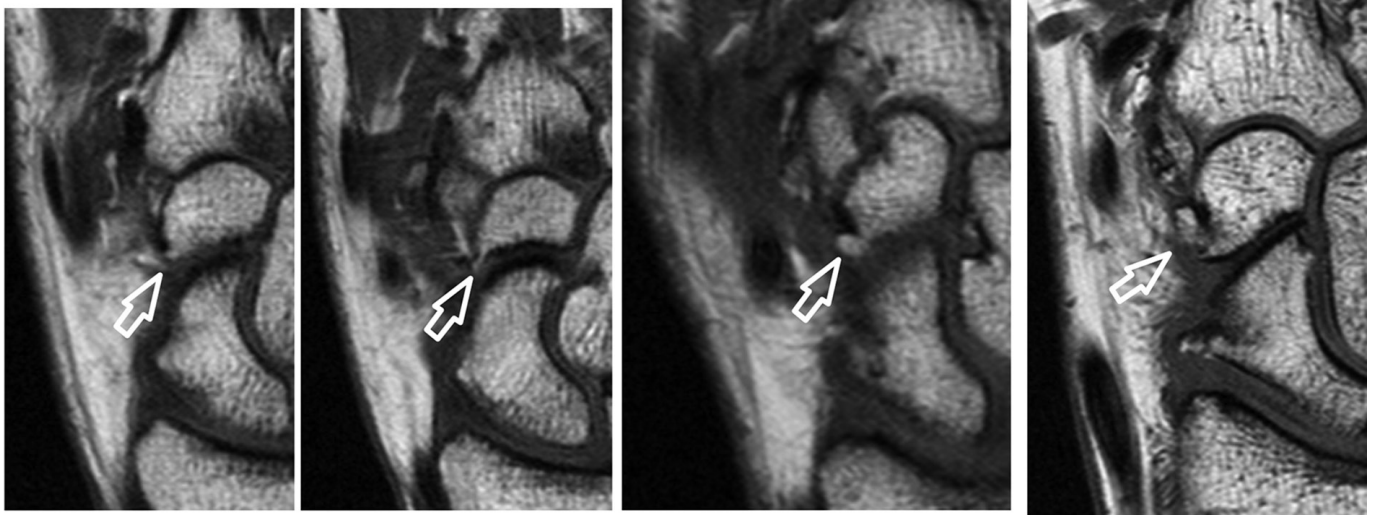


Grade 2



Grade 3

Osteophytes scapho-trapezio-trapezoid: proximal trapezium (T1 weighted images).

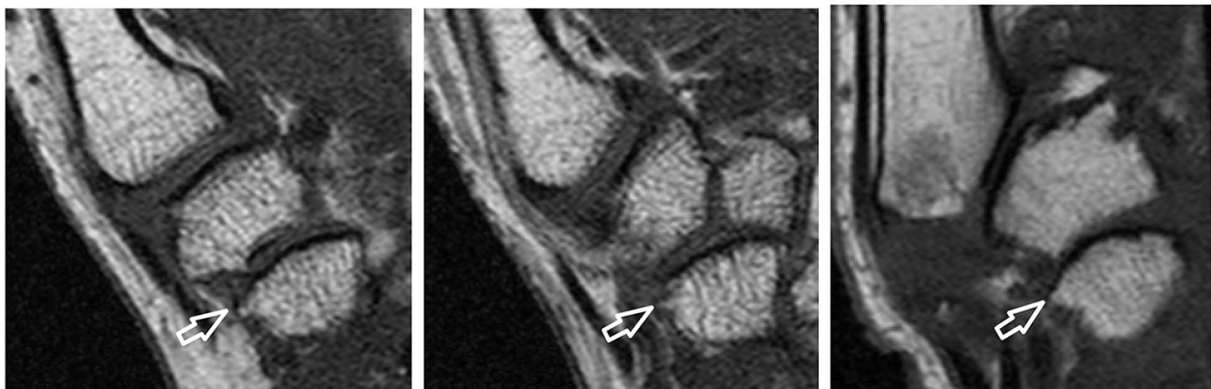

Grade 1

Grade 2

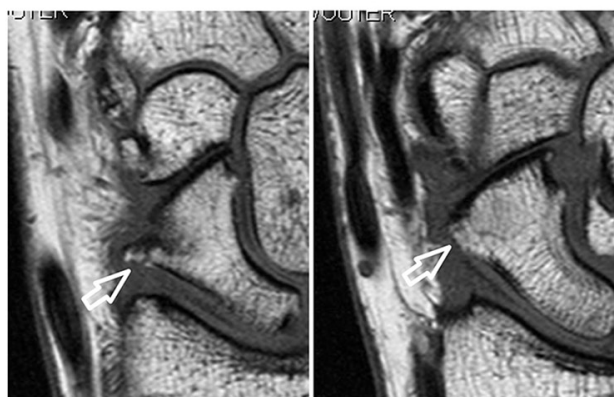
Grade 3

Osteophytes scapho-trapezio-trapezoid: proximal trapezoid (T1 weighted images).



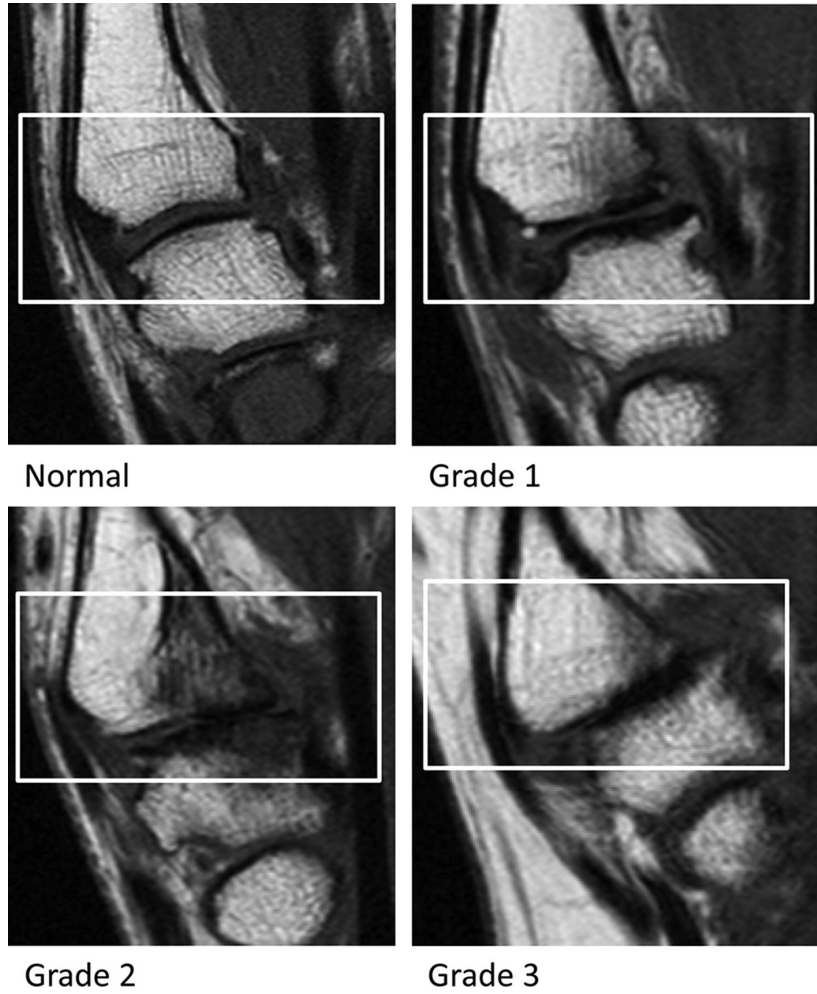
Grade 1

Grade 2

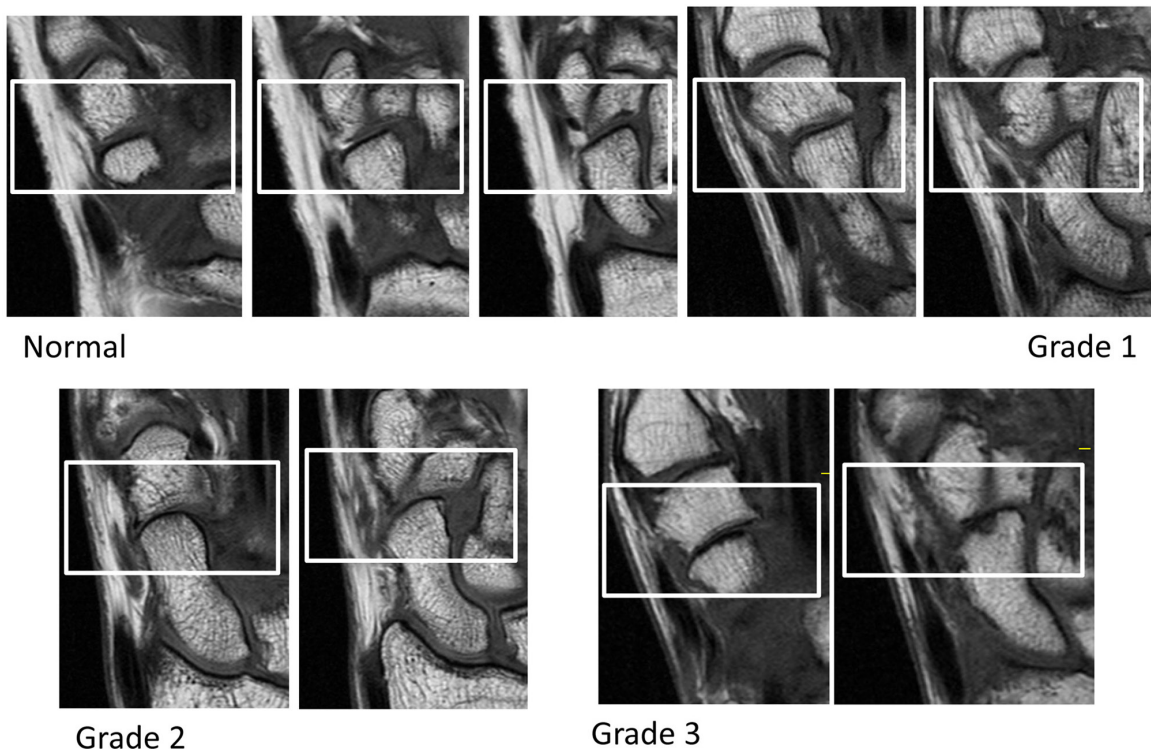


Grade 3

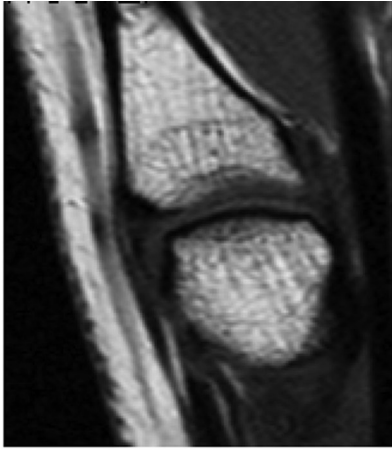
Osteophytes scapho-trapezio-trapezoid: distal scaphoid (T1 weighted images).



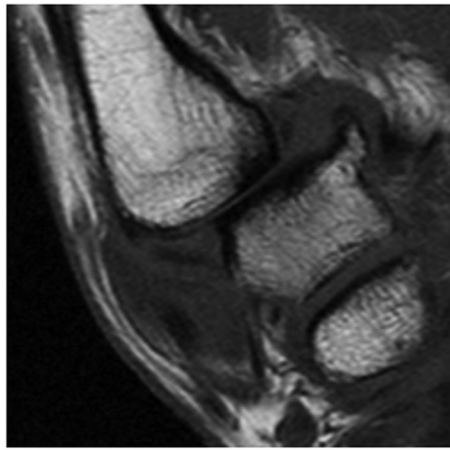
Cartilage assessment first carpometacarpal (T1 weighted images).



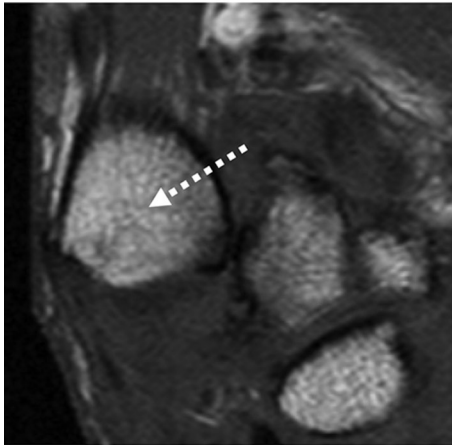
Cartilage assessment scapho-trapezio-trapezoid (T1 weighted images).



Normal

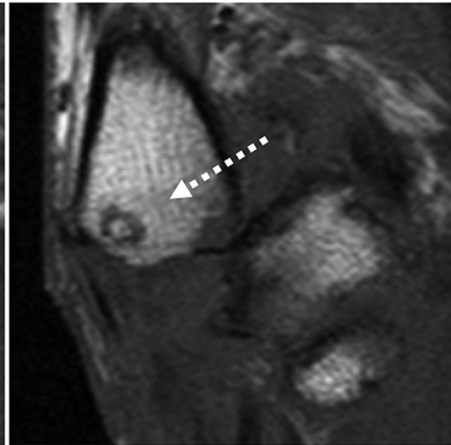


Subluxation present

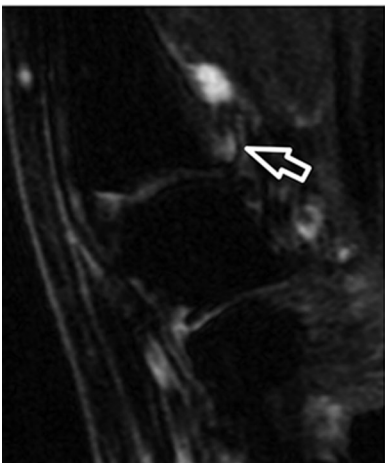


Subluxation present (severe)

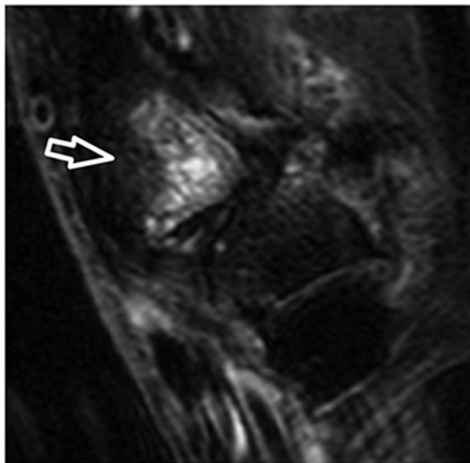
[arrow points into direction of subluxation]



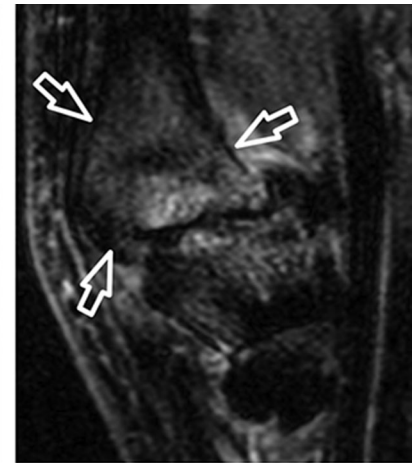Subluxation first carpometacarpal (T1 weighted images).



Grade 1

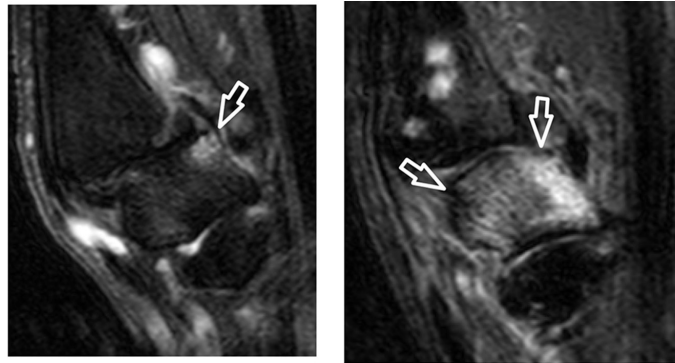


Grade 2



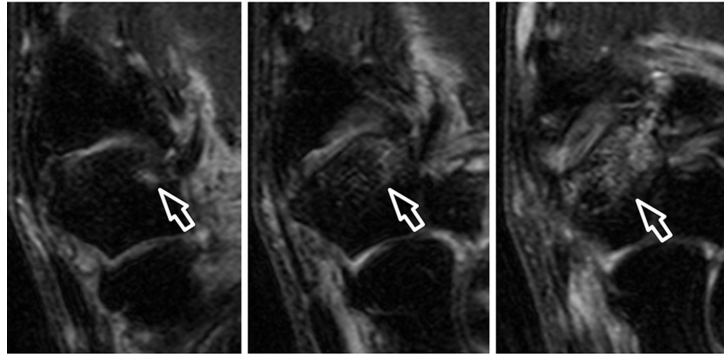
Grade 3

Bone marrow lesions first carpometacarpal: proximal first metacarpal (T2 weighted-fat saturated images).



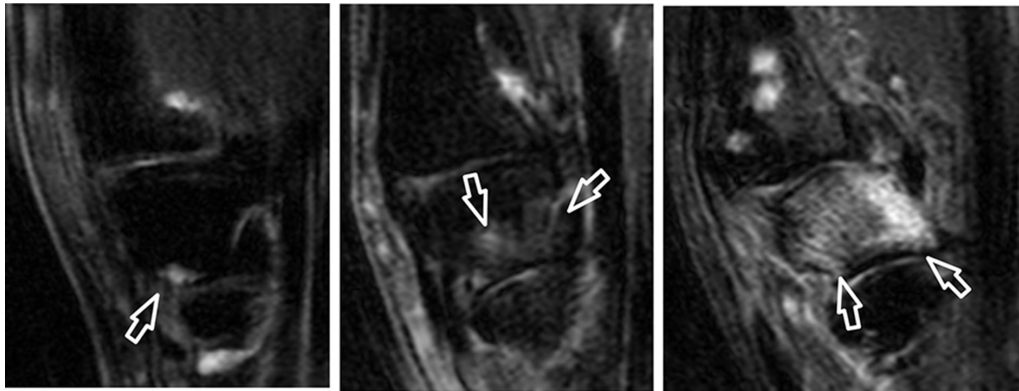
Grade 1

Grade 3



Grade 2

Bone marrow lesions first carpometacarpal: distal trapezium (T2 weighted-fat saturated images).

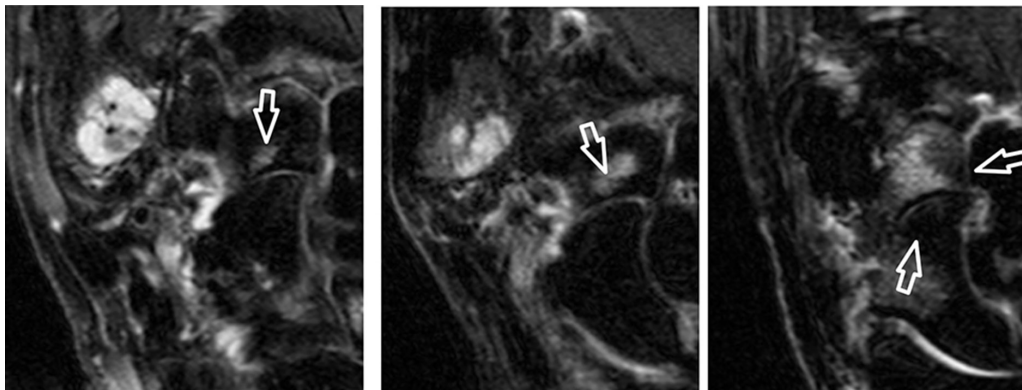


Grade 1

Grade 2

Grade 3

Bone marrow lesions scapho-trapezio-trapezoid: proximal trapezium (T2 weighted-fat saturated images).

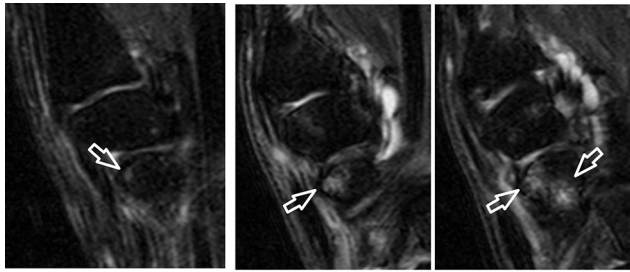


Grade 1

Grade 2

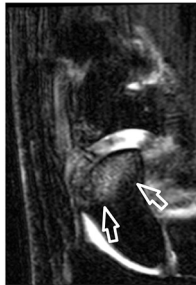
Grade 3

Bone marrow lesions scapho-trapezio-trapezoid: proximal trapezoid (T2 weighted-fat saturated images).



Grade 1

Grade 2



Grade 3

Bone marrow lesions scapho-trapezio-trapezoid: distal scaphoid (T2 weighted-fat saturated images).

Author affiliations

¹Department of Rheumatology, Leiden University Medical Center, Leiden, The Netherlands

²Spire Sciences Inc, Boca Raton, Florida, USA

³Leeds Institute of Rheumatic and Musculoskeletal Medicine, University of Leeds and National Institute for Health Research, Leeds Biomedical Research Centre, Leeds, UK

⁴Department of Rheumatology, Pitié Salpêtrière Hospital, APHP, Université Pierre et Marie Curie, Paris, France

⁵Department of Diagnostic Imaging, Sheba Medical Center, Tel Aviv University, Tel Aviv, Israel

⁶Department of Radiology, University of California San Francisco, San Francisco, California, USA

⁷Department of Medicine, University of California San Francisco, San Francisco, California, USA

⁸Copenhagen Center for Arthritis Research, Center for Rheumatology and Spine Diseases, Glostrup Hospital, Copenhagen, Denmark

⁹Department of Clinical Medicine, University of Copenhagen, Copenhagen, Denmark

¹⁰Department of Radiology, Leiden University Medical Center, Leiden, The Netherlands

¹¹Department of Rheumatology, Diakonhjemmet Hospital, Oslo, Norway

¹²Department of Clinical Epidemiology, Leiden University Medical Center, Leiden, The Netherlands

Correction notice This article has been corrected since it first published. The article type has been changed from 'Review' to 'Original article'.

Acknowledgements Images from the HOSTAS study were provided by the Department of Radiology and Rheumatology of the LUMC (Leiden, the Netherlands). We acknowledge W Damman and R Liu for acquisition of the images. Images from the Nor-Hand study were provided by the Diakonhjemmet Hospital (Oslo, Norway).

Contributors FPBK and MK were responsible for the conception of the study. FPBK and IKH were responsible for data acquisition. FPBK, CGP, MR, JLB, IKH and MK were responsible for data analysis, interpretation and drafting of the manuscript. All authors critically revised the manuscript and approved the final version.

Competing interests None declared.

Provenance and peer review Not commissioned; externally peer reviewed.

Data sharing statement FPBK and MK have access to all data, and these are available upon request.

Open Access This is an Open Access article distributed in accordance with the Creative Commons Attribution Non Commercial (CC BY-NC 4.0) license, which permits others to distribute, remix, adapt, build upon this work non-commercially, and license their derivative works on different terms, provided the original work is properly cited and the use is non-commercial. See: <http://creativecommons.org/licenses/by-nc/4.0/>

© Article author(s) (or their employer(s) unless otherwise stated in the text of the article) 2018. All rights reserved. No commercial use is permitted unless otherwise expressly granted.

REFERENCE

1. Kroon FPB, Conaghan PG, Foltz V, *et al.* Development and reliability of the OMERACT thumb base osteoarthritis magnetic resonance imaging scoring system. *J Rheumatol* 2017;44:1694–8.