

CASE REPORT

Nagoya J. Med. Sci. 77. 653 ~ 657, 2015

Tuberculous meningitis with dementia as the presenting symptom after intramedullary spinal cord tumor resection

Kazuyoshi Kobayashi¹, MD, PhD; Shiro Imagama¹, MD, PhD; Zenya Ito¹, MD, PhD; Kei Ando¹, MD, PhD; Hideki Yagi¹, MD; Ryuichi Shinjo¹, MD; Tetsuro Hida¹, MD; Kenyu Ito¹, MD; Yoshimoto Ishikawa¹, MD; Yukihiro Matsuyama², MD, PhD; and Naoki Ishiguro¹, MD, PhD

¹Department of Orthopaedic Surgery, Nagoya University Graduate School of Medicine, Nagoya, Japan

²Department of Orthopaedic Surgery, Hamamatsu University School of Medicine, Hamamatsu, Japan

ABSTRACT

Early-stage TB meningitis has no specific symptoms in patients, potentially leading to delayed diagnosis and consequently worsening prognosis. The authors present the fatal case with a delayed diagnosis of tuberculous (TB) meningitis with dementia as the presenting symptom after intramedullary spinal cord tumor resection. The medical records, operative reports, and radiographical imaging studies of a single patient were retrospectively reviewed. A 77-year-old man who underwent thoracic intramedullary hemangioblastoma resection for 2 times. The postoperative course was uneventful, but 1.5 months after surgery, the patient suffered from dementia with memory loss and diminished motivation and speech in the absence of a fever. No abnormalities were detected on blood test, brain computed tomography and cerebrospinal fluid (CSF) analysis. A sputum sample was negative for *Mycobacterium tuberculosis* in the QuantiFERON®-TB Gold (QFT-G) In-Tube Test and the tuberculin skin test was also negative. The patient was diagnosed with senile dementia by a psychiatrist. However, the patient's symptoms progressively worsened. Despite the absence of TB meningitis findings, we suspected TB meningitis from the patient's history, and administered a four-drug regimen. However the patient died 29 days after admission, subsequently *M. tuberculosis* was detected in the CSF sample. This case is a rare case of TB meningitis initially mistaken for dementia after intramedullary spinal cord tumor resection. Symptoms of dementia after intramedullary spinal cord tumor resection should first be suspected as one of TB meningitis, even if the tests for meningitis are negative. We propose that anti-tuberculosis therapy should be immediately initiated in cases of suspected TB meningitis prior to positive identification on culture.

Key Words: tuberculous meningitis, dementia, intramedullary spinal cord tumor resection, Vietnam diagnostic rule

This is an Open Access article distributed under the Creative Commons Attribution-NonCommercial-NoDerivatives 4.0 International License. To view the details of this license, please visit (<http://creativecommons.org/licenses/by-nc-nd/4.0/>).

INTRODUCTION

Early-stage tuberculous (TB) meningitis has no specific symptoms, which may lead to delayed diagnosis and consequently to a worsened prognosis.¹⁾ TB meningitis with dementia as the presenting symptom after intramedullary spinal cord tumor resection without meningitis symptoms or positive tests for TB has not been described. Here, we report a fatal case with

Received: June 1, 2015; accepted: August 19, 2015

Corresponding author: Shiro Imagama, MD, PhD

Department of Orthopaedic Surgery, Nagoya University Graduate School of Medicine, 65, Tsurumai-cho, Showa-ku, Nagoya, 466-8560, Japan

Phone: +81-52-741-2111, Fax : +81-52-744-2260, Email: imagama@med.nagoya-u.ac.jp

delayed diagnosis of TB meningitis after intramedullary spinal cord tumor resection.

CASE REPORT

The patient was a 77-year-old man with recurrence of gait disturbance and dysuria. He had undergone resection of thoracic intramedullary hemangioblastoma 9 years ago (Fig. 1a,b). Gadolinium-enhanced magnetic resonance imaging (MRI) revealed tumor recurrence with syrinx formation (Fig. 2a-d). There were no abnormalities in blood tests and brain MRI. Reoperation was performed, and the pathological diagnosis was consistent with hemangioblastoma. The postoperative course was uneventful and he was discharged after regaining the ability to walk normally.

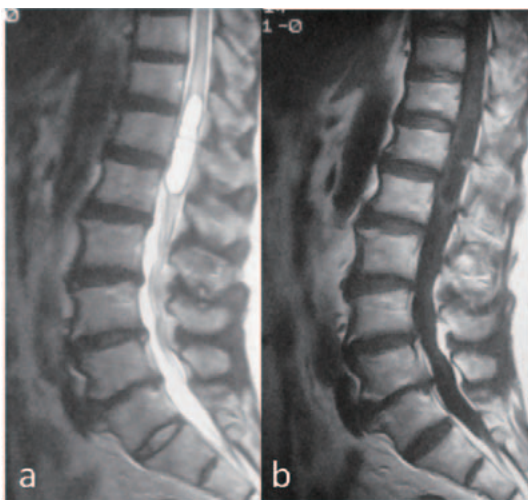


Fig. 1 (a) T2 MRI and (b) Gd-enhanced MRI before the initial surgery (nine years ago), showing the presence of an intramedullary tumor.

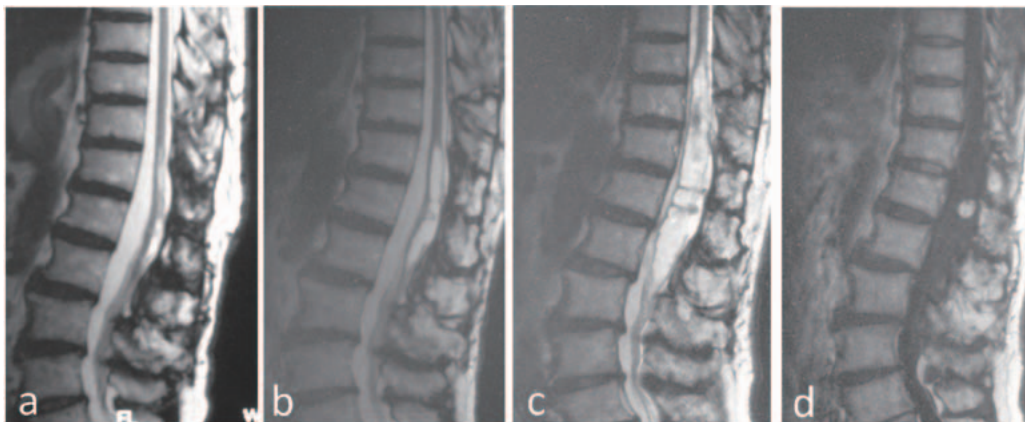


Fig. 2 (a) T2 MRI after the first surgery, showing total resection of the tumor. (b) T2 MRI four years after the first surgery, showing regrowth of the tumor. (c) T2 MRI and (d) Gd enhanced MRI nine years after the first surgery.

At 1.5 months after surgery, the patient suffered from dementia with memory loss and diminished motivation and speech in the absence of fever, and was readmitted. Tumor recurrence was not seen on MRI and blood parameters did not indicate an infection (white blood cell count [WBC], 7900 /mm³; C-reactive protein level [CRP], 0.1 mg/dL; erythrocyte sedimentation rate [ESR], 13 mm/h). No abnormalities were detected on chest X-ray (Fig. 3a), and cerebrospinal fluid (CSF) analysis was normal. Brain computed tomography (CT) (Fig. 2b) and MRI revealed slight enlargement of the ventricles (mild hydrocephalus) and the patient was diagnosed with senile dementia by a psychiatrist. However, after two weeks, his symptoms progressively worsened: dementia was more severe, he became disoriented, and his temperature increased to 39°C in association with a decrease in consciousness. At that time, the WBC count (12000 /mm³), CRP level (0.9 mg/dL) and ESR (42 mm/h) were elevated, and meropenem (2.0 g/day) was started. After a further one week, he became comatose and a second MRI revealed further hydrocephalus-induced ventricular dilatation (Fig. 2c). No tuberculosis bacteria in CSF were detected in a polymerase chain reaction (PCR) test, β -D-glucan in serum was normal, a sputum sample was negative for *Mycobacterium tuberculosis* in a QuantiFERON®-TB Gold (QFT-G) In-Tube Test, and a tuberculin skin test (TST) was also negative. Despite the absence of findings of TB meningitis, we suspected that this disease was present from the patient's history, and based on the relatively slow progression of symptoms and the increases in adenosine deaminase (ADA), cell counts and protein and the decrease in glucose in the CSF. We administered a four-drug regimen (isoniazid, 0.3 g; rifampicin, 0.5 g; ethambutol, 0.75 g; streptomycin, 0.5 g), but the patient died 29 days after admission. Subsequently, *M. tuberculosis* was detected in the second CSF sample after a 28-day culture. The patient's wife and son gave informed consent to submit this case study for publication.

DISCUSSION

We encountered a relatively rare case of TB meningitis in an elderly patient that manifested as dementia and impaired consciousness. Fever, elevation of inflammatory markers, and signs of fever, neck stiffness, and headache, which are characteristic of meningitis, were notably absent. Furthermore, β -D-glucan in serum was normal, no bacteria were detected in the initial CSF,

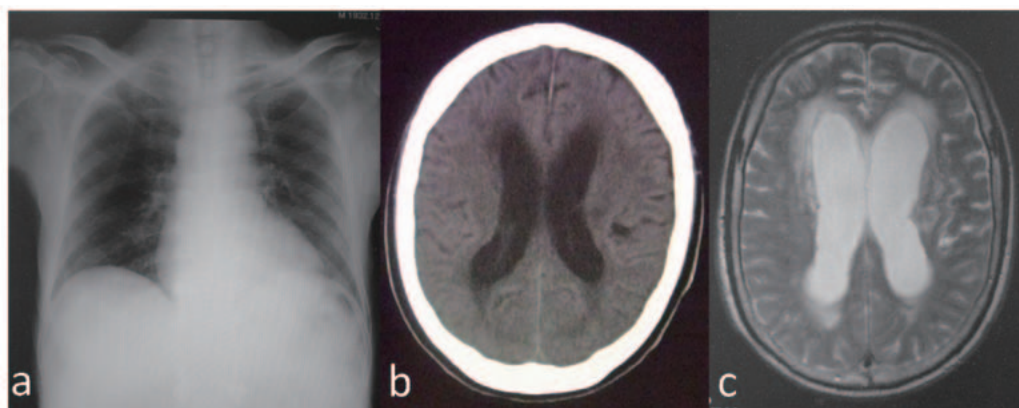


Fig. 3 (a) Normal chest X-ray. (b) Brain CT showing slight ventricle enlargement. (c) Brain MRI showing ventricle enlargement.

sputum was negative for *Mycobacterium tuberculosis* in the QFT-G In-Tube Test, and the TST was negative. Therefore, we initially assumed age-related dementia or depression, rather than fungal or TB meningitis.

Common initial symptoms of TB meningitis include internuclear ophthalmoplegia and sensorineural hearing loss,^{2,4)} but the disease may be asymptomatic.³⁾ TB meningitis accounts for only 0.5% of all TB cases, but the mortality is as high as 30% because of delayed diagnosis.⁵⁾ In previous reports, <20% of TB meningitis infections were detected in CSF cultures¹⁾; PCR had low sensitivity (53%), compared with microbiological Ziehl-Neelsen staining and culture methods (73%)⁶⁾; and the sensitivities of the QFT-G and TST were 80% and 28%, respectively.³⁾ In our case, these tests were negative and *M. tuberculosis* was detected in a the second CSF sample after long-term culture, although the initial findings were negative. Thus, a definitive diagnosis of TB meningitis is difficult. In a review by Thwaites *et al.* in 2013,¹⁾ the sensitivity and specificity of the “Vietnam diagnostic rule”⁷⁾ (Table 1) for TB meningitis were shown to be 86% and 79%, respectively.^{1,8)} This rule can help in diagnosis of TB meningitis using simple clinical and laboratory data, and can be used for TB meningitis with low glucose in CSF, particularly in settings with limited microbiological resources.¹⁾ Retrospectively, the present case had a total score ≤ 4 , which is suspicious for TB meningitis. Therefore, our case supports the effectiveness of this rule for early diagnosis of TB meningitis, especially for cases without abnormal findings.

Table 1 The Vietnam diagnostic rule

Early criteria
· Adult(age>15 years) with meningitis and ratio of CSF to plasma glucose<0.5
Clinical features and scores
· Age ≥ 36 years (score +2)
· Age < 36 years (score 0)
· Blood white cell count $\geq 15 \times 10^9/L$ (score +4)
· Blood white cell count < $15 \times 10^9/L$ (score 0)
· History of illness ≥ 6 days (score -5)
· History of illness <6 days (score 0)
· CSF white cell count $\geq 0.75 \times 10^9/L$ (score +3)
· CSF white cell count < $0.75 \times 10^9/L$ (score 0)
· CSF neutrophils $\geq 90\%$ of total white cells (score +4)
· CSF neutrophils <90% of total white cells (score 0)
Interpretation
· Total score ≤ 4 tuberculous meningitis
· Total score >4 alternative diagnosis

TB meningitis may occur as a primary or secondary disease. Many secondary cases develop due to a decrease in immunity caused by diabetes or a malignant tumor in the elderly, and many of these cases have no obvious active pulmonary tuberculosis.⁹⁾ The patient in the present case had no history of HIV, diabetes, steroid hormone treatment, or malignant tumor, but he had undergone two surgeries for an intramedullary tumor and may have been in a postoperative compromised

state. Also, in spinal cord tumor surgery, CSF leakage may occur after a dura mater procedure, and there is a risk of postoperative meningitis due to long-term drain placement. Even if typical symptoms such as headache, fever, and stiff neck are absent, meningitis should be suspected in a patient with deterioration of consciousness and disorientation after intramedullary surgery.

The present case indicates that symptoms of dementia after intramedullary spinal cord tumor resection should first be suspected as TB meningitis, even if tests for meningitis are negative. We propose that anti-tuberculosis therapy should be initiated immediately in cases of suspected TB meningitis prior to positive identification in culture.

CONFLICT OF INTEREST

No potential conflict of interest relevant to this article was reported.

REFERENCES

- 1) Thwaites GE, van Toorn R, Schoeman J. Tuberculous meningitis: more questions, still too few answers. *Lancet Neurol*, 2013; 12: 999–1010.
- 2) Daif A, Obeid T, Yaqub B, AbdulJabbar M. Unusual presentation of tuberculous meningitis. *Clin Neurol Neurosurg*, 1992; 94: 1–5.
- 3) Khalil KF, Ambreen A, Butt T. Comparison of sensitivity of QuantiFERON-TB Gold Test and Tuberculin Skin Test in active pulmonary tuberculosis. *J Coll Physicians Surg Pak*, 2013; 23: 633–636.
- 4) Kotnis R, Simo R. Tuberculous meningitis presenting as sensorineural hearing loss. *J Laryngol Otol*, 2001; 115: 491–492.
- 5) Sheller JR, Des Prez RM. CNS tuberculosis. *Neurol Clin*, 1986; 4: 143–158.
- 6) Brienze VM, Tonon AP, Pereira FJ, Liso E, Tognola WA, dos Santos MA, Ferreira MU. Low sensitivity of polymerase chain reaction for diagnosis of tuberculous meningitis in southeastern Brazil. *Rev Soc Bras Med Trop*, 2001; 34: 389–393.
- 7) Thwaites GE, Chau TT, Stepniewska K, Phu NH, Chuong LV, Sinh DX, White NJ, Parry CM, Farrar JJ. Diagnosis of adult tuberculous meningitis by use of clinical and laboratory features. *Lancet*, 2002; 26: 1287–1292.
- 8) Garg RK. Tuberculosis of the central nervous system. *Postgrad Med J*, 1999; 75: 133–140.
- 9) Takahashi T, Nakayama T, Tamura M, Ogawa K, Tsuda H, Morita A, Hara M, Togo M, Shiota H, Suzuki Y, Minami M, Ishikawa H, Miki K, Shikata E, Takahashi S, Kuragano T, Matsumoto K, Sawada S, Mizutani T. Nested polymerase chain reaction for assessing the clinical course of tuberculous meningitis. *Neurology*, 2005; 24: 1789–1793.