

# Sentinel Node Biopsy in Young Patients with Atypical Melanocytic Tumors of the Head and Neck

David Pfau<sup>1</sup>, Akina Tamaki, MD<sup>2</sup>, Kathryn R. Hoppe, MD<sup>2</sup>, Kord Honda, MD<sup>3</sup>, Rod Rezaee, MD<sup>2</sup>, and Chad A. Zender, MD<sup>2</sup>

OTO Open

1-5

© The Authors 2019

Article reuse guidelines:

sagepub.com/journals-permissions

DOI: 10.1177/2473974X19850752

http://oto-open.org



Sponsorships or competing interests that may be relevant to content are disclosed at the end of this article.

## Abstract

**Objective.** To examine the diagnostic value of the sentinel lymph node biopsy in pediatric through young adult head and neck melanocytic tumors of unknown malignant potential.

**Study Design.** Retrospective case series.

**Setting.** Single academic institution.

**Subjects and Methods.** Demographics, histology, and outcomes were examined in 14 patients aged 4 to 24 years with head and neck melanocytic tumors of unknown malignant potential. Information on age at diagnosis, primary lesion characteristics, and sentinel lymph node biopsy were compared.

**Results.** Of 14 patients meeting criteria for head and neck melanocytic tumors of unknown malignant potential, 8 patients underwent sentinel lymph node biopsy (57%). Of those, 4 biopsies (50%) had positive sentinel nodes. All patients undergoing sentinel lymph node biopsy had primary lesions greater than 1 mm depth or mitotic rate of at least 1 mitosis per mm<sup>2</sup>. No patients had recurrence of their primary lesion at time of follow-up.

**Conclusion.** Our data show a high rate of node-positive sentinel lymph node biopsy for pediatric and young adult head and neck patients with melanocytic tumors of unknown malignant potential, supporting the value of sentinel lymph node biopsy in this population.

## Keywords

sentinel lymph node biopsy, pediatric, melanoma, melanocytic tumors of unknown malignant potential, head and neck

Received February 25, 2019; revised March 19, 2019; accepted April 25, 2019.

**P**ediatric and adolescent melanomas comprise approximately 1% to 4% of melanomas and 1% to 3% of all pediatric malignancies.<sup>1</sup> Over the past 3 decades, the

incidence of melanoma in patients younger than 20 years has been rising by approximately 3% per year.<sup>1,2</sup> Pediatric melanomas have been found to present differently compared to adults. Several studies have shown that pediatric melanomas have thicker Breslow depth at presentation, more atypical clinical features, and more frequent nodal metastasis.<sup>3-6</sup> Fortunately, younger patients have a higher overall survival compared to stage-matched adults.<sup>3</sup> The primary location of melanoma presentation is important in prognosis, given head and neck has worse prognosis compared to other sites in the body.<sup>7-9</sup> Given the relative rarity of head and neck melanomas in the pediatric population, clinical guidelines and prognostic factors are not well defined.

Furthermore, there is little guidance regarding management of melanocytic skin lesions that are not unequivocally malignant. These lesions are referred to as melanocytic tumors of unknown malignant potential (MelTUMPs). These lesions are difficult to histologically classify as benign or malignant. Lesions included in this categorization of MelTUMPs include atypical Spitz neoplasms, blue nevi, and deep-penetrating nevi. MelTUMPs share a common ability for regional and distant metastasis.<sup>10,11</sup> Management of MelTUMPs can be difficult due to the subjective nature of histologic identification, lack of concrete classifications, and the problematic tendency for these tumors to show variable characteristics.<sup>10-12</sup> The scarcity of data on pediatric MelTUMPs hinders the creation of reliable standards for these lesions.

<sup>1</sup>Case Western Reserve University School of Medicine, Cleveland, Ohio, USA

<sup>2</sup>Ear, Nose, and Throat Institute, Case Western Reserve University, University Hospitals Cleveland Medical Center, Cleveland, Ohio, USA

<sup>3</sup>Department of Dermatology, Case Western Reserve University, University Hospitals Cleveland Medical Center, Cleveland, Ohio, USA

## Corresponding Author:

Chad A. Zender, MD, Department of Otolaryngology-Head and Neck Surgery, University Hospitals Case Medical Center, 11100 Euclid Avenue, LKS 5045, Room 4535, Cleveland, OH 44106, USA.  
 Email: Chad.Zender@UHhospitals.org



There is controversy in the utility of sentinel lymph node biopsy (SLNB) in the treatment of MelTUMPs.<sup>13,14</sup> SLNB is used to stage patients with malignancies that have potential to spread via lymphatic pathways. However, it has been demonstrated that in the pediatric population, a positive sentinel lymph node may not be predictive of worsened prognosis.<sup>15</sup> Specifically in the head and neck, SLNB may be limited by several factors, including complex lymphatic drainage and multiple channels for lymphatic spread.<sup>16</sup> In the setting of a relatively rare disease such as pediatric melanoma, SLNB may play a more central role in guiding clinical decision making and predicting disease behavior and prognosis. There is a lack of clinical information regarding the diagnostic and therapeutic benefits of SLNB for MelTUMPs in the pediatric through young adult population, especially in the head and neck. In this study, we examined MelTUMPs with and without SLNB at our institution in the past 16 years. Measured outcomes include the use of SLNB, follow-up completion lymph node dissection (CLND), primary lesion recurrence, and overall, regional, and distant disease-free survival.

## Methods

This retrospective study reviewed pediatric and young adult head and neck MelTUMPs at our tertiary care academic hospital. The study was approved through our institution's institutional review board. Patients aged 0 to 25 years treated for MelTUMPs of the head and neck from January 1, 2000, to December 31, 2016, were collected. Only patients with a minimum of 1-year follow-up were included. Demographics, outcomes, and histologic data were examined in 14 patients. Demographic information included sex, race, and age at diagnosis, while histologic data included lesion site, depth, mitotic rate, and ulceration presence. Age at diagnosis, primary lesion characteristics, SLNB results, and disease-free survival were compared.

The primary lesion was removed via wide local excision. SLNB was performed in accordance to the recommendations by the American Joint Committee on Cancer (AJCC) Melanoma Staging Committee. SLNB was offered to patients who had T1b (with adverse features), T2, T3, and T4 melanomas.<sup>11,17</sup> Lymphoscintigraphy was performed followed by excision of the sentinel lymph node. If sentinel lymph node was positive for melanoma, a CLND was subsequently offered.

Patients were grouped by age at initial evaluation. Patients younger than 12 years were categorized as *child*, those aged 12 to 19 years as *adolescent*, and those aged 20 to 25 years as *young adult*. These classifications are consistent with the age guidelines described by the Centers for Disease Control and Prevention.<sup>18</sup> MelTUMPs included categorizations of favor benign, uncertain, and favor malignant. Favor benign included those with focal proliferation but limited scope, while favor malignant include Spitz-like neoplasms with high dermal cellularity, deep dermal extension, high mitotic rate deep in the dermis, and asymmetry and necrosis.<sup>19</sup>

**Table 1.** Demographics.<sup>a</sup>

Characteristic	No. of Patients
Sex	
Male	9
Female	5
Race/ethnicity	
White	14
Asian, African American, Latino	0
Other/unspecified	0
Age at diagnosis, y	
Pediatric, 0-11	3
Adolescent, 12-19	6
Young adult, 20-25	5

<sup>a</sup>Demographics of 14 patients presenting with melanocytic tumors of unknown malignant potential.

Lesion severity was assessed by examining Breslow thickness, presence of ulceration, mitotic count, and Clark level of invasion. Measured outcomes include the use of SLNB, follow-up CLND, primary lesion recurrence, and overall, regional, and distant disease-free survival.

## Results

Our institutional experience demonstrates a high rate of node positivity following SLNB for MelTUMPs. Fourteen patients between the ages of 4 and 24 years were identified as having a diagnosis of head and neck MelTUMPs. All patients met the criteria of at least 1 year of follow-up. The median age was 16 years, with a range of 4 to 24 years. There were 9 males and 5 females. All patients were white. Three patients in the pediatric age group were aged 0 to 11 years, 6 in the adolescent group were aged 12 to 19 years, and 5 in the young adult group were aged 20 to 25 years (**Table 1**).

Individual features of each respective skin lesion are described in **Table 2**. In total, 8 patients had SLNB performed, and there was an overall sentinel lymph node positivity rate of 50% (n = 4). All patients undergoing SLNB had primary lesions of greater than 1 mm depth or mitotic rate of at least 1 mitosis per mm<sup>2</sup>. Patients not receiving SLNB either declined the procedure or were not offered it based on their lesion characteristics. Subgroup analysis (**Figure 1**) revealed 14 patients were initially diagnosed with MelTUMPs by pathology based on histologic and immunohistochemical examination, of whom over half (n = 8, 57%) underwent SLNB. Node-positive lesion locations included the temple, ear, scalp, and neck. Four biopsies (50%) returned positive for 1 or more sentinel nodes, and all 4 underwent further CLND. Of the 4 patients who underwent CLND, only 1 had a positive node on completion dissection. No patients had developed recurrence of their primary disease at the time of review. One patient of the 14 did undergo adjuvant interferon treatment. Patients not managed with SLNB were treated with excision alone. Median

**Table 2.** Tumor Characteristics, Testing, and Outcome.<sup>a</sup>

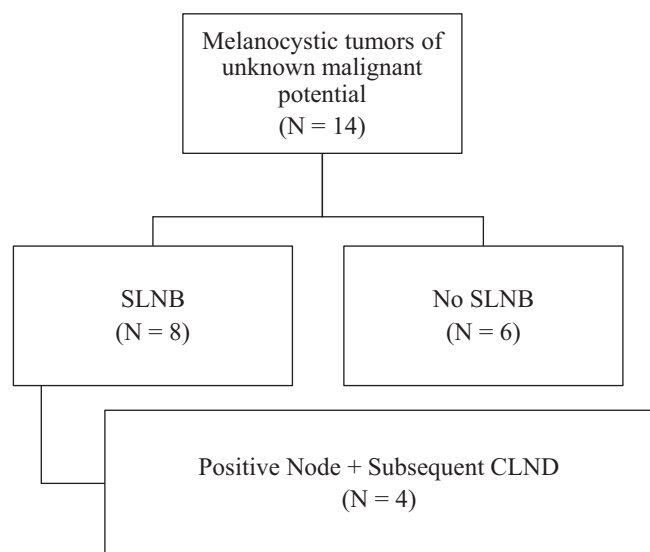
Patient No.	Age, y	Sex	Site	Depth, mm	Mitoses, per mm <sup>2</sup>	Ulceration	SLNB	Dissection	DFS, <sup>b</sup> mo
1	4	M	L temple	1.01	2	Yes	Negative	—	57
2	6	M	L cheek	—	—	—	—	—	44
3	6	F	R ear	—	4+	No	Negative	—	108
4	12	M	R scalp	1.87	1	No	Negative	—	28
5	13	F	R temple	2	1-2	No	+ 1 node	Clear	37
6	16	M	L ear	—	Present	No	+ 1 node	Clear	156 <sup>c</sup>
7	16	M	L neck	0.66	2	No	—	—	41
8	17	M	Scalp	1.75	1-2	No	+ 1 node	+ 1 node	43
9	19	M	Scalp	2.38	2-3	No	Negative	—	39
10	21	F	R jaw	—	—	No	—	—	109
11	22	F	Forehead	0.31	0	No	—	—	95
12	23	F	L neck	1.18	1	No	+ 1 node	Clear	41
13	24	M	R scalp	0.65	0	No	—	—	52
14	24	M	L cheek	2.33	—	No	—	—	46

Abbreviations: F, female; L, left; M, male; R, right.

<sup>a</sup>This table displays the individual features of each melanocytic tumor of unknown malignant potential diagnosis. Sentinel lymph node biopsy and dissection results are reported as “—” if the procedure was not performed, “negative” if no nodes were found to have evidence of metastasis, and “+N nodes” for positive nodal metastasis of N nodes. Ulceration status was noted for each lesion.

<sup>b</sup>Disease-free survival (DFS) is noted as overall disease-free survival with regard to primary lesion or primary lesion recurrence, in months.

<sup>c</sup>Received adjuvant interferon treatment.



**Figure 1.** Subgroup analysis of head and neck melanocytic tumors of unknown malignant potential. Division of patients who underwent sentinel lymph node biopsy (SLNB) and completion lymph node dissection (CLND).

follow-up was 44 months with an interquartile range of 16 months.

## Discussion

There are various types of melanocytic neoplasms and there are occasional challenges in differentiating benign from malignant disease. These melanocytic neoplasms were divided into 2 broad categories: superficial atypical melanocytic proliferations of uncertain significance (SAMPUS) and

MelTUMPs. SAMPUS are superficial and show no proliferation or mitotic activity in the dermis, resulting in excellent prognosis and low risk of metastasis. In comparison, MelTUMP lesions exhibit pathology in the reticular dermis and have potential for local and distant disease dissemination.<sup>11</sup> Atypical Spitz neoplasms, blue nevi, and deep-penetrating nevi are categorized as MelTUMPs. There are recommendations that MelTUMPs be managed in the same manner as malignant melanomas.<sup>11,14,20</sup>

Due to the rarity of pediatric melanomas, and even more so for MelTUMP lesions, the current recommendations for management are based on adult guidelines. Multiple studies have shown a higher incidence of positive SLNB in the pediatric and young adult population compared to adults.<sup>3-6,21,22</sup> In our study, SLNB was offered in accordance with the recommendations by the AJCC Melanoma Staging Committee. Although there are no established guidelines for MelTUMPs, SLNB was offered to patients with primary lesions greater than 1 mm depth or with adverse features, including high mitotic rate or ulceration. One patient with a Breslow thickness of 2.33 mm did not undergo SLNB. Upon review, this patient underwent wide local excision of his lesion in the clinic rather than in the operating room. This was also the only patient who underwent MelTUMP treatment in a department other than otolaryngology and may reflect a lack of consistent guidelines in MelTUMP management.

SLNB for MelTUMP lesions in our series reveals a high rate of node positivity and supports the use of SLNB for these lesions. Most of the positive node biopsies were in the adolescent age range of 12 to 19 years. While there was 1 patient with at least 1 positive lymph node on SLNB, there

was no development of local recurrence or distance metastasis. Longer-term follow-up is necessary to further determine the prognostic value of SLNB in MelTUMPs. This is consistent with data from a 2010 single-institution review of cutaneous head and neck pediatric melanoma, wherein a positive SLNB did not indicate an increased likelihood for distant metastasis or worsened prognosis.<sup>15</sup> Despite this, SLNB may be justified for MelTUMPs for 2 reasons. First, if the pathology confirms melanoma, the patient will undergo the recommended treatment for this malignant disease. Second, the presence of a positive sentinel lymph node may assist in validating a diagnosis of melanoma.<sup>13</sup>

The role of CLND remains controversial. Four patients with MelTUMPs and positive sentinel node biopsy underwent CLND. Within this group, 1 patient had a positive node on CLND and remains disease free at the time of this publication. Of the 14 patients in this study, all patients survived without complication and with no evidence of locoregional or distal recurrence at the time of last follow-up. The Multicenter Selective Lymphadenectomy Trial II (MSLT-II) was an international, multicenter, randomized phase 3 trial, evaluating the value of CLND in the setting of a positive SLNB. This study concluded that there was no difference in 3-year melanoma-specific survival between CLND and observation. However, the CLND group did have improved disease-free survival and regional control.<sup>23</sup> CLND was also associated with a significant rate of postoperative complications.<sup>23,24</sup> Given the lack of consensus on the value of CLND and the life-long implications in this young population of patients, the utility of CLND in pediatric MelTUMPs requires further research.

The high rate of sentinel lymph node positivity in our series supports the potential value of SLNB in the pediatric through young adult MelTUMP population. However, there are limitations in our study. The small number of patients limits the generalizability of our conclusion. Longer follow-up is also needed given the lack of any recurrent or metastatic disease in our series.

## Conclusion

Our institution's experience demonstrates the value of SLNB in pediatric through young adult MelTUMPs of the head and neck. While there are no clear protocols on the role of SLNB in head and neck MelTUMPs in the pediatric and young adult population, the high rate of positive SLNBs in this group at our institution suggests this procedure should be incorporated more formally into treatment algorithms. Due to the rarity and uncertain behavior of these tumors, previously demonstrated safety of the SLNB, and SLNB's prognostic and therapeutic value, SLNB should be considered in this population. Further research is necessary to guide clinical decision making and provide appropriate patient counseling.

## Author Contributions

**David Pfau**, design, conduct, analysis, IRB, writing, review and approval; **Akina Tamaki**, analysis, writing, review and approval; **Kathryn R. Hoppe**, analysis, writing, review and approval;

**Kord Honda**, data acquisition, analysis, supervision, review and approval; addition to manuscript in the form of revision for important intellectual content; insight on critical discussion points; **Rod Rezaee**, design, data acquisition, supervision, review and approval; addition to manuscript for clarification on several important diagnostic details as well as several discussion points; **Chad A. Zender**, design, supervision, review and approval; addition to manuscript in the form of revision for important intellectual content; insight on critical discussion points.

## Disclosures

**Competing interests:** Rod Rezaee is a speaker/consultant for Biomet.

**Sponsorships:** None.

**Funding source:** None.

## References

1. Austin MT, Xing Y, Hayes-Jordan AA, Lally KP, Cormier JN. Melanoma incidence rises for children and adolescents: an epidemiologic review of pediatric melanoma in the United States. *J Pediatr Surg*. 2013;48:2207-2213.
2. Strouse JJ, Fears TR, Tucker MA, Wayne AS. Pediatric melanoma: risk factor and survival analysis of the surveillance, epidemiology and end results database. *J Clin Oncol*. 2005;23:4735-4741.
3. Richards MK, Czechowicz J, Goldin AB, et al. Survival and surgical outcomes for pediatric head and neck melanoma. *JAMA Otolaryngol Head Neck Surg*. 2017;143:34-40.
4. Ferrari A, Bono A, Baldi M, et al. Does melanoma behave differently in younger children than in adults? A retrospective study of 33 cases of childhood melanoma from a single institution. *Pediatrics*. 2005;115:649-654.
5. Tcheung WJ, Marcello JE, Puri PK, Abernethy AP, Nelson KC. Evaluation of 39 cases of pediatric cutaneous head and neck melanoma. *J Am Acad Dermatol*. 2011;65:e37-e42.
6. Han D, Zager JS, Han G, et al. The unique clinical characteristics of melanoma diagnosed in children. *Ann Surg Oncol*. 2012;19:3888-3895.
7. O'Brien CJ, Coates AS, Petersen-Schaefer K, et al. Experience with 998 cutaneous melanomas of the head and neck over 30 years. *Am J Surg*. 1991;162:310-314.
8. Lachiewicz AM, Berwick M, Wiggins CL, Thomas NE. Survival differences between patients with scalp or neck melanoma and those with melanoma of other sites in the Surveillance, Epidemiology, and End Results (SEER) program. *Arch Dermatol*. 2008;144:515-521.
9. Golger A, Young DS, Ghazarian D, Neligan PC. Epidemiological features and prognostic factors of cutaneous head and neck melanoma: a population-based study. *Arch Otolaryngol Head Neck Surg*. 2007;133:442-447.
10. Berk DR, LaBuz E, Dadras SS, Johnson DL, Swetter SM. Melanoma and melanocytic tumors of uncertain malignant potential in children, adolescents and young adults—the Stanford experience 1995-2008. *Pediatr Dermatol*. 2010;27:244-254.
11. Elder DE, Xu X. The approach to the patient with a difficult melanocytic lesion. *Pathology*. 2004;36:428-434.

12. Cordoro KM, Gupta D, Frieden IJ, McCalmont T, Kashani-Sabet M. Pediatric melanoma: results of a large cohort study and proposal for modified ABCD detection criteria for children. *J Am Acad Dermatol.* 2013;68:913-925.
13. Joyce DP, Prichard RS, Gulmann C, Hill AD. The surgical management of Spitz naevi and atypical spitzoid neoplasms: a review of the literature. *Surgeon.* 2013;11:205-209.
14. McCormack CJ, Conyers RK, Scolyer RA, et al. Atypical spitzoid neoplasms: a review of potential markers of biological behavior including sentinel node biopsy. *Melanoma Res.* 2014; 24:437-447.
15. Howman-Giles R, Shaw HM, Scolyer RA, et al. Sentinel lymph node biopsy in pediatric and adolescent cutaneous melanoma patients. *Ann Surg Oncol.* 2010;17:138-143.
16. Shashanka R, Smitha BR. Head and neck melanoma. *ISRN Surg.* 2012;2012:948302.
17. Stebbins WG, Garibyan L, Sober AJ. Sentinel lymph node biopsy and melanoma: 2010 update part II. *J Am Acad Dermatol.* 2010;62:737-750.
18. Centers for Disease Control and Prevention. Life Stages and Populations. <https://www.cdc.gov/nchs/fastats/life-stages-and-populations.htm>. Published 2017. Accessed February 20, 2017.
19. Sreeraman Kumar R, Messina JL, Reed D, Navid F, Sondak VK. Pediatric melanoma and atypical melanocytic neoplasms. *Cancer Treat Res.* 2016;167:331-369.
20. Murali R, Sharma RN, Thompson JF, et al. Sentinel lymph node biopsy in histologically ambiguous melanocytic tumors with spitzoid features (so-called atypical spitzoid tumors). *Ann Surg Oncol.* 2008;15:302-309.
21. Roaten JB, Partrick DA, Pearlman N, Gonzalez RJ, Gonzalez R, McCarter MD. Sentinel lymph node biopsy for melanoma and other melanocytic tumors in adolescents. *J Pediatr Surg.* 2005;40:232-235.
22. Livestro DP, Kaine EM, Michaelson JS, et al. Melanoma in the young: differences and similarities with adult melanoma: a case-matched controlled analysis. *Cancer.* 2007;110:614-624.
23. Faries MB, Thompson JF, Cochran AJ, et al. Completion dissection or observation for sentinel-node metastasis in melanoma. *N Engl J Med.* 2017;376:2211-2222.
24. Morton DL, Cochran AJ, Thompson JF, et al. Sentinel node biopsy for early-stage melanoma: accuracy and morbidity in MSLT-I, an international multicenter trial. *Ann Surg.* 2005; 242:302-311.