



Case Report

Acute limb ischemia due to iliac thrombosis following laparoscopic surgery for hiatal hernia: Report from a medical malpractice litigation

Pasqualino Sirignano^{a,*}, Giuseppe Galiero^b, Ascanio Sirignano^c, Maurizio Taurino^d

^a Department of Surgery "Paride Stefanini", "Sapienza" University of Rome, Italy, Vascular and Endovascular Surgery Division, Sant'Andrea Hospital of Rome, Italy

^b Legal Medicine Unit, Department of Advanced Biomedical Sciences, School of Medicine, "Federico II", University of Naples, Italy

^c School of Law, Medico-Legal Section, University of Camerino, Italy

^d Department of Clinical and Molecular Medicine, "Sapienza" University of Rome, Italy, Vascular and Endovascular Surgery Division, Sant'Andrea Hospital of Rome, Italy

ARTICLE INFO

Keywords:

Laparoscopic surgery
Vascular surgery
Malpractice
Complications
Litigation
Iliac artery thrombosis

ABSTRACT

Aim of this paper is to report an unusual case of iliac artery acute thrombosis following a laparoscopic elective surgery for hiatal hernia repair and observed during a medical malpractice litigation.

A 69-year-old woman submitted to laparoscopic hiatal hernia repair developed a lower limb ischemia in 5th postoperative day due to common iliac and popliteal arteries acute occlusion. Patient was urgently treated with iliac embolectomy with Fogarty's catheter, and femoral endarterectomy, followed on 1st post-operative day by external iliac artery stenting and multiple attempts of popliteal artery recanalization.

After 4 years of follow-up, despite symptoms at rest were disappeared, a severe (<200 m) right limb claudication was still present.

1. Introduction

After elective surgery, deep vein thrombosis (DVT) and pulmonary embolism (PE), are the most frequent vascular complications commonly reported as causes of medical litigations [1], and frequently described as alarming cause of morbidity and mortality. Factors contributing to the development of DVT include long operative time under anesthesia, reverse Trendelenburg positioning, and impaired lower extremity venous return with resultant stasis secondary to increased abdominal pressure from pneumoperitoneum; conversely, less thromboembolic events were noted in patients who had appropriate anticoagulant prophylaxis prior and after surgery [2].

Although rarely, even arterial lesions have been reported in Literature following laparoscopic procedures. Mostly, those lesions leading to acute ischemia potentially limb- and life-threatening. Differently from venous lesions, in those anecdotal cases precise identification of etiopathogenetic mechanisms and risk factors is not possible, while it is well recognized the high incidence of associated permanent disabling complications [3–7].

Aim of this report is to describe a case of acute arterial occlusion occurred after laparoscopic hiatal hernia repair, and observed during a

medical malpractice litigation.

2. Case report

A 69-year-old woman was hospitalized for a hiatal hernia requiring surgical repair. Patient's medical history was negative, except for arterial hypertension, tobacco abuse, and previous surgery for a not better specified breast infection. Physical examination was normal, and distal pulses were present in both limbs. Elective surgery was performed via laparoscopic approach under general anesthesia. Post-operative course was uneventful, and patient was discharged on 3rd postoperative day in good general conditions. Thrombotic prophylaxis with low molecular weight heparin (4000 IU) was prescribed.

In fifth post-operative day, patient come back to hospital for sudden onset of pain at right limb, toe's cyanosis, and forefoot anesthesia. At physical examination, femoral, popliteal and tibial pulses were not evident. Duplex-ultrasound-scan (DUS), and computed tomographic angiography (CTA) showed a complete thrombotic occlusion of the iliac axis, a patent common femoral artery, and an additional popliteal artery occlusion with only posterior tibial artery partial rehabilitation, in absence of detectable arteries at the foot level (Fig. 1). At physical

* Corresponding author. Department of Surgery "Paride Stefanini" "Sapienza" University of Rome Vascular and Endovascular Surgery Division Sant'Andrea Hospital Via di Grottarossa, 1035/1039, 00189, Roma, Italy.

E-mail address: pasqualino.sirignano@uniroma1.it (P. Sirignano).

<https://doi.org/10.1016/j.amsu.2021.102505>

Received 13 May 2021; Accepted 9 June 2021

Available online 13 June 2021

2049-0801/© 2021 The Authors. Published by Elsevier Ltd on behalf of IJS Publishing Group Ltd. This is an open access article under the CC BY-NC-ND license

(<http://creativecommons.org/licenses/by-nc-nd/4.0/>).

examination, left limb was normal with detectable distal pulses; no atherosclerotic lesions were evident at performed imaging studies.

After referral to a tertiary hospital, patient was evaluated by Vascular Surgeons and urgently submitted to iliac embolectomy with Fogarty's catheter, and femoral endarterectomy plus Dacron patch angioplasty with partial symptoms relief. On post-operative day one, a new endovascular procedure was performed: under local anesthesia, via percutaneous left common femoral artery access, external iliac artery stenting was performed (7 × 100mm Everflex; Medtronic Inc, Santa Rosa, CA – USA), followed by multiple attempts of popliteal artery recanalization. Patient was discharged at home on post-operative day 6th in good general condition under dual antiplatelet therapy. After 4 years of follow-up, despite symptoms at rest were disappeared, a severe (<200 m) right limb claudication was still present.

The patient given her consent to publish present information.

3. Discussion

At our best knowledge, this case represents one of the fourth case described in Literature in which iliac artery thrombosis leading to ALI occurred after a laparoscopic surgical procedure.

Although rare, retrospective studies and surveys report an incidence ranging from 0.04% to 0.5% [3], direct major vascular injuries are well-known potential complications of laparoscopic surgery. In almost a quarter of cases, iliac artery is directly involved, and lesions became clinically evident as arterial transection and active bleeding, while thrombosis and limb ischemia are extremely rare occurrences [3].

In 2008, Nakamura et al. reported of ALI and compartment syndrome after gynaecological laparoscopic procedure, radical hysterectomy for endometrial cancer. The Authors attributed the ALI occurrence to a prolonged procedural time (lasting for 6 hours) in lithotomy position [8]. Yeon and collaborators, in 2017 described a really comparable case: external iliac artery thrombosis occurred after laparoscopic radical hysterectomy for cervical cancer, lasting more than 6 hours, and performed in lithotomy position [6]. In both cases, no clear traumatic injury was identified, and thrombotic occurrences were empirically associated with operating time, position, and presence of unspecific risk-factors.

More interesting, for the first time, McLean and co-workers described a case of iliac thrombosis directly resulting of blunt trauma to the vessel by trocar at the time of its placement, occurring in a 13-year-old lady during robotic assisted laparoscopic surgery for obstructed uterine horn. However, their patient presented with a thin body mass (index of 20.7) and an unusual distance between the navel and the retroperitoneal vascular structures, suggesting that this kind of occurrence should be considered little more than anecdotal [3].

Lastly, Sahara et al. described the first evidence of iliac artery thrombosis after non uro-gynecological procedure, as result of a laparoscopic resection of a rectal adenocarcinoma. Despite this apparent similarity with the case here reported, in their experience preoperative atherosclerotic disease was clearly recognizable as a potential cause of the thrombotic occurrence [7].

Differently from previous reported experiences, here presented case has several peculiar characteristics that should be underlined. First of all, no lithotomy position was adopted during surgery, and no specific thrombotic risk factors or pre-existent atherosclerotic lesions were detected. Moreover, index laparoscopic procedure was performed neither for malignancy, neither for uro-gynecological disease.

Finally, but certainly worthy of attention, this case was evaluated during a medical malpractice litigation. This should be carefully considered first of all because claim has been settled, and it's really unusual considering that less than 15% of medical malpractice litigations are settled in Italy [9]. Moreover, such a case is a momentum for all Physician that Vascular Surgery, and possible vascular related complications should never be underestimate, while they should be always considered at high risk for medical malpractice litigation [10].

Funding

None.

Ethical approval

This is a case report and no formal approval was required to ethical committee.

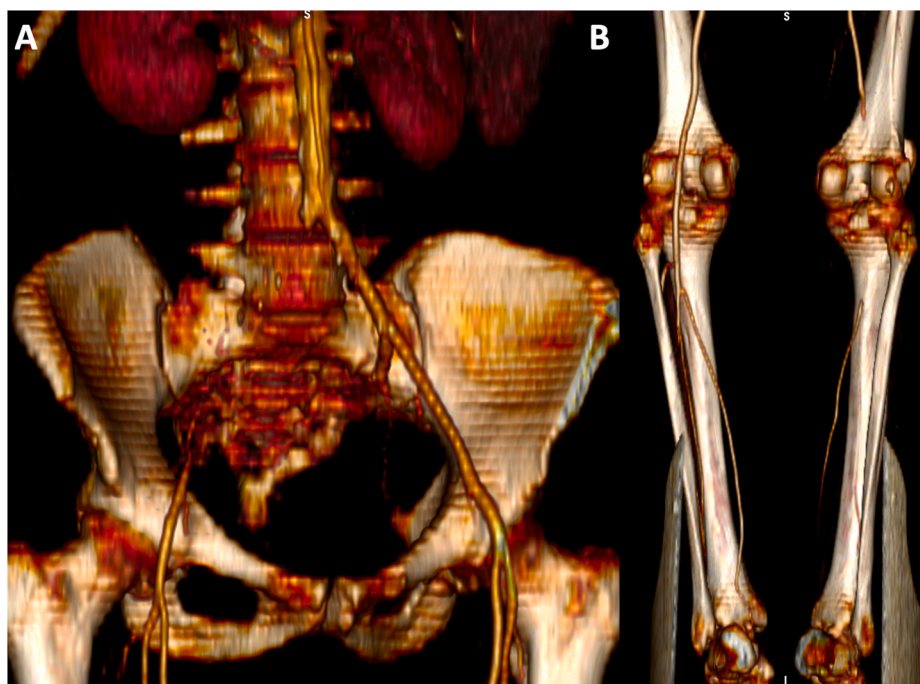


Fig. 1. CTA three-dimensional reconstruction showing complete thrombotic occlusion of the right iliac axis, with patent common femoral artery (A, anterior view), and popliteal artery occlusion with only posterior tibial artery partial rehabilitation (B, posterior view).

Consent

The patient given consent to publication.

Author contribution

Pasqualino Sirignano: paper design and writing
Giuseppe Galiero data collection
Ascanio Sirignano: literature review
Maurizio Taurino: final manuscript revision.

Registration of Research Studies

1. Name of the registry:
2. Unique Identifying number or registration ID:
3. Hyperlink to your specific registration (must be publicly accessible and will be checked):

Guarantor

Pasqualino Sirignano.

Declaration of competing interest

None.

References

- [1] P. Frati, F.P. Busardò, P. Sirignano, et al., Does defensive medicine change the behaviors of vascular surgeons? A qualitative review, *BioMed Res. Int.* (2015) 170692, 2015.
- [2] Gaar E. Errors in laparoscopic surgery. *J. Surg. Oncol.* 2004, Dec, 1;88(3):153-160.
- [3] McLean K, Dillman JR, McCarthy JD, et al. Delayed iliac artery thrombosis after blunt trauma during operative laparoscopy. *J. Minim. Invasive Gynecol.* 2009, Jan-Feb;16(1):102-105.
- [4] Tomassetti C, Meuleman C, Vanacker B, et al. Lower limb compartment syndrome as a complication of laparoscopic laser surgery for severe endometriosis. *Fertil. Steril.* 2009, Dec;92(6):2038.e9-12.
- [5] Boesgaard-Kjer DH, Boesgaard-Kjer D, Kjer JJ. Well-leg compartment syndrome after gynecological laparoscopic surgery. *Acta Obstet. Gynecol. Scand.* 2013, May; 92(5):598-600.
- [6] Yeon J, Jung YW, Yang SS, et al. Lower limb compartment syndrome by reperfusion injury after treatment of arterial thrombosis post-laparoscopic radical hysterectomy and pelvic lymph node dissection for cervical cancer. *Obstet Gynecol Sci.* 2017, Mar;60(2):223-226.
- [7] Sahara K, Ishibe A, Yabuno T, et al. Acute iliac arterial thrombosis during laparoscopic abdominoperineal resection. *J. Surg. Case Rep.* 2019, Feb, 5;2019(2): rjz020.
- [8] K. Nakamura, H. Aoki, T. Hirakawa, et al., Compartment syndrome with thrombosis of common iliac artery after gynecologic surgery, *Obstet. Gynecol.* 112 (2008) 486–488.
- [9] Sirignano P, Setacci F, Galzerano G, et al. Claimants in vascular surgery. *J. Cardiovasc. Surg.* 2012, Dec;53(6):715-717.
- [10] P. Frati, F.P. Busardò, P. Sirignano, et al., Does defensive medicine change the behaviors of vascular surgeons? A qualitative review, *BioMed Res. Int.* (2015) 170692, 2015.