

Acute abdomen and massive hemorrhage due to placenta percreta leading to spontaneous uterine rupture in the second trimester

Burcu A. Ulkumen, MD, Halil G. Pala, MD, Yesim Baytur, MD.

ABSTRACT

أن الشذوذ الغروي للمشيمة مضاعفات الولادة النادرة والذي يؤدي إلى نزيف الربع الثالث من الحمل، ونزيف بعد الولادة، ومرض الأمهات ووفاتهم إلا في حالة تشخيصه قبل الولادة. نستعرض في هذا التقرير حالة مشيمة عميقة الانغراس تؤدي إلى تمزق تلقائي للرحم خلال الثلث الثاني من الحمل مع آلام بطن حادة ونقص حجم الدم.

Placental invasion anomalies are rare obstetrical complications. They cause severe third trimester hemorrhage, severe postpartum bleeding, and maternal morbidity and mortality unless they are diagnosed antenatally. We present a rare case with placenta percreta leading to spontaneous uterine rupture during the second trimester with an acute abdomen and hypovolemia.

Saudi Med J 2014; Vol. 35 (9): 1131-1132

From the Obstetrics and Gynecology Department, School of Medicine, Celal Bayar University, Manisa, Turkey.

Received 5th March 2014. Accepted 27th May 2014.

Address correspondence and reprint request to: Assistant Professor Burcu A. Ulkumen, Obstetrics and Gynecology Department, School of Medicine, Celal Bayar University, Manisa 45210, Turkey. Tel. +90 (236) 4144162. Fax. +90 (236) 4652434. E-mail: artunc.burcu@gmail.com

Placental invasion anomalies refer to the abnormal adherence of the placenta to the uterine wall, resulting in detachment failure after delivery.¹ They are classified according to invasion depth. Placenta accreta occurs if the villi penetrates the decidua but not myometrium, placenta increta occurs if the villi penetrate the myometrium, and placenta percreta occurs if these villi perforate the serosa and also sometimes into adjacent organs such as the bladder.² The prevalence is approximately one in 2,500 pregnancies. However,

placenta previa raises the risk more than 10 times.³ The most frequent predisposing factors are prior cesarean operations and placenta previa. The worldwide increase in cesarean operations has raised the prevalence of placental invasion anomalies.⁴ Abnormal placentation is a serious obstetrical complication due to severe bleeding, which can cause shock and maternal mortality even in developed countries.⁵ Our case with uterine rupture due to placenta percreta during the second trimester is a rare, but life-threatening complication. Its exact incidence is not known, because there are only a few isolated case reports in the literature. In this paper, we present this unusual case, followed by a brief review of the published data.

Case Report. A 25-year-old gravida 2, parity one pregnant woman was referred to our clinic due to sudden onset of severe abdominal pain. The pain had started approximately 8-10 hours before referral. She was admitted to a town hospital's general surgery department and then referred to a tertiary center due to her pregnancy. The pain had been getting worse over time. She could not describe any factors modifying the pain in terms of aggravation or reduction. There were no uterine contractions. She reported having a cesarean operation 2 years before this incident. The current pregnancy was uneventful. She was followed up in a peripheral hospital in her hometown. Her pregnancy comprised 24 gestational weeks so far. The placenta was lying through the anterior uterine wall without covering the cervical os. There was a moderate amount of free fluid in the abdomen. She had rebound, especially at the right lower quadrant. Her blood pressure was 100/60 mm Hg; heart rate was 92 beats/min; and body temperature was 36.4°C. Her hemoglobin (Hb) level was 8.8 g/L, her white blood cells (WBC) were 20,000/mm³ (normal range: 11.7-15.5 g/L), and her platelet level was 220,000/mm³ (normal range: 4500-11000/mm³). An emergent laparotomy was performed. Approximately 2 L of blood was removed from the abdomen. Perioperative Hb level was 5.0 g/L.

Perioperatively, her blood pressure was diminished to 70/40 mm Hg with prominent tachycardia of 140 beats/min. There was uterine rupture at the isthmic level, and the placenta was protruding from the ruptured area. A vertical fundal incision was performed to avoid the placenta, and thus prevent further bleeding. The fetus, 730 g, was delivered; the cord was clamped and the placenta was left in the uterus. Due to severe bleeding from the ruptured uterine area, hysterectomy was performed. A total of 6 U erythrocyte suspension and 3 U of fresh frozen plasma were used. After the surgery, the Hb level was 8.2 g/L. She was discharged on the postoperative sixth day. The newborn died due to respiratory failure on the third day of life. The uterus (**Figure 1**) was sent for pathologic evaluation. The pathology report revealed placenta percreta.

Discussion. Spontaneous uterine rupture due to placenta percreta is a rare obstetric emergency with an estimated incidence of 1/5,000 pregnancies.⁶ Placenta percreta accounts for 5% of all placental invasion anomalies.⁷ The main risk factor is previous cesarean operation.^{3,4} The majority of uterine ruptures occur during the third trimester due to thinned uterine lower segment.⁸ The main difficulty is the failure of the initial diagnosis to take spontaneous uterine rupture with placenta percreta into account in cases with acute abdomen with massive hemorrhage during the twenty-fourth gestational week. This is also occurred in our case. The differential diagnosis includes acute appendicitis, ovarian torsion or cyst rupture, hepatic or splenic rupture.⁹

There are only a few isolated case reports with early uterine rupture due to placenta percreta. Medel et al¹⁰ describes an 18-gestational-week patient who conceived artificially and died due to hemorrhagic shock and

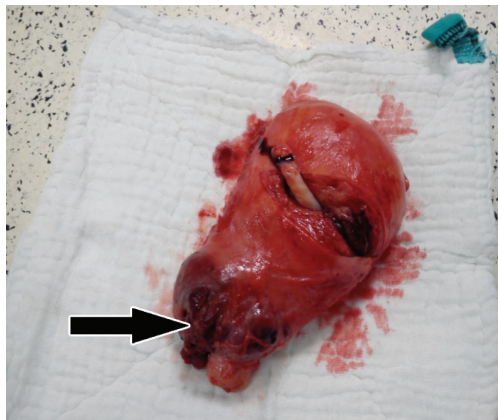


Figure 1 - Postoperative view of the uterus showing the spontaneous rupture region due to placenta percreta (arrow).

disseminated intravascular coagulation (DIC). Hornemann et al⁹ describes a naturally conceived patient at her twenty-first gestational week with a prior curettage history managed with hysterectomy. Likewise, Jang et al's patient,⁸ who had 2 prior curettage histories, was treated with hysterectomy in her fourteenth gestational week. Roeters et al⁷ performed a pregnancy-preserving operation on a patient in her fourteenth gestational week; the baby was delivered via cesarean operation in the thirty-fifth week. Siwatch et al⁵ performed a uterus-preserving operation in the presence of a 24-gestational-week fundal rupture.

Case management depends mainly on the amount of blood loss and the patient's hemodynamic status. Our patient was admitted to the emergency surgery room with massive intra-abdominal hemorrhage. By laparotomy, acute bleeding from the ruptured uterine regions was continuing so we performed a life-saving hysterectomy.

In conclusion, the differential diagnosis of acute abdomen and acute hypovolemia in a pregnant woman should keep placenta percreta induced uterine rupture in mind. Prior uterine interventions leading to scar tissue raises the likelihood of such a diagnosis.

References

1. Kent A. Management of placenta accreta. *Rev Obstet Gynecol* 2009; 2: 127-128.
2. Callen PW. Ultrasound evaluation of the placenta and umbilical cord. In: Feldstein VA, editor. *Ultrasonography in Obstetrics and Gynecology*. 5th ed. Philadelphia (PA): Saunders Elsevier; 2008. p. 737-739.
3. Morgan K, Arulkumaran S. Antepartum haemorrhage. *Curr Obstet Gynecol* 2003; 13: 81- 87.
4. Dahiya B, Nayar KD, Gulati JSA, Dahiya K. Placenta accreta causing uterine rupture in second Trimester of pregnancy after in vitro fertilization: a case report. *J Reprod Infertil* 2012; 13: 61-63.
5. Siwatch S, Chopra S, Suri V, Gupta N. Placenta percreta: rare presentation of haemorrhage in the second trimester. *BMJ Case Rep* 2013; 2013: bcr2012007782.
6. Gardeil F, Daly S, Turner MJ. Uterine rupture in pregnancy reviewed. *Eur J Obstet Gynecol Reprod Biol* 1994; 56: 107-110.
7. Roeters AE, Oudijk MA, Heydanus R, Bruinse HW. Pregnancy outcome after intra-abdominal bleeding due to placenta percreta at 14 weeks of gestation. *Obstet Gynecol* 2007; 109: 574-576.
8. Jang DG, Lee GSR, Yoon JH, Lee SJ. Placenta percreta-induced uterine rupture diagnosed by laparoscopy in the first trimester. *Int J Med Sci* 2011; 8: 424-427.
9. Hornemann A, Bohlmann MK, Diedrich K, Kavallaris A, Kehl S, Kelling K, et al. Spontaneous uterine rupture at the 21st week of gestation caused by placenta percreta. *Arch Gynecol Obstet* 2011; 284: 875-878.
10. Medel JM, Mateo SC, Conde CR, Cabistany Esque' AC, Rios Mitchell MJ. Spontaneous uterine rupture caused by placenta percreta at 18 weeks' gestation after in vitro fertilization. *J Obstet Gynaecol Res* 2010; 36: 170-173.