

Rapid maturation of unilateral cataract in leptospirosis

S R Rathinam, Shanthi Rathakrishnan¹

Leptospirosis is a bacterial cause for nongranulomatous uveitis in tropical countries. It is known to cause rapid maturation of cataract in young adults. Here we present six patients who had presenting sign as fully matured pearly white unilateral cataract without history of any trauma in their first visit. All except one patient were positive for leptospirosis by ELISA testing. Histopathological analyses of those lenses showed globular degeneration.

Key words: Globular degeneration of lens, leptospirosis, rapid maturation of cataract

Unilateral mature cataract in young individuals is usually posttraumatic, and history of injury can be elicited. All other causes such as congenital, metabolic, and senile cataracts are in general bilateral in presentation. Unilateral uveitis with or without steroid treatment can cause unilateral complicated cataract; however, they are usually posterior subcapsular and take a much longer time to reach the mature cataract stage. Leptospirosis is a waterborne spirochetel disease common in tropical countries.^[1-5] It is known to cause nongranulomatous uveitis and rapid maturation of unilateral or bilateral cataract in young adults, who are infected by leptospire.^[6,7] Here we present six patients who had presenting sign as fully matured pearly white unilateral cataract without history of any trauma. In this report, we present histopathological analyses of those lenses and senile cataract controls.

Case Reports

Institutional review board approval was obtained (IRB2009013BAS). Declaration of Helsinki was adhered to when enrolling subjects. Written informed consent was obtained from the patients before enrolling in the study. Six patients who gave history of defective vision within 3 months and had unilateral matured cataract were enrolled in the study. All of them

opted for small incision cataract surgery and intraocular lens implantation. Their age ranged from 14 to 21 years with a mean age of 16 years [Fig. 1]. Five were males and one was female [B]. They were from agricultural background; all of them gave past history of fever for which they had received symptomatic treatment. On ocular examination, three patients had hypopyon and mature cataract on their first visit to the hospital [A, D, F] with history of defective vision for 15 days. They also complained of pain and redness for 3 days. On examination, they had cells 2 + and flare 2+ with hypopyon. Three more patients [B, C, E] came with history of defective vision for 1 month, of them one had posterior synechiae and was on oral and topical steroids given outside [E]. All six patients on their first presentation showed fully matured pearly white cataract in one eye, and there was no history of trauma. Other eye lens was clear. Vision ranged from hand movements to counting fingers close to face in the eye which had cataract. Intraocular pressures were normal. Best corrected vision of other eyes with clear lenses was 6/6 in all these patients. Ultrasonogram of posterior segment of affected eye was normal in all patients. Complete blood count, Trepanema pallidum haemagglutination test, and Mantoux test were not significantly contributed. Our clinical diagnosis was leptospirosis.^[6-8] The diagnosis of leptospirosis was confirmed with Leptospira ELISA Pan Bio kit according to the manufacture's instruction. Except patient E who was on oral steroids, all were positive for leptospirosis by ELISA testing. As there was no active inflammation, three patients [B, C, E] were advised for small incision cataract surgery. After controlling inflammation, one patient [A] underwent cataract removal and the lens materials were collected for histopathological study. However, two patients deferred surgery [D, F]. The lens materials were fixed in paraffin blocks for further staining. The lens materials were stained with haemotoxin eosin stain. Four senile cataracts were also collected for controls and stained in the same process. All of the four leptospiral lenses showed globular degeneration^[9] of the lens fibers [Fig. 2], while the controls showed regular uniform arrangement of lens fibers in spite of the fact they were also cataractous lenses.

Discussion

Leptospire are waterborne spirochetes and can cause fever, chills, intense headache, myalgia, and muscle tenderness in human beings.^[1] Physicians may easily miss the diagnosis, as symptoms are extremely variable, and can mimic other infectious fever. Leptospiral uveitis is one of the most common late complications. Hypopyon, optic disc edema, retinal vasculitis, and membranous vitreous opacities are the important diagnostic indicators of leptospiral uveitis.^[7] Early onset and a rapid progression of cataract are unique features in this infection.^[6-8] Here we report histopathology of four lenses

Access this article online	
Quick Response Code:	Website: www.ijo.in
	DOI: 10.4103/ijo.IJO_535_20

Uveitis Service, Aravind Eye Hospital and PG. Institute of Ophthalmology, ¹Department of Pathology, Aravind Eye Hospital and PG Institute of Ophthalmology, Madurai, Tamil Nadu, India

Correspondence to: Dr. S R Rathinam, Department of Uveitis Service, Aravind Eye Hospital and PG Institute of Ophthalmology, 1. Anna Nagar, Madurai - 625 020, Tamil Nadu, India. E-mail: rathinam@aravind.org

Received: 14-Mar-2019
Accepted: 07-May-2020

Revision: 09-Apr-2020
Published: 20-Aug-2020

This is an open access journal, and articles are distributed under the terms of the Creative Commons Attribution-NonCommercial-ShareAlike 4.0 License, which allows others to remix, tweak, and build upon the work non-commercially, as long as appropriate credit is given and the new creations are licensed under the identical terms.

For reprints contact: WKHLRPMedknow_reprints@wolterskluwer.com

Cite this article as: Rathinam SR, Rathakrishnan S. Rapid maturation of unilateral cataract in leptospirosis. Indian J Ophthalmol 2020;68:1977-9.

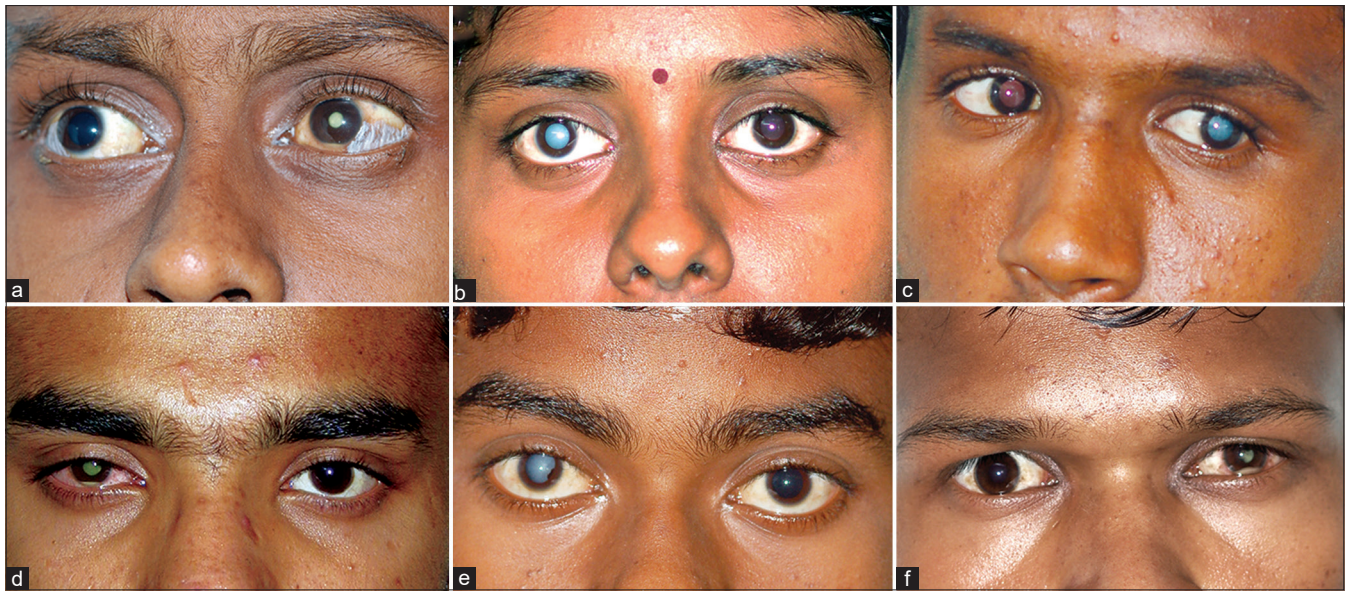


Figure 1: (a-f) Unilateral mature cataract in young patients. (a, d, and f) have hypopyon and mature cataract. (b, c, and e) only mature cataract, patient E in addition has posterior synechiae

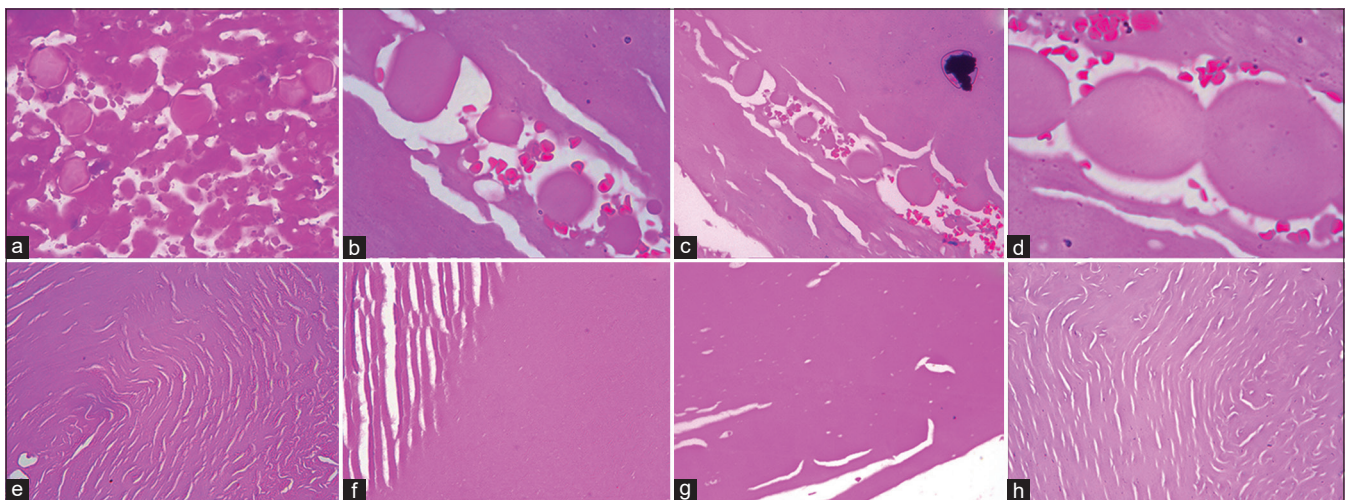


Figure 2: Lens tissues stained with haematoxylin and eosin stain. (a-d) belong to patients showing globular degeneration. (e-h) control senile cataracts with no evidence of globules

from patients who came with rapidly matured pearly white cataracts with and without hypopyon. All four lenses showed globular degeneration in contrast to parallel fiber arrangement of senile cataract controls. As reported earlier,^[6] the postsurgical prognosis was good, all patients regained 6/6 vision in 1 month.

Leptospirosis patient's serum was found to contain leptospiral antibodies that cross-reacted with multiple lens proteins that have a role in maintaining lens transparency.^[8] Authors concluded that these antibodies could act as a potential trigger for cataractogenesis.^[8] Our patients demonstrated leptospiral antibodies in their serum in the ELISA for leptospirosis test. In our patients, leptospiral antibodies could have triggered the cataract. More recently, cell membrane injuries have been reported as an important pathogenesis in leptospirosis specifically involving the loss of E-cadherin membrane expression in leptospiral of liver damage.^[10] Future study of the lens capsule may shed

additional evidences on involvement of these proteins in cataract formation as well.

Conclusion

Rapid maturation of cataract is a feature of leptospirosis.

Declaration of patient consent

The authors certify that they have obtained all appropriate patient consent forms. In the form, the patient (s) has/have given his/her/their consent for his/her/their images and other clinical information to be reported in the journal. The patients understand that their names and initials will not be published and due efforts will be made to conceal their identity, but anonymity cannot be guaranteed.

Financial support and sponsorship

Nil.

Conflicts of interest

There are no conflicts of interest.

References

1. Haake DA, Levett PN. Leptospirosis in humans. *Curr Top Microbiol Immunol* 2015;387:65-97.
 2. Sturman RM, Laval J, Weil VJ. Leptospiral uveitis. *Arch Ophthalmol* 1959;61:633-9.
 3. Duke-Elder S, editor. Leptospirosis in Diseases of the Uveal Tract System of Ophthalmology. Vol II. London: Henry Kimpton; 1966. p. 322-5.
 4. Woods AC, editor. Endogenous Uveitis. Leptospirosis Baltimore: Williams and Wilkins; 1960. p. 76-8.
 5. Rathinam SR, Selvaraj S, Dean D, Nozik RA, Namperumalsamy P. Uveitis associated with an epidemic outbreak of leptospirosis. *Am J Ophthalmol* 1997;124:71-9.
 6. Rathinam SR, Namperumalsamy P, Cunningham Jr, Emmett T. Spontaneous cataract absorption in patients with leptospiral uveitis. *Br J Ophthalmol* 2000;84:1135-41
 7. Sivakumar R, Balakrishnan V, Gowri P, Visalakshi J. Leptospiral uveitis: Usefulness of clinical signs as diagnostic predictors. *Ocul Immunol Inflamm* 2018;26:569-76.
 8. Rathinam SR, Irene D, Dharmalingam K, Jeya Maheshwari J. Molecular mimicry between betaine aldehyde dehydrogenase of leptospira and retinal dehydrogenase 1 of human lens: A potential trigger for cataract formation in leptospiral uveitis patients. *Ocul Immunol Inflamm* 2019;1-8. doi: 10.1080/09273948.2019.1687732.
 9. Duke Elder S. Diseases of the lens and vitreous. In: Duke Elder S, editor. System of Ophthalmology. Vol 11. London: Henry Kimpton; 1966. p. 220-3.
 10. De Brito T, Silva AMGD, Abreu PAE. Pathology and pathogenesis of human leptospirosis: A commented review. *Rev Inst Med Trop Sao Paulo* 2018;60:e23.
-