



Clinical Course of Small Subepithelial Tumors of the Small Bowel Detected on CT

전산화단층촬영에서 확인된 소장의 작은 상피하종양의 임상 경과 연구

Seohyun Kim, MD , Seung Joon Choi, MD* , Su Joa Ahn, MD ,
So Hyun Park, MD , Young Sup Shim, MD , Jeong Ho Kim, MD

Department of Radiology, Gil Medical Center, Gachon University College of Medicine, Incheon, Korea

Purpose This study aimed to evaluate the natural growth of subepithelial tumors of the small bowel detected on CT.

Materials and Methods Consecutive patients who were suspected of having subepithelial tumors of the small bowel between January 2005 and December 2020 were reviewed. Eligible patients with suspected small (< 30 mm) subepithelial tumors on at least two CT evaluations were included in the analysis. The patients' data on demographic characteristics, tumoral characteristics, and tumoral size changes during the follow-up were collected.

Results This study included 64 patients with suspected small subepithelial tumors ($n = 64$) of the small bowel. After a median follow-up of 15.8 months, the diameter and volume growth rates were 0.02 mm/month and 1.5 mm³/month, respectively. A significant correlation was observed between the initial size and the growth rate of the small bowel subepithelial tumors. The group of large-sized tumors (initial diameter ≥ 10 mm) tended to show lobulated contours, heterogeneous enhancement, and necrotic changes more frequently than the group of small-sized tumors (initial diameter < 10 mm).

Conclusion Small bowel subepithelial tumors measuring less than 10 mm grew more slowly than those measuring 10–30 mm.

Index terms Intestine, Small; Neoplasm; Growth; Tomography

INTRODUCTION

Subepithelial tumors are frequently encountered during routine upper endoscopies, with a detection frequency in the stomach of approximately 0.3% (1, 2). The prevalence

Received March 23, 2021

Revised July 23, 2021

Accepted September 4, 2021

*Corresponding author

Seung Joon Choi, MD
Department of Radiology,
Gil Medical Center,
Gachon University
College of Medicine,
21 Namdong-daero 774beon-gil,
Namdong-gu, Incheon 21565,
Korea.

Tel 82-32-460-3059

Fax 82-32-460-3045

E-mail sjchoi1118@gmail.com

This is an Open Access article distributed under the terms of the Creative Commons Attribution Non-Commercial License (<https://creativecommons.org/licenses/by-nc/4.0>) which permits unrestricted non-commercial use, distribution, and reproduction in any medium, provided the original work is properly cited.

ORCID iDs

Seohyun Kim

<https://orcid.org/0000-0003-4638-4903>

Seung Joon Choi

<https://orcid.org/0000-0003-3861-7682>

Su Joa Ahn

<https://orcid.org/0000-0001-9026-0399>

So Hyun Park

<https://orcid.org/0000-0001-9935-2863>

Young Sup Shim

<https://orcid.org/0000-0002-8214-2904>

Jeong Ho Kim

<https://orcid.org/0000-0002-1404-2821>

of subepithelial tumors is increasing with the widespread use of endoscopy and CT for screening (3-5).

Although small subepithelial tumors are mostly asymptomatic, some may cause pain, bleeding, or obstruction and are potentially malignant. The most common subepithelial tumors are gastrointestinal stromal tumors (GISTs), leiomyomas, lipomas, granular cell tumors, ectopic pancreas, and carcinoid tumors. Several guidelines recommend regular surveillance for small gastric subepithelial tumors without high-risk findings on endoscopic US (EUS) (6-8), owing to the low probability of malignancy. Nevertheless, the concern about the possibility of malignancy prompts some clinicians and patients to consider tumor resection despite the medical risks and high costs.

For small bowel GISTs, guidelines recommend surgical resection regardless of tumor size because the risk of disease progression may be higher compared to gastric GISTs (6, 7, 9). However, few studies have investigated the clinical course of incidentally detected small subepithelial tumors of the small bowel on CT, although previous studies (10, 11) have shown a slow size increase in small subepithelial tumors of the stomach during upper endoscopies.

Therefore, in the present study, we aimed to investigate the clinical course and imaging findings of incidentally detected small subepithelial tumors of the small bowel.

MATERIALS AND METHODS

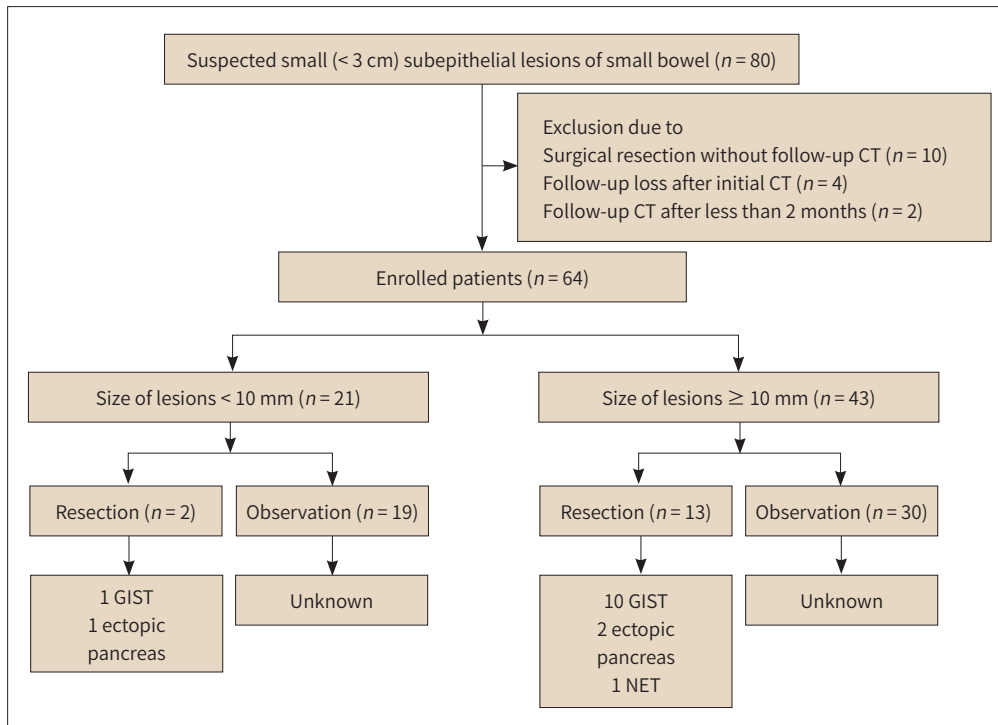
PATIENTS

This retrospective study was approved by our Institutional Review Board, which waived the requirement for informed consent (IRB No. GBIRB2021-037). We collected computerized medical records and searched the Picture Archiving and Communication System (PACS) for patients with subepithelial tumors of the small bowel detected on CT between January 2005 and December 2020. The inclusion criteria were as follows: 1) suspected subepithelial tumors of the small bowel, 2) available contrast-enhanced CT images, 3) follow-up CT interval of > 2 months, and 4) tumors < 3 cm in maximum diameter on initial CT. The exclusion criteria were as follows: 1) surgical resection and/or chemotherapy without a follow-up CT examination, 2) loss to follow-up after the initial CT, and 3) < 2 months interval between the initial and follow-up CT. The follow-up duration was defined as the time from the initial CT with a visualized tumor to the last CT examination before the operation. Finally, 64 patients with 64 subepithelial tumors were enrolled in this study (Fig. 1).

CT ACQUISITION

The patients underwent contrast-enhanced multidetector CT, including triple-phase (arterial, portal venous, and delayed phases), double-phase (arterial and portal venous phases), and single-phase (portal venous phase) CT using 16-, 64-, or 128-detector scanners (Sensation 16, Somatom Definition 64, Somatom Definition Flash, and Somatom Force; Siemens Medical Solutions, Erlangen, Germany). Arterial and portal venous phase images were obtained with delays of 13–18 s and 50–75 s, respectively, owing to the time required to achieve 100 Hounsfield unit enhancement of the descending aorta using a bolus-tracking method. Only portal venous phase images were obtained 60–75 s after contrast agent administration. De-

Fig. 1. Flow diagram of the inclusion of participants in the study.



GIST = gastrointestinal stromal tumor, NET = neuroendocrine tumor

layered scanning was performed with a fixed delay of 3 minutes after the start of contrast agent administration. Multiphase dynamic CT evaluations were performed in 107 cases: arterial and portal venous phases in 101 cases, and arterial, portal, and delayed phases in 6 cases. In the remaining 21 cases, only portal phase scanning was performed.

A nonionic contrast agent (iohexol, Bonorex 300, Central Medical System, Seoul, Korea; iopamidol, Pamiray, Dongkook Pharmaceutical, Seoul, Korea; or iopromide, Ultravist 300, Bayer Schering Pharma, Berlin, Germany) was injected at a volume of 1.5–2.0 mL/kg body weight (maximum 150 mL) through an 18-gauge peripheral venous access at a flow rate of 3–4 mL/s using an automatic power injector (OptiVantage, Liebel-Flarsheim; Mallinckrodt, Neustadt, Germany).

IMAGE ANALYSIS

Two board-certified abdominal radiologists with 7 years (S.J.A.) and 9 years (S.J.C.) of experience reviewed the CT findings in consensus. They were blinded to the demographic findings and histopathologic results.

The following findings were evaluated: number of lesions; tumor diameter, volume, location, contour, margin, and growth pattern; degree and pattern of enhancement; and presence of necrosis, calcification, surface ulceration, and lymph node enlargement. The tumor diameter was defined as the greatest length on transverse, coronal, or sagittal CT images. Tumor volumes were calculated through area summation using an area-measuring tool; that is, in each case, the tumor areas on cross-sections were traced using the area-measuring tool of

PACS, the cross-sectional areas were summed, and the sum was multiplied by the section thickness. The volume doubling times (VDTs) were calculated using Schwartz's equation (12):

$$\text{VDT} = (T - T_0) \times \log 2 / (\log V - \log V_0)$$

where V_0 and V indicate the volume on the initial and follow-up scans, respectively, and $T-T_0$ indicates the elapsed time between measurements. The tumor diameters and volumes were independently measured by the two radiologists, and the mean values were recorded. The location was divided into the duodenum, jejunum, and ileum. The contour and margin were classified as round or lobulated and well-defined or ill-defined, respectively. The tumor growth pattern was categorized as endophytic, exophytic, or mixed. A tumor that was attached to the bowel wall and completely surrounded by the bowel lumen without bulging toward the extraluminal space was defined to have an endophytic growth pattern. A mass confined to the extraluminal space without bulging into the bowel lumen was defined to have an exophytic growth pattern. Tumors that did not belong to either of the first two patterns were defined to have a mixed growth pattern. The degree of enhancement of the tumor was compared with that of the overlying or adjacent normal bowel mucosa and was divided into low, iso, and high density. The enhancement pattern was classified as homogeneous or heterogeneous. Necrosis within the lesion was considered present when nonenhancing and hypoenhancing areas were observed within the tumor. Surface ulcerations were considered present if there was a focal margin defect on the endoluminal surface of the lesion. Lymph nodes with a short diameter of > 1 cm were considered enlarged lymph nodes (13-15).

STATISTICAL ANALYSIS

Fisher's exact test was used for the analysis of morphologic CT findings. The Mann-Whitney U test was used for continuous variables. SPSS software (version 25.0; IBM Corp., Armonk, NY, USA) was used for statistical analysis. Statistical significance was set at $p < 0.05$.

RESULTS

Table 1 shows the baseline characteristics of the 64 enrolled patients. The median age was 63 years (range, 26-87 years), and the male-to-female ratio was 0.94:1 (31 male, 33 female). The median follow-up duration was 15.8 months (interquartile range [IQR] 6.0-47.8; range 2.4-186.9). The patients underwent two to 15 (median, 3) CT scans (44 patients underwent < 5 CT scans and 20 patients underwent ≥ 5 CT scans). The median initial diameter of the tumors was 14.5 mm (IQR, 9.0-19.1; range, 6.5-29.0). The jejunum (53%) was the most common location of small-bowel subepithelial tumors, followed by the duodenum (42%) and ileum (5%). The median follow-up diameter of the tumors was 15.3 mm (IQR, 10.5-20.1; range, 6.5-49.0). The median initial and follow-up tumor volumes were 116.0 mm³ (IQR, 33.5-353.6; range, 15.5-1307.0) and 149.8 mm³ (IQR, 38.5-394.5; range, 19.1-5824.5), respectively. The median diameter and volume growth rates were 0.02 mm/month (IQR, 0-0.1; range, -0.3-1.3) and 1.5 mm³/month (IQR, 0.4-3.9; range, 0.01-153.8), respectively. The median VDT was 81.1 months (IQR, 27.2-251.3; range, 3.2-1784.0).

Table 1. Baseline Characteristics of Patients

	All Tumors (n = 64)
Age, years	63
Sex, male/female	31/33 (48/52)
Location of tumors	
Duodenum	27 (42)
Jejunum	34 (53)
Ileum	3 (5)
Initial diameter, mm	15.0 (6.3)
< 10	21 (33)
≥ 10	43 (67)
Follow-up diameter, mm	15.3 (6.5–49)
Diameter growth rate, mm/month	0.02 (0–0.1)
Initial volume, mm ³	116.0 (33.5–353.6)
Follow-up volume, mm ³	149.8 (38.5–394.5)
Volume growth rate, mm ³ /month	1.5 (0.4–3.9)
Volume doubling time, months	81.1 (27.2–251.3)
Follow-up interval, months	15.8 (6.0–47.8)

Data are expressed as median (interquartile range) or n (%), unless otherwise specified.

Of the 64 tumors, 21 and 43 had an initial diameter of < 10 and ≥ 10 mm, respectively (Table 2). The smaller group (tumors with an initial diameter of < 10 mm) showed a slower volume growth rate than the larger group (tumors with an initial diameter of ≥ 10 mm). The initial tumor diameter was associated with the follow-up diameter, initial and follow-up volumes, and volume growth rate ($p < 0.05$). In addition, contour, enhancement pattern, and presence of necrosis were associated with the initial diameter of the tumors ($p < 0.05$).

We divided the tumors into slowly growing and rapidly growing tumors based on the median volume growth rate (1.5 mm³/month) (Table 3). Slowly and rapidly growing tumors were defined as tumors with a volume growth rate of ≤ 1.5 and > 1.5 mm³/month, respectively. The initial and follow-up diameters, initial and follow-up volumes, volume growth rate, and VDTs were significantly different between slowly and rapidly growing tumors. The rapidly growing group tended to more frequently have a lobulated contour, heterogeneous enhancement, and necrotic change than the slowly growing group.

Surgical resection was performed for 15 tumors, which were diagnosed as GISTs with a low ($n = 8$), intermediate ($n = 2$), or high risk of malignancy ($n = 1$); ectopic pancreas ($n = 3$); and neuroendocrine tumor ($n = 1$) (Figs. 1–3). Among tumors ≤ 1 cm ($n = 21$), two tumors were surgically resected (one diagnosed as GIST with a low risk of malignancy and one diagnosed as ectopic pancreas). The reasons for not performing surgery were as follows: follow-up loss ($n = 18$), refusal of surgery ($n = 13$), inoperable cases ($n = 8$), and unknown cause ($n = 10$).

DISCUSSION

Our study demonstrated that the diameter and volume growth rates of small (< 30 mm) sus-

Table 2. CT Findings and Growth Rate of the Subepithelial Tumors according to the Initial Diameter

	Initial Tumoral Diameter < 10 mm (n = 21)	Initial Tumoral Diameter ≥ 10 mm (n = 43)	p-Value
Contour			0.006
Round	21 (100)	31 (72)	
Lobulated	0	12 (28)	
Margin			NS
Well defined	21 (100)	43 (100)	
Ill defined	0	0	
Growth pattern			NS
Endoluminal	20 (95)	43 (100)	
Exophytic or mixed	1 (5)		
Enhancement pattern			0.037
Homogeneous	19 (90)	28 (65)	
Heterogeneous	2 (10)	15 (35)	
Enhancement degree			NS
High density	20 (95)	36 (84)	
Iso or low density	1 (5)	7 (16)	
Necrosis	2 (10)	15 (35)	0.037
Calcification	0	2 (5)	NS
Surface ulceration	0	0	NS
LN enlargement	0	0	NS
Follow-up diameter, mm	9.0 (7.5–9.0)	18.0 (14.7–22.5)	< 0.001
Diameter growth rate, mm/month	0.02 (0–0.05)	0.01 (0–0.1)	NS
Initial volume, mm ³	27.5 (23.5–32)	317.0 (116.0–379.7)	< 0.001
Follow-up volume, mm ³	31.5 (27.5–38.5)	365.0 (136.0–409.2)	< 0.001
Volume growth rate, mm ³ /month	0.2 (0.1–0.5)	2.2 (0.7–6.2)	< 0.001
Volume doubling time, months	97.7 (40.5–251.6)	70.6 (24.3–239.6)	NS

Data are expressed as *n* (%) or median (interquartile range), unless otherwise specified.
LN = lymph node, NS = not significant

pected subepithelial tumors of the small bowel were 0.02 mm/month and 1.5 mm³/month, respectively. The smaller group (tumors with an initial diameter of < 10 mm) showed smaller follow-up diameter and volume and slower volume growth rate than the larger group (tumors with an initial diameter of ≥ 10 mm). In addition, the larger group tended to more frequently have a lobulated contour, heterogeneous enhancement, and necrotic change than the smaller group.

Small subepithelial tumors of the small bowel are clinically important because they may be malignant or have a malignant potential. Although surgical resection is recommended for small intestinal GISTs (6, 7), there have been relatively few studies on the natural clinical course of small non-gastric GISTs compared to gastric GISTs.

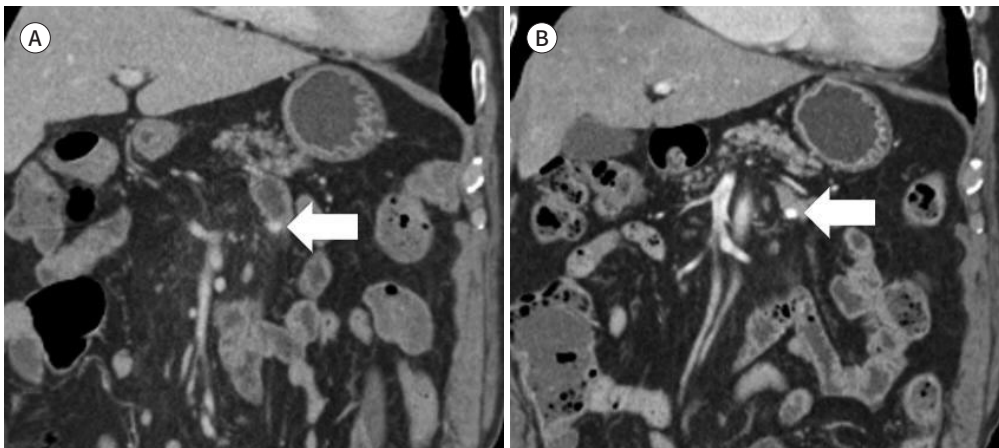
Prior studies have reported that because most small subepithelial tumors of the stomach do not show size increments that could raise the suspicion for malignancy, surveillance as a conservative management is safe. According to the classification system proposed by the Na-

Table 3. Size and Growth Rate of the Slowly and Rapidly Growing Tumors

	Slowly Growing Tumors ($\leq 1.5 \text{ mm}^3/\text{month}$) ($n = 32$)	Rapidly Growing Tumors ($> 1.5 \text{ mm}^3/\text{month}$) ($n = 32$)	<i>p</i> -Value
Initial diameter, mm	9.2 (9.0–15.6)	16.2 (12.5–21.0)	< 0.001
Follow-up diameter, mm	11.0 (10.0–15.6)	18.7 (14.1–26.7)	< 0.001
Diameter growth rate, mm/month	0.01 (0.005–0.04)	0.06 (0–0.1)	NS
Initial volume, mm^3	47.0 (27.5–176.6)	278.2 (97.2–547.5)	0.001
Follow-up volume, mm^3	58.2 (31.3–215.0)	367.5 (122.5–1277.2)	0.003
Volume growth rate, mm^3/month	0.4 (0.1–0.6)	3.8 (2.2–9.3)	< 0.001
Volume doubling time, months	224.1 (68.8–343.3)	28.2 (16.1–109.8)	< 0.001
Contour			0.003
Round	31 (97)	21 (66)	
Lobulated	1 (3)	11 (34)	
Enhancement pattern			0.004
Homogeneous	29 (91)	18 (56)	
Heterogeneous	3 (9)	14 (44)	
Necrosis	3 (9)	14 (44)	0.004

Data are expressed as median (interquartile range) or *n* (%), unless otherwise specified.
NS = not significant

Fig. 2. An 87-year-old male with a suspected small subepithelial tumor (8 mm) of the jejunum. CT images show no interval change in the subepithelial tumor of the proximal jejunum from (A) baseline to (B) the 45-month follow-up (arrows).



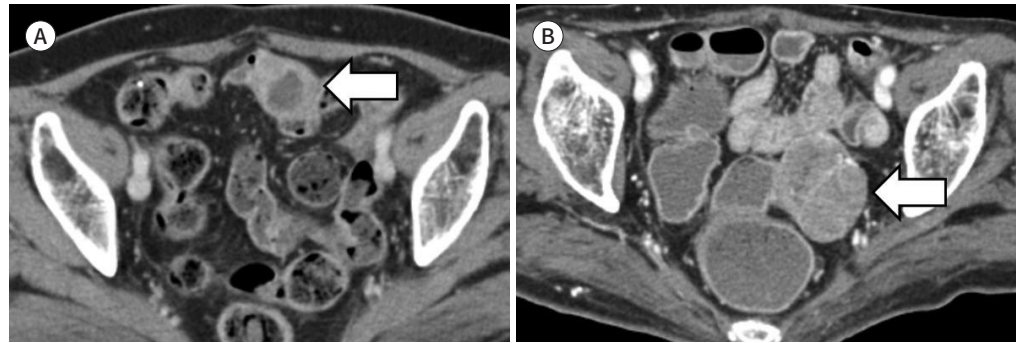
tional Institutes of Health Consensus Conference, small GISTs (< 2 cm) have a very low malignant potential (16). Tio et al. (17) observed that small (< 3 cm) subepithelial tumors did not significantly change over a period of 1–3 years. Lim et al. (18) reported that small (< 3 cm) subepithelial tumors did not change over 83 months of endoscopic follow-ups. Melzer and Fiddler (19) reported no significant increase in the size of small (< 4 cm) subepithelial tumors over a mean period of 19 months.

However, these studies evaluated subepithelial tumors confined to the stomach that could be accessed using the endoscopic approach. In the endoscopic approach, the size measurements can differ according to the operator. Moreover, the approach does not allow accurate

Fig. 3. A 76-year-old female with suspected subepithelial tumor of the ileum.

A. Axial CT image shows a 2.6-cm, lobulated, contoured, and heterogeneously enhancing mass in the proximal ileum (arrow).

B. Follow-up CT image after 16 months shows increased size of the subepithelial tumor in the ileum (4.5 cm, arrow) that was surgically resected, and the pathologic diagnosis was gastrointestinal stromal tumor with a high risk of malignancy.



differentiation between intramural and extramural lesions.

The purpose of surveillance is to identify small subepithelial tumors with a malignant potential and to determine the appropriate time for resection. Several management guidelines have been proposed for small gastric subepithelial tumors. The recommendations from different countries and associations differ for gastric GISTs. The European Society for Medical Oncology and the European Society for Gastrointestinal Endoscopy suggest initial EUS after 3 months of detection, followed by annual follow-up for asymptomatic small gastric GISTs (< 2 cm) without evidence of a high risk of malignancy based on EUS features (irregular border, cystic space, ulceration, echogenic foci, and heterogeneity) (7). The National Comprehensive Cancer Network highly recommends follow-ups at intervals of 6–12 months for incidentally discovered small gastric GISTs (< 2 cm) without high-risk EUS features (6). The Japan Gastroenterological Endoscopy Society suggests that a follow-up interval of 1–2 years is sufficient for such small lesions, and the French guidelines recommend EUS follow-up at 6 and 18 months and every 2 years thereafter (20, 21).

The American Gastroenterological Association recommends that subepithelial tumors > 30 mm in size originating in the muscularis propria with hypoechoic and malignant echo patterns should be surgically resected, whereas those < 30 mm in size without malignant EUS features can be periodically followed up to identify changes in the lesions (22). In clinical practice, very small gastric subepithelial tumors (< 10 mm in size) should be endoscopically assessed within 1 year after diagnosis (23), whereas gastric subepithelial tumors 10–30 mm in size should be assessed with EUS at intervals of 3 months to 2 years (7, 11, 23).

According to previous studies, small bowel GISTs have a more aggressive course and biology than gastric stromal tumors (24, 25). Hence, guidelines recommend that surgery is indicated irrespective of size due to the higher malignant potential of small bowel GISTs (6, 7, 9, 26). Miettinen et al. (25) showed that small bowel GISTs are more aggressive than gastric GISTs and this should be factored into the risk assessment of a primary tumor. They demonstrated that almost all small bowel GISTs \leq 2 cm had low mitotic activity \leq 5 mitoses per 50 high-power fields (HPFs) (> 97%), and the group with tumor size \leq 2 cm and \leq 5 mitoses per 50 HPF

had no tumor-related mortality, similar to corresponding gastric GISTs. There are little data on small tumors ≤ 2 cm with mitotic activity > 5 mitoses per 50 HPF because such tumors are very rare, as mitotically active tumors mostly grow larger than the 2 cm. In addition, the median size of enrolled small bowel GISTs was relatively large (median 7 cm; range, 0.3–40.0 cm) in this study. Similarly, Dematteo et al. (27) reported that patients with gastric GISTs have a more favorable course than small intestinal GISTs. However, the median size of the enrolled tumors was also relatively large (median 6 cm; range 0.3–50.0 cm) in their study. Therefore, to predict the clinical course and prognosis of small bowel GISTs, it is necessary to correct the enrolled tumor size; further studies enrolling small GISTs of small bowel are needed.

In the present study, a significant correlation was found between the initial size and the growth rate of small-bowel subepithelial tumors, which is consistent with previous reports on gastric subepithelial tumors (10, 23). Prior studies reported that subepithelial tumors < 10 mm in size showed slower growth rates than larger lesions in the stomach (10, 23). In this study, there were no GISTs with an intermediate or high risk of malignancy among the very small bowel subepithelial tumors (< 10 mm), whereas subepithelial tumors 14–30 mm in size were diagnosed as GISTs with an intermediate or high risk of malignancy. Although guidelines recommend surgical resection, based on our results, regular CT follow-up for small and asymptomatic small intestinal subepithelial tumors may be carefully recommended for patients who are unable to undergo or refuse surgery. In addition, it is recommended to use a dedicated small bowel protocol CT, such as CT enterography, for follow-up imaging. Identification of small bowel tumors in conventional CT is often limited by the bowel peristalsis, degree of distension or mesenteric redundancy. CT enterography improves the detection and characterization of small bowel tumors by achieving adequate small bowel distension, and reducing peristalsis (28–30).

Morphologic CT findings can be used as a rationale for tumor growth. Previous studies have shown that heterogeneous enhancement and the presence of necrosis are highly suggestive CT findings for GISTs in the differentiation from benign lesions such as schwannomas or leiomyomas (13, 14). Consistent with prior studies on gastric subepithelial tumors, our study also showed that CT findings of heterogeneous enhancement and the presence of necrosis indicate the possibility of size increments. Therefore, for such tumors, clinicians should actively recommend surgical removal and provide patients with sufficient information about their disease.

This study had some limitations. As this was a retrospective study, the CT protocols and follow-up intervals could not be standardized. Moreover, only a small number of patients from a single center were included. The number of pathologically proven tumors was too small to assess significant radiological differences between GISTs and non-GISTs.

In conclusion, subepithelial tumors less than 10 mm in size grew more slowly than tumors of 10 to 30 mm. In addition, the larger tumors showed a lobulated contour, heterogeneous enhancement, and necrotic change compared to smaller tumors. Although, for small intestinal GIST, surgical resection is recommended, further prospective, multicenter studies may consider to validate the usefulness of regular CT follow-up for small and asymptomatic small bowel subepithelial tumors in patients who are unable or refuse surgical resection.

Author Contributions

Conceptualization, C.S.J.; data curation, K.S., C.S.J.; formal analysis, K.S., C.S.J.; investigation, K.S., C.S.J.; methodology, K.S., C.S.J.; project administration, K.S., C.S.J.; resources, K.S., C.S.J.; software, K.S., C.S.J.; supervision, K.S., C.S.J.; validation, K.S., C.S.J., A.S.J.; visualization, K.S., C.S.J.; writing—original draft, all author; and writing—review & editing, all author.

Conflicts of Interest

The authors have no potential conflicts of interest to disclose.

Funding

None

REFERENCES

- Hedenbro JL, Ekelund M, Wetterberg P. Endoscopic diagnosis of submucosal gastric lesions. The results after routine endoscopy. *Surg Endosc* 1991;5:20-23
- Papanikolaou IS, Triantafyllou K, Kourikou A, Rösch T. Endoscopic ultrasonography for gastric submucosal lesions. *World J Gastrointest Endosc* 2011;3:86-94
- Kawanowa K, Sakuma Y, Sakurai S, Hishima T, Iwasaki Y, Saito K, et al. High incidence of microscopic gastrointestinal stromal tumors in the stomach. *Hum Pathol* 2006;37:1527-1535
- Nilsson B, Bümming P, Meis-Kindblom JM, Odén A, Dortok A, Gustavsson B, et al. Gastrointestinal stromal tumors: the incidence, prevalence, clinical course, and prognostication in the preimatinib mesylate era—a population-based study in western Sweden. *Cancer* 2005;103:821-829
- Patel N, Benipal B. Incidence of gastrointestinal stromal tumors in the United States from 2001-2015: a United States cancer statistics analysis of 50 states. *Cureus* 2019;11:e4120
- Demetri GD, von Mehren M, Antonescu CR, DeMatteo RP, Ganjoo KN, Maki RG, et al. NCCN Task Force report: update on the management of patients with gastrointestinal stromal tumors. *J Natl Compr Canc Netw* 2010;8 Suppl 2:S1-41; quiz S42-S44
- Casali PG, Abecassis N, Aro HT, Bauer S, Biagini R, Bielack S, et al. Gastrointestinal stromal tumours: ESMO-EURACAN Clinical Practice Guidelines for diagnosis, treatment and follow-up. *Ann Oncol* 2018;29:iv267
- Cho JW; Korean ESD Study Group. Current guidelines in the management of upper gastrointestinal subepithelial tumors. *Clin Endosc* 2016;49:235-240
- Nishida T. Asian consensus guidelines for gastrointestinal stromal tumor: what is the same and what is different from global guidelines. *Transl Gastroenterol Hepatol* 2018;3:11
- Kim MY, Jung HY, Choi KD, Song HJ, Lee JH, Kim DH, et al. Natural history of asymptomatic small gastric subepithelial tumors. *J Clin Gastroenterol* 2011;45:330-336
- Ye LS, Li Y, Liu W, Yao MH, Khan N, Hu B. Clinical course of suspected small gastrointestinal stromal tumors in the stomach. *World J Gastrointest Surg* 2020;12:171-177
- Schwartz M. A biomathematical approach to clinical tumor growth. *Cancer* 1961;14:1272-1294
- Choi JW, Choi D, Kim KM, Sohn TS, Lee JH, Kim HJ, et al. Small submucosal tumors of the stomach: differentiation of gastric schwannoma from gastrointestinal stromal tumor with CT. *Korean J Radiol* 2012;13:425-433
- Choi YR, Kim SH, Kim SA, Shin CI, Kim HJ, Kim SH, et al. Differentiation of large (≥ 5 cm) gastrointestinal stromal tumors from benign subepithelial tumors in the stomach: radiologists' performance using CT. *Eur J Radiol* 2014;83:250-260
- Cai PQ, Lv XF, Tian L, Luo ZP, Mitteer RA Jr, Fan Y, et al. CT characterization of duodenal gastrointestinal stromal tumors. *AJR Am J Roentgenol* 2015;204:988-993
- Fletcher CD, Berman JJ, Corless C, Gorstein F, Lasota J, Longley BJ, et al. Diagnosis of gastrointestinal stromal tumors: a consensus approach. *Hum Pathol* 2002;33:459-465
- Tio TL, Tytgat GN, den Hartog Jager FC. Endoscopic ultrasonography for the evaluation of smooth muscle tumors in the upper gastrointestinal tract: an experience with 42 cases. *Gastrointest Endosc* 1990;36:342-350
- Lim YJ, Son HJ, Lee JS, Byun YH, Suh HJ, Rhee PL, et al. Clinical course of subepithelial lesions detected on

upper gastrointestinal endoscopy. *World J Gastroenterol* 2010;16:439-444

19. Melzer E, Fidler H. The natural course of upper gastrointestinal submucosal tumors: an endoscopic ultrasound survey. *Isr Med Assoc J* 2000;2:430-432
20. Nishida T, Kawai N, Yamaguchi S, Nishida Y. Submucosal tumors: comprehensive guide for the diagnosis and therapy of gastrointestinal submucosal tumors. *Dig Endosc* 2013;25:479-489
21. Landi B, Blay JY, Bonvalot S, Brasseur M, Coindre JM, Emile JF, et al. Gastrointestinal stromal tumours (GISTs): French Intergroup Clinical Practice Guidelines for diagnosis, treatments and follow-up (SNFGE, FFCD, GERCOR, UNICANCER, SFCD, SFED, SFRO). *Dig Liver Dis* 2019;51:1223-1231
22. Hwang JH, Rulyak SD, Kimmey MB; American Gastroenterological Association Institute. American Gastroenterological Association Institute technical review on the management of gastric subepithelial masses. *Gastroenterology* 2006;130:2217-2228
23. Song JH, Kim SG, Chung SJ, Kang HY, Yang SY, Kim YS. Risk of progression for incidental small subepithelial tumors in the upper gastrointestinal tract. *Endoscopy* 2015;47:675-679
24. Miettinen M, Lasota J. Gastrointestinal stromal tumors: pathology and prognosis at different sites. *Semin Diagn Pathol* 2006;23:70-83
25. Miettinen M, Makhlof H, Sobin LH, Lasota J. Gastrointestinal stromal tumors of the jejunum and ileum: a clinicopathologic, immunohistochemical, and molecular genetic study of 906 cases before imatinib with long-term follow-up. *Am J Surg Pathol* 2006;30:477-489
26. Koo DH, Ryu MH, Kim KM, Yang HK, Sawaki A, Hirota S, et al. Asian consensus guidelines for the diagnosis and management of gastrointestinal stromal tumor. *Cancer Res Treat* 2016;48:1155-1166
27. Dematteo RP, Gold JS, Saran L, Gönen M, Liau KH, Maki RG, et al. Tumor mitotic rate, size, and location independently predict recurrence after resection of primary gastrointestinal stromal tumor (GIST). *Cancer* 2008;112:608-615
28. Sokhandon F, Al-Katib S, Bahoura L, Copelan A, George D, Scola D. Multidetector CT enterography of focal small bowel lesions: a radiological-pathological correlation. *Abdom Radiol (NY)* 2017;42:1319-1341
29. Paulsen SR, Huprich JE, Fletcher JG, Booya F, Young BM, Fidler JL, et al. CT enterography as a diagnostic tool in evaluating small bowel disorders: review of clinical experience with over 700 cases. *Radiographics* 2006;26:641-657; discussion 657-662
30. Elsayes KM, Al-Hawary MM, Jagdish J, Ganesh HS, Platt JF. CT enterography: principles, trends, and interpretation of findings. *Radiographics* 2010;30:1955-1970

전산화단층촬영에서 확인된 소장외 종양의 임상 경과 연구

김서현 · 최승준* · 안수좌 · 박소현 · 심영섭 · 김정호

목적 이 연구의 목적은 CT에서 확인된 소장외 종양의 임상 경과를 밝히는 것이다.

대상과 방법 2005년 1월부터 2020년 12월까지 전산화단층촬영에서 소장외 종양이 의심되는 환자들을 분석했다. 최소 2개월 간격을 두고 시행한 2차례 이상 전산화단층촬영에서 30 mm 미만의 소장외 종양이 보인 환자를 연구에 포함시켰다. 저자들은 환자의 임상 정보, 병변의 소견 및 추적 관찰 영상에서의 변화를 기록하였다.

결과 총 64명의 환자에서 64개의 소장외 종양이 분석에 포함되었다. 추적관찰 기간의 중앙값인 15.8개월 동안 병변의 길이 변화와 부피 변화는 각각 0.02 mm/월, 1.5 mm³/월이었다. 소장외 종양의 초기 병변의 크기와 크기 변화속도는 통계적으로 유의한 연관성을 보였다. 추가적으로 10 mm 이상의 그룹은 10 mm 미만의 그룹보다 lobulated contour, 불균질한 조영증강, 괴사를 보이는 경우가 더 많았다.

결론 10 mm 미만의 소장외 종양이 10 mm 이상 30 mm 미만의 종괴보다 천천히 자란다.

가천대학교 의과대학 길병원 영상의학과