

# Right aortic arch with mirror image branching found incidentally during coronary surgery

SAGE Open Medical Case Reports  
Volume 9: 1–3  
© The Author(s) 2021  
Article reuse guidelines:  
sagepub.com/journals-permissions  
DOI: 10.1177/2050313X211030014  
journals.sagepub.com/home/sco



Girish N Rao<sup>1</sup>, Sabin S Sainudeen<sup>2</sup>, Samah Mohamed<sup>2</sup>,  
Maryam E Alkuwari<sup>2</sup>, Abdulaziz M Alkhulaifi<sup>1</sup>  
and Cornelia S Carr<sup>1</sup> 

## Abstract

Right aortic arch with a left innominate (brachiocephalic) artery with mirror image branching (RAMI) is a rare congenital anomaly, and it is unusual to diagnose it in adulthood. There are very few cases of cardiac surgery being performed for acquired cardiac disease on a congenital RAMI patient. We present a patient who had an incidental finding of a RAMI anomaly found during coronary artery bypass surgery. Post-operatively computerised tomography showed both his congenital lesions and his bypass grafts.

## Keywords

Right aortic arch, mirror image branching, coronary artery bypass surgery

Date received: 20 December 2020; accepted: 16 June 2021

## Introduction

Embryonic aortic development is complex and the final aortic arrangement is formed when some of the segments of the pharyngeal arch arteries regress, whereas others persist and become incorporated into the final anatomic structure. Aortic anomalies include left-sided, right-sided and double aortic arches with variable branching patterns. Aortic sidedness is determined by which bronchus is crossed by the arch.<sup>1</sup>

Anomalies of the aortic arch may cause vascular rings causing compression and may be associated with other congenital cardiac malformations as well as with underlying chromosomal abnormalities (22q11 deletion).<sup>1</sup>

Right aortic arch with aberrant left subclavian artery is usually associated with normal cardiac anatomy whereas more than 98% of cases of right aortic arch with a left innominate (brachiocephalic) artery with mirror image branching (RAMI) are associated with congenital heart defects, with Tetralogy of Fallot, truncus arteriosus, tricuspid atresia and transposition of the great arteries the usual malformations seen.<sup>2</sup> Echocardiography, cardiac magnetic resonance imaging and computed tomographic angiography are all used as imaging modalities to diagnose aortic arch anomalies.<sup>1,3</sup>

Coronary angiography is increasingly performed via the radial artery and therefore screening of the descending aorta

and arch of the aorta is no longer routine; this may lead to abnormalities of the aorta being missed pre-operatively.<sup>4</sup>

RAMI is a rare congenital anomaly, and it is unusual to diagnose it in adulthood. There are very few cases of cardiac surgery being performed for acquired cardiac disease on a patient with congenital RAMI.

## Case report

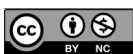A 50-year-old man presented with typical anginal pain (only known risk factor was hypertension). Initial investigations showed normal blood tests, a normal electrocardiogram (ECG) with the chest X-ray reported as normal apart from a tortuous descending thoracic aorta. Echocardiogram showed an ejection fraction of 55%, with no abnormalities reported. Coronary angiogram performed through the right radial artery (our hospital's first choice access point) showed

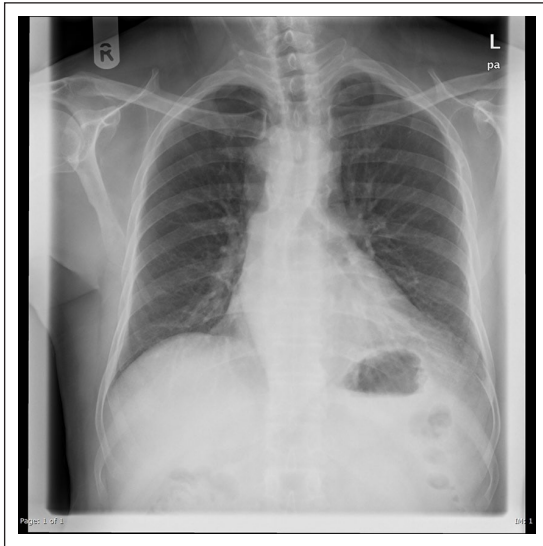<sup>1</sup>Department of Cardiothoracic Surgery, Heart Hospital, Doha, Qatar

<sup>2</sup>Department of Radiology, Heart Hospital, Doha, Qatar

### Corresponding Author:

Cornelia S Carr, Department of Cardiothoracic Surgery, Heart Hospital, Hamad Medical Corporation, PO Box 3050, Doha, Qatar.  
Email: ccarr@hamad.qa





**Figure 1.** Plain frontal chest X-ray showing widened superior mediastinum and a right-sided descending aorta.

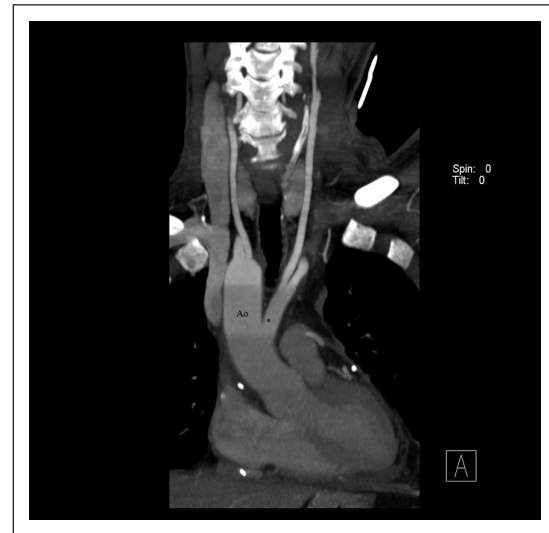
significant left main stem and three vessel coronary artery disease (aortogram not performed; when questioned later, the cardiologist reported no apparent problems with reaching the ascending aorta and cannulating the coronary ostia). He proceeded to coronary artery bypass graft surgery. At operation, the left internal mammary artery (LIMA) was harvested (normal anatomy) and had excellent flow. On opening the pericardium, it was noted that the ascending aorta bifurcated 2 cm below the pericardial reflection with the left branch noted to be half the size of the right branch. There was adequate ascending aorta to cannulate and perform coronary artery bypass grafts (saphenous vein to the right coronary and obtuse marginal arteries and LIMA to left anterior descending artery) in a routine manner. The post-operative course was completely uneventful.

Further review of the pre-operative chest X-ray suggested a right aortic arch (Figure 1). Post-operative computerised tomography (CT) of the Aorta confirmed a RAMI, with no evidence of tracheal or oesophageal compression (Figure 2). Reconstruction shows the malformation and the bypass grafts (Figure 3).

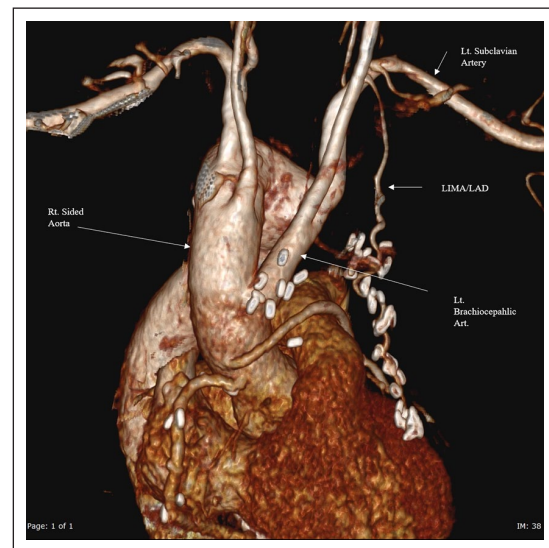
## Discussion

During embryonic development, six pairs of aortic arches develop, with the left fourth arch normally forming the final aortic arch seen after birth. The right fourth arch normally disappears, resulting in the normal mature aorta arching to the left and descending the thorax to the left of the spine. If the left fourth arch disappears and the right persists, a right aortic arch develops and if both persist, a double aortic arch (vascular ring) forms.

Right aortic arch is a rare congenital defect and there are several classifications proposed based on the arrangement



**Figure 2.** Oblique coronal computerised tomogram of aorta, maximum intensity projection (MIP), showing right aortic arch (Ao) and left innominate (\*) artery with mirror image branching.



**Figure 3.** A 3D volume rendering technique reconstruction showing RAMI anatomy with the left internal mammary artery and saphenous vein grafts present.

of the arch vessels, relationship with the oesophagus and whether there are associated congenital cardiac defects.<sup>5</sup> One classification suggests two variants: Type 1, the left subclavian artery originates with the left common carotid artery (or just proximal) and is effectively the mirror image of normal anatomy. Type 2, aberrant left subclavian artery arising as the last branch of the right-sided aortic arch or from a Kommerell's diverticulum (left dorsal aortic arch remnant).<sup>6</sup>

A right aortic arch is seen in 0.01%–0.1% of the population, and patients can present at any age with symptoms and

signs of airway or oesophageal compression, complications of cardiac defects or merely be picked up due to abnormal imaging.<sup>7,8</sup> RAMI found on CT scanning of adults is extremely rare, with a reported incidence of 0.012%–0.018% and is associated with aneurysmal dilatation of the aorta,<sup>9,10</sup> suggesting inherent weakness of the aortic wall compared to the normal configuration.

In RAMI, the first branch is the left innominate (brachiocephalic) artery, followed by the right carotid artery and then the right subclavian artery. While RAMI does not cause any compression, the patient may present due to the associated cardiac defects and is therefore usually found in childhood.<sup>1,7</sup>

Surgery for acquired cardiac disease has rarely been performed on RAMI patients, but a mitral valve replacement (rheumatic heart disease) has been reported,<sup>11</sup> but there are no reported cases of RAMI patients undergoing coronary artery bypass surgery. This patient had a short ascending aorta prior to the left innominate artery arising inside the pericardium, but fortunately, there was enough room for cannulation and both proximal ends of the bypass grafts to be secured to the aorta. The LIMA had completely normal anatomy and excellent flow; RAMI is associated with subclavian abnormalities and this could have impacted the use of this conduit.<sup>1,7</sup> The fact that the patient had RAMI increased the chance that there could have been other congenital anomalies, including those of the coronary arteries (ruled out by the coronary angiogram), but echocardiography and CT scanning showed no other abnormalities were present.

The increasing use of the radial artery for coronary artery catheterization means that abnormalities of the aorta and its branches may be less likely to be found pre-operatively and so aortic anomalies may be increasingly seen incidentally during cardiac surgery for acquired cardiac disease. The femoral approach for cardiac catheterization allows for screening of the whole aorta as the guidewires are advanced towards the heart under x-ray screening, so revealing the exact anatomy and any associated stenoses.

## Conclusion

RAMI is a rare congenital anomaly usually diagnosed in childhood due to the associated congenital cardiac defects (98%), and it is unusual to diagnose it in adulthood. There are very few cases of cardiac surgery being performed for acquired cardiac disease on a patient with congenital RAMI and we present such a case and its imaging.

## Declaration of conflicting interests

The author(s) declared no potential conflicts of interest with respect to the research, authorship, and/or publication of this article.

## Ethical approval

Our institution does not require ethical approval for reporting individual cases or case series.

## Funding

The author(s) received no financial support for the research, authorship, and/or publication of this article.

## Informed consent

Written informed consent was obtained from the patient(s) for their anonymized information to be published in this article.

## ORCID iD

Cornelia S Carr  <https://orcid.org/0000-0002-0247-220X>

## References

- Hanneman K, Newman B and Chan F. Congenital variants and anomalies of the aortic arch. *Radiographics* 2017; 37(1): 32–51.
- Glew D and Hartnell GG. The right aortic arch revisited. *Clin Radiol* 1991; 43(5): 305–307.
- Nada A, Cousins JP, Ahsan H, et al. Right aortic arch with mirror image branching pattern and isolated left brachiocephalic artery: a case report. *Radiol Case Rep* 2020; 15(10): 1786–1791.
- Aoun J, Hattar L, Dgayli K, et al. Update on complications and their management during transradial cardiac catheterization. *Expert Rev Cardiovasc Ther* 2019; 17(10): 741–751.
- Lee CH, Son JW and Park JS. Comprehensive three-dimensional analysis of right-sided aortic arch with multiple vascular anomalies. *BMC Cardiovasc Disord* 2004; 14: 104.
- Felson B and Palayew MJ. The two types of right aortic arch. *Radiology* 1963; 81: 745–759.
- Kanne JP and Godwin JD. Right aortic arch variants. *J Cardiovasc Comput Tomogr* 2010; 4(5): 293–300.
- Morosetti D, Di Stefano C, Mondillo M, et al. Right-sided aortic arch with mirror image branching and situs solitus: a case of a 79 years old woman. *Radiol Case Rep* 2019; 14(10): 1246–1251.
- Hayashi T, Ichikawa T, Yamamuro H, et al. Right aortic arch with mirror-image branching in adults: evaluation using CT. *Tokai J Exp Clin Med* 2018; 43(1): 30–37.
- Khitin L, Kim K, Phillips KD, et al. An aneurysm of right-sided aortic arch with mirror-image brachiocephalic branching. *J Thorac Imaging* 2005; 20(4): 307–309.
- Nair KKM, Ganapathi S, Inamdar S, et al. Incidentally detected right aortic arch with mirror image branching in a patient with rheumatic calcific mitral valve disease. *Natl Med J India* 2018; 31(1): 22–23.