

Case Report

Ruptured Intracranial Mycotic Aneurysm in Infective Endocarditis: A Natural History

Isabel Kuo,¹ Theodore Long,¹ Nathan Nguyen,² Bharat Chaudry,² Michael Karp,² and Nerses Sanossian³

¹ *University of Southern California Keck School of Medicine, Los Angeles, CA 90089, USA*

² *Division of Geriatric, Hospitalist, Palliative, and General Internal Medicine, Department of Medicine, LAC+USC Medical Center, University of Southern California Keck School of Medicine, 1200 N. State St. IRD 310, Los Angeles, CA 90033, USA*

³ *Department of Neurology, LAC+USC Medical Center, University of Southern California Keck School of Medicine, Los Angeles, CA 90033, USA*

Correspondence should be addressed to Nathan Nguyen, nnguyenmd@gmail.com

Received 18 April 2010; Revised 16 August 2010; Accepted 27 August 2010

Academic Editor: J. W. M. Van Der Meer

Copyright © 2010 Isabel Kuo et al. This is an open access article distributed under the Creative Commons Attribution License, which permits unrestricted use, distribution, and reproduction in any medium, provided the original work is properly cited.

Mycotic aneurysms are a rare cause of intracranial aneurysms that develop in the presence of infections such as infective endocarditis. They account for a small percentage of all intracranial aneurysms and carry a high-mortality rate when ruptured. The authors report a case of a 54-year-old man who presented with infective endocarditis of the mitral valve and acute stroke. He subsequently developed subarachnoid hemorrhage during antibiotic treatment, and a large intracranial aneurysm was discovered on CT Angiography. His lesion quickly progressed into an intraparenchymal hemorrhage, requiring emergent craniotomy and aneurysm clipping. Current recommendations on the management of intracranial Mycotic Aneurysms are based on few retrospective case studies. The natural history of the patient's ruptured aneurysm is presented, as well as a literature review on the management and available treatment modalities.

1. Introduction

Mycotic aneurysms (MAs), also known as infective or microbial aneurysms, are rare inflammatory neurovascular lesions that account for 0.7–6.5% of all intracranial aneurysms [1]. MAs are unique in their natural history and pathologic findings, with distinct angiographic features, and frequently develop at terminal arterial branches. Because their spontaneous rupture results in subarachnoid and intracerebral hemorrhage, they are associated with significant morbidity and mortality, as high as 60%–90% in earlier case studies, and 12–32% in more recent literature reviews [1, 2]. The following is a case report coupled with a methodical review of the presentation, diagnosis, complications, and management of MAs.

2. Case History

A 54-year-old Caucasian male with a history of IE complicated by cerebrovascular accident 15 years prior presented

to the emergency department complaining of slurred speech for the past two days. He reported that his lower mouth felt as though it had been “numbed by a dentist,” resulting in subjective dysarthria. At the time of presentation, he denied headaches, visual changes, nausea, vomiting, or numbness or weakness in the extremities.

The patient was febrile at 102.3 degrees Fahrenheit, and his cardiovascular exam revealed a 3/6 holosystolic murmur most prominent at the left midclavicular line with radiation to the axilla. The neurologic exam was significant for left facial weakness, subtle slurring of speech, and diffuse hyperreflexia of all four extremities. Marked clubbing of his fingers on both hands was appreciated.

The head CT showed an old left posterior cerebral artery infarct and prominent basal ganglia calcification, but neither active bleeding nor acute infarction. The MRI was significant for a small acute nonhemorrhagic infarct in the right frontal periventricular white matter as well as scattered punctate areas of chronic blood products (Figure 1).

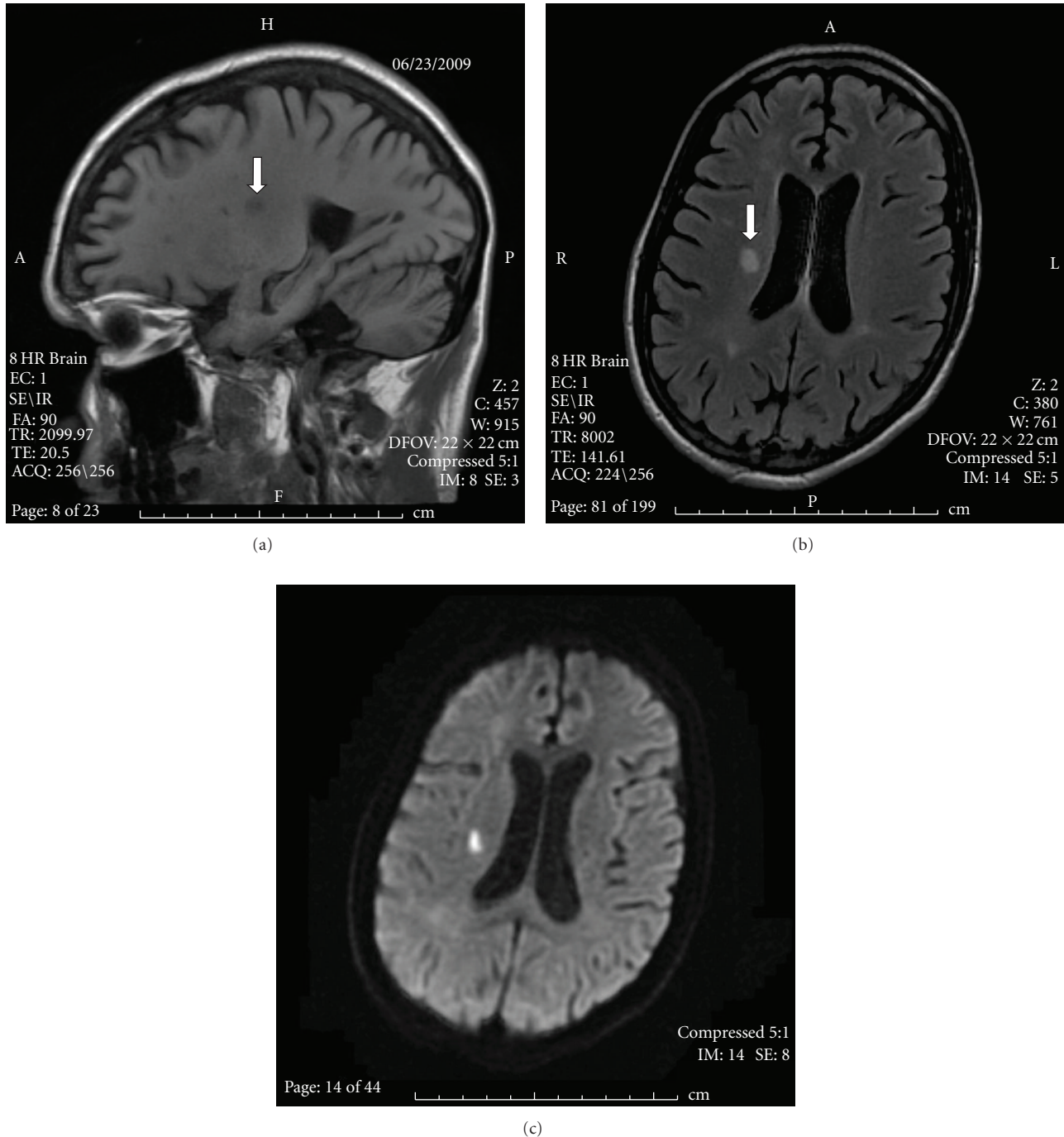


FIGURE 1: MRI of brain on presentation: (a) sagittal view showing acute right side frontal lobe infarct marked by arrow. (b) Axial view with same right side frontal lobe infarct marked by arrow. (c) Diffusion-Weighted Image of ischemic stroke in the right centrum semiovale.

The echocardiogram visualized large mobile vegetations on the mitral valve (Figure 2). 6 of 6 blood cultures were positive for *Streptococcus viridans*. Intravenous Penicillin G and Gentamicin were started immediately, and after 5 days of antibiotic treatment, the patient's dysarthria and left facial weakness improved.

Six days into antibiotic therapy, the patient complained of a severe headache and was noticeably slow to respond.

The slurred speech and left facial weakness also returned. A noncontrast CT head was repeated and showed acute subarachnoid hemorrhage (Figure 3). The patient's condition deteriorated; he became obtunded and required endotracheal intubation and mechanical ventilation.

The subsequent CT Cerebral Angiogram established a multilobulated cerebral aneurysm at the A3 segment of the right distal anterior cerebral artery measuring 13 mm by

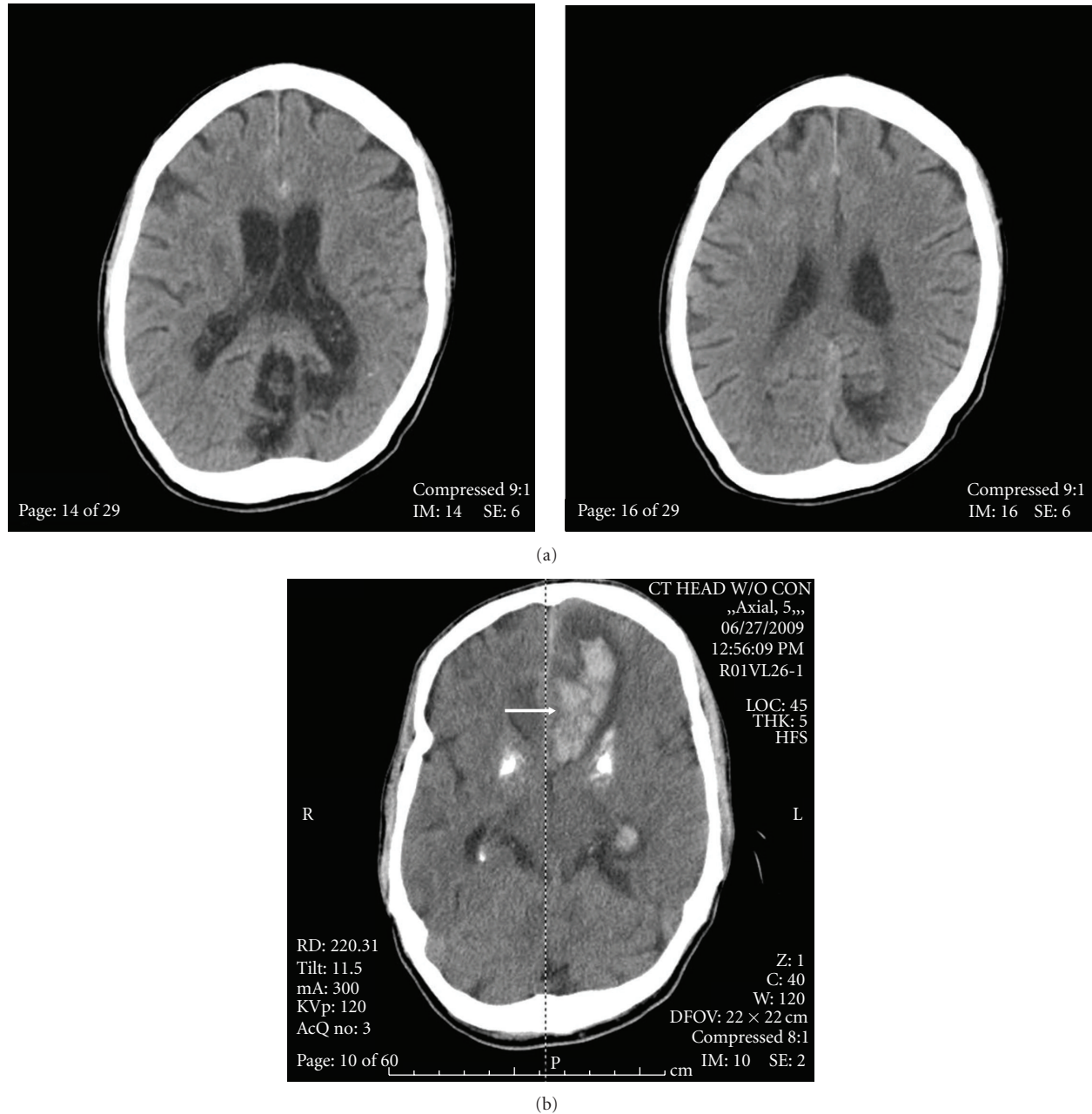


FIGURE 3: Progression of the ruptured Mycotic Aneurysm: (a) initial subarachnoid hemorrhage after 6 days IV antibiotics. Note interhemispheric hemorrhage. (b) Repeat noncontrast CT Brain 12 hours later, intraparenchymal hemorrhage is marked by arrow. Note prominent basal ganglia calcifications.

MAs could undergo spontaneous thrombosis, suggesting that MAs could resolve completely with antibiotic therapy alone [3]. In a review of 20 cases of MAs over a ten-year period by Chun in 2001, seven patients were initially treated conservatively with IV antibiotics alone and followed by serial angiography [12]. In this series, the aneurysms in two patients decreased in size, one did not change, two achieved successful thrombosis, and the remaining two enlarged. Based on this review, the conclusion regarding unruptured MAs is that medical management with 6 weeks of IV antibiotic therapy is reasonable if closely followed by

serial angiography. The goal of serial angiography would be to demonstrate improvement in aneurysm size and resolution. Zhao et al. reported a case in which a MA failed to show radiographic decrease in size after 2 weeks of medical therapy, and was successfully treated with endovascular therapy [13].

Endovascular therapy has rapidly evolved in its efficacy and ability to access more distal aneurysms. The safety profile of this intervention is difficult to interpret, as it is based only on anecdotal and case-report data. A meta-analysis was performed on 16 patients in previously published cases

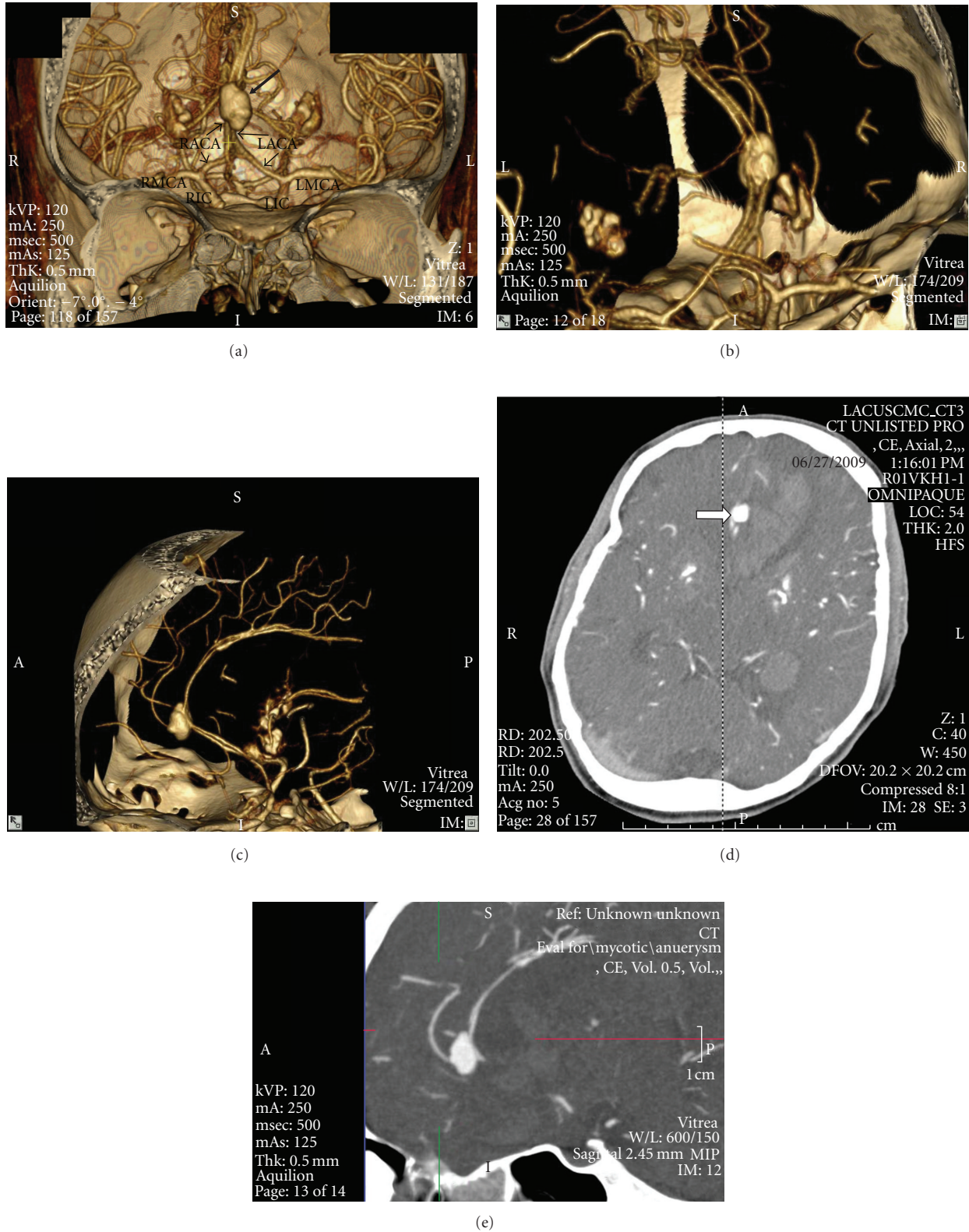


FIGURE 4: CT Cerebral angiogram showing a large fusiform aneurysm at the distal anterior cerebral artery (ACA). (a) Shaded Surface Display CT coronal view showing a large fusiform aneurysm at the distal segment of the ACA marked by the large arrow. Proximal ACA segments are marked by the smaller arrows. RIC: right internal carotid artery, LIC: left internal carotid artery, RMCA: right middle cerebral artery, LMCA-left middle cerebral artery, RACA and LACA are right and left anterior cerebral arteries, respectively. (b) Close-up coronal view of ACA mycotic aneurysm. (c) Additional sagittal view of mycotic aneurysm. (d) CT Angiogram axial view, an arrow marks the location of the ruptured aneurysm adjacent to a large hemorrhagic lesion. (e) CT Angiogram sagittal view demonstrating areas of intracerebral hemorrhage.

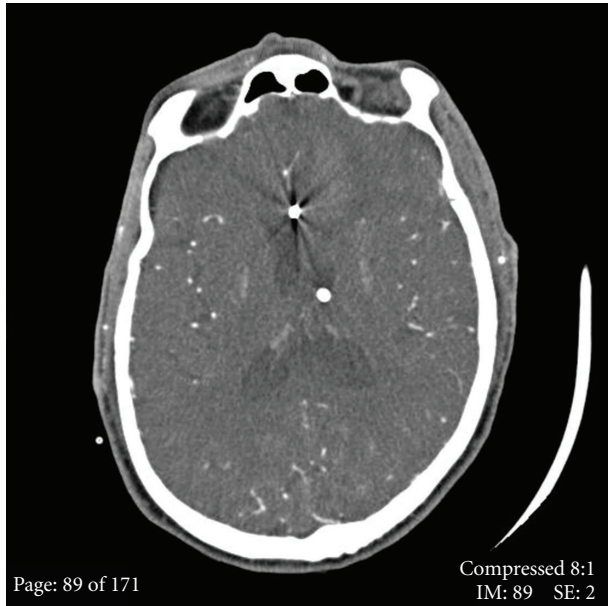


FIGURE 5: One week postoperative CT imaging demonstrating a metallic clip in the ACA, and a ventriculostomy in the lateral ventricle.

who underwent endovascular treatment; 69% had a good outcome, while none had procedural-related complications [12]. However, parent artery sacrifice was much more common in patients who underwent endovascular treatment versus open craniotomy with surgical ligation. This affects the management of diseased vessels supplying eloquent brain parenchyma, such as areas that involve language, sensorimotor cortex, visual cortex, hypothalamus, thalamus, cerebral peduncles, and brain stem.

In a retrospective review performed on 14 patients with intracranial MAs who underwent endovascular intervention at between 1991 and 1999 at a major French hospital [14], no deaths or complications were reported, 11 of the 14 patients showed stable lesions on followup angiography 6–24 months after endovascular embolization, and 9 had complete resolution of their presenting neurologic deficit [14]. Endovascular therapy is potentially safer and more effective than open craniotomy if performed at a high volume tertiary center and in the absence of increased ICP, mass effect, hypotension, hematoma, or involvement of eloquent territory.

Surgical therapy with open craniotomy and aneurysm clipping is reserved for patients with intraparenchymal hemorrhage, or for those who require clot evacuation and emergent reversal of increasing intracranial pressure. Another distinct advantage of surgical intervention is the option of vascular bypass to preserve distal blood flow, which is a vital consideration when the aneurysm involves eloquent territory.

3.5. Valvular Repair in the Setting of Intracranial Septic Emboli. The purpose of cardiac surgery is to remove the source of cerebral emboli and to improve hemodynamics [3].

Whether the aneurysm has ruptured influences the timing and sequence of cardiothoracic and neurosurgery [1].

Cardiac surgery is relatively safe if the MA is unruptured. Cardiopulmonary bypass, even with its requirement for heparinization, does not impose additional risks of rupture perioperatively [15]. In the absence of a hemorrhagic infarct, valve replacement can be performed with very little risk of perioperative stroke [16]. However, if the MA has ruptured and there is mass effect from an intracerebral hematoma or abscess, the intracranial aneurysm should be repaired first [3]. In the presence of cerebral infarction, the danger of hemorrhagic transformation warrants a 2–3 week postponement of cardiac surgery [1]. The exception to this rule would be if left heart failure were to develop as a consequence to IE. The presence of left heart failure would compromise cerebral perfusion, thus negating the benefits of any prior interventions performed on an intracranial MA. Hashimoto et al. reported a case in which a 24-year-old female with mitral valve IE and ruptured intracranial MA, safely underwent urgent mechanical mitral valve replacement for worsening congestive heart failure 10 days after suffering from an intracerebral hemorrhage. Neither the IE nor MA recurred in the postoperative 4 year followup period [17]. Shiraishi et al. reported a similar case in a 55 year old patient who presented with ruptured MA and left heart failure from aortic valve IE. In this case the patient underwent emergent bioprosthetic aortic valve replacement and did well with resolution of MA 9 months postoperatively [18].

3.6. Prognosis and Outcome. The general consensus in the current literature is that ruptured MAs carry a worse prognosis than unruptured MAs; however, the rarity of intracranial MAs makes it difficult to ascertain prognostic markers that may help predict likely outcomes. A comprehensive review of 27 clinical series and 287 patients with intracranial MA diagnosed between 1950–2009 was recently conducted by Ducruet et al. The analysis, while limited due to heterogeneity of presentations and variable followup duration, concluded that in all treatment modalities combined, 62% of patients had a positive outcome, 20% faced further neurological decline, 5% died before an invasive intervention could be performed, and 12% died immediately after an intervention was performed whether surgical or endovascular [19].

4. Summary

In the case of our patient, the diagnosis of an acute stroke was made early in the hospital course but a MA was not considered in the differential until after the patient had a subarachnoid hemorrhage. MA can be prevented from rupture when they are suspected and treated early. This case emphasizes the importance of considering the presence of MA in the differential diagnosis in the setting of suspected endocarditis and focal neurological deficits. If this constellation is present, MA should be investigated with CT Angiography. Frequent evaluations of neurological status should be performed, and a low threshold of suspicion for subarachnoid hemorrhage should be maintained. Finally, a neurosurgical consult

should be obtained to determine the appropriate therapeutic intervention once the diagnosis has been made.

Medical management should be reserved for patients with aneurysms that have not yet ruptured and should be followed closely with serial cerebral angiograms. Endovascular intervention should be based on the stability of the patient and involvement of eloquent territory. Surgical treatment should be performed emergently in the setting of intraparenchymal hemorrhage or increased intracranial pressure.

Acknowledgment

The authors acknowledge Gene Sung, MD.

References

- [1] S. Kannoth and S. V. Thomas, "Intracranial microbial aneurysm (infectious aneurysm): current options for diagnosis and management," *Neurocritical Care*, vol. 11, no. 1, pp. 120–129, 2009.
- [2] A. Watanabe, K. Hirano, and R. Ishii, "Cerebral mycotic aneurysm treated with endovascular occlusion—case report," *Neurologia Medico-Chirurgica*, vol. 38, no. 10, pp. 657–660, 1998.
- [3] R. B. Morawetz and R. B. Karp, "Evolution and resolution of intracranial bacterial (mycotic) aneurysms," *Neurosurgery*, vol. 15, no. 1, pp. 43–49, 1984.
- [4] Y. Nakata, S. Shionoya, and K. Kamiya, "Pathogenesis of mycotic aneurysm," *Angiology*, vol. 19, no. 10, pp. 593–601, 1968.
- [5] G. F. Molinari, "Septic cerebral embolism," *Stroke*, vol. 3, no. 2, pp. 117–122, 1972.
- [6] G. L. Bohmfalk, J. L. Story, J. P. Wissinger, and W. E. Brown Jr., "Bacterial intracranial aneurysm," *Journal of Neurosurgery*, vol. 48, no. 3, pp. 369–382, 1978.
- [7] I. Nakahara, M. M. Taha, T. Higashi et al., "Different modalities of treatment of intracranial mycotic aneurysms: report of 4 cases," *Surgical Neurology*, vol. 66, no. 4, pp. 405–409, 2006.
- [8] S. Kannoth, R. Iyer, S. V. Thomas et al., "Intracranial infectious aneurysm: presentation, management and outcome," *Journal of the Neurological Sciences*, vol. 256, no. 1-2, pp. 3–9, 2007.
- [9] S. Kannoth, S. V. Thomas, S. Nair, and P. S. Sarma, "Proposed diagnostic criteria for intracranial infectious aneurysms," *Journal of Neurology, Neurosurgery and Psychiatry*, vol. 79, no. 8, pp. 943–946, 2008.
- [10] M. N. Diringer, "Management of aneurysmal subarachnoid hemorrhage," *Critical Care Medicine*, vol. 37, no. 2, pp. 432–440, 2009.
- [11] A. J. P. Goddard, G. Tan, and J. Becker, "Computed tomography angiography for the detection and characterization of intra-cranial aneurysms: current status," *Clinical Radiology*, vol. 60, no. 12, pp. 1221–1236, 2005.
- [12] J. Y. Chun, W. Smith, V. Van Halbach, R. T. Higashida, C. B. Wilson, and M. T. Lawton, "Current multimodality management of infectious intracranial aneurysms," *Neurosurgery*, vol. 48, no. 6, pp. 1203–1214, 2001.
- [13] P. C. Zhao, J. Li, M. He, and C. You, "Infectious intracranial aneurysm: endovascular treatment with onyx case report and review of the literature," *Neurology India*, vol. 58, no. 1, pp. 131–134, 2010.
- [14] R. Chapot, E. Houdart, J.-P. Saint-Maurice et al., "Endovascular treatment of cerebral mycotic aneurysms," *Radiology*, vol. 222, no. 2, pp. 389–396, 2002.
- [15] J. V. Richardson, R. B. Karp, J. W. Kirklin, and W. E. Dismukes, "Treatment of infective endocarditis: a 10-year comparative analysis," *Circulation*, vol. 58, no. 4, pp. 589–597, 1978.
- [16] W. Ting, N. Silverman, and S. Levitsky, "Valve replacement in patients with endocarditis and cerebral septic emboli," *Annals of Thoracic Surgery*, vol. 51, no. 1, pp. 18–22, 1991.
- [17] W. Hashimoto, M. Hamawaki, K. Hashizume, and K. Eishi, "A Patient in whom survival was achieved by acute-stage surgery for infective endocarditis complicated by a cerebral hemorrhage," *Annals of Thoracic and Cardiovascular Surgery*, vol. 15, no. 4, pp. 257–260, 2009.
- [18] Y. Shiraishi, A. Awazu, T. Harada, K. Ohara, I. Matsuda, and S. Kamijou, "Valve replacement in a patient with infective endocarditis and ruptured mycotic cerebral aneurysm," *Nippon Kyobu Geka Gakkai Zasshi*, vol. 40, no. 1, pp. 118–123, 1992.
- [19] A. F. Ducruet, Z. L. Hickman, B. E. Zacharia et al., "Intracranial infectious aneurysms: a comprehensive review," *Neurosurgical Review*, vol. 33, no. 1, pp. 37–45, 2010.