

# Performing EUS during COVID-19 postendemic period: A report from endoscopy center in Wuhan

Yuchong Zhao<sup>1,2,\*</sup>, Qian Chen<sup>1,\*</sup>, Qiaozhen Guo<sup>1</sup>, Nianjun Chen<sup>1</sup>, Wei Hou<sup>1</sup>, Yun Wang<sup>1</sup>, Weinuo Qu<sup>1,2</sup>, Shou Jiang Tang<sup>3</sup>, Siyu Sun<sup>4</sup>, Bin Cheng<sup>1</sup>

<sup>1</sup>Department of Internal Medicine, The Division of Gastroenterology and Hepatology, Tongji Hospital, Tongji Medical College, Huazhong University of Science and Technology, Wuhan, Hubei Province, China; <sup>2</sup>The Second Clinical School Affiliated Tongji Hospital, Tongji Medical College, Huazhong University of Science and Technology, Wuhan, Hubei Province, China; <sup>3</sup>Department of Medicine, Division of Digestive Diseases, University of Mississippi Medical Center, Jackson, MS, USA; <sup>4</sup>Department of Gastroenterology, Shengjing Hospital of China Medical University, Shenyang, Liaoning Province, China

## ABSTRACT

In early April 2020, the 3-month-long city-wide lockdown was lifted in Wuhan, the epicenter of China during Coronavirus Disease 2019 (COVID-19) global pandemic. However, continuing precautions are still practiced considering the risk of transmission from asymptomatic carriers. Given that COVID-19 is spread via airborne droplets, including aspiration of oral and fecal material through endoscopes, our endoscopy center has strategically assigned health-care providers to ensure triage workflow and to minimize concomitant exposure from potential asymptomatic carriers. Here, we share the experience of performing EUS-FNA during the COVID-19 pandemic and postendemic periods. We illustrate our workflow using a patient with a left adrenal mass as an example and followed a biosafety level-2 standard. We believe all endoscopy centers need to focus on these three directions: (1) pre-EUS patients risk assessment and triage, (2) Personal protective equipment (PPE), and (3) dressing code modalities. We fully adopted them in our hospital to reduce COVID-19 resurgence risk.

**Key words:** COVID-19, EUS, postendemic

## INTRODUCTION

On April 5, 2020, there were 50,333 confirmed COVID-19 cases and 3869 deaths in Wuhan. Up-to-date, there are more than 4,000,000 confirmed cases globally. The true impact of COVID-19 is seriously underestimated.<sup>[1]</sup> The mean latency of

COVID-19 is 5.2 (4.1–7) days, while in some cases the latency can be longer than 20 days.<sup>[2-4]</sup> Various transmission routes include airborne droplets, direct contamination, and possible oral-fecal.<sup>[5,6]</sup> Early evidence

This is an open access journal, and articles are distributed under the terms of the Creative Commons Attribution-NonCommercial-ShareAlike 4.0 License, which allows others to remix, tweak, and build upon the work non-commercially, as long as appropriate credit is given and the new creations are licensed under the identical terms.

**For reprints contact:** WKHLRPMedknow\_reprints@wolterskluwer.com

**How to cite this article:** Zhao Y, Chen Q, Guo Q, Chen N, Hou W, Wang Y, *et al.* Performing EUS during COVID-19 postendemic period: A report from endoscopy center in Wuhan. *Endosc Ultrasound* 2021;10:93-7.

Access this article online	
<b>Quick Response Code:</b> 	<b>Website:</b> <a href="http://www.eusjournal.com">www.eusjournal.com</a>
	<b>DOI:</b> 10.4103/eus.eus_37_20

\*These authors are co-first authors.

### Address for correspondence:

Prof. Bin Cheng, Department of Internal Medicine, The Division of Gastroenterology and Hepatology, Tongji Hospital, Tongji Medical College, HUST, Wuhan, 430030, China. E-mail: b.cheng@tjh.tjmu.edu.cn

Prof. Siyu Sun, Department of Gastroenterology, Shengjing Hospital of China Medical University, Shenyang 110004, China. E-mail: sun-siyu@163.com

**Received:** 2020-04-23; **Accepted:** 2020-05-19; **Published Online:** 2020-07-11

suggested that COVID-19 can transmit in a humid and high-temperature environment.<sup>[7]</sup> All these viral features create great difficulties in infection control. In addition, COVID-19 viral RNA has been detected in human feces. Therefore, endoscopists and endoscopy staff are inevitably exposing to respiratory exposure risks.<sup>[8,9]</sup> As the Chinese government gradually lifts the national lockdown, most endoscopy centers are reopening in China. Our Hubei province has a population of approximately 60 million, and there is a big demand for all types of endoscopic procedures. In the early stage of the COVID-19 outbreak, only emergent or urgent endoscopy was performed under biosafety level 3 conditions for positive or “high-risk” COVID-19 patients.<sup>[8-10]</sup> The current recommendations from the Chinese endoscopy society and other world organizations mainly aim for urgent endoscopy during the pandemic period. During the transition into the postendemic period, cautions still need to be practiced. Increasing cases of recurrent positive Severe acute respiratory syndrome coronavirus 2 (SARS-CoV-2)-19 RNA test in discharged patients pose great challenge to normal medical order.<sup>[11,12]</sup> Here, we share our experience of conducting EUS-guided FNA following our hospital guidelines and we hope these measures could help other endoscopy centers anticipating a smooth transition without compromising patient and staff safety [Figure 1]. We illustrate our workflow using a patient with a left adrenal mass as an example and followed a biosafety level-2 standard.

A 57-year-old male was referred for a 7 cm × 6 cm left retroperitoneal mass on imaging study. Due to Wuhan lockdown, he was only able to come until March 31, 2020. After outpatient COVID-19 prescreening, the patient was admitted to our hospital. His positron emission tomography computed tomography (CT) scan showed multiple hypermetabolic lesions in the left kidney suggestive of neoplasm, and multiple hypermetabolic lesions suspecting metastases. To confirm the diagnosis, we performed EUS-FNA.

To minimize transmission risks, all health-care providers wear a proper set of personal protective equipment (PPE) which includes a medical protective mask, medical hair net, double gloves, goggle, face shields boot covers, and a single-use gown in our center [Figure 2]. The patient and his family members are also provided with surgical masks and the patient with a medical hair net and gown. To reduce intubation-induced aerosol generation,

moderate anesthesia with intravenous propofol is provided to reduce coughing and gagging regurgitation during EUS-FNA. During moderate sedation, only one anesthetist is allowed in the procedure room to minimize the exposure risk. We have observed that one of the disadvantages related to PPE usage is easy lens fogging when wearing goggles and face shields together. To prevent fogging, we rub the entire lens surface with a drop of liquid soap. During specimen preparation, rapid on-site evaluation (ROSE) or cellblock assessment is performed wearing PPE. In some hospitals, the ROSE team let the slides air dry instead of using an air blower to dry the slides to minimize aerosol generation.

### *Patients' screening and triage*

According to our hospital policies, the endoscopy center remains a high-risk exposure location and should adhere to the biosafety level-2 requirement even in the postendemic period. Although this may not be adopted by some endoscopy units worldwide,<sup>[13]</sup> we strongly recommend careful patient screening or triage, and to reduce ambulatory endoscopy procedures at a limited level. As more evidence show that asymptomatic carriers could lead to family cluster infection,<sup>[14-17]</sup> screening tests and proper protection are still necessary to prevent transmission from asymptomatic carriers. Therefore, COVID-19 nucleic acid detection, CT scan, and SARS-CoV-2 antibody test are still currently needed as a part of screening during the postendemic period in Wuhan.

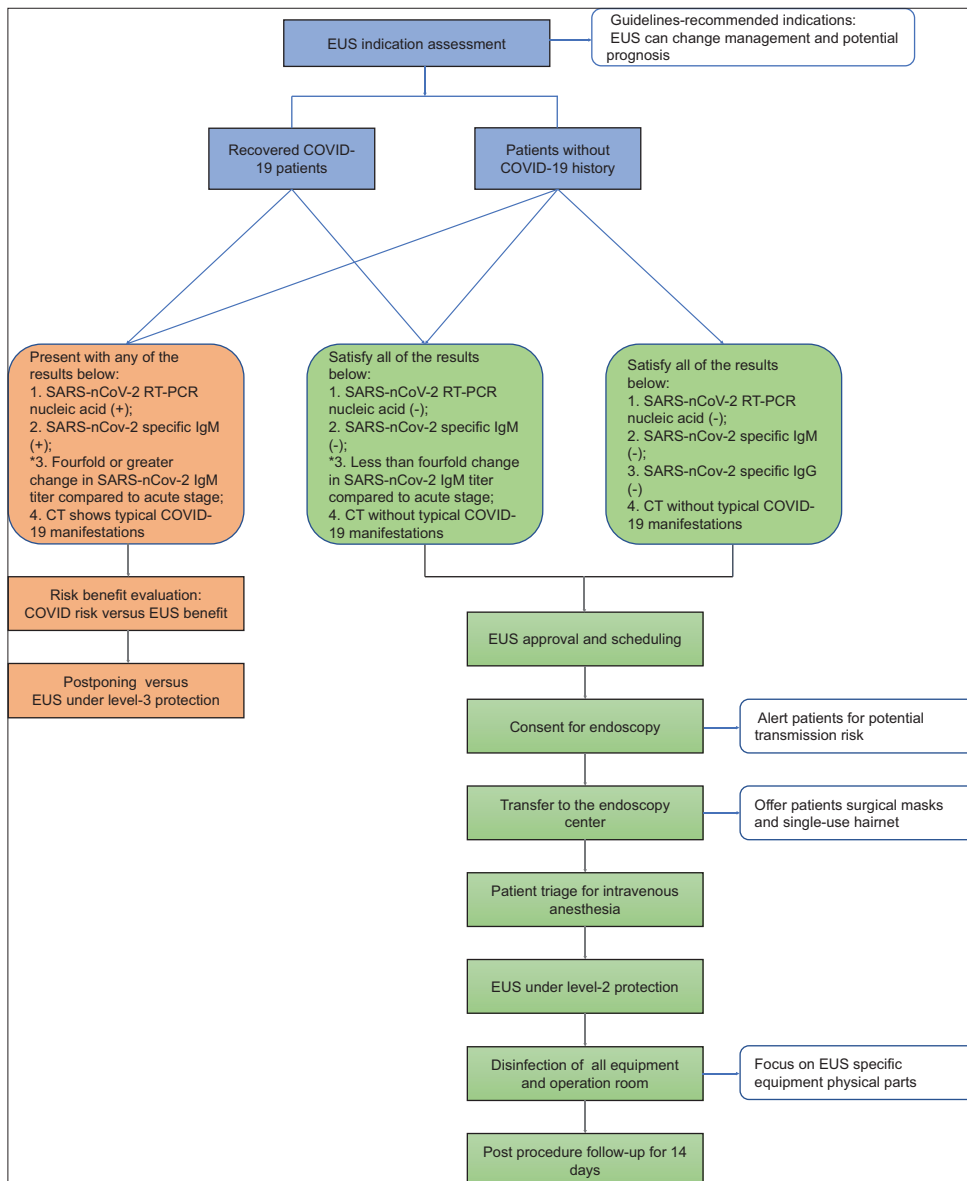
According to the guidelines published in China on 5<sup>th</sup> April,<sup>[18]</sup> all discharged COVID-19 patients still need to have a 14-days home quarantine. In our center, recovered COVID-19 patients can schedule an endoscopy 14 days after home quarantine. If the patient's SARS-CoV-2 Reverse transcription polymerase chain reaction nucleic acid test or IgM antibody is still positive, we will consider postponing the elective endoscopy. According to our hospital COVID-19 management policy, these patients are provided with surgical masks and transferred to the quarantine room. For discharged COVID-19 patients, if the serum SARS-CoV-2 IgG titer multiplies by four times or more than that of the acute stage, the decision to perform endoscopy will be made after risk–benefit analysis: benefits from EUS versus potential COVID-19 transmission risks.

### *Endoscopy staff protection*

According to the new official report, there was new neighborhood cluster infection. This endemic



**Figure 1.** Endoscopy operators' dress code (a) high-risk dressing equipment before entering contamination area; (b) high-risk dressing equipment during EUS procedure



**Figure 2.** Recommended workflow of EUS in postendemic period in Wuhan

rebounded after lockdown lifted for months in Wuhan lifted. Although we have postponed all unnecessary endoscopy procedures at best, there are still more than 60 cases in our center daily, cumulated since lockdown. Due to dense population and inevitable airway exposure, we still take level-2 protection at endoscopy centers in accordance with instructions of hospital epidemic-prevention agency. During the postendemic period, PPE still should be worn to reduce exposure hazards even if the patient is properly screened and considered as “low-risk” for COVID-19 infection from our perspective. All endoscopy staff have been trained to wear and remove PPE properly. During the outbreak, a shortage of N95 (FFP2 standard or equivalent) respirators was a risk factor for COVID-19 nosocomial infection,<sup>[19]</sup> and there is evidence showing that surgical masks can also provide effective protection.<sup>[20]</sup> We recommend wearing medical protective masks/N95 respirators and surgical masks when they are available. For safety concerns, we recommend that all advanced procedures should be performed by experienced endoscopists in order to reduce total procedure time and to limit potential exposure risk. Based on an infectious disease control model, our endoscopy center has completed unit modification and reconstruction during the outbreak and it has been divided into 3 zones (clean, semi-contaminated, and contaminated) with 2 different passages (medical personnel passage and patient passage). In addition, we implemented these measures: Stricter medical waste disposal and handling, sterilization of air and hard surfaces by the ultraviolet light, and soaking endoscope and water pocket installer in peroxide acid detergent (Acecide; Saraya Cor, Osaka, Japan).

#### *EUS equipment and device handling*

We strictly follow the required decontamination steps: Disinfection, washing, and sterilization.<sup>[21]</sup> After procedure, the endoscopes and reusable accessories were put in a double-layer yellow medical waste bag, sealed, and then transported. EUS equipment and accessories should be decontaminated with special considerations. The structures of ultrasound fan in scanning EUS different from ordinary endoscopes, are an ultrasonic probe and forceps elevators. In addition, the elevator has its own cleaning channels. Thus, these are the key focus during cleaning and sterilization. Furthermore, the cable connecting EUS and monitor can only be sterilized by 75% alcohol.

#### *EUS indications*

For EUS indications in the postendemic period, we suggest giving priority to those patients with suspected cancers. Below is a summary of our recommended indications based on current guidelines.<sup>[22,23]</sup>

- a. EUS/-FNA/-elastography: Esophageal cancer staging
- b. EUS: Prior to endoscopy resection of early gastric cancer
- c. EUS-FNA: Biopsy of liver mass, poorly accessible by percutaneous imaging
- d. EUS/-FNA/IDUS (intraductal ultrasonography): Staging or biopsy of cholangiocarcinoma
- e. EUS-FNA: Pancreatic solid tumor (1) CT or magnetic resonance imaging cannot differentiate between benign and malignant; (2) primary or metastatic lesion required for pathologic diagnosis; (3) neoadjuvant or palliative radio/chemotherapy
- f. EUS/EUS-FNA: Lesions in other parts including lung, mediastinum, adrenal gland, lymph node of unknown origin, retroperitoneum.

Currently, it is difficult to estimate how long this COVID-19 pandemic will last globally. Our workflow modifications and protection standards will be revisited and revised based on new evidence and the latest guidelines. Overall, based on our experience and currently published guidelines, we strategically assigned HCP to minimize exposure and applied the triage workflow throughout EUS procedure. We hope our experience can help other centers in setting up their own policies and guidelines during the postpandemic period.

#### *Declaration of patient consent*

The authors certify that they have obtained all appropriate patient consent forms. In the form the patient(s) has/have given his/her/their consent for his/her/their images and other clinical information to be reported in the journal. The patients understand that their names and initials will not be published and due efforts will be made to conceal their identity, but anonymity cannot be guaranteed.

#### *Financial support and sponsorship*

Nil.

#### *Conflicts of interest*

There are no conflicts of interest.

## REFERENCES

1. Verity R, Okell LC, Dorigatti I, *et al.* Estimates of the severity of coronavirus disease 2019: A model-based analysis. *Lancet Infect Dis* 2020. pii: S1473-3099(20)30243-7.
2. Guan WJ, Ni ZY, Hu Y, *et al.* Clinical characteristics of coronavirus disease 2019 in China. *N Engl J Med* 2020;382:1708-20.
3. Huang C, Wang Y, Li X, *et al.* Clinical features of patients infected with 2019 novel coronavirus in Wuhan, China. *Lancet* 2020;395:497-506.
4. Wölfel R, Corman VM, Guggemos W, *et al.* Virological assessment of hospitalized patients with COVID-2019. *Nature* 2020;581:465-9.
5. Spellberg B, Haddix M, Lee R, *et al.* Community prevalence of SARS-CoV-2 among patients with influenzalike illnesses presenting to a los angeles medical center in March 2020. *JAMA* 2020;323:1966-7.
6. Chen H, Guo J, Wang C, *et al.* Clinical characteristics and intrauterine vertical transmission potential of COVID-19 infection in nine pregnant women: A retrospective review of medical records. *Lancet* 2020;395:809-15.
7. Luo C, Yao L, Zhang L, *et al.* Possible transmission of severe acute respiratory syndrome coronavirus 2 (SARS-CoV-2) in a public bath center in Huai'an, Jiangsu Province, China. *JAMA Network Open* 2020;3:e204583.
8. Lui RN, Wong SH, Sánchez-Luna SA, *et al.* Overview of guidance for endoscopy during the coronavirus disease 2019 pandemic. *J Gastroenterol Hepatol* 2020;35:749-59.
9. Repici A, Maselli R, Colombo M, *et al.* Coronavirus (COVID-19) outbreak: What the department of endoscopy should know. *Gastrointest Endosc* 2020. pii: S0016-5107(20)30245-5.
10. Zhang Y, Zhang X, Liu L, *et al.* Suggestions for infection prevention and control in digestive endoscopy during current 2019-nCoV pneumonia outbreak in Wuhan, Hubei province, China. *Endoscopy* 2020;52:312-4.
11. Chen D, Xu W, Lei Z, *et al.* Recurrence of positive SARS-CoV-2 RNA in COVID-19: A case report. *Int J Infect Dis* 2020;93:297-9.
12. Yuan J, Kou S, Liang Y, *et al.* PCR assays turned positive in 25 discharged COVID-19 patients. *Clin Infect Dis* 2020. pii: ciaa398.
13. Thompson CC, Shen L, Lee LS. COVID-19 in endoscopy: Time to do more? *Gastrointest Endosc* 2020;S0016-5107(20)34126-2.
14. Zhang JJ, Tian SJ, Lou J, *et al.* Familial cluster of COVID-19 infection from an asymptomatic. *Crit Care* 2020;24:3.
15. Li C, Ji F, Wang L, *et al.* Asymptomatic and human-to-human transmission of SARS-CoV-2 in a 2-family cluster, Xuzhou, China. *Emerg Infect Dis* 2020;26:7.
16. Qiu J. Covert coronavirus infections could be seeding new outbreaks. *Nature* 2020. Available from: <https://www.nature.com/articles/d41586-020-00822-x>. [Last accessed on 2020 Apr 10].
17. Day M. Covid-19: Four fifths of cases are asymptomatic, China figures indicate. *BMJ* 2020;369:m1375.
18. Qu J, Wang C, Cao B. Guide for the prevention and treatment of coronavirus disease 2019 Chinese. *J Tubercul Respir Dis* 2020;43:E041.
19. Guo X, Wang J, Hu D, *et al.* Survey of COVID-19 disease among orthopaedic surgeons in Wuhan, people's republic of China. *J Bone Joint Surg Am* 2020;102:847-54.
20. Leung NH, Chu DK, Shiu EY, *et al.* Respiratory virus shedding in exhaled breath and efficacy of face masks. *Nat Med* 2020;26:676-80.
21. ASGE Quality Assurance in Endoscopy Committee, Calderwood AH, Day LW, Muthusamy VR, *et al.* ASGE guideline for infection control during GI endoscopy. *Gastrointest Endosc* 2018;87:1167-79.
22. Dumonceau JM, Deprez PH, Jenssen C, *et al.* Indications, results, and clinical impact of endoscopic ultrasound (EUS)-guided sampling in gastroenterology: European Society of Gastrointestinal Endoscopy (ESGE) Clinical Guideline-Updated January 2017. *Endoscopy* 2017;49:695-714.
23. Ge N, Zhang S, Jin Z, *et al.* Clinical use of endoscopic ultrasound-guided fine-needle aspiration: Guidelines and recommendations from Chinese Society of Digestive Endoscopy. *Endosc Ultrasound* 2017;6:75-82.