

# Improvement of lung function and pulmonary hypertension after pulmonary aneurysm repair: case series

Satoshi Akagi<sup>1</sup> , Kentaro Ejiri<sup>1</sup>, Shingo Kasahara<sup>2</sup>, Kazufumi Nakamura<sup>1</sup> and Hiroshi Ito<sup>1</sup>

<sup>1</sup>Department of Cardiovascular Medicine, Okayama University Graduate School of Medicine, Dentistry and Pharmaceutical Science, Okayama, Japan; <sup>2</sup>Department of Cardiovascular Surgery, Okayama University Hospital, Okayama, Japan

## Abstract

Pulmonary artery aneurysms (PAA) can be complicated with pulmonary arterial hypertension (PAH), causing sudden death due to PA rupture and dissection. Because treatment with PAH-targeted drugs does not always prevent PAA progression, prophylactic surgical repair of the PAA seems a promising alternative. However, although it avoids rupture and dissection of the PAs, additional benefits have not been forthcoming. We therefore present two patients with co-existing PAH and a PAA who underwent surgical repair of the aneurysm. Following the surgery, their lung function and pulmonary hypertension improved. Optimal treatment of PAA remains uncertain, however, with no clear guidelines regarding the best therapeutic approach. This case series provides physicians with reasons to repair PAA surgically in patients with PAH.

## Keywords

vital capacity, pulmonary artery pressure, lung perfusion and oxygenation

Date received: 22 October 2018; accepted: 18 January 2019

Pulmonary Circulation 2019; 9(1) 1–4

DOI: 10.1177/2045894019831217

## Introduction

Pulmonary artery aneurysms (PAA) are sometimes associated with pulmonary arterial hypertension (PAH).<sup>1</sup> A PAA can be an independent risk factor for unexpected death due to aneurysm rupture or dissection in patients with PAH.<sup>2</sup> Because it is known that PAAs progress in patients with PAH despite treatment for the pulmonary hypertension (PH),<sup>3</sup> prophylactic surgical repair of a PAA could be a treatment option.<sup>4</sup> The benefit of surgical repair of a PAA is that it precludes the possibility of its rupture and dissection. Any additional benefits of such surgical repair of a PAA in the presence of PAH have not been elucidated. We therefore present two patients, each with coexisting PAH and a PAA, who underwent surgical repair of the aneurysm and whose lung function and PH improved.

PAA (diameter 67 mm). Right heart catheterization (RHC) showed a mean pulmonary artery pressure (mPAP) of 75 mmHg. She was started on beraprost with sequentially added bosentan at the age 51 years and sildenafil at 54 years. The bosentan was changed to ambrisentan at age 57 years and the sildenafil to riociguat at the age of 60 years. Although mPAP decreased to 44 mmHg, the PAA's diameter had expanded to 129 mm (Fig. 1a), and her SpO<sub>2</sub> was 95% with oxygen administration at 4 L/min. She had exertional breathlessness and was in World Health Organization (WHO) functional class (FC) II. We therefore decided to repair the PAA surgically. When she was aged 61 years, we reconstructed the right ventricular outflow tract and performed bilateral pulmonary artery plication (Fig. 1b). Seven months postoperatively, RHC showed a mPAP of 35 mmHg

## Case report I

A 63-year-old woman had been diagnosed with idiopathic PAH at the age of 49 years. At that time, contrast-enhanced computed tomography (CT) showed a large

Corresponding author:

Satoshi Akagi, Department of Cardiovascular Medicine, Okayama University Graduate School of Medicine, Dentistry and Pharmaceutical Science, 2-5-1, Kita-ku, Shikata-cho, Okayama 700-8558, Japan.

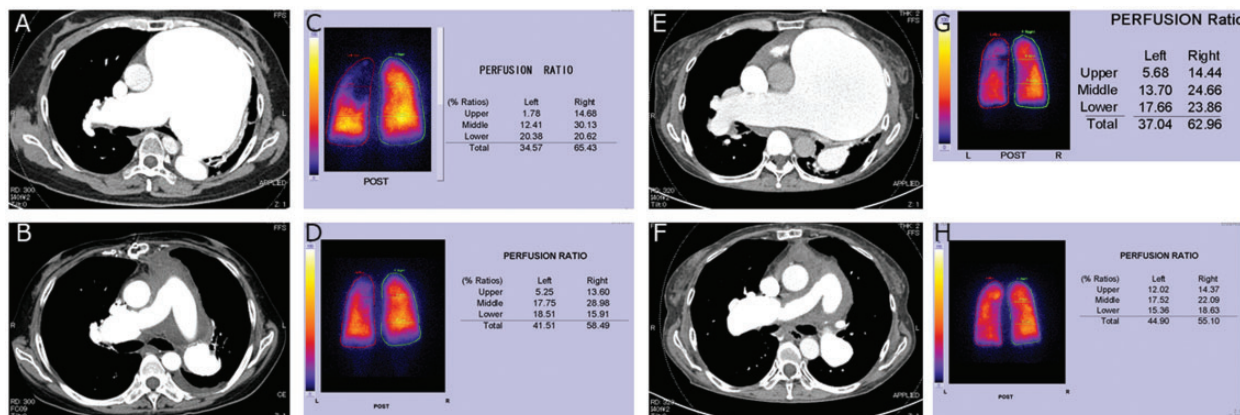
Email: akagi-s@cc.okayama-u.ac.jp



Creative Commons Non Commercial CC BY-NC: This article is distributed under the terms of the Creative Commons Attribution-NonCommercial 4.0 License (<http://www.creativecommons.org/licenses/by-nc/4.0/>) which permits non-commercial use, reproduction and distribution of the work without further permission provided the original work is attributed as specified on the SAGE and Open Access pages (<https://us.sagepub.com/en-us/nam/open-access-at-sage>).

© The Author(s) 2019.  
Article reuse guidelines:  
[sagepub.com/journals-permissions](http://sagepub.com/journals-permissions)  
[journals.sagepub.com/home/pul](http://journals.sagepub.com/home/pul)





**Fig. 1** Chest CT and lung perfusion scintigraphy. Top: Before repair of a PAA. Bottom: After repair of a PAA. (a, b) Contrast-enhanced CT of case 1. (c, d) Lung perfusion scintigraphy of case 1. (e, f) Contrast-enhanced CT of case 2. (g, h) Lung perfusion scintigraphy of case 2. CT, computed tomography; PAA, pulmonary artery aneurysm.

(with the patient on ambrisentan and riociguat). Lung perfusion scintigraphy showed that a preoperative perfusion ratio in her left upper and middle lung had increased postoperatively (Fig. 1c and d). In addition, the lung function test showed that her preoperative vital capacity of 1.7 L (71.4% of predicted value) had increased postoperatively to 2.4 L (93.7% of predicted value). Her SpO<sub>2</sub> was 99% with oxygen administration at 1 L/min. Precise clinical, echocardiographic, and hemodynamic parameters, lung function test, and blood gas test of case 1 before and after surgery of PAA are shown in Table 1.

## Case report 2

A 61-year-old woman had been diagnosed at the age of 31 years with portopulmonary hypertension associated with a congenital portosystemic venous shunt. At age 50 years, CT demonstrated a large PAA (diameter 71 mm). RHC showed a mPAP of 52 mmHg. Bosentan was initiated; tadalafil was added sequentially at age 54 years. Bosentan was changed to ambrisentan at age 56 years. Although her mPAP had decreased to 41 mmHg, the aneurysm's diameter had expanded to 133 mm (Fig. 1e), and her SpO<sub>2</sub> was 95% with oxygen administration at 3 L/min. She underwent coil occlusion of a congenital portosystemic venous shunt and intravenous epoprostenol was added to the regimen. She had exertional breathlessness, cough, and general fatigue and was in WHO FC III. Because the mPAP had decreased to 35 mmHg, we decided repair the aneurysm surgically. At the age of 61 years, she underwent reconstruction of the right ventricular outflow tract and bilateral pulmonary artery plication (Fig. 1f). RHC performed nine months postoperatively showed a mPAP of 26 mmHg (with the patient on ambrisentan, tadarafil, and selexipag). Lung perfusion scintigraphy showed that a preoperative perfusion ratio in her left upper and middle lung had increased postoperatively (Fig. 1g and h). The lung function test revealed that her preoperative vital capacity of 1.6 L (57.8% of predicted

value) increased postoperatively to 2.2 L (82.3% of predicted value). Also, her SpO<sub>2</sub> was 99% with oxygen administration at 2 L/min. Precise clinical, echocardiographic, and hemodynamic parameters, lung function test, and blood gas test of case 2 before and after PAA surgery are shown in Table 1.

## Discussion

PAA is defined as the main pulmonary artery diameter measuring > 40 mm.<sup>5</sup> Its prevalence was approximately 1 in 14,000 autopsies.<sup>6</sup> Elevated PAP, high flow, connective tissue diseases, pulmonary valve stenosis, systematic vasculitis, infections, and trauma are the most probable causes of a PAA.<sup>1</sup> Dissection or rupture of PAA is rare but life-threatening. Hence, prophylactic treatment for PAA is required—although there is no clear evidence that one or another treatment/therapeutic strategy for PAA is more effective than any other. Reduced hemodynamic stress on the pulmonary artery wall might help prevent the formation and progression of PAA because increased shear stress would injure a pulmonary artery wall.<sup>7</sup> However, lowering the PAP by PAH-targeted drugs has not always prevented PAA progression.<sup>3,8</sup> Aggressive surgical intervention has also been advocated for patients with PAH.

To date, although surgical repair of PAA precludes the possibility of impending dissection and rupture, there has been no evidence reported that the repair offers additional benefits. In our two patients, however, their vital capacity increased after repairing the PAA. We think that expansion of the left upper and middle lung, which had been compressed by the PAA in each patient, resulted in the improved lung function. In addition, repair of the PAA recanalized the left upper and middle pulmonary artery, which allowed increased pulmonary blood flow. Thus, these ventilation and perfusion recoveries in the left upper and middle lung could lead to improved oxygenation. Furthermore, expansion of the pulmonary vascular bed could result in reduced

**Table 1.** Clinical, echocardiographic, and hemodynamic parameters, lung function test, and blood gas test of patients before and after surgery of PAA.

Parameters	Case 1		Case 2	
	Pre	Post	Pre	Post
<i>Clinical</i>				
WHO FC	II	II	III	II
<i>Echocardiographic</i>				
TR	Trivial	Trivial	Mild	Mild
TRPG (mmHg)	68	49	55	44
TAPSE (mm)	13	13	12	14
S' (cm/s)	9	9	8	8
RVFAC (%)	35	33	32	29
<i>Hemodynamic</i>				
PAP (s/d/m) (mmHg)	62/35/44	63/16/35	56/17/35	50/14/26
RVSP/EDP (mmHg)	62/2	75/0	57/8	54/6
RAP (mmHg)	2	0	8	6
PAWP (mmHg)	–	0	–	14
CO (L/min)	2.3	3.6	5.7	8.1
CI (L/min/m <sup>2</sup> )	1.6	2.5	3.9	5.3
PVR or TPR (Wood units)	19*	10	6*	2
<i>Lung function test</i>				
VC (L)	1.7	2.4	1.6	2.2
%VC (%)	71.4	93.7	57.8	82.3
FEV <sub>1.0</sub> (L)	1.03	1.59	0.95	1.24
FEV <sub>1.0%</sub> (%)	66.0	69.4	60.0	58.2
Pattern	Mixed	Obstructive	Mixed	Obstructive
<i>Blood gas test</i>				
Oxygen administration	4L	–	4L	2L
pH	7.4	–	7.4	7.4
PaO <sub>2</sub> (mmHg)	94.7	–	72.2	88.3
PaCO <sub>2</sub> (mmHg)	33.9	–	45.9	43.4

\*Values are TPR because PAWP was not measured due to large PAA.

WHO FC, World Health Organization functional class; TR, tricuspid regurgitation; TRPG, tricuspid regurgitation pressure gradient; TAPSE, tricuspid annular plane systolic excursion; S', tricuspid annular velocity; RVFAC, right ventricular fractional area change; PAP, pulmonary artery pressure; s/d/m, systolic/diastolic/mean; RVSP, right ventricular systolic pressure; RVEDP, right ventricular end diastolic pressure; RAP, right atrial pressure; PAWP, pulmonary artery wedge pressure; CO, cardiac output; CI, cardiac index; PVR, pulmonary vascular resistance; TPR, total pulmonary resistance; VC, vital capacity; FEV<sub>1.0</sub>, forced expiratory volume in 1 s.

hemodynamic stress, thereby contributing to decreased PAP. Hence, we believe that there are additional benefits of surgical repair of PAA. They are improved lung function and PH in patients with PAH.

Kreibich et al. recommended the following indications for PAA surgery: (1) an absolute PAA diameter of  $\geq 5.5$  cm; (2) increase in the aneurysm's diameter of  $\geq 0.5$  cm within six months; (3) compression of adjacent structures; (4) thrombus formation in the aneurysm sac;

(5) appearance of clinical symptom; (6) evidence of valvular pathology or a shunt; (7) verification of PAH; (8) signs of rupture or dissection.<sup>1</sup> More evidence is needed to know whether the benefit of therapeutic intervention exceeds the risk of the surgery. We think that appropriate indications for PAA surgery would provide the benefit of therapeutic intervention beyond risks of the surgery. Preoperative lung function test showed the reduced vital capacity and mixed pattern in both cases. Preoperative lung perfusion scintigraphy showed the reduced perfusion ratio in lung compressed by PAA in both cases. Cardiac output (CO) was also an important factor for indication for PAA surgery. There were some case reports and series of PAA surgery with or without PAH. In reports with patients without PAH who were received PAA surgery, CO was not described,<sup>9,10</sup> but ejection fraction was preserved (EF = 51%).<sup>10</sup> In reports of patients with PAH who received PAA surgery, CO was not described.<sup>11</sup> In a report of a patient with PAH who did not receive PAA surgery, the patient had a low cardiac index (2.5 L/min/m<sup>2</sup>) and died although the patient was treated with PAH-specific drugs.<sup>12</sup> Decreased CO was an independent risk factor of all all-cause mortality in PAH patients with PAA.<sup>2</sup> In our cases, CO was relatively preserved before PAA surgery. In our opinion, these respiratory function, image findings, and preserved CO would be factors of indication for PAA surgery.

The diameter of PAA at diagnosis was  $> 55$  mm in both cases. However, we chose not to operate on the patients then because PAP was high (Case 1: mPAP = 75 mmHg, Case 2: mPAP = 52 mmHg) and PH was not stable in both cases. Thereafter, we chose to operate patients because mPAP decreased, PH improved, and CO was relatively preserved, but hypoxia progressed.

As these two cases suggested, surgical repair of a PAA could achieve improved lung function and PH. Therefore, we believe that the presence of reduced vital capacity, reduced perfusion ratio in lung compressed by PAA, and severe oxygen desaturation indicate the need to consider surgical repair of a PAA.

### Acknowledgments

We thank Nancy Schatken, from Edanz Group ([www.edanzediting.com/ac](http://www.edanzediting.com/ac)), for editing a draft of this manuscript. We thank Nobuhiro Tahara and Yoshihiro Fukumoto (Division of Cardiovascular Medicine, Department of Internal Medicine, Kurume University School of Medicine) and Machiko Asaka (Department of Cardiovascular Medicine, Saga University) for their contributions to the management of a patient (case 2).


### Conflict of interest

The author(s) declare that there is no conflict of interest.

### Funding

This research received no specific grant from any funding agency in the public, commercial, or not-for-profit sectors.

**ORCID iD**

Satoshi Akagi  <http://orcid.org/0000-0002-9392-7117>

**References**

1. Kreibich M, Siepe M, Kroll J, et al. Aneurysms of the pulmonary artery. *Circulation* 2015; 131: 310–316.
2. Zylkowska J, Kurzyna M, Florczyk M, et al. Pulmonary artery dilatation correlates with the risk of unexpected death in chronic arterial or thromboembolic pulmonary hypertension. *Chest* 2012; 142: 1406–1416.
3. Akagi S, Nakamura K, Sarashina T, et al. Progression of pulmonary artery dilatation in patients with pulmonary hypertension coexisting with a pulmonary artery aneurysm. *J Cardiol* 2018; 71: 517–522.
4. Hou R, Ma GT, Liu XR, et al. Surgical treatment of pulmonary artery aneurysm: an institutional experience and literature review. *Interact Cardiovasc Thorac Surg* 2016; 23: 438–442.
5. Duijnhouwer AL, Navarese EP, Van Dijk AP, et al. Aneurysm of the pulmonary artery, a systematic review and critical analysis of current literature. *Congenit Heart Dis* 2016; 11: 102–109.
6. Deterling RA Jr and Clagett OT. Aneurysm of the pulmonary artery; review of the literature and report of a case. *Am Heart J* 1947; 34: 471–499.
7. Akagi S, Matsubara H, Nakamura K, et al. Modern treatment to reduce pulmonary arterial pressure in pulmonary arterial hypertension. *J Cardiol* 2018; 72: 466–472.
8. Boerrigter B, Mauritz GJ, Marcus JT, et al. Progressive dilatation of the main pulmonary artery is a characteristic of pulmonary arterial hypertension and is not related to changes in pressure. *Chest* 2010; 138: 1395–1401.
9. Theodoropoulos P, Ziganshin BA, Tranquilli M, et al. Pulmonary artery aneurysms: four case reports and literature review. *Int J Angiol* 2013; 22: 143–148.
10. Vistarini N, Aubert S, Gandjbakhch I, et al. Surgical treatment of a pulmonary artery aneurysm. *Eur J Cardiothorac Surg* 2007; 31: 1139–1141.
11. Reisenauer JS, Said SM, Schaff HV, et al. Outcome of surgical repair of pulmonary artery aneurysms: a single-center experience with 38 patients. *Ann Thorac Surg* 2017; 104: 1605–1610.
12. Degano B, Prevot G, Tetu L, et al. Fatal dissection of the pulmonary artery in pulmonary arterial hypertension. *Eur Respir Rev* 2009; 18: 181–185.