

Erratum

Erratum to “Fat Embolism Syndrome: A Case Report and Review Literature”

Nattaphol Uransilp,¹ Sombat Muengtaweepongsa ,² Nuttawut Chanalithichai ,³ and Nattapol Tammachote ³

¹Fellowship in Cerebrovascular Disease and Neurovascular Ultrasound, Faculty of Medicine, Thammasat University, Pathum Thani, Thailand

²Department of Internal Medicine, Faculty of Medicine, Thammasat University, Pathum Thani, Thailand

³Department of Orthopedic Surgery, Faculty of Medicine, Thammasat University, Pathum Thani, Thailand

Correspondence should be addressed to Sombat Muengtaweepongsa; sombatm@hotmail.com

Received 21 May 2018; Accepted 24 May 2018; Published 27 June 2018

Copyright © 2018 Nattaphol Uransilp et al. This is an open access article distributed under the Creative Commons Attribution License, which permits unrestricted use, distribution, and reproduction in any medium, provided the original work is properly cited.

In the article titled “Fat Embolism Syndrome: A Case Report and Review Literature” [1], the legends of Figures 3 and 4 were reversed due to a production error. The correct figures and their legends are shown below.

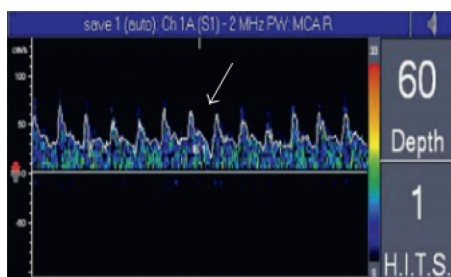
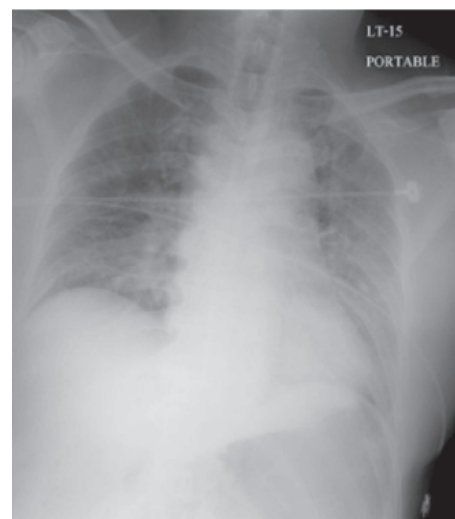
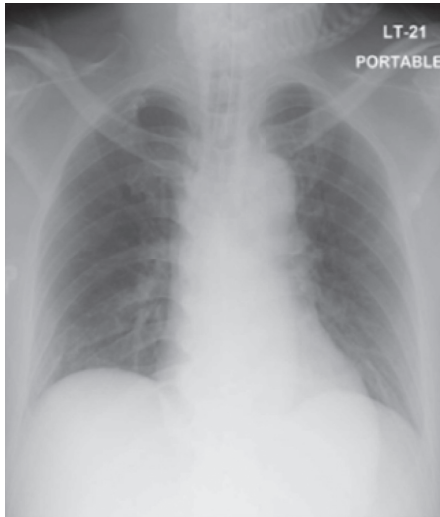


FIGURE 3: MES was detected in right MCA.



(a)

FIGURE 4: Continued.



(b)

FIGURE 4: Chest radiograph at 1 hour after surgery (a) and 24 hours after surgery (b).

References

- [1] N. Uransilp, S. Muengtaweepongsa, N. Chanalithichai, and N. Tammachote, "Fat embolism syndrome: a case report and review literature," *Case Reports in Medicine*, vol. 2018, Article ID 1479850, 6 pages, 2018.