

ARTICLE

Radiolabeled antibodies in renal cell carcinoma

Alexander B. Stillebroer^{a,b}, Egbert Oosterwijk^a, Wim J.G. Oyen^b, Peter F.A. Mulders^a and Otto C. Boerman^b

^aDepartment of Urology and ^bDepartment of Nuclear Medicine, Radboud University Nijmegen Medical Centre, Nijmegen, The Netherlands

Corresponding address: Alexander B. Stillebroer, MD, Radboud University Nijmegen Medical Centre, Department of Urology - 659, PO Box 9101, 6500 HB Nijmegen, The Netherlands.
Email: a.stillebroer@uro.umcn.nl

Data accepted for publication 15 August 2007

Abstract

Renal cell carcinoma (RCC) is a radio- and chemotherapy resistant tumor, which has a very high morbidity and mortality when metastasized. The current treatment options demonstrate limited efficacy and severe side-effects. Therefore, there is a need for new therapeutic strategies for RCC. As for other malignancies, monoclonal antibodies (mAbs) targeting tumor-associated antigens have been developed for RCC. One of these, mAb G250, targets the MN/CAIX/G250 antigen, which is ubiquitously expressed in clear cell RCC (ccRCC). ccRCC is the most common form of RCC with a prevalence of 80%. Expression of G250 in normal tissue is restricted to the gastrointestinal mucosa and related structures, thereby making it a suitable candidate for targeting ccRCC. In several clinical studies the efficient accumulation of mAb G250 in ccRCC has been demonstrated, resulting in high contrast images. G250-imaging could prove to be a valuable tool in diagnosing metastases in patients with a G250-antigen positive primary tumor and/or in the differential diagnosis of suspect kidney lesions. Furthermore, the therapeutic efficacy of radiolabeled G250 has been investigated in a series of studies. Thus far, most efforts have been devoted to G250 labeled with high doses of ¹³¹I. Other radionuclides which may enhance the therapeutic index of this radiolabeled mAb are currently under investigation. In our institution, an activity dose escalation study is currently ongoing to investigate the therapeutic potential of ¹⁷⁷Lu-labeled G250 in metastatic ccRCC patients. In this review, the current status of the diagnostic and therapeutic properties of radiolabeled antibodies in RCC is described.

Keywords: Radioimmunotherapy; RIT; immunoscintigraphy; iodine; lutetium; indium; antibody-dependent cellular cytotoxicity.

Introduction

Renal cell carcinoma (RCC) is the most common malignancy arising in the kidney. In the United States alone, each year 39,000 people are diagnosed with RCC and 13,000 people die from the disease^[1]. The classic triad of Virchow (flank pain, hematuria and a palpable abdominal mass) is only seen in approximately 9% of newly diagnosed patients^[2]. This considerably complicates the diagnosis, since the disease can present with a broad array of (paraneoplastic) symptoms^[3,4]. As a consequence, 30% of patients will present with metastatic disease, whereas of the other 70% treated by nephrectomy, 30–40% will eventually relapse^[1]. The 5-year survival rate for small (less than 7 cm) tumors limited to the

kidney (pT1 tumor) is more than 90%^[5], but prognosis for metastatic disease is bleak, with a median survival of only 10 months^[6]. RCC is known as a chemotherapy and radiation resistant tumor^[7,8]. Therefore, therapeutic strategies focus on immunotherapy, neoangiogenesis inhibitors and other targeted approaches. In this review, another approach using antibodies developed for targeting RCC is discussed and particularly their application in the diagnosis and therapy of RCC.

Monoclonal antibodies

Since the first description of Ehrlich to specifically guide cytotoxic therapy to cancer tissue^[9], much has been

debated on the feasibility of this approach. Development of the hybridoma technique^[10] allowed isolation of large quantities of antibodies with predefined specificity. With the identification of the tumor-associated target antigens, real progress has been made on developing treatment and/or diagnostic strategies using mAbs.

To date, no tumor specific antigen, i.e. an antigen expressed on all tumor cells which is not expressed by normal cells in the body, has been identified. Tumor-associated antigens (TAA) have been identified for a series of human tumor types^[11–15]. These are either differentiation antigens, (transiently) expressed during organogenesis, or aberrantly expressed antigens, (transiently) expressed elsewhere in non-related normal tissue(s). Expression of antigen on the primary tumor or metastases is generally heterogeneous. For tumor targeting with mAbs this is a suboptimal feature, since not all cells can be targeted by the mAb. Heterogeneous expression between different tumor sites, varying degrees of expression in tumor cells of the same tumor and temporal modulation of TAA-expression are considered major limitations of effective targeting of tumors with mAbs.

In addition to intratumoral heterogeneity of antigen expression, other parameters have been defined that may be equally important in hampering tumor targeting with mAbs. These are: size of the tumor mass, the antigen density, the fate of antigen/antibody complex, presence of circulating antigen, mAb format, mAb dose, route of administration and mAb circulating half-life^[16]. These parameters can differ from one tumor type to another. Also, tumor physiology is an important factor in antigen targeting by mAbs. Mab targeting is complicated by large tumor blood vessels as well as impaired blood flow in the tumor by elevated interstitial fluid pressure (IFP)^[17]. High vascular density is not equivalent to high perfusion rates in the tumor, which are required for optimal mAb delivery. RCC has always been considered a highly vascularized tumor by morphologic standards. However, in comparison with normal kidney tissue RCC is poorly perfused^[17], thereby impeding adequate mAb delivery to the tumor cells. These limitations of delivering the

mAb to tumor tissue have to be overcome in order to develop a suitable mAb-based treatment strategy.

Several mechanisms to eradicate tumor cells by mAbs are available: either via effector cells or complement dependent cytotoxicity or through conjugation of the mAb to toxins, drugs or radionuclides. Since antigen expression within tumors is heterogeneous, antigen-negative tumor cells may evade tumor cell lysis by effector cell- or complement-mediated cytotoxicity, which may eventually lead to tumor recurrence. The same applies to mAbs conjugated to toxins or drugs, since internalization of a mAb conjugated to a toxin or drug is required to mediate cell-killing^[16].

Radiolabeling of antibodies was developed in 1950, when Eisen observed that proteins could be labeled with ¹³¹I without altering their immunological specificity^[18]. Besides ¹³¹I, other radionuclides (⁹⁰Y, ¹⁷⁷Lu, ¹⁸⁶Re, ¹⁸⁸Re and ⁶⁷Cu) have since been investigated to induce tumor cell death (see Table 1). The advantage of radiolabeled antibodies is that the mAb does not have to bind to every tumor cell to induce cytotoxicity, since the radionuclides emit β -particles, which can be effective for up to 50 or more cell diameters. This so-called crossfire effect can thus overcome heterogeneity of antigen expression, as the radiation destroys the antigen-negative cells as well. A disadvantage of this technique is the sensitivity of normal organs to radiation, particularly the bone marrow. The dose limiting toxicity of delivering high-dose radioimmunotherapy (RIT), i.e. a radionuclide conjugated to a tumor-associated mAb, is therefore generally hematological.

Using the previously mentioned hybridoma technique a wide array of mAbs against TAAs has been produced, e.g. mAbs against carcino-embryonic antigen (CEA) (mainly expressed in colorectal and medullary thyroid carcinomas), MUC-1 (mainly ovarian and breast cancer), TAG72 (mainly ovarian and colorectal cancer), CD-20 (non-Hodgkin's lymphoma (NHL)) and G250-antigen (RCC). In various clinical trials safety and efficacy of these newly developed mAbs labeled with various radionuclides have been investigated^[11]. Radioimmunotherapy with mAbs targeting NHL have

Table 1 Radionuclides used in radioimmunotherapy of clear cell renal cell carcinoma

Radionuclide	Half-life	β -average (keV)	γ (keV)	Maximum range β -particles in tissue (mm)	Advantages	Disadvantages
¹³¹ I	8.0 days	192	362	3.0	Easy labeling; inexpensive	High radiation burden to personnel/relatives; hospital admittance required
¹⁸⁶ Re	90.7 h	362	137	5.1	Out-patient treatment possible; ideal gamma for imaging	Laborious labeling
⁹⁰ Y	64 h	935	None	12	High-energy beta-emission; prolonged tumor retention; out-patient treatment possible	No imaging possible
¹⁷⁷ Lu	6.7 days	149	208	2.5	Prolonged tumor retention	

shown exciting results. These tumors are relatively radio-sensitive and mAbs have good access to the tumor. The effector cell, complement and apoptosis inducing cytotoxicity of the mAb give high intrinsic anti-tumor activity as well. Extensive research has resulted in the first registered treatment with radiolabeled mAbs directed against the surface antigen CD-20 expressed on B-cell NHL (^{90}Y -labeled anti-CD20 mAb Ibritumomab Tiuxetan (Zevalin[®], Biogen Idec, Boston MA, USA and Schering, Berlin, Germany) and ^{131}I -labeled anti-CD20 mAb tositumomab (Bexxar[®], GSK, Philadelphia, PA, USA).

In patients with solid tumors, therapeutic strategies with radiolabeled mAbs have been less successful than in patients with hematological malignancies. This is partly due to the lower radiation sensitivity of solid tumors. However, as mentioned previously, tumor-related factors also play an important role. The most common types of solid malignancies targeted in clinical trials with RIT have been epithelial cancers, e.g. colorectal cancer, ovarian cancer, medullary thyroid cancer, breast cancer, prostate cancer and RCC. Results of these trials did not result in registration of radiolabeled mAb preparations for regular treatment of these cancer types. However, patients entered in these trials often had bulky metastatic disease and had been heavily pretreated with chemotherapy and/or radiotherapy in most cases. Complete responses to RIT have incidentally been reported. Partial responses and stabilization of previously progressive disease have been seen in few patients in most of these trials^[19].

Radiolabeled peptides in renal cell carcinoma

Peptides have been used for radionuclide targeting of tumors to overcome the difficulties in tumor targeting with mAbs mentioned above. These peptides have a high affinity for specific receptors that are expressed on the tumor cell. Following binding to the receptor the peptide–receptor complex is internalized, resulting in intracellular retention. Tumor targeting peptides have advantages over mAbs, as they diffuse rapidly in target tissue and clear rapidly from the blood and from the non-target tissues. Peptides are usually non-immunogenic and generally have a low toxicity profile. Peptide receptor radionuclide imaging (PRRI) and therapy (PRRT) are now under investigation. To date, the somatostatin (SST) analog ^{111}In -labeled-octreotide (OctreoScan[®], Mallinckrodt Tyco Healthcare, Petten, The Netherlands) is the most successful radiopeptide for tumor imaging and has been the first to be approved for scintigraphic localization of primary and metastatic neuro-endocrine tumors expressing SST2 and SST5 receptor subtypes^[20]. Expression of these receptors was found in 72% of RCC samples analyzed, irrespective of histopathological subtype or grading of the tumor^[21].

The use of [^{111}In]octreotide has been evaluated in patients with metastatic RCC. In this study, 68 RCC metastases in 9 patients, confirmed by diagnostic CT and/or X-ray images were evaluated. Forty (59%) of the 68 known sites were visualized^[22]. Besides octreotide, a new series of peptides is now being evaluated for targeting of solid tumors. Cholecystokinin (CCK) analogues, vasoactive intestinal peptide (VIP), neuropeptide Y (NPY), bombesin, glucagon-like peptide-1 (GLP-1) and RGD peptides have shown promising preclinical tumor-receptor targeting (for review see Reubi^[23]).

The gastrointestinal peptide gastrin acts as a neurotransmitter in the brain and as a regulator of various functions in the gastrointestinal tract^[24]. It mediates its actions via the CCK₁ and CCK₂ receptors^[25]. These receptors are highly expressed in medullary thyroid carcinoma (MTC), enabling gastrin to visualize metastatic MTC with very high sensitivity^[26]. RCC however, does not express these receptors and gastrin is therefore not suitable for RCC imaging^[23].

VIP, a member of the group of secretin-like peptides, is an important neurotransmitter in the gut. Its actions are mediated by specific G protein-coupled receptors that can be internalized upon ligand binding^[27]. Although expression of the VIP receptors has been found on neuroblastomas^[28], expression on RCC has not been determined.

NPY is a neurotransmitter that is predominantly found in the central nervous system, where it functions as a stimulator of feeding behavior and inhibition of anxiety^[29]. More recently, expression of NPY receptors has been found on RCC and neuroblastomas, suggesting a potential role for RCC targeting using radiolabeled NPY^[30].

Bombesin has a high and specific affinity for the gastrin releasing peptide receptor (GRP-R) and this receptor stimulates proliferation of tumor growth in various tumor types^[31]. RCC has been found to have a high expression of GRP-R^[32]. Targeting of RCC was done using a bombesin analogue labeled with ^{177}Lu . In this study, *in vitro* autoradiography showed specific uptake of the radioligand in five of the six RCC samples evaluated^[33].

Recently, GLP-1 receptor expression in solid human tumors has been evaluated extensively and systematically. This study found no GLP-1 receptor expression in 20 RCC tissue samples analyzed, excluding GLP-1 receptor as a target for *in vivo* RCC imaging or therapy^[34].

RGD peptides contain the amino acid sequence Arg-Gly-Asp that has high and specific affinity for the $\alpha_v\beta_3$ integrin^[35]. This integrin is mainly expressed on proliferating endothelial cells, whereas it is not expressed on quiescent endothelial cells^[36]. In growing tumors a continuous formation of new blood vessels is required. The $\alpha_v\beta_3$ integrin is considered a marker of angiogenesis in tumors. In addition, $\alpha_v\beta_3$ integrin is also expressed on various tumor cells including RCC. The expression of $\alpha_v\beta_3$ has been found to increase with higher RCC

tumor grades. Of the RCC metastases examined, 2 of 14 showed high expression of $\alpha_v\beta_3$, 8 of 14 showed weak expression and 4 of 14 did not express the $\alpha_v\beta_3$ integrin^[37]. To date, RGD peptides have not been evaluated for RCC imaging.

Monoclonal antibodies in renal cell carcinoma

In RCC, several mAbs have been defined that are reactive with RCC-associated antigens^[38–47]. Most of these recognize kidney differentiation antigens expressed by subsets of RCC. Cross-reactivity with non-kidney tissue was seen in some of these mAbs, whereas others were only expressed in kidney/RCC.

One of these mAbs, which showed relative high tumor-to-blood ratios in mice with RCC xenografts is mAb A6H^[48,49]. This mAb recognizes an antigen common to RCC, some lung and colon carcinomas, the proximal renal tubules but no other normal tissues *in vivo*^[50]. In a clinical study, the imaging and RIT potential of this mAb was examined^[49]. Positive images were obtained in 5 of 15 patients. This low sensitivity was attributed to soluble antigen binding by the mAb and the expression of antigen in normal tissue, thereby not allowing the mAb to bind to tumor tissue. This clinical finding of antigen expression in normal tissue was not in line with the previous findings. After modification of the dosing regimen, the detection rate of metastatic lesions increased, but the number of detected lesions remained unsatisfactory. As a result, the use of mAb A6H for diagnosis and treatment of RCC was discontinued.

Discovery and use of G250: from mG250 to cG250

G250, a mAb against a RCC-associated antigen has been investigated extensively, because the antigen which this mAb recognizes showed remarkable tissue distribution and expression. The mAb G250 was obtained after fusion of spleen cells from a mouse immunized with fresh RCC homogenates. The antigen that mAb G250 targets has been designated in the literature as MN, CA IX and G250. The term G250-antigen is used in this review. Of the 47 primary RCC specimens initially analyzed, 42 (89%) showed homogeneous G250-antigen expression, whereas four tumors showed heterogeneous expression and one tumor was G250-antigen-negative. Of the eight metastases examined, G250-antigen expression was homogeneous in five (62%), heterogeneous in two, while one did not express the G250-antigen^[43]. Expression in normal tissues has been evaluated extensively and has been shown to be restricted to the (upper) gastrointestinal mucosa (stomach, ileum, proximal and middle colon) and gastrointestinal related structures (intra- and extrahepatic biliary system, pancreas)^[43,51,52].

Later studies showed an almost ubiquitous expression (>90%) of G250-antigen in clear cell RCC (ccRCC), being the most prominent form of RCC (80% of cases). G250-antigen expression in the different histological subtypes of RCC was determined by RT-PCR and immunohistochemistry. All the clear cell tumors displayed G250-antigen mRNA, but expression of G250-antigen by oncocytomas, chromophobe or papillary RCC was low or absent^[53–55]. These results directed the scope of G250-mAb studies to clear cell type RCC.

An early or a first event in the clear cell RCC tumorigenic pathway is mutations leading to loss of Von Hippel Lindau protein (pVHL) in 50–75% of sporadic RCC. In normoxic conditions pVHL is responsible for degradation of hypoxia inducible factor-1 α (HIF-1 α), which thereby cannot bind to HIF-1 β to form HIF-1. In hypoxic conditions, however, degradation does not occur and HIF-1 can cause the transcription of a number of hypoxia-inducible genes. These include vascular endothelial growth factor (VEGF), transforming growth factor- α (TGF α), erythropoietin, G250-antigen and others. Clearly, expression of these proteins is advantageous for tumor growth. With the loss of functional pVHL in RCC the hypoxia response pathway is also active, thereby mimicking hypoxic conditions^[56]. This mutational loss of pVHL thus explains why G250-antigen is almost invariably upregulated in ccRCC. G250-antigen is also expressed in various other tumor types (e.g. cervix, lung) under hypoxic conditions.

Various animal and *ex vivo* experiments have shown the potential of the G250 mAb as a targeting modality of RCC^[57–62]. Since G250-antigen is high and homogeneously expressed in RCC tissue, is restricted to a few normal tissues and other tumors, and a low mAb dose is needed to obtain antigen saturation, mAb G250 seemed a suitable candidate for further investigation in clinical studies.

Two clinical studies with radiolabeled murine G250 (mG250) have been completed. Imaging and biodistribution were studied in 16 patients receiving 370 MBq ¹³¹I-labeled mG250 at escalating protein dose levels 1 week prior to nephrectomy. After 3–4 days clear delineation of tumors was seen in 12 patients, imaged with a gamma camera. Ten of these tumors proved to be G250-positive, whereas the other two showed less than 5% G250-antigen expression. The four tumors that were not visualized were non-clear cell RCC. After nephrectomy, tumor samples were shown to have high and focal uptake of G250, up to 0.21 % injected dose/gram (%ID/g). Tumor targeting was not the result of blood pooling, as the blood volume marker ^{99m}Tc-labeled human serum albumin showed significantly lower tumor uptake than [¹³¹I]mG250 that had been administered earlier. Therefore, this was indicative of true antibody targeting of the tumor by mG250^[63]. As good targeting of ccRCC by mG250 was seen in this study, a phase I/II radioimmunotherapy (RIT) dose escalation

study was performed by Divgi *et al.* Patients in this study were treated with one high-activity-dose injection of [^{131}I]mG250. After reaching the maximum tolerated dose (MTD), another 15 patients were enrolled and treated at the MTD to monitor any possible therapeutic effects. In the phase I dose-escalation study, MTD was defined at 3330 MBq/m², due to hematological toxicity. Transient hepatic toxicity occurred at dose levels of 1665 MBq/m² and higher, but was not dose limiting. Fourteen patients had grade 3 hepatic toxicity, that did not last for more than 2 weeks. A total of 33 patients was treated, 18 in the dose-escalating part of the study and another 15 patients at the MTD (3330 MBq/m²), to evaluate therapeutic efficacy. Of these 33 patients, 17 stabilized for 3 months, after which patients received other treatments, preventing further follow-up. Three patients showed regression of some of their lesions, but no partial or complete responses were noted^[64].

The formation of human anti mouse antibodies (HAMA) in all patients receiving mG250 prohibited retreatment. Formation of immune complexes with rapid clearance of the radiolabeled mAb to liver and spleen would have occurred in the case of multiple administrations, thereby limiting targeting of the mAb to the tumor^[64]. This, in combination with the high potential of G250 as a targeting agent in the treatment of metastasized RCC, led to the development of a chimeric form of G250 (cG250)^[65]. This mAb is composed of murine antigen-binding variable domains, that recognize the TAA and human constant domains of heavy and light chains derived from the human IgG₁ isotype^[66,67]. The rationale behind this construction was the decrease in immunogenicity of the antibody, potentially allowing multiple administrations.

Use of unlabeled antibody cG250

Unlabeled G250 antibody facilitates antibody-dependent cellular cytotoxicity (ADCC) of G250-antigen expressing cells, which leads to induction of lysis of these cells^[66]. This finding led to a study where 36 patients with metastatic ccRCC received 50 mg cG250 weekly for 12 weeks. No drug-related grade 3–4 toxicity occurred during this trial^[68]. Development of human anti chimeric antibody (HACA) was low and not clinically significant. Before treatment, 80% of patients were progressive. After treatment, 11 patients had stable disease and during follow-up one complete and one partial response were seen. The median survival of 15 months suggested that G250 may be able to immunomodulate the natural course of metastatic RCC^[69]. Based on these results, an adjuvant phase III trial has been initiated in high-risk ccRCC patients who are nephrectomized and have no known metastases, using this treatment regimen.

Since the 1990s, high-dose bolus interleukin-2 (IL-2) has been established as a first-line therapy for metastatic RCC. IL-2 is a T-cell growth factor that is thought to play

a critical role in T-cell dependent immune responses. High-dose bolus IL-2 as therapy in metastatic RCC has had varying success, with responses in up to 15% of patients^[70]. It was hypothesized that the immunological specificity of lymphokine-activated killer cells of patients receiving IL-2 therapy may be enhanced through the co-administration of cG250^[66]. Vice versa, co-administration of IL-2 can enhance the therapeutic efficacy of G250^[71–73].

In a phase II trial 35 patients with progressive ccRCC received weekly i.v. infusions of 50 mg G250 and daily s.c. low-dose IL-2, for 11 weeks. When patients responded or disease stabilized, therapy was continued for another 6 weeks. Treatment was safe and well tolerated. After 16 weeks, 1 partial response was noted and 11 patients had stabilized. These 12 patients continued treatment. This resulted in 1 partial response and 7 patients retained stable disease. Mean survival was 24 months in this trial, compared to 16.3 months median survival with high-dose IL-2 therapy^[70], which also has toxic side effects. The authors considered it unlikely that the increased survival was due to the low-dose IL-2, using a six-fold decrease of normal IL-2 dose used to induce clinical efficacy. They considered it rather a synergic effect of G250 and IL-2^[74].

Studies with cG250 labeled with indium, iodine and lutetium

After cG250 became available, the pharmacokinetics, biodistribution, imaging characteristics and dosimetry of this new radiolabeled targeting vehicle was studied in a protein dose escalation study identical to murine G250. Sixteen presurgical RCC patients received increasing doses of cG250 between 2 and 50 mg labeled with ^{131}I , given i.v. a week before they underwent nephrectomy. Highest tumor uptake was observed in the patients that received 5 and 10 mg [^{131}I]mG250, with focal tumor uptake as high as 0.52% ID/g. At higher protein doses, focal tumor uptake did not exceed 0.017% ID/g. This suggested that antigen-saturation could have occurred at protein doses exceeding 10 mg. Excellent images of G250-antigen positive tumors were obtained, with visualization of tumor lesions and metastases, seen earlier on CT or X-ray. No previously unknown lesions were visualized. Dosimetric analysis showed a high radiation-absorbed dose to primary tumors as well as metastases (up to 1.9 cGy/MBq to primary tumor). Up to 20 weeks post-injection, human anti chimeric antibody (HACA) responses were seen in two patients, but titers were considered low and clinically irrelevant^[75]. Reducing the immunogenic properties of the antibody opened the possibility of multiple treatments. These results justified further investigation on the use of cG250 as a radioimmunotherapeutic agent.

The MTD of [^{131}I]cG250 in metastatic RCC was determined in a phase I radioactivity dose escalation

trial in patients with progressive metastatic RCC at study entry. Twelve patients received 5 mg of cG250 labeled with 185 MBq ^{131}I (scout dose). When accumulation of antibody was seen in any tumor site, patients received escalating radioactivity-doses of [^{131}I]cG250. In contrast to the trials performed with murine G250, no hepatic toxicity was seen. This was believed to be the result of saturation of the hepatic compartment by the diagnostic scout dose of [^{131}I]cG250. Besides mild nausea without vomiting and transient fatigue (both grade 1 CTC), no other non-hematological side effects occurred. The MTD was observed to be 2220 MBq/m², with hematological toxicity as the dose-limiting factor. Of the 8 patients receiving treatment, 1 showed stable disease and 1 had a partial response^[76].

In subsequent studies two strategies were tested to optimize targeting of metastatic ccRCC with RIT. These were fractionation of the dose and two sequential high-dose treatments.

Fractionation of the dose was done in a phase I study by Divgi *et al.*^[77]. In this study, patients received 1110 MBq of [^{131}I]cG250 and whole-body activity was measured after 2–3 days. Then, another administration of [^{131}I]cG250 was given to again ‘top up’ the radioactivity in the body to 1110 MBq. This was continued until a whole-body absorbed dose of 0.50 Gy was reached. Patients without disease progression were retreated after recovery from hematological toxicity. In subsequent cohorts, the whole-body absorbed dose was increased by 0.25 Gy. A total of 15 patients were included in the trial. HACA development was measured in two patients, altering pharmacokinetics and excluding them from further treatment. Dose-limiting toxicity was again hematopoietic, with the MTD at 0.75 Gy as whole-body absorbed dose. Four patients received multiple fractionated doses. Seven patients stabilized, but no major clinical responses were seen. This trial therefore provided no evidence of a potential benefit of fractionation of RIT doses in treating ccRCC.

The MTD found in the activity dose-escalation study by Steffens *et al.* (2220 MBq/m²), combined with the properties of cG250 allowing multiple administrations, led to a study where two sequential high doses of [^{131}I]cG250 treatment were given. Patients had progressive metastatic ccRCC at study entry. Patients received 2220 MBq/m² [^{131}I]cG250. Three months later, rapid clearance of the mAb by HACA development was excluded by imaging of a scout dose of 185 MBq [^{131}I]cG250. When tumor targeting was seen again, the second high-dose injection [^{131}I]cG250 was given. MTD of the second RIT proved to be again due to hematological toxicity and was set at 1665 MBq/m², being 75% of the MTD of the first infusion). Subsequently, 15 patients were treated at this dose level to evaluate tumor response. In total, 29 patients entered the study, 11 were excluded due to grade 4 hematological toxicity after the first RIT ($n=3$), palliative treatment ($n=2$), rapid progressive

disease ($n=2$) or HACA development ($n=4$). Of the 18 patients evaluated (3 not receiving the second RIT at MTD), 5 patients had stabilization of their disease, lasting 3–12 months. No partial or complete responses were seen. There proved to be an inverse correlation between the size of metastases and radiation absorbed dose. Therapeutic radiation doses (more than 50 Gy)^[78] were only guided to the lesions smaller than 5 g. The authors concluded that RIT in RCC patients could best be given in the setting of small volume disease or as adjuvant therapy^[79].

Various radionuclides in targeting ccRCC with cG250 have been under investigation. First, the targeting capabilities of [^{111}In]cG250 have been compared to those of [^{131}I]cG250. In nude mice-human tumor models, superior targeting of ^{111}In over ^{131}I had been shown^[80,81]. As part of the cG250 antibody-antigen complex is internalized, intracellular [^{131}I]cG250 is metabolized and rapidly excreted by the tumor cell. Metallic radionuclides, such as ^{111}In , ^{90}Y and ^{177}Lu , are trapped in the lysosomes and residualize after internalization of the mAb-antigen complex by the target cells^[82–85]. To investigate whether this phenomenon may also occur in humans, five patients with metastatic RCC were i.v. injected with 185 MBq of [^{111}In]DTPA-cG250 on day 0 and 185 MBq of [^{131}I]cG250 on day 4. Gamma images were made directly and on day 4 after both injections and compared (Fig. 1). [^{111}In]DTPA-cG250 images revealed more lesions than [^{131}I]cG250 (47 vs. 30) and quantitative analysis showed higher accumulation of [^{111}In]DTPA-cG250 in 20 of 25 lesions measured in terms of %ID/g^[52].

The therapeutic properties of cG250 labeled with four radionuclides have been tested in nude mice with human RCC xenografts. The four radionuclides under investigation were ^{90}Y and ^{177}Lu (both residualizing), and ^{131}I and ^{186}Re (both non-residualizing). After determining the MTD for each radionuclide conjugated to cG250 in mice, an RIT experiment was done comparing tumor growth and survival after treatment with each radiolabeled cG250 preparation. Tumor growth was delayed most effectively by ^{177}Lu , followed by ^{90}Y and ^{186}Re and least by ^{131}I (185, 125, 90 and 25 days, respectively). The best median survival was observed for ^{177}Lu (300 days), with the control group having a median survival of less than 150 days. The residualizing radionuclides ^{177}Lu and ^{90}Y led to higher radiation doses to the tumor. These radionuclides should be considered better candidates for RIT with cG250 than ^{131}I ^[86].

Based on these preclinical and clinical data (Table 2), an ongoing phase I/II [^{177}Lu]DOTA-cG250 dose escalation RIT study in progressive, metastatic RCC patients was designed. Patients in whom cG250 targeting of RCC metastases is observed are treated with up to three cycles of [^{177}Lu]DOTA-cG250 to determine MTD. So far, minor responses have been noted at the lower dose levels and dose escalation is ongoing.

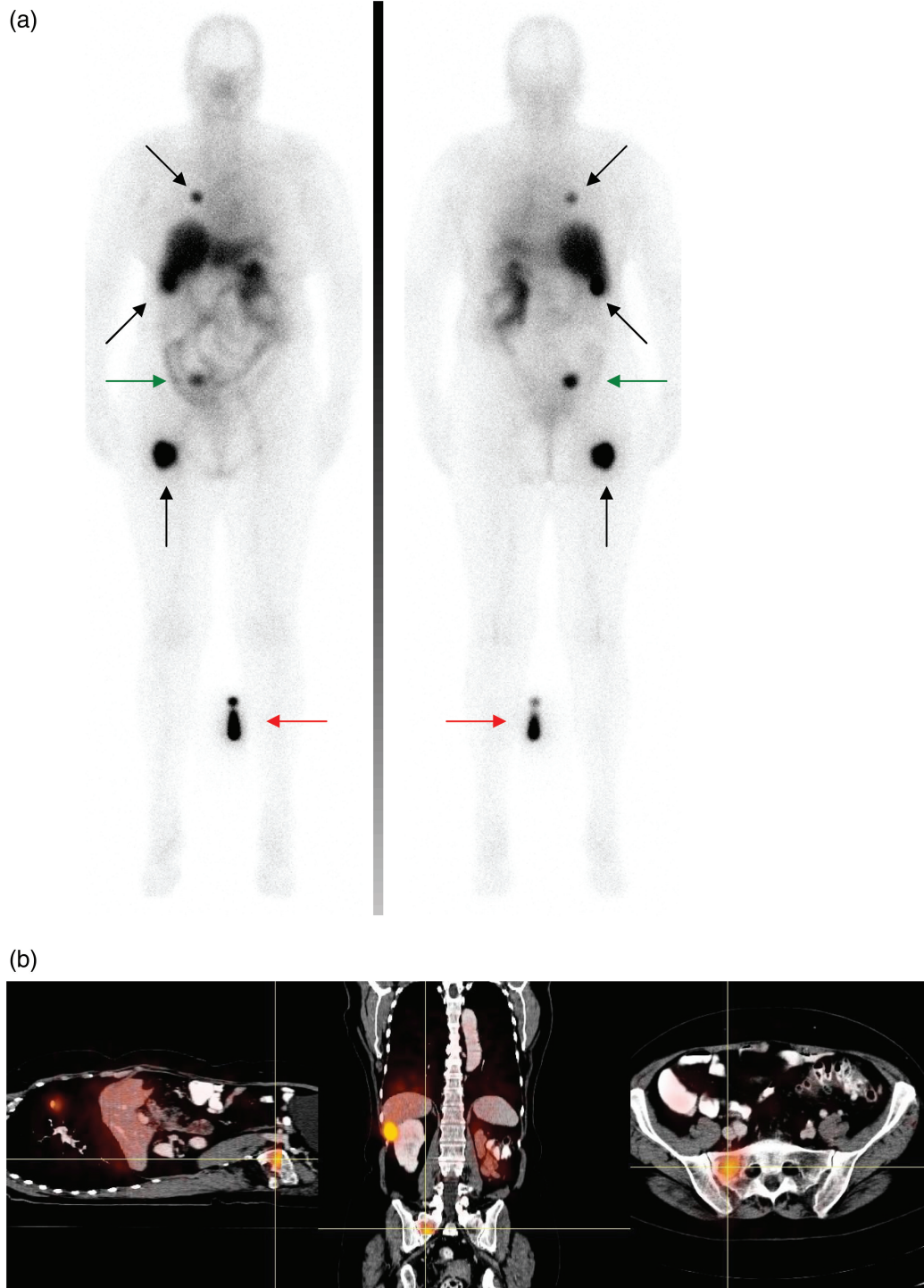


Figure 1 (a) [^{111}In]cG250 immunoscintigram of a patient with metastatic ccRCC, acquired 6 days after injection of 185 MBq of [^{111}In]cG250. Black arrows mark the RCC lesions. Green arrows mark a lesion not seen on the fluorodeoxyglucose (FDG)-positron emission tomography (PET)-computed tomography(CT) images shown in (b). Red arrows indicate the injection standard. The anterior image is shown in the left panel, the posterior image is shown in the right panel. (b) PET-CT scan of the same patient acquired after injection of 250 MBq of [^{18}F]FDG.

Future strategies to improve clinical efficacy of cG250 could be: (1) tumor pretargeting; (2) high dose RIT with bone marrow support or transplant or (3) use of high linear energy transfer (LET) particles emitting

radionuclides. In pretargeting RIT, administration of the mAb is separated from the injection of the radionuclide. This allows the unlabeled mAb to bind to the tumor as well as to clear from circulation and normal organs.

Table 2 Phase I/II radioimmunotherapy trials in clear cell renal cell carcinoma

Reference	Radiopharmaceutical	Target antigen	MAb type	No. of patients	Responses	Special features
Divgi et al. ^[46]	[¹³¹ I]G250	G250	Murine G250	33	17 SD	
Steffens et al. ^[57]	[¹³¹ I]G250	G250	Chimeric G250	12	1 PR; 1 SD	
Divgi et al. ^[59]	[¹³¹ I]cG250	G250	Chimeric G250	15	7 SD	Fractionated RIT
Brouwers et al. ^[61]	[¹³¹ I]cG250	G250	Chimeric G250	27	5 SD	Two high-dose treatment

The radionuclide is administered in a second injection as a rapidly clearing agent with high affinity to the previously administered mAb. Affinity of the radionuclide binding to the mAb may be achieved through, e.g. an avidin-biotin complex or with bispecific mAbs (bsmAbs). Biotinylated mAb and radionuclides can be coupled through an extremely avid interaction with avidin (for review see Boerman et al.^[87] and Goldenberg et al.^[88]). For cG250, a bsmAb (cG250 X DTIn-1) was produced and pretargeting experiments in nude mice with RCC xenografts targeted with ¹¹¹In-labeled bivalent peptide showed excellent tumor targeting^[89,90]. To date, however, this approach has not been tested clinically for cG250.

Autologous marrow transplantation or peripheral blood stem cell reinfusion has been investigated as a means to overcome bone marrow toxicity in RIT, thereby allowing administration of activity doses more than twice as high as without any bone marrow support^[91,92].

The use of LET (alpha) particle emitting radionuclides has the advantage of high cytotoxic potency, combined with a low range and thus not reaching most normal tissue surrounding the tumor. However, most alpha-emitters have a half-life of less than 1 h, which is hardly compatible with mAbs targeting tumors.

G250 has demonstrated excellent targeting abilities in ccRCC patients. Nevertheless, to date clinical impact of RIT for treatment of ccRCC has been minimal. It remains to be established whether the use of more powerful radionuclides can lead to alteration of the clinical course of metastatic ccRCC. Second, G250 may be more valuable in an adjuvant setting and/or as a diagnostic means. Finally, with the advent of new treatment possibilities for RCC such as angiogenesis inhibitors, combination treatment with G250 RIT and these new substances may play a role in more effective management of ccRCC.

References

- [1] Jemal A, Siegel R, Ward E, et al. Cancer statistics, 2006. *CA Cancer J Clin* 2006; 56: 106–30.
- [2] DeKernion JB. Real numbers. In: Campbell's urology. Philadelphia: WB Saunders; 1986.
- [3] Skinner DG, Colvin RB, Vermillion CD, Pfister RC, Leadbetter WF. Diagnosis and management of renal cell carcinoma. A clinical and pathologic study of 309 cases. *Cancer* 1971; 28: 1165–77.
- [4] Gold PJ, Fefer A, Thompson JA. Paraneoplastic manifestations of renal cell carcinoma. *Semin Urol Oncol* 1996; 14: 216–22.
- [5] Pantuck AJ, Zisman A, Beldegrun AS. The changing natural history of renal cell carcinoma. *J Urol* 2001; 166: 1611–23.
- [6] Zisman A, Pantuck AJ, Wieder J, et al. Risk group assessment and clinical outcome algorithm to predict the natural history of patients with surgically resected renal cell carcinoma. *J Clin Oncol* 2002; 20: 4559–66.
- [7] Motzer RJ, Russo P. Systemic therapy for renal cell carcinoma. *J Urol* 2000; 163: 408–17.
- [8] Yagoda A, Petrylak D, Thompson S. Cytotoxic chemotherapy for advanced renal cell carcinoma. *Urol Clin North Am* 1993; 20: 303–21.
- [9] Ehrlich P. Collected studies on immunology. New York: John Wiley; 1906.
- [10] Kohler G, Milstein C. Continuous cultures of fused cells secreting antibody of predefined specificity. *Nature* 1975; 256: 495–7.
- [11] Larson SM. Lymphoma, melanoma, colon cancer: diagnosis and treatment with radiolabeled monoclonal antibodies. The 1986 Eugene P. Pendergrass New Horizons Lecture. *Radiology* 1987; 165: 297–304.
- [12] Larson SM, Divgi CR, Scott AM. Overview of clinical radioimmunodetection of human tumors. *Cancer* 1994; 73: 3 (Suppl): 832–5.
- [13] Mach JP, Pelegrin A, Buchegger F. Imaging and therapy with monoclonal antibodies in non-hematopoietic tumors. *Curr Opin Immunol* 1991; 3: 685–93.
- [14] Goldenberg DM. Current status of cancer imaging with radiolabeled antibodies. *J Cancer Res Clin Oncol* 1987; 113: 203–8.
- [15] Goldenberg DM, Larson SM, Reisfeld RA, Schlom J. Targeting cancer with radiolabeled antibodies. *Immunol Today* 1995; 16: 261–4.
- [16] Oosterwijk E, Divgi CR, Brouwers A, et al. Monoclonal antibody-based therapy for renal cell carcinoma. *Urol Clin North Am* 2003; 30: 623–31.
- [17] Jain RK. Delivery of molecular medicine to solid tumors: lessons from in vivo imaging of gene expression and function. *J Control Release* 2001; 74: 7–25.
- [18] Eisen NH, Keston AS. The immunologic reactivity of bovine serum albumin labeled with trace-amounts of radioactive iodine (I-131). *J Immunol* 1950; 63: 71–80.
- [19] Koppe MJ, Postema EJ, Aarts F, Oyen WJ, Bleichrodt RP, Boerman OC. Antibody-guided radiation therapy of cancer. *Cancer Metastasis Rev* 2005; 24: 539–67.
- [20] Ricke J, Klose KJ, Mignon M, Oberg K, Wiedenmann B. Standardisation of imaging in neuroendocrine tumours: results of a European Delphi process. *Eur J Radiol* 2001; 37: 8–17.
- [21] Reubi JC, Kvolis L. Somatostatin receptors in human renal cell carcinomas. *Cancer Res* 1992; 52: 6074–8.
- [22] Edgren M, Westlin JE, Kalkner KM, Sundin A, Nilsson S. [¹¹¹In-DPTA-D-Phe1]-octreotide scintigraphy in the management of patients with advanced renal cell carcinoma. *Cancer Biother Radiopharm* 1999; 14: 59–64.
- [23] Reubi JC. Peptide receptors as molecular targets for cancer diagnosis and therapy. *Endocr Rev* 2003; 24: 389–427.
- [24] Walsh J. Gastrin. In: Walsh JH, Dockray GJ, editors. Gut peptides: biochemistry and physiology. New York: Raven Press, 1994: 75–121.

- [25] Wank SA, Pisegna JR, de WA. Brain and gastrointestinal cholecystokinin receptor family: structure and functional expression. *Proc Natl Acad Sci U S A* 1992; 89: 8691–5.
- [26] Gotthardt M, Behe MP, Beuter D, *et al.* Improved tumour detection by gastrin receptor scintigraphy in patients with metastasised medullary thyroid carcinoma. *Eur J Nucl Med Mol Imaging* 2006; 33: 1273–9.
- [27] Ottaway CA. Insertion and internalization of vasoactive intestinal peptide (VIP) receptors in murine CD4T lymphocytes. *Regul Pept* 1992; 41: 49–59.
- [28] Reubi JC, Laderach U, Waser B, Gebbers JO, Robberecht P, Laissue JA. Vasoactive intestinal peptide/pituitary adenylate cyclase-activating peptide receptor subtypes in human tumors and their tissues of origin. *Cancer Res* 2000; 60: 3105–12.
- [29] Pedrazzini T, Seydoux J, Kunstner P, *et al.* Cardiovascular response, feeding behavior and locomotor activity in mice lacking the NPY Y1 receptor. *Nat Med* 1998; 4: 722–6.
- [30] Korner M, Waser B, Reubi JC. Neuropeptide Y receptors in renal cell carcinomas and nephroblastomas. *Int J Cancer* 2005; 115: 734–41.
- [31] Carney DN, Cuttitta F, Moody TW, Minna JD. Selective stimulation of small cell lung cancer clonal growth by bombesin and gastrin-releasing peptide. *Cancer Res* 1987; 47: 821–5.
- [32] Pansky A, de Weerth A, Fasler-Kan E, *et al.* Gastrin releasing peptide-preferring bombesin receptors mediate growth of human renal cell carcinoma. *J Am Soc Nephrol* 2000; 11: 1409–18.
- [33] Waser B, Eltschinger V, Linder K, Nunn A, Reubi JC. Selective in vitro targeting of GRP and NMB receptors in human tumours with the new bombesin tracer (177)Lu-AMBA. *Eur J Nucl Med Mol Imaging* 2007; 34: 95–100.
- [34] Korner M, Stockli M, Waser B, Reubi JC. GLP-1 receptor expression in human tumors and human normal tissues: potential for in vivo targeting. *J Nucl Med* 2007; 48: 736–43.
- [35] Plow EF, Haas TA, Zhang L, Loftus J, Smith JW. Ligand binding to integrins. *J Biol Chem* 2000; 275: 21785–8.
- [36] Brooks PC. Role of integrins in angiogenesis. *Eur J Cancer* 1996; 32A: 2423–9.
- [37] Wechsel HW, Petri E, Feil G, Nelde HJ, Bichler KH, Loeser W. Renal cell carcinoma: immunohistological investigation of expression of the integrin alpha v beta 3. *Anticancer Res* 1999; 19(2C): 1529–32.
- [38] Bander NH, Cordon-Cardo C, Finstad CL, *et al.* Immunohistologic dissection of the human kidney using monoclonal antibodies. *J Urol* 1985; 133: 502–5.
- [39] Bander NH, Finstad CL, Cordon-Cardo C, *et al.* Analysis of a mouse monoclonal antibody that reacts with a specific region of the human proximal tubule and subsets renal cell carcinomas. *Cancer Res* 1989; 49: 6774–80.
- [40] Finstad CL, Cordon-Cardo C, Bander NH, Whitmore WF, Melamed MR, Old LJ. Specificity analysis of mouse monoclonal antibodies defining cell surface antigens of human renal cancer. *Proc Natl Acad Sci U S A* 1985; 82: 2955–9.
- [41] Fischer P, Storkel S, Haase W, Scherberich JE. Differential diagnosis of histogenetically distinct human epithelial renal tumours with a monoclonal antibody against gamma-glutamyl-transferase. *Cancer Immunol Immunother* 1991; 33: 382–8.
- [42] Kinouchi T, Nakayama E, Ueda R, *et al.* Characterization of a kidney antigen defined by a mouse monoclonal antibody K2.7. *J Urol* 1987; 137: 151–4.
- [43] Oosterwijk E, Ruiters DJ, Hoedemaeker PJ, *et al.* Monoclonal antibody G 250 recognizes a determinant present in renal-cell carcinoma and absent from normal kidney. *Int J Cancer* 1986; 38: 489–94.
- [44] Oosterwijk E, Ruiters DJ, Wakka JC, *et al.* Immunohistochemical analysis of monoclonal antibodies to renal antigens. Application in the diagnosis of renal cell carcinoma. *Am J Pathol* 1986; 123: 301–9.
- [45] Tokuyama H, Tokuyama Y. Mouse monoclonal antibodies with restricted specificity for human renal cell carcinoma and ability to modulate the tumor cell growth in vitro. *Hybridoma* 1988; 7: 155–65.
- [46] Vessella RL, Lange PH, Palme DF, Chiou RK, Elson MK, Wessels BW. Radioiodinated monoclonal antibodies in the imaging and treatment of human renal cell carcinoma xenografts in nude mice. *Targeted Diagn Ther* 1988; 1: 245–82.
- [47] Yoshida SO, Imam A. Monoclonal antibody to a proximal nephrogenic renal antigen: immunohistochemical analysis of formalin-fixed, paraffin-embedded human renal cell carcinomas. *Cancer Res* 1989; 49: 1802–9.
- [48] Chiou RK, Vessella RL, Elson MK, *et al.* Localization of human renal cell carcinoma xenografts with a tumor-preferential monoclonal antibody. *Cancer Res* 1985; 45(12 Pt 1): 6140–6.
- [49] Vessella RL, Chiou RK, Grund FM. Renal cell carcinoma (RCC) phase I–II trials with ¹³¹I labeled monoclonal antibody A6H: imaging and pharmacokinetic studies. *Proc Am Assoc Cancer Res* 1987; 28–480(abstract 1525).
- [50] Vessella RL, Moon TD, Chiou RK, *et al.* Monoclonal antibodies to human renal cell carcinoma: recognition of shared and restricted tissue antigens. *Cancer Res* 1985; 45(12 Pt 1): 6131–9.
- [51] Pastorekova S, Parkkila S, Parkkila AK, *et al.* Carbonic anhydrase IX, MN/CA IX: analysis of stomach complementary DNA sequence and expression in human and rat alimentary tracts. *Gastroenterology* 1997; 112: 398–408.
- [52] Brouwers AH, Buijs WC, Oosterwijk E, *et al.* Targeting of metastatic renal cell carcinoma with the chimeric monoclonal antibody G250 labeled with (¹³¹I) or (¹¹¹In): an intrapatient comparison. *Clin Cancer Res* 2003; 9(10 Pt 2): S3953–60.
- [53] Bismar TA, Bianco FJ, Zhang H, *et al.* Quantification of G250 mRNA expression in renal epithelial neoplasms by real-time reverse transcription-PCR of dissected tissue from paraffin sections. *Pathology* 2003; 35: 513–7.
- [54] Chen YT, Tu JJ, Kao J, Zhou XK, Mazumdar M. Messenger RNA expression ratios among four genes predict subtypes of renal cell carcinoma and distinguish oncocytoma from carcinoma. *Clin Cancer Res* 2005; 11: 6558–66.
- [55] Uemura H, Nakagawa Y, Yoshida K, *et al.* MN/CA IX/G250 as a potential target for immunotherapy of renal cell carcinomas. *Br J Cancer* 1999; 81: 741–6.
- [56] Sufan RI, Jewett MA, Ohh M. The role of von Hippel-Lindau tumor suppressor protein and hypoxia in renal clear cell carcinoma. *Am J Physiol Renal Physiol* 2004; 287: F1–6.
- [57] Kranenborg MH, Boerman OC, de Weijert MC, Oosterwijk-Wakka JC, Corstens FH, Oosterwijk E. The effect of antibody protein dose of anti-renal cell carcinoma monoclonal antibodies in nude mice with renal cell carcinoma xenografts. *Cancer* 1997; 80: 12 Suppl): 2390–7.
- [58] Steffens MG, Kranenborg MH, Boerman OC, *et al.* Tumor retention of ¹⁸⁶Re-MAG3, ¹¹¹In-DTPA and ¹²⁵I labeled monoclonal antibody G250 in nude mice with renal cell carcinoma xenografts. *Cancer Biother Radiopharm* 1998; 13: 133–9.
- [59] Steffens MG, Oosterwijk-Wakka JC, Zegwaard-Hagemeyer NE, *et al.* Immunohistochemical analysis of tumor antigen saturation following injection of monoclonal antibody G250. *Anticancer Res* 1999; 19(2A): 1197–200.
- [60] van Dijk J, Oosterwijk E, van Kroonenburgh MJ, *et al.* Perfusion of tumor-bearing kidneys as a model for scintigraphic screening of monoclonal antibodies. *J Nucl Med* 1988; 29: 1078–82.
- [61] van Dijk J, Uemura H, Beniers AJ, Peelen WP, *et al.* Therapeutic effects of monoclonal antibody G250, interferons and tumor necrosis factor, in mice with renal-cell carcinoma xenografts. *Int J Cancer* 1994; 56: 262–8.
- [62] van Dijk J, Zegveld ST, Fleuren GJ, Warnaar SO. Localization of monoclonal antibody G250 and bispecific monoclonal antibody CD3/G250 in human renal-cell carcinoma xenografts: relative effects of size and affinity. *Int J Cancer* 1991; 48: 738–43.
- [63] Oosterwijk E, Bander NH, Divigi CR, *et al.* Antibody localization in human renal cell carcinoma: a phase I study of monoclonal antibody G250. *J Clin Oncol* 1993; 11: 738–50.

- [64] Divgi CR, Bander NH, Scott AM, *et al.* Phase I/II radioimmunotherapy trial with iodine-131-labeled monoclonal antibody G250 in metastatic renal cell carcinoma. *Clin Cancer Res* 1998; 4: 2729–39.
- [65] Oosterwijk E, Debruyne FM, Schalken JA. The use of monoclonal antibody G250 in the therapy of renal-cell carcinoma. *Semin Oncol* 1995; 22: 34–41.
- [66] Surfus JE, Hank JA, Oosterwijk E, *et al.* Anti-renal-cell carcinoma chimeric antibody G250 facilitates antibody-dependent cellular cytotoxicity with in vitro and in vivo interleukin-2-activated effectors. *J Immunother Emphasis Tumor Immunol* 1996; 19: 184–91.
- [67] Morrison SL, Johnson MJ, Herzenberg LA, Oi VT. Chimeric human antibody molecules: mouse antigen-binding domains with human constant region domains. *Proc Natl Acad Sci U S A* 1984; 81: 6851–5.
- [68] Trotti A, Colevas AD, Setser A, *et al.* CTCAE v3.0: development of a comprehensive grading system for the adverse effects of cancer treatment. *Semin Radiat Oncol* 2003; 13: 176–81.
- [69] Bleumer I, Knuth A, Oosterwijk E, *et al.* A phase II trial of chimeric monoclonal antibody G250 for advanced renal cell carcinoma patients. *Br J Cancer* 2004; 90: 985–90.
- [70] Fyfe G, Fisher RI, Rosenberg SA, Sznol M, Parkinson DR, Louie AC. Results of treatment of 255 patients with metastatic renal cell carcinoma who received high-dose recombinant interleukin-2 therapy. *J Clin Oncol* 1995; 13: 688–96.
- [71] Atkins M, Regan M, McDermott D, *et al.* Carbonic anhydrase IX expression predicts outcome of interleukin 2 therapy for renal cancer. *Clin Cancer Res* 2005; 11: 3714–21.
- [72] Brouwers AH, Boerman OC, Oyen WJ. In vivo molecular prediction of carbonic anhydrase IX-G250MN expression on immunotherapy outcome in renal cancer. *Clin Cancer Res* 2005; 11(24 Pt 1): 8886.
- [73] Liu Z, Smyth FE, Renner C, Lee FT, Oosterwijk E, Scott AM. Anti-renal cell carcinoma chimeric antibody G250: cytokine enhancement of in vitro antibody-dependent cellular cytotoxicity. *Cancer Immunol Immunother* 2002; 51: 171–7.
- [74] Bleumer I, Oosterwijk E, Oosterwijk-Wakka JC, *et al.* A clinical trial with chimeric monoclonal antibody WX-G250 and low dose interleukin-2 pulsing scheme for advanced renal cell carcinoma. *J Urol* 2006; 175: 57–62.
- [75] Steffens MG, Boerman OC, Oosterwijk-Wakka JC, *et al.* Targeting of renal cell carcinoma with iodine-131-labeled chimeric monoclonal antibody G250. *J Clin Oncol* 1997; 15: 1529–37.
- [76] Steffens MG, Boerman OC, de Mulder PH, *et al.* Phase I radioimmunotherapy of metastatic renal cell carcinoma with ¹³¹I-labeled chimeric monoclonal antibody G250. *Clin Cancer Res* 1999; 5: 10 Suppl): s3268–74.
- [77] Divgi CR, O'Donoghue JA, Welt S, *et al.* Phase I clinical trial with fractionated radioimmunotherapy using ¹³¹I-labeled chimeric G250 in metastatic renal cancer. *J Nucl Med* 2004; 45: 1412–21.
- [78] Goldenberg DM. Targeted therapy of cancer with radiolabeled antibodies. *J Nucl Med* 2002; 43: 693–713.
- [79] Brouwers AH, Mulders PF, de Mulder PH, *et al.* Lack of efficacy of two consecutive treatments of radioimmunotherapy with ¹³¹I-cG250 in patients with metastasized clear cell renal cell carcinoma. *J Clin Oncol* 2005; 23: 6540–8.
- [80] Carrasquillo JA, Mulshine JL, Bunn PA Jr, *et al.* Indium-111 T101 monoclonal antibody is superior to iodine-131 T101 in imaging of cutaneous T-cell lymphoma. *J Nucl Med* 1987; 28: 281–7.
- [81] Yokoyama K, Carrasquillo JA, Chang AE, *et al.* Differences in biodistribution of indium-111-and iodine-131-labeled B72.3 monoclonal antibodies in patients with colorectal cancer. *J Nucl Med* 1989; 30: 320–7.
- [82] Shih LB, Thorpe SR, Griffiths GL, *et al.* The processing and fate of antibodies and their radiolabels bound to the surface of tumor cells in vitro: a comparison of nine radiolabels. *J Nucl Med* 1994; 35: 899–908.
- [83] Geissler F, Anderson SK, Venkatesan P, Press O. Intracellular catabolism of radiolabeled anti- μ antibodies by malignant B-cells. *Cancer Res* 1992; 52: 2907–15.
- [84] Press OW, Shan D, Howell-Clark J, *et al.* Comparative metabolism and retention of iodine-125, yttrium-90, and indium-111 radioimmunoconjugates by cancer cells. *Cancer Res* 1996; 56: 2123–9.
- [85] Sharkey RM, Behr TM, Mattes MJ, *et al.* Advantage of residualizing radiolabels for an internalizing antibody against the B-cell lymphoma antigen, CD22. *Cancer Immunol Immunother* 1997; 44: 179–88.
- [86] Brouwers AH, van Eerd JE, Frielink C, *et al.* Optimization of radioimmunotherapy of renal cell carcinoma: labeling of monoclonal antibody cG250 with ¹³¹I, ⁹⁰Y, ¹⁷⁷Lu, or ¹⁸⁶Re. *J Nucl Med* 2004; 45: 327–37.
- [87] Boerman OC, van Schaijk FG, Oyen WJ, Corstens FH. Pretargeted radioimmunotherapy of cancer: progress step by step. *J Nucl Med* 2003; 44: 400–11.
- [88] Goldenberg DM, Sharkey RM, Paganelli G, Barbet J, Chatal JF. Antibody pretargeting advances cancer radioimmunodetection and radioimmunotherapy. *J Clin Oncol* 2006; 24: 823–34.
- [89] van Schaijk FG, Oosterwijk E, Molkenboer-Kueneen JD, *et al.* Pretargeting with bispecific anti-renal cell carcinoma x anti-DTPA(In) antibody in 3 RCC models. *J Nucl Med* 2005; 46: 495–501.
- [90] Kranenborg MH, Boerman OC, Oosterwijk-Wakka JC, de Weijert MC, Corstens FH, Oosterwijk E. Two-step radioimmunotargeting of renal-cell carcinoma xenografts in nude mice with anti-renal-cell-carcinoma X anti-DTPA bispecific monoclonal antibodies. *Int J Cancer* 1998; 75: 74–80.
- [91] Liu SY, Eary JF, Petersdorf SH, *et al.* Follow-up of relapsed B-cell lymphoma patients treated with iodine-131-labeled anti-CD20 antibody and autologous stem-cell rescue. *J Clin Oncol* 1998; 16: 3270–8.
- [92] Press OW, Eary JF, Appelbaum FR, *et al.* Phase II trial of 131I-B1 (anti-CD20) antibody therapy with autologous stem cell transplantation for relapsed B cell lymphomas. *Lancet* 1995; 346: 336–40.