

The Use of Three-Column Enhanced Percutaneous Vertebroplasty to Treat Kummell's Disease

Yapu Liu, Yuanyuan Su , Yonghui Xu, Songmao Wang, Lifeng Gao, Xiaochen Zheng, Hailong Ge

Department of Spinal Surgery, Second Affiliated Hospital of Luohe Medical College, Luohe City, People's Republic of China

Correspondence: Yapu Liu, Department of Spinal Surgery, Second Affiliated Hospital of Luohe Medical College, Luohe City, People's Republic of China, Tel +86-0395-6162312, Fax +86-0395-6162312, Email 460547380@qq.com

Purpose: To describe the operative technique and clinical effects of three-column enhanced percutaneous vertebroplasty used to treat Kummell's disease.

Methods: From April 2017 to April 2020, 39 patients with Kummell's disease were treated via three-column enhanced percutaneous vertebroplasty. There were 12 males and 27 females of average age 70.23 ± 7.41 years. The operative time, volume of bone cement injected, and intraoperative cement leakage were recorded. The patients were re-examined postoperatively. The VAS was used to evaluate low back pain and the ODI score to evaluate improvement in the quality-of-life.

Results: All patients were successfully operated upon; the average operation time was 35.1 ± 4.7 min and average volume of bone cement injected 4.5 ± 0.92 mL. Five cases exhibited bone cement leakage during operation, two into the intervertebral disc and three into the anterior upper margin of the vertebral body. No leakage into the vertebral canal occurred. The average hospital stay was 2.50 ± 0.86 days. The VAS score before operation was 7.47 ± 0.24 , but low back pain symptoms were significantly relieved after operation ($P < 0.05$). The VAS scores at 1 day and 1, 3, 6, and 12 months after operation were 2.91 ± 0.09 , 2.04 ± 0.07 , 1.59 ± 0.05 , 1.28 ± 0.15 , and 0.8 ± 0.18 , respectively. The preoperative ODI score was 72.97 ± 1.45 and significantly decreased postoperatively ($P < 0.05$), being 30.08 ± 1.79 at 1 day, and 25.35 ± 0.94 , 23.19 ± 1.76 , 20.49 ± 0.65 , and 20.05 ± 0.58 at 1, 3, 6, and 12 months after operation respectively.

Conclusion: Three-column enhanced percutaneous vertebroplasty effectively treats Kummell's disease. The surgical trauma is low, recovery rapid, and bone cement fixation firm, especially in patients with stage I and II disease.

Keywords: three-column enhancement, vertebroplasty, Kummell's disease, surgical technique

Introduction

Kummell's disease is a particular type of osteoporotic fracture in older adults. The characteristic imaging manifestation is a vacuum fissure sign caused by absorption of osteonecrotic tissue of the vertebral body, with gas or liquid within, often in the central part of the anterior vertebral body.¹⁻⁴ Patients usually present with severe back pain, which compromises quality-of-life and responds poorly to conservative treatment. Surgery is required. Percutaneous vertebroplasty (PVP), percutaneous kyphoplasty (PKP), or bone graft fusion with internal fixation of a pedicle screw are usually employed.⁴⁻⁹ However, these techniques are associated with bone cement leakage, long-term bone cement loosening (or even displacement), and internal fixation surgery trauma that affects spinal mobility.^{2,3,10} As the cortex of the anterior edge of the vertebral body or the upper endplate is incomplete, the bone cement leakage rate during PVP is 34.4–79%. As the hardened bone on both sides of the vertebral fissure of Kummell's disease exerts a blocking effect, it is difficult for bone cement to enter loose trabecular bone, and cement thus cannot be used to anchor the bone, creating a free smooth-edged mass of cement in the vertebral body. This cement block does not stabilize the vertebral body, and is prone to loosening, displacement, and prolapse in the long term.²⁻⁴ A typical case is described in Figure 1.

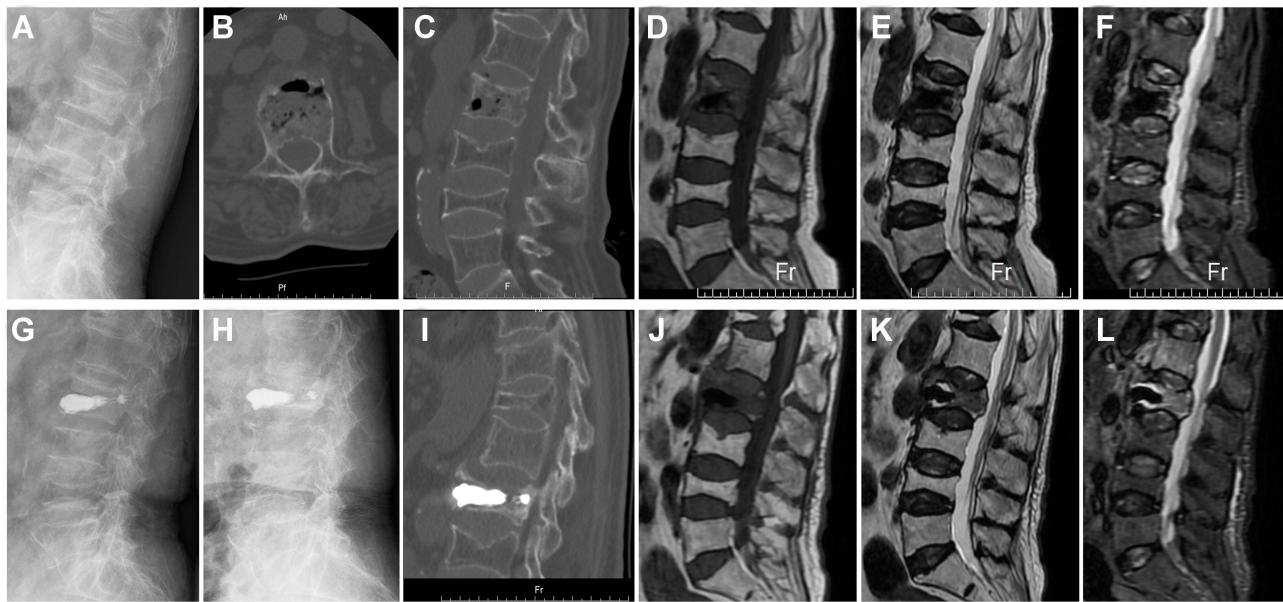


Figure 1 Bone cement loosening and displacement after traditional PVP in a patient with Kummell's disease. A female 82 years of age complained of "low back pain and discomfort for 2 months". (A) The preoperative lateral X-ray suggested a reduction in the height of the L2 vertebral body. (B and C) Preoperative CT revealed dehiscence of the anterior middle region of vertebra L2 and formation of a vacuum fissure within the vertebra. (D–F) Preoperative magnetic resonance imaging (MRI) confirmed that the L2 vertebral body was a fresh fracture. Also, the vacuum fissure in the vertebral body evidenced a fluid signal. (G) An X-ray taken on the first day after surgery showed that the bone cement filled the fissure in the middle of the anterior vertebral body, and that the vertebral body height was good. (H and I) Three months after operation, an X-ray and CT showed that the height of the L2 vertebral body was obviously less, and the vertebral body cement appeared to be displaced forward. (J–L) Three months postoperatively, MRI revealed a liquid signal around the bone cement.

Previous studies have described good clinical outcomes after three-column enhanced PVP to treat Kummell's disease.⁴ Here, we retrospectively analyze 39 such patients who underwent three-column enhanced PVP from April 2017 to April 2020. We (1) summarize the clinical efficacy; and, (2) discuss the operative details, precautions, and indications for treatment.

Methods

General Information

A total of 39 patients diagnosed with Kummell's disease via imaging from April 2017 to April 2020 underwent three-column enhanced PVP under local anesthesia. There were 12 males and 27 females aged from 58 to 86 years (average 70.23 ± 7.41 years). The preoperative, bone mineral density T-score measured via dual-energy X-ray absorption ranged from -2.5 to -5.5 (average -3.55 ± 0.52). The fracture sites were: T9 1, T10 1, T11 9, T12 14, L1 11, and L2 3. After being educated about the procedure, all patients signed an informed consent form authorized by our local ethics committee.

Inclusion and Exclusion Criteria

Inclusion criteria: (1) Minor trauma (fall or strain) followed by pain that worsens with postural changes, lasts for at least 4 weeks on average, and leads to kyphosis; (2) MRI, CT, and X-ray scan showing typical "vertebral body vacuum fissure" sign or effusion, with the posterior wall of the body was intact; (3) age > 55 years and a bone mineral density T value ≤ -2.5 ; and, (4) no obvious nerve or spinal cord compression or injury.

Exclusion criteria: (1) Symptoms of nerve injury; (2) a malignant tumor, an infection, metabolic bone disease, or a coagulation dysfunction; and, (3) severe compression of the vertebral body rendering puncture impossible.

Surgical methods

All patients were operated upon under local anesthesia and their vital signs were monitored. Each was placed prone on a soft pillow in the chest and iliac region and the abdomen was suspended. The fracture was reduced in the

hyperextension position. C-arm fluoroscopy was used to locate injured vertebrae and pedicles. The medial edges of the upper and outer pedicle projection of the injured vertebra served as the puncture points, and the needles were slowly rotated during entry. When a tip attained the medial 1/3 of the pedicular anteroposterior projection, insertion ceased. The contralateral pedicle was punctured in the same manner. The lateral fluoroscopic view showed that the tip had attained the posterior edge of the vertebral body, and confirmed that the needle had not entered the spinal canal. The needle was very slowly advanced along the direction of the original puncture; this ceased when the tip attained the anterior 1/3 of the vertebral body (as revealed by lateral fluoroscopy). Orthopedic fluoroscopy showed that the tip lay between the medial side of the vertebral pedicle and the spinous process. The needle core was pulled out, and a 10-mL syringe connected to the end of the puncture trocar (to remove the effusion from the vertebral body). Unformed bone cement and coagulant were simultaneously (and slowly) injected on both sides during the removal period. When the vertebral body fissure was satisfactorily filled and cement diffusion into the injured vertebra adequate, the puncture needle was slowly retracted (stepwise) to the anterior edge of the vertebral pedicle. The bone cement was pushed in slowly while the puncture needle was being withdrawn; injection ceased when the posterior edge of the pedicle was attained. The bone cement was cut off by sliding it in all directions at the edge of the puncture trocar. This ensured that no cement remained in subcutaneous soft tissue when the puncture trocar was pulled out. After the puncture needle was removed, the cement distribution in the vertebral body and pedicle was again confirmed to be satisfactory, thus reinforcing the three columns. The absence of cement from subcutaneous tissue was confirmed. The puncture site was covered with a sterile dressing. After the cement was completely set, each patient was turned over and the vital signs checked prior to return to the ward. The puncture was strictly intrapedicle; this route only was used to place cement in the vertebral body. During puncture and cement injection, lower limb sensory and motor functions were closely monitored to ensure the absence of spinal cord injury or compression.

Postoperative Management

An X-ray was obtained and CT performed 12–24 h after surgery. The patient was discharged after confirming the appropriate cement location and ensuring that the patient was able to comfortably get out of bed wearing the waist. Calcium, vitamin D3, vitamin K2, bisphosphonates, and other drugs were added to the regular anti-osteoporosis treatments.

Observational Indicators

The operative time, volume of bone cement injected, and intraoperative cement leakage were recorded. The patients were re-examined at 1 day; and at 1, 3, 6, and 12 months postoperatively. A visual analog scale (VAS, 0: no pain at all; 10: worst pain imaginable) was used to evaluate the extent of low back pain.⁴ The Oswestry Disability Index (ODI) (0%: best functional state; 100%: worst functional state) score was used to evaluate improvement in quality of life.⁷

Statistical Analysis

SPSS ver. 21.0 statistical software was used for all analysis. Data are expressed as means \pm standard deviations. One-way analysis of variance was employed to perform the paired-samples *t*-test. $P < 0.05$ was taken to indicate a statistically significant difference.

Results

Clinical Results

All 39 patients were successfully operated upon. The postoperative X-ray and CT confirmed that the cement was well-positioned; the mean operative time was 35.1 ± 4.7 min (range 25–45 min). The average volume of cement injected was 4.5 ± 0.92 mL (range 3.5 to 6 mL). There was very little intraoperative blood loss. Intraoperative cement leakage occurred in five cases (12.8%). In two patients, cement infiltrated the intervertebral disc and, in three cases, cement entered the anterior and upper vertebral margins. No leakage into the vertebral canal was noted. There was no serious complication (great vessel or spinal cord injury). The mean hospital stay was 2.50 ± 0.86 days (range 2 to 4 days). A typical case is described in [Figure 2](#).

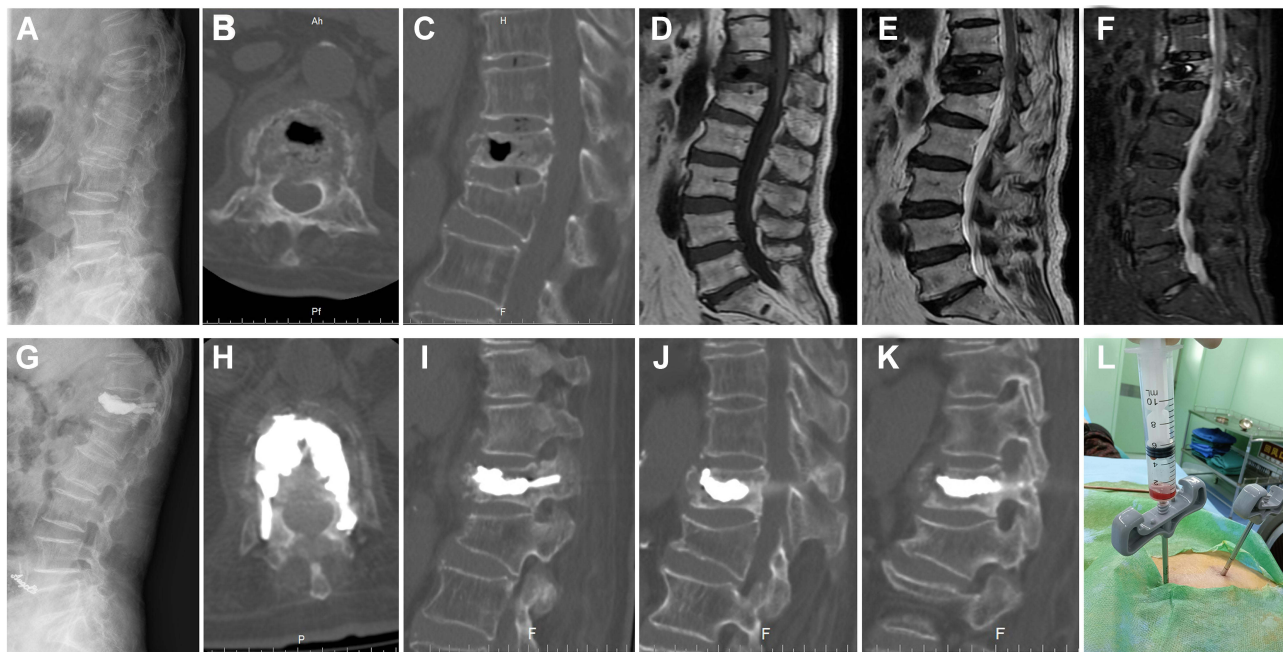

Figure 2 Treatment of Kummell's disease via three-column enhanced PVP. A female aged 85 years complained of "low back pain and discomfort for 2 months". **(A)** The preoperative lateral X-ray suggested a reduction in the height of the T12 vertebral body. **(B and C)** Preoperative CT revealed dehiscence of the anterior middle region of vertebra T12 and formation of a vacuum fissure within the vertebra. **(D–F)** Preoperative MRI confirmed that the T12 vertebral body was a fresh fracture. Also, the vacuum fissure in the vertebral body evidenced a fluid signal. **(G)** The patient underwent three-column, enhanced PVP. An X-ray taken on the first day after surgery revealed that the bone cement was evenly distributed in the vertebral body and the pedicle. **(H)** A postoperative plain cross-sectional CT scan showed that the bone cement was evenly distributed in the vertebral body and bilateral pedicle, without leakage into the vertebral canal. **(I–K)** A postoperative plain sagittal CT scan showed that the bone cement was evenly distributed in the vertebral body and bilateral pedicle. **(L)** A light-red clear liquid was drawn from the vertebral fissure during the operation.

Follow-Up

All symptoms improved significantly after operation. Low back pain was alleviated; the VAS scores were 2.91 ± 0.09 , 2.04 ± 0.07 , 1.59 ± 0.05 , 1.28 ± 0.15 , and 0.98 ± 0.18 at 1 day; and 1, 3, 6, and 12 months after operation respectively. All were significantly better than the 7.47 ± 0.24 score before surgery ($P < 0.05$) (Figure 3A). The ODI scores at 1 day; and 1, 3, 6, and 12 months after surgery were 30.08 ± 1.79 , 25.35 ± 0.94 , 23.19 ± 1.76 , 20.49 ± 0.65 , and 20.05 ± 0.58 ; all significantly better than the preoperative score of 72.97 ± 1.45 ($P < 0.05$) (Figure 3B).

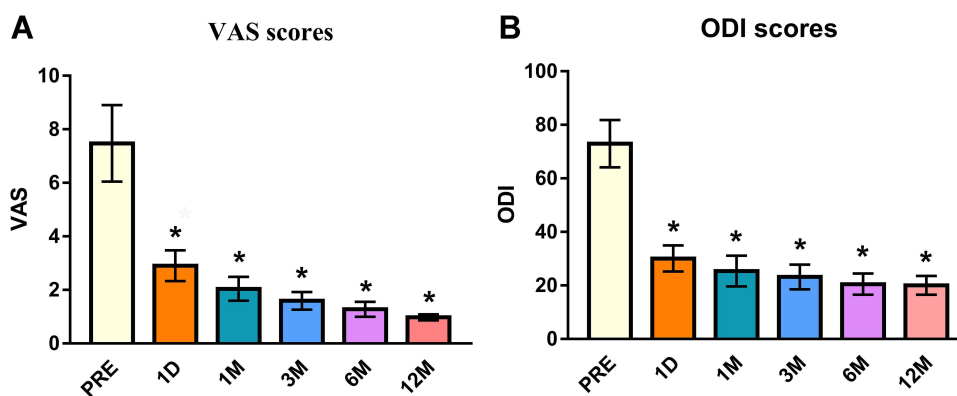


Figure 3 The VAS and ODI scores. **(A)** The VAS scores at 1 day; and 1, 3, 6 and 12 months after surgery were significantly better than those before surgery. **(B)** The ODI scores at 1 day; and 1, 3, 6 and 12 months after surgery were significantly better than those before surgery. * $P < 0.05$ compared to the preoperative scores.

Discussion

We used three-column enhanced PVP to treat Kummell's disease. We modified the traditional method of injecting bone cement directly into the vertebral fissure: we used the three column stages of the injured vertebra to slowly inject bone cement; this enhanced three-column fixation of the vertebral body and the pedicle. The cement not only diffused well in the vertebral body but also in the bilateral pedicle, strongly anchoring the injured vertebral body and reducing the long-term risk of cement loosening, displacement, and prolapse.

Technical Points

The Puncture Point

Using C-arm fluoroscopic positioning, select the inner sides of the outer upper edges of the pedicle projection as the puncture points. The inner edge of the left pedicle at 9 o'clock is a puncture point, as is the inner edge of the right pedicle at 3 o'clock.⁷

Anesthesia

Patients with Kummell's disease tend to be older with underlying diseases. All patients completed surgery under local anesthesia (1% (w/v) lidocaine hydrochloride injections around the puncture site). The anesthetists were prepared to give midazolam sedation and propofol analgesia; this was not necessary. Vital signs were monitored throughout.

Puncture Route

After puncture, rotate the needle slowly and avoid excessive abduction. When the needle tip attains the inner 1/3 of the anterior pedicle projection, pause. The tip should have attained or passed the posterior edge of the vertebral body, and the puncture path at this time runs entirely through the bony structure of the vertebral pedicle. Creation of this channel prevents later cement leakage. Continue to rotate the needle along the original puncture direction until lateral fluoroscopy reveals that the needle tip has attained the anterior 1/3 of the vertebral body. Stop the puncture then. Frontal fluoroscopy should reveal that the needle tip lies between the inner edge of the pedicle and the outer edge of the spinous process.

Remove the Vertebral Body Effusion

After absorption of osteonecrotic tissue in the vertebral body, the vacuum fissure sign forms, and the fissure contains fluid.³ When puncture ceases, pull out the needle and connect the end of the puncture cannula to a 10-mL syringe to remove the vertebral body fluid, which now cannot affect later cement dispersion and distribution.

Push Bone Cement into the Vertebra

Evenly mix bone cement and coagulant. When the cement enters the drawing phase, slowly inject the puncture sleeves (both sides) under continuous fluoroscopy and withdraw the puncture sleeves.⁴ At this time, if a small amount of cement leaks out of the vertebral body, bolus injection should be suspended. Under continuous fluoroscopy, slowly pull back the puncture sleeve, and gradually push it in again when the cement becomes more viscous and injection resistance increases. This will reduce leakage.

Intrapedicular Cement Injection

When the vertebral body fissure is filled and cement diffusion within the vertebra is satisfactory, move the puncture needle slowly backward into the vertebral pedicle while slowly injecting cement. Monitor the sensory and motor status of the lower limbs. At this point, the cement should be linearly distributed along the puncture direction. Stop injecting when the posterior edge of the pedicle is attained. If the cement exhibits obvious diffusion to the top or bottom of the pedicle, the possibility of leakage into or out of the pedicle should be considered and injection should cease. Use the edge of the puncture cannula to slide and cut the cement in all directions to ensure that no cement remains in the subcutaneous tissue.

After the needle is removed, re-confirm that the cement distribution in the vertebral body and pedicle is satisfactory, and that enhanced three-pillar fixation is apparent. Re-confirm the absence of cement in subcutaneous tissue.

Advantages of the Three-Column Enhanced PVP Technology

The three-column enhanced PVP technique with solid cement fixation reduces the risks of cement loosening, displacement, and prolapse that are not uncommon after traditional PVP and PKP.¹ The extent of trauma is low, recovery rapid, nursing easy, and the cost low. There is no need for bone graft fusion via pedicle screw internal fixation. The alternative techniques are associated with considerable trauma, effects on spinal activity and other conditions, inconvenient nursing, and high cost.^{8,9,11}

Disadvantages of the Three-Column Enhanced PVP Technology

Given the rapid solidification of cement *in vivo*, the several operative steps, and the narrow time window, constant fluoroscopy is required during cement injection. As cement is injected, the puncture sleeve is pushed back, increasing the radiation dose to the operator and patient. If injection is too slow, pedicle strengthening may not be achieved before the cement sets. The three-column enhancement technique requires very high-quality puncture and injection, and must be performed by a surgeon experienced in percutaneous puncture vertebroplasty. Inexperienced surgeons should not use the technique.⁴

Complications of the Three-Column Strengthening Technique and Their Prevention

Leakage of Bone Cement Outside the Vertebral Body

Most sites of extracorporeal vertebral leakage develop at the anterior edge of the vertebral body in the direction of the upper endplate. When the cement enters the wire drawing stage, some cement is slowly pushed to both sides under continuous fluoroscopy.⁴ Early cement injection is associated with good dispersion, anchoring the fracture end and sealing the fracture gap. Under continuous fluoroscopy, the puncture sleeve is slowly pushed back. As the cement gradually thickens, the injection resistance increases and the sleeve is gradually pushed back into the vertebral body. Slow, staged, and fluoroscopically guided downthrust injection reduces the risk of cement leakage from the vertebral body.

Bone Cement Leakage into the Spinal Canal

Preoperative CT of the vertebral body was performed to confirm that the bony structure of the pedicle was intact. During operation, the bone of the vertebral pedicle was meticulously punctured, establishing a channel to prevent later leakage of bone cement. Excessive abduction should be avoided after needle insertion at the puncture point. When the tip attains the medial 1/3 of the pedicular anteroposterior projection, lateral fluoroscopy is performed to confirm that the tip has reached or crossed the posterior edge of the vertebral body. If significant cement is dispersed on and/or below the bony pathway of the pedicle puncture, the possibility of leakage into or out of the pedicle should be considered and injection should be terminated.

Indications for the Three-Column Enhancement Technique

Patients with Kummell's disease of pathological stages I and II may be treated using this procedure. Stage III patients exhibit severe collapse of the vertebral body posterior wall, resulting in compression of the spinal cord or nerve roots. The procedure is not then recommended; patients can be treated via decompression and internal fixation.^{10,12} The three-column enhanced PVP technique is not recommended for patients with common osteoporotic vertebral compression fractures.

Conclusion

In conclusion, three-column enhanced PVP treatment of Kummell's disease is characterized by less surgical trauma and faster recovery than other methods, and firm fixation with bone cement. The method reduces the risk of cement

loosening, displacement, and prolapse after traditional PVP and PKP, and can be used to treat Kummell's disease effectively, especially patients of pathological stages I and II. However, there is a risk of bone cement leakage into the spinal canal. To avoid cement leakage from the pedicle, transpedicular puncture must be meticulously performed when establishing a bone puncture channel.

Ethics Approval and Consent to Participate

This study was conducted in agreement with the Ethics Committee of Second Affiliated Hospital of Luohe Medical College. All participants had provided a written informed consent. This study follows the Declaration of Helsinki, as well as local and national regulations.

Acknowledgments

The authors thank patients and their families for their participation in the study, and colleagues such as LP, HXW, and WGL for their feedback on the study.

Author Contributions

All authors made a significant contribution to the work reported, whether that is in the conception, study design, execution, acquisition of data, analysis and interpretation, or in all these areas; took part in drafting, revising or critically reviewing the article; gave final approval of the version to be published; have agreed on the journal to which the article has been submitted; and agree to be accountable for all aspects of the work.

Funding

This work was supported by Key Scientific Research Projects of Universities in Henan Province (21B320004), Joint Co-construction Project of Henan Medical Science and Technology Research Plan (LHGJ20200887), Luohe Youth Talents Fund of China (2018QNBjRC01004), and Luohe Medical College Innovation and Entrepreneurship Promotion Project (2019-LYZKYZD004 & 2019-LYZKYB016).

Disclosure

The authors declare that they have no conflicts of interest in this work.

References

1. Wang W, Liu Q, Liu WJ, Li QB, Cai L, Wang Z-K. Different performance of intravertebral vacuum clefts in kummell's disease and relevant treatment strategies. *Orthop Surg.* 2020;12(1):199–209. doi:10.1111/os.12609
2. Zhang C, Wang G, Liu X, Li Y, Sun J. Failed percutaneous kyphoplasty in treatment of stage 3 Kummell disease: a case report and literature review. *Medicine.* 2017;96(47):e8895. doi:10.1097/MD.00000000000008895
3. Kim JE, Choi SS, Lee MK, Lee DK, Cho SI. Failed percutaneous vertebroplasty due to insufficient correction of intravertebral instability in Kummell's disease: a case report. *Pain Pract.* 2017;17(8):1109–1114. doi:10.1111/papr.12561
4. Park JW, Park JH, Jeon HJ, Lee JY, Cho BM, Park SH. Kummell's disease treated with percutaneous vertebroplasty: minimum 1 year follow-up. *Korean J Neurotrauma.* 2017;13(2):119–123. doi:10.13004/kjnt.2017.13.2.119
5. Kim P, Kim SW. Balloon kyphoplasty: an effective treatment for kummell disease? *Korean J Spine.* 2016;13(3):102–106. doi:10.14245/kjs.2016.13.3.102
6. Li H-K, Hao D-J, Yang J-S, et al. Percutaneous kyphoplasty versus posterior spinal fixation with vertebroplasty for treatment of Kummell disease. *Medicine.* 2017;96(51):e9287. doi:10.1097/MD.00000000000009287
7. Wu XF, Ping Y, Zeng XQ, et al. Percutaneous vertebroplasty with side-opening cannula or front-opening cannula in the treatment of kummell disease? *Orthop Surg.* 2020;12(4):1190–1198.
8. Mei L, Sang W, Chen Z, et al. Titanium mesh bone grafting combined with pedicle screw internal fixation for treatment of Ku[Combining Diaeresis]mmell disease with cord compression: a case report and literature review. *Medicine.* 2018;97(36):e12183.
9. Yang DL, Yang SD, Chen Q, Shen Y, Ding WY. The treatment evaluation for osteoporotic kummell disease by modified posterior vertebral column resection: minimum of one-year follow-up. *Med Sci Monit.* 2017;23:606–612.
10. Wang H, Ding W. Posterior vertebral column resection through unilateral osteotomy approach for old lumbar fracture combined with kummell disease. *World Neurosurg.* 2018;109:147–151. doi:10.1016/j.wneu.2017.09.148
11. Lee SH, Jain V, Lee S-H, Baek OK, Moon K-H. Transpedicular intrabody cage insertion with posterior spine stabilization in Kummell disease: report of 2 cases. *World Neurosurg.* 2018;116:236–240. doi:10.1016/j.wneu.2018.05.133
12. Cho Y. Posterior vertectomy and circumferential fusion for the treatment of advanced thoracolumbar Kummell disease with neurologic deficit. *Asian Spine J.* 2017;11(4):634–640. doi:10.4184/asj.2017.11.4.634

Journal of Pain Research

Dovepress

Publish your work in this journal

The Journal of Pain Research is an international, peer reviewed, open access, online journal that welcomes laboratory and clinical findings in the fields of pain research and the prevention and management of pain. Original research, reviews, symposium reports, hypothesis formation and commentaries are all considered for publication. The manuscript management system is completely online and includes a very quick and fair peer-review system, which is all easy to use. Visit <http://www.dovepress.com/testimonials.php> to read real quotes from published authors.

Submit your manuscript here: <https://www.dovepress.com/journal-of-pain-research-journal>