

Diaphragmatic palsy after cardiac surgical procedures in patients with congenital heart

Sachin Talwar, Sandeep Agarwala, Chander Mohan Mittal, Shiv Kumar Choudhary, Balram Airan

Cardiothoracic Centre and Department of Pediatric Surgery, All India Institute of Medical Sciences, New Delhi, India

ABSTRACT

Paralysis of diaphragm on one or, exceptionally, both sides is a common cause of delayed recovery and excessive morbidity following pediatric cardiac surgery. The consequences of this complication after all forms of congenital heart surgery in newborns and young infants can be potentially serious. The impact of diaphragmatic palsy on the physiology after single ventricle palliations is particularly significant. It is necessary for all professionals taking care of children with heart disease to be familiar with the etiology, diagnosis, and management of this condition. Early recognition and prompt management of diaphragmatic palsy can potentially reduce the duration of mechanical ventilation and intensive care in those who develop this complication. This review summarizes the anatomy of the phrenic nerves, reasons behind the occurrence of diaphragmatic palsy, and suggests practical guidelines for management.

Keywords: Diaphragm, paralysis, phrenic nerve

DOI: 10.4103/0974-2069.64370

INTRODUCTION

Diaphragm is a musculo-fibrous sheet that separates the abdominal and thoracic cavities. It has two components: peripheral muscular arising from chest wall and the upper lumbar vertebrae and a central fibrous body. It has an important respiratory function and acts as a main muscle for inspiration. It is innervated by the phrenic nerve that may be injured during various cardiac surgical procedures leading to unilateral or bilateral diaphragmatic paralysis. In this review, we briefly review the anatomy of the phrenic nerve and discuss the incidence, pathophysiology, clinical presentation, and management of this common problem.

RELATED ANATOMY

The diaphragm is innervated by the phrenic nerve that arises chiefly from the fourth cervical ventral ramus, but also has contributions from the third and fifth rami. It is formed at the upper part of the lateral border of scalenus anterior and descends vertically across its anterior surface behind prevertebral fascia. It descends posterior to sternocleidomastoid, inferior belly of omohyoid, the internal jugular vein, transverse cervical and suprascapular arteries and on the left, the thoracic duct [Figures 1 and 2]. The phrenic nerve enters the

thorax by crossing medially in front of the internal mammary artery.^[1] Within the thorax, the phrenic nerve descends anteriorly to pulmonary hilum, between the fibrous pericardium and mediastinal pleura, to the diaphragm accompanied by pericardiophrenic vessels. The right phrenic nerve is shorter and more vertical. It descends lateral to the right brachiocephalic vein, the superior vena cava [Figure 1], and the fibrous pericardium that covers the right surface of the right atrium and inferior vena cava. The left phrenic nerve crosses anterior to the left internal thoracic artery, descending across the medial aspect of the apex of the left lung and its pleura to the first part of subclavian artery, where it crosses obliquely to reach the groove between the left common carotid and subclavian arteries. It passes anteromedially, superficial to the left vagus nerve just above the aortic arch and behind the left brachiocephalic vein, and then passes superficial to the aortic arch and the left superior intercostal vein, anterior to the left pulmonary hilum, to lie between the fibrous pericardium covering the surface of the left ventricle and the mediastinal pleura [Figure 2].^[2]

INJURY TO PHRENIC NERVE

The phrenic nerve may be injured by the ice cold slush used for myocardial protection. Because of its course on

Address for correspondence: Dr. Sachin Talwar, Cardiothoracic Centre, All India Institute of Medical Sciences, New Delhi-110029, India.

E-mail: sachintalwar@hotmail.com

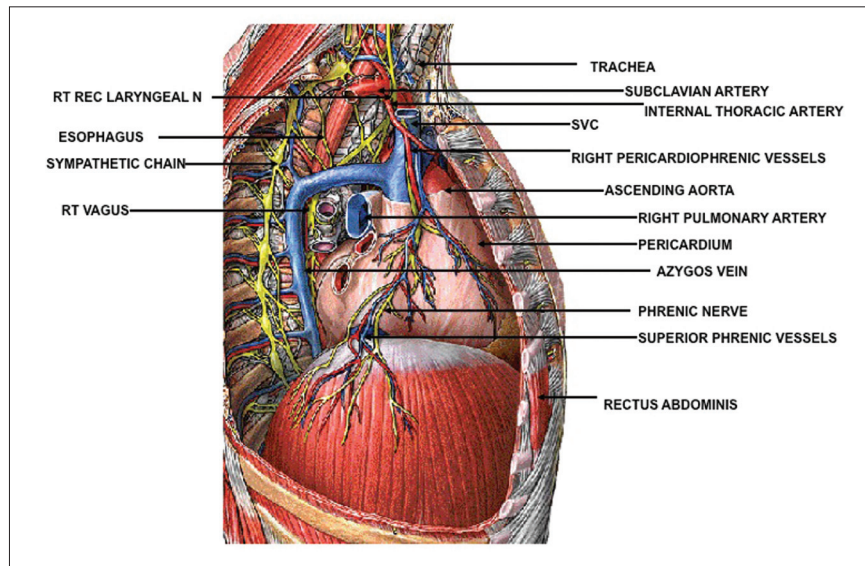


Figure 1: Anatomy and relations of right phrenic nerve. For details, see the text. N: Nerve, REC: Recurrent, RT: Right, SVC: Superior venacava

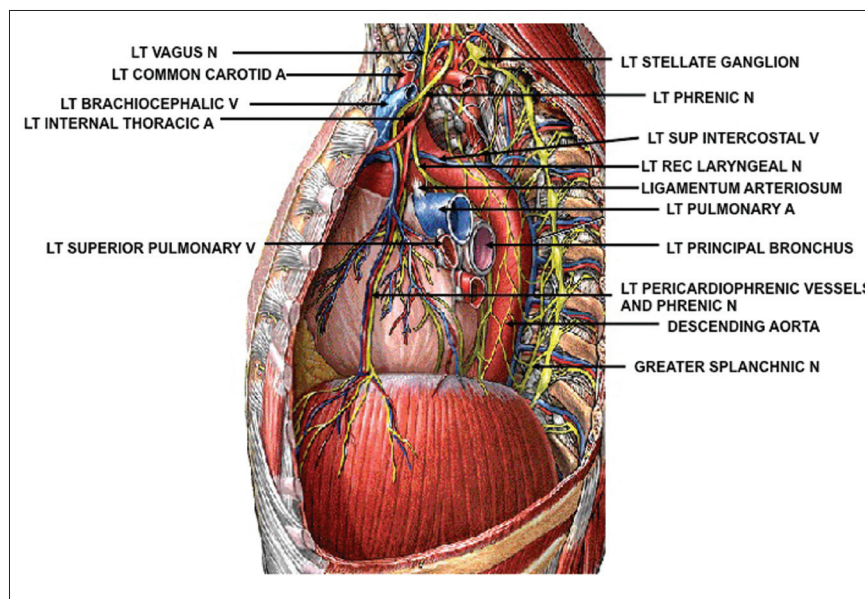


Figure 2: Anatomy and relations of left phrenic nerve. For details, see the text. A: Artery, LT: Left, N: Nerve, V: Vein

the left side, ice slush injury is more likely on the left, although there may be bilateral involvement. Dissecting near the area of internal thoracic artery pedicle in adults can cause its damage. The left phrenic nerve may get damaged while removing thymus on the left side or during the dissection of the vertical vein in patients undergoing repair of total anomalous pulmonary venous return. The phrenic nerve may be severed while dissecting or it may be injured due to conducted heat while dissecting in area near to its course. This is particularly likely to happen on the right side when the superior vena cava is being dissected and mobilized. At

re-operations, the lung is often adherent to the cardiac chambers, and during dissection, to separate the heart and lungs, the phrenic nerve may get accidentally damaged. Rarely, it may be injured during placement of a subclavian or jugular vein catheter or a pacing lead. During pericardiectomy for constrictive pericarditis, it is common to accidentally sever the phrenic nerve on one or both the sides.

INCIDENCE

Cardiovascular surgery is the most common cause of

acquired diaphragmatic palsy (DP) and accounts for about 64% of phrenic nerve injuries.^[3] Various studies of the etiology of DP in children have addressed the incidence of this complication following heart surgery and have reported it to range from 0.28 to 5.6%.^[4-14] Table 1. The incidence is particularly high after the bidirectional Glenn or Fontan operation, systemic to pulmonary artery shunts particularly the classic or modified Blalock-Taussig (BT) shunt, ventricular septal defect closure, surgery for tetralogy of Fallot, and arterial switch operation. Akay^[6] reported a high incidence of DP following correction of tetralogy of Fallot (31.5%), BT shunt (11.1%), and VSD closure with pulmonary artery patch plasty (11.1%). The incidence of DP requiring diaphragmatic plication was higher following BT shunt (23.8%), arterial switch operation (19%), and correction of tetralogy of Fallot (11.9%).^[6] Joho-areola *et al.*^[7] also reported a higher incidence of DP after arterial switch operation (10.8%), Fontan procedure (17.6%), and BT Shunt (12.8%). Watanabe *et al.*^[13] found the incidence of DP to be 6.7% after the Mustard procedure, 5.6% after right ventricular outflow tract reconstruction, and 2.7% following repair of tetralogy of Fallot; in patients undergoing closed heart procedures, it was 6.2% following the Glenn anastomosis, 5.9% following Blalock-Hanlon atrial septectomy, and 5.1% following the right BT shunt.

CLINICAL FEATURES AND DIAGNOSIS

Unilateral DP reduces pulmonary function by about 25% in older children and is usually well tolerated; however, it causes severe respiratory embarrassment in infants and young children.^[15,16] This is because neonates and infants are diaphragmatic breathers with intercostal muscles playing a little or no role in respiration. Bilateral DP is more sinister as it can reduce the respiratory function by up to 60% resulting in failure to wean from ventilator support. Even if the patient is extubated, it increases chances of atelectasis, pneumonia, and lung collapse.^[17]

EFFECTS OF DP IN PATIENTS UNDERGOING UNIVENTRICULAR REPAIR

Diaphragmatic palsy has a significantly unfavorable impact on the early and late post-operative course of patients undergoing univentricular repair and this has prompted us to discuss this issue separately. After univentricular repair, the systemic venous return enters the pulmonary arteries without the aid of a right-sided pump. Therefore, the flow in the pulmonary circulation is non-pulsatile. In normal biventricular circulation, the normal pulsatile flow is responsible for keeping the distal pulmonary vasculature patent. Loss of this pulsatility following univentricular repair effectively increases the afterload because of elevation of pulmonary arterial impedance. In addition after univentricular repair, the systemic and pulmonary venous circulations are in series and this adds further resistance to the systemic venous return. These problems are further compounded by the transient ventricular dysfunction that is common in these patients and the heightened gravitational variation. All these factors put together impede the systemic venous return. In such a situation, the negative intrathoracic pressure generated by a normally functioning diaphragm assumes significance in ensuring optimal systemic venous and pulmonary arterial circulation. In the presence of DP, these patients have higher Fontan pressures, resulting in a significant increase in morbidity, including pleural effusions, ascites, duration of hospital stay, and need for readmission [Figure 3a]. These are likely to improve with early diaphragmatic plication as has been demonstrated in previous studies [Figure 3b].^[18,19]

The diagnosis of DP should be considered whenever there is persistent atelectasis, paradoxical breathing, or inability to wean from ventilation. The clinical diagnosis is nearly impossible because of the presence of intercostal drainage tubes particularly in patients on positive pressure mechanical ventilation. In patients who are not on positive pressure ventilation, simple inspection may reveal paradoxical breathing and optical markers can be used to amplify this paradoxical movement. Inspiratory

Table 1: Studies on the incidence of diaphragmatic palsy

Author	Year	Total number	No. with DP	Incidence (%)	Study period (Years)	Time to plication (days)	Time to extubation (days)
Dagan ^[4]	2006	3214	9	0.28	10	*	*
Lemme ^[5]	2006	5128	74	1.4	14	*	*
Akay ^[6]	2006	3071	152	4.9	10	12	
Joho Arreola ^[7]	2005	802	43	5.4	6	21	5
Van Onna ^[8]	1998	867	17	1.9	5	5	4
Vazquez ^[9]	1996	556	13	2.3	5	*	*
Tonz ^[10]	1996	1656	25	1.5	-	15-110	3
Picardo ^[11]	1996	3400	25	0.73	-	*	*
Serraf ^[12]	1989	9149	109	1.2	10	18	3
Watanabe ^[13]	1986	7670	125	1.6	12	14	2
Mickell ^[14]	1978	1891	32	1.7	8	*	*

*Data not available, DP: Diaphragmatic palsy

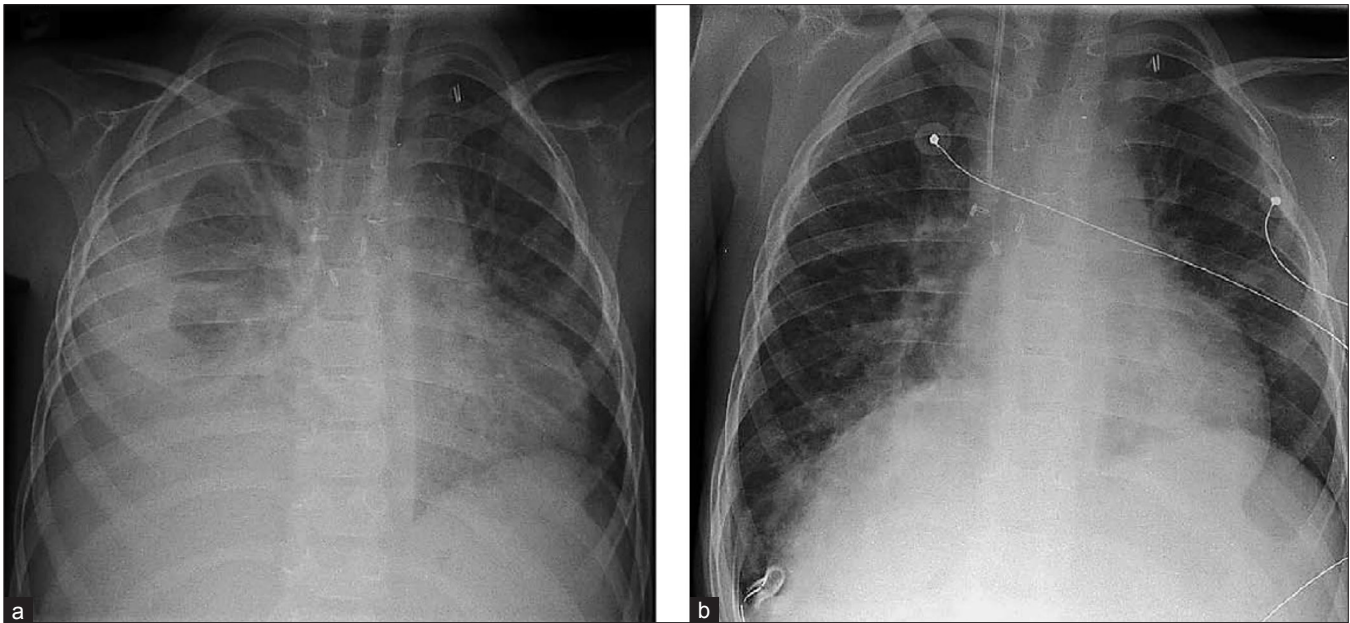


Figure 3: (a) Right-sided phrenic nerve paralysis in a 4.2-year-old boy with chronic ascites and pleural effusions 1 year after extracardiac conduit Fontan operation. The mean pulmonary artery pressure 9 months after surgery was 13 mmHg. (b) Significant augmentation of the lung volume on the affected side after diaphragm plication. Disappearance of ascites and effusions was observed within the following weeks. (Reproduced with permission from [19].)

indrawing of the lateral chest (Hoover's sign) is typical of infants with diaphragmatic paralysis.

DP should be suspected with progressive elevation of a hemidiaphragm on serial chest radiographs [Figure 4], but this sign can be inconsistent on mechanical ventilation. Diagnosis is confirmed in suspected cases by the use of bedside echocardiography (ultrasonography) or fluoroscopy while the patient is breathing spontaneously without any positive pressure ventilatory support (Kienbock's sign). On echocardiography, DP may be identified as paradoxical movement of the diaphragm with respiration [Figures 5 and 6]. A paralyzed diaphragm may appear atrophic, with less contraction and shortening on inspiration than occurs in the normal diaphragm. On fluoroscopy, the diagnosis is established by the "sniff test" in a spontaneously breathing patient; when a patient is observed fluoroscopically while sniffing, the affected diaphragm will move paradoxically upward due to negative intra-thoracic pressure. Both the modalities have been shown to be equally useful with sensitivity of 100% and specificity of 74% and 81% for fluoroscopy and echocardiography, respectively.^[16] However, the gold standard for assessment of the phrenic nerve/diaphragm unit is electrical or magnetic stimulation of the phrenic nerve with recordings of the compound muscle action potential [Figure 7] and/or the transdiaphragmatic pressure.^[20] Transdiaphragmatic pressure is measured by placing an esophageal catheter with an esophageal balloon and a gastric balloon. The difference between the pressures measured at the two balloons is the transdiaphragmatic pressure. Patients

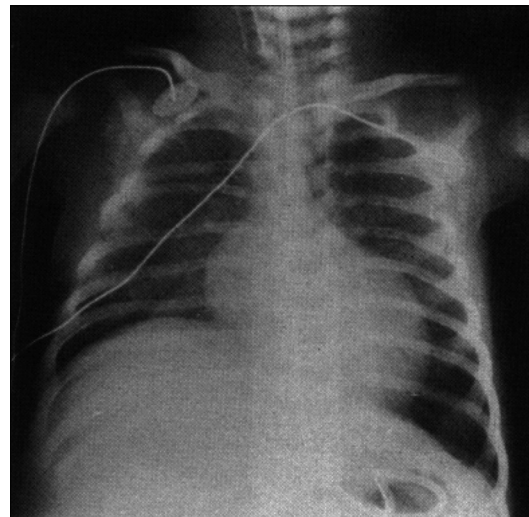


Figure 4: Chest X-ray showing raised hemidiaphragm on the right side suggestive of right-sided phrenic nerve injury. (Reproduced with permission from [29].)

with diaphragmatic dysfunction and paralysis have a decrease in transdiaphragmatic pressures.

MANAGEMENT

The management of the phrenic nerve injury leading to diaphragmatic paralysis mainly harbors around preservation of respiratory function. Optimal management of phrenic nerve palsy (PNP) in children who have undergone cardiac surgery remains controversial and consists of prolonged ventilation or diaphragmatic

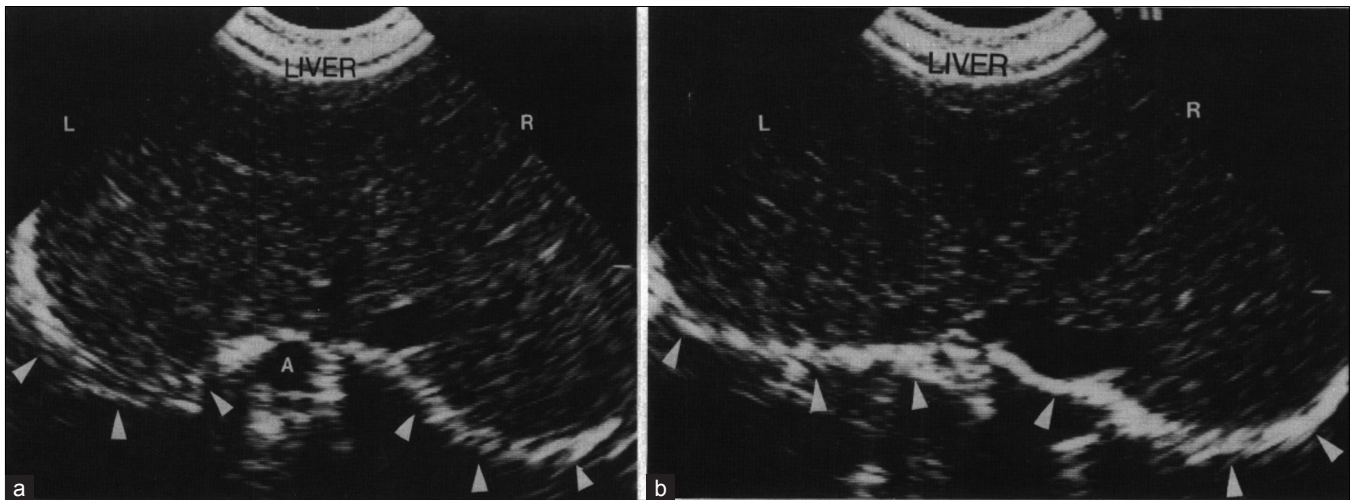


Figure 5: Subcostal view of the two hemidiaphragms (arrowheads) in (a) expiration and (b) inspiration. Note that both hemidiaphragms have moved downwards (closer to the transducer) and appear flatter. A, aorta. (Reproduced with permission from [30].)

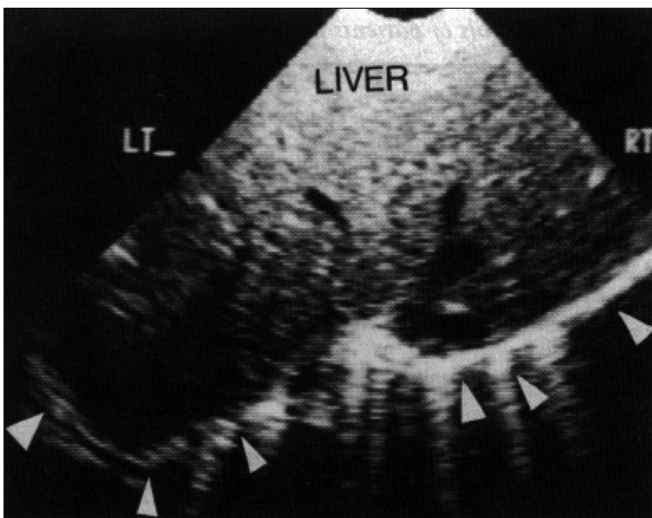


Figure 6: Subcostal view from a patient with paralyzed left hemidiaphragm. The right hemidiaphragm has contracted and flat, while the left side has moved upwards---there is paradoxical motion away from the transducer. (Reproduced with permission from [30].)

plication. A guideline is suggested in Figure 8. The patients are kept on mechanical ventilatory support and tracheostomy may be required. Haller *et al.* suggested a trial of continuous positive airway pressure (CPAP) for 4–6 weeks during which the diaphragmatic function is presumed to improve with conservative management.^[21] A major difficulty with this approach is that the natural history of PNP following cardiac surgery is unknown. With the conservative approach, Watanabe *et al.*^[13] reported recovery of the affected diaphragm between 5 and 51 days indicating that recovery is an unpredictable phenomenon. Further follow-up suggested that 16% never recovered. Iverson^[22] showed that in many cases of traumatic injury to the phrenic nerve, normal diaphragmatic function could be expected to return after 6–12 months. Mickell^[14] noted radiographic or

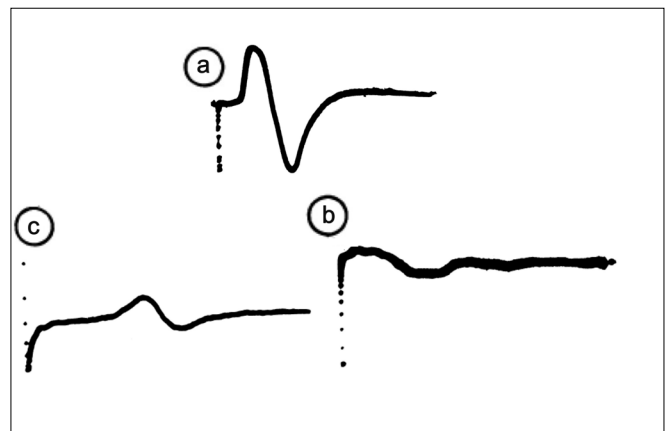


Figure 7: Typical electromyograms obtained on testing the phrenic nerve: (a) normal response (b) delayed response (c) no response (Reproduced with permission from [29].)

fluoroscopic resolution of PNP in 95% of children up to 3.5 years after operation. Our institutional policy is to follow the guidelines suggested in [Figure 8]. However, in patients undergoing univentricular repair, we would elect to perform early diaphragmatic plication to prevent significant morbidity as discussed above.

The definitive surgical option in patients with DP is plication of diaphragm. The decision of plication should be based on the respiratory status of the patient.^[23] In earlier years, the use of mechanical ventilation was the favored option. However, in the current era, surgical plication is the widely accepted treatment of diaphragmatic palsy (DP) especially in children under 1 year of age. Controversy still persists on when this procedure should be undertaken. Some authors recommend that diaphragmatic plication should be performed as soon as the diagnosis of DP has been confirmed^[24] while others recommend a waiting period of 1–6 weeks in anticipation of potential spontaneous

recovery.^[10,12-14,25,26] Late surgical plication may be jeopardized by atrophy of the diaphragm which may even preclude successful surgical plication. A broad guideline about the indications is suggested in Table 2.

In cases of acquired DP, no portion of diaphragm needs to be excised. The thinned out diaphragm is just plicated to make it taut, and in this way damage to the phrenic nerve is avoided. A transverse upper abdominal incision is used for bilateral DP but for unilateral affection, a trans-thoracic repair through a posterior-lateral thoracotomy through the seventh intercostal space is preferred. There are two main techniques of plicating the diaphragm, and depending on the surgeon preference, pledgeted or non-pledgeted non-absorbable sutures may be used. In one technique [Figure 9], sutures are passed through the diaphragm three or four times and then tied. Multiple such rows

of sutures are placed to gather or reef the diaphragm. In the second technique, the dome of the diaphragm is held up in a series of Babcock forceps to achieve the required tautness of the diaphragm [Figure 10]. A row of interrupted non-absorbable sutures are then placed at the base of this gathered diaphragm and then the held up portion is just folded down anteriorly or posteriorly and sutured again to the diaphragm by a row of interrupted sutures thus creating three overlapping layers in the thinned out central portion of the diaphragm [Figure 10]. Care is taken to pass the sutures through the muscles of the diaphragm but not deep enough to injure the underlying organs such as the spleen or liver. The result is a tense and firm diaphragm that eliminates the paradoxical movement.

In the era of minimally invasive surgery, endoscopic techniques are being increasingly used for plication of the diaphragm, even in small children. Using video-assisted techniques, the diaphragm is elevated, clamped, oversewn, and tacked down into the pleural gutter. In an early experience,^[27] this procedure was performed in five children. Three of these patients were immediately extubated and the remaining were extubated within 2-3 days. Although, experience with these techniques in children is limited, this procedure may well become the management strategy of choice in the coming years.

The physiological success of plication has been well-

Table 2: Indications for diaphragmatic plication in children with diaphragmatic palsy after open-heart surgery

Age under 6 months
Respiratory distress
Tachypnea
Oxygen dependency
CO ₂ retention
Inability to wean from ventilator
Children with cavopulmonary shunts with the intention to prevent increase in pulmonary vascular resistance

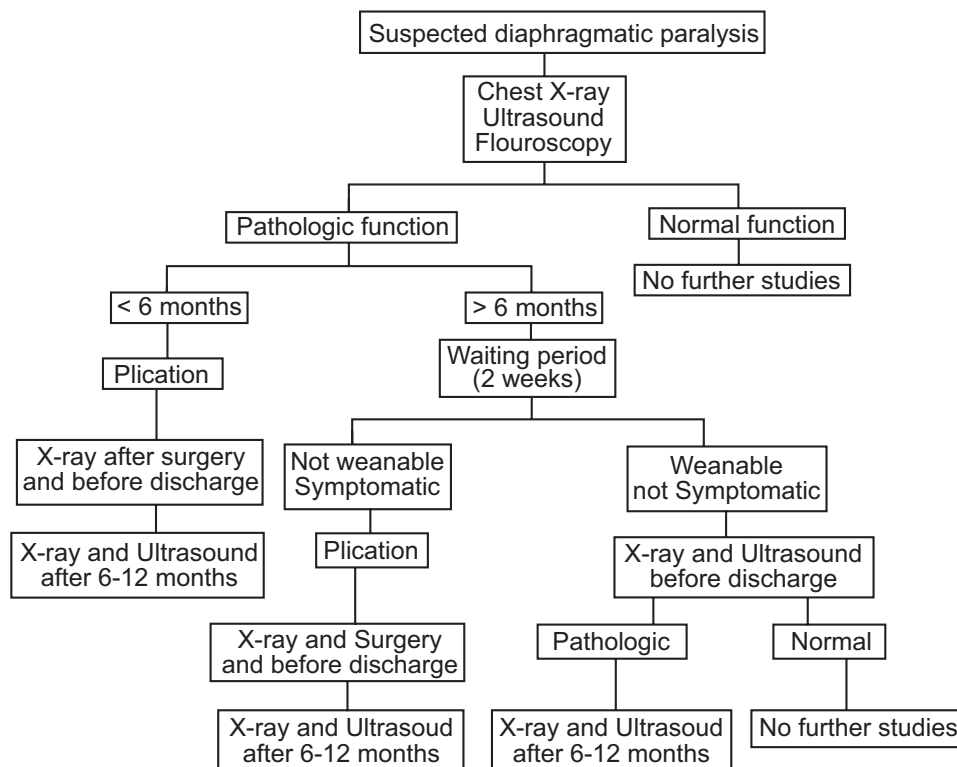


Figure 8: Algorithm of patients with diaphragmatic paralysis. (Reproduced with permission from [31].)

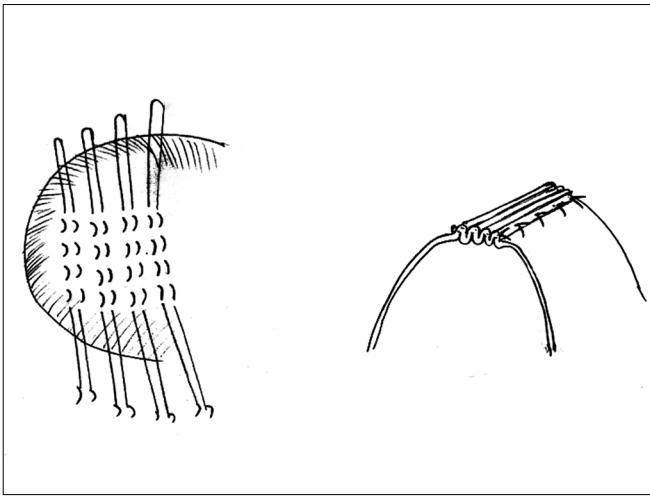


Figure 9: Technique of diaphragmatic plication (for details see the text)

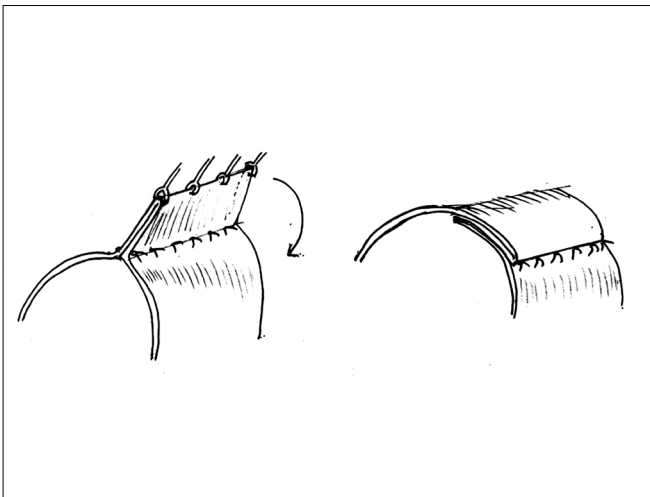


Figure 10: Alternative technique of diaphragmatic plication (for details see the text)

demonstrated.^[25] As is well known, the downward movement of the healthy side of the diaphragm during inspiration produces negative intrathoracic pressure and the abdominal contents are drawn into the paralyzed side of the thorax due to the paradoxical upward movement of the paralyzed side. This paradoxical motion does not let the lung expand on this side and results in poor gas exchange. After plication, the paralyzed side is more resistant to these pressure changes and over a period of time, the adjacent lung segments expand.^[28]

CONCLUSIONS

DP is not uncommon following open-heart surgery in children and can be a cause of significant morbidity and mortality. A high-index of suspicion is required for timely diagnosis and the management has to be individualized depending on the overall clinical scenario. Patients undergoing univentricular repair should have early

diaphragmatic plication.

REFERENCES

1. Standring S. Neck: Phrenic nerve. In: Standring S, editor. *Gray's Anatomy-The anatomical basis of clinical practice*. 40th ed. Spain: Churchill Livingstone Elsevier; 2008. p. 456-7.
2. Standring S. Diaphragm. Innervations: Phrenic nerve. In: Standring S, editor. *Gray's Anatomy-The anatomical basis of clinical practice*. 40th ed. Spain: Churchill Livingstone Elsevier; 2008. p. 1110-1.
3. Abad P, Lloret J, Martinez Ibanez V, Patino B, Boix-Ochoa J. Diaphragmatic paralysis: Pathology at the reach of the pediatric surgeon. *Circ Pediatr* 2001;14:21-4.
4. Dagan O, Nimri R, Katz Y, Birk E, Vidne B. Bilateral diaphragm paralysis following cardiac surgery in children: 10 year's experience. *Intensive Care Med* 2006;32:1222-6.
5. Lemmer J, Stiller B, Heise G, Hubler M, Alexi-Meskishvili V, Weng Y, *et al.* Postoperative phrenic nerve palsy: Early clinical implications and management. *Intensive Care Med* 2006;32:1227-33.
6. Akay TH, Ozkan S, Gultekin B, Uguz E, Varan B, Sezgin A, *et al.* Diaphragmatic paralysis after cardiac surgery in children: Incidence, prognosis and surgical management. *Pediatr Surg Int* 2006;22:341-6.
7. Joho-Arreola AL, Bauersfeld U, Stauffer UG, Baenziger O, Bernet V. Incidence and treatment of diaphragmatic paralysis after cardiac surgery in children. *Eur J Cardiothorac Surg* 2005;27:53-7.
8. Van Onna IE, Metz R, Jekel L, Woolley SR, Van de Wal HJ. Post cardiac surgery phrenic nerve palsy: Value of plication and potential for recovery. *Eur J Cardiothorac Surg* 1998;14:179-84.
9. Vazquez Lopez P, Medrano Lopez C, Serrano Madrid M, Lopez-Herce Cid J, Alcaraz Romero A, Zabala Arguelles I, *et al.* Diaphragmatic paralysis in the postoperative period after heart surgery in children. *An Esp Pediatr* 1996;45:591-6.
10. Tonz M, von Segesser LK, Mihaljevic T, Arbenz U, Stauffer UG, Turina MI. Clinical implications of phrenic nerve injury after pediatric cardiac surgery. *J Pediatr Surg* 1996;31:1265-7.
11. Picardo S, Testa G, Giamberti A, Rossi E, Catena G. Diaphragm paralysis following pediatric heart surgery: Review of 25 treated cases. *Minerva Anestesiol* 1996;62:177-81.
12. Serraf A, Planche C, Lacour Gayet F, Bruniaux J, Nottin R, Binet JP. Post cardiac surgery phrenic nerve palsy in pediatric patients. *Eur J Cardiothorac Surg* 1990;4:421-4.
13. Watanabe T, Trusler GA, Williams WG, Edmonds JF, Coles JG, Hosokawa Y. Phrenic nerve paralysis after pediatric cardiac surgery: Restrospective study of 125 cases. *J Thorac Cardiovasc Surg* 1987;94:383-8.
14. Mickell JJ, Oh KS, Siewers RD, Galvis AG, Fricker FJ, Mathews RA. Clinical implications of postoperative unilateral phrenic nerve paralysis. *J Thorac Cardiovasc Surg* 1978;76:297-304.
15. Davis J, Goldman M, Loh L, Casson M. Diaphragm function and alveolar hypoventilation. *Q J Med* 1976;45:87-100.
16. Robotham JL. A physiological approach to hemidiaphragm paralysis. *Crit Care Med* 1979;7:563-6

17. Wang CS, Josenhaus WT. Contribution of the diaphragmatic-abdominal displacement to ventilation in supine man. *J Appl Physiol* 1971;31:576-80.
18. Amin Z, McElhinney DB, Strawn JK, Kugler JD, Duncan KF, Reddy VM, *et al.* Hemidiaphragmatic paralysis increases postoperative morbidity after a modified Fontan operation. *J Thorac Cardiovasc Surg* 2001;122:856-62.
19. Ovroutski S, Alexi-Meskishvili V, Stiller B, Ewert P, Abdul-Khaliq H, Lemmer J, *et al.* Paralysis of the phrenic nerve as a risk factor for suboptimal Fontan hemodynamics. *Eur J Cardiothorac Surg* 2005;27:561-5.
20. Miller SG, Brook MM, Tacy TA. Reliability of two-dimensional echocardiography in the assessment of clinically significant abnormal hemidiaphragm motion in pediatric cardiothoracic patients: Comparison with fluoroscopy. *Pediatr Crit Care Med* 2006;7:441-4.
21. Haller JA Jr, Pickard LR, Tepas JJ, Rogers MC, Robotham JL, Shorter N, *et al.* Management of diaphragmatic paralysis in infants with special emphasis on selection of patients for operative plication. *J Pediatr Surg* 1979;14:779-85.
22. Iverson LI, Mittal A, Dugan DJ, Samson PC. Injuries to the phrenic nerve resulting in diaphragmatic paralysis with special reference to stretch trauma. *Am J Surg* 1976;132:263-9.
23. de Leeuw M, Williams JM, Freedom RM, Williams WG, Shemie SD, McCrindle BW. Impact of diaphragmatic paralysis after cardiothoracic surgery in children. *J Thorac Cardiovasc Surg* 1999;118:510-7.
24. Stauffer UG, Rickham PP. Acquired eventration of the diaphragm in the newborn. *J Pediatr Surg* 1972;7:635-40.
25. Schwartz MZ, Filler RM. Plication of the diaphragm for symptomatic phrenic nerve paralysis. *J Pediatr Surg* 1978;13:259-63.
26. Hamilton JR, Tocewicz K, Elliott MJ, de Leval M, Stark J. Paralyzed diaphragm after cardiac surgery in children: Value of plication. *Eur J Cardiothorac Surg* 1990;4:487-90.
27. Hines MH. Video-assisted diaphragm plication in children. *Ann Thorac Surg* 2003;76:234-6.
28. Ciccolella DE, Daly BD, Celli BR. Improved diaphragmatic function after surgical plication for unilateral diaphragmatic paralysis. *Am Rev Respir Dis* 1992;146:797-9.
29. Mok Q, Ross-Russel R, Mulvey D, Green M, Shinebourne EA. Phrenic nerve injury in infants and children undergoing cardiac surgery. *Br Heart J* 1991;65:287-92.
30. Balaji S, Kunowsky P, Sullivan I. Ultrasound in the diagnosis of diaphragmatic paralysis after operation for congenital heart disease. *Br Heart J* 1990;64:20-2.
31. Joho-Arreola AL, Bauersfeld U, Stauffer UG, Baenziger O, Bernet V. Incidence and treatment of diaphragmatic paralysis after cardiac surgery in children. *Eur J Cardiothorac Surg* 2005;27:53-7.

Source of Support: Nil, Conflict of Interest: None declared
