

Grand Rounds

The Chest Radiograph

Barry Kelly

Accepted 1 September 2012

INTRODUCTION

The chest radiograph accounts for a very significant proportion of imaging throughout the world. It often represents the first imaging step, not only in diseases that focus on the cardiovascular and respiratory systems, but in systemic illness. For this reason, its ubiquity can be beguiling. There is an inclination to feel that because one grows up with the chest radiograph, there must be an innate and acquired knowledge not always tested by rigorous curriculum or by assessment. The purpose of this Ground Rounds paper is to set out some basic principles which I hope will be helpful for the medical student and postgraduate trainee.

THE NORMAL CHEST RADIOGRAPH

Before reviewing the radiograph itself it is important to confirm that the study associated with the **right patient** and has been performed on the **right date**. As someone once said, it is difficult to make an original mistake, and reviewing a radiograph in its incorrect sequence is not uncommon but can be a very important error in retrospect. It is also important to remember that the most influential radiograph might be the previous study. Therefore, when reviewing any chest radiograph it is vital to ascertain if there are previous studies available, either in celluloid format or on the Picture Archive Communication System (PACS) timeline. For example, the Kerley B lines seen at the costophrenic angles and lateral chest walls are not specific to cardiac failure and, in fact, represent the manifestation of enlargement of the interlobular septa of the secondary pulmonary lobules. In other words, interstitial lung diseases will produce precisely the same appearance. However, it is likely that a patient with interstitial lung disease will have previous studies indicating that the appearances are stable, whereas in cardiac failure, the transient nature of the appearances may be a vital diagnostic clue.

TECHNICAL ASPECTS

The three criteria routinely reviewed to confirm the satisfactory quality of any chest radiograph are: rotation, inspiration and penetration. Penetration, using modern digital techniques is less relevant nowadays, so I will concentrate on the remaining two. A satisfactory chest radiograph should have no rotation. This is confirmed by ensuring that the medial borders of the clavicle are equidistant from the spinous processes of the vertebral bodies.

It is also important to ensure that the patient has made a good

inspiratory effort. This is confirmed by ascertaining that there are ten ribs visible posteriorly in the mid clavicular line on the frontal chest radiograph. It is important at this stage to consider why these two technical factors are so important. Effectively, the answer is because in each case, failure to ensure the correct standard can mimic life-threatening pathology.

In the case of rotation, one side of the radiograph becomes darker than the other. This phenomenon is known as *increased transradiancy*. Therefore, one side becomes more transradiant (darker) than the other. The diagnostic error here is that the reviewer may misinterpret this difference in transradiancy as pathology. For example, the darker side may represent a pneumothorax, or pulmonary embolism (the *Westermarck* sign). In addition, the lighter side may be misinterpreted as a pleural fluid collection or air space consolidation. This is particularly likely on a supine radiograph.

Poor inspiratory effort is equally important. Essentially, the problem is that with a poor inspiratory effort, the pulmonary vessels become more prominent and an erroneous diagnosis of cardiac failure (probably the single most common diagnostic error made by medical students on any chest radiograph) is all too easy. We will consider the criteria for cardiac failure shortly.

A SYSTEM FOR REVIEWING THE CHEST RADIOGRAPH

Having confirmed that the patient's details are correct and that the radiograph is technically satisfactory one should proceed to reviewing the chest radiograph in a systematic order. There are several such paradigms. This is the one that I use and recommend.

AP or PA Orientation?

The international standard for labelling a chest radiograph is that a PA (posteroanterior) standard film has no annotative marking on it. All other variations: anteroposterior (AP); the decubitus; supine, or semi erect are all so annotated for the reviewer's assistance. By definition the patients in this

Level 4 Imaging Centre, Royal Victoria Hospital, Grosvenor Road, Belfast BT12 6BA

email: editor@ums.ac.uk

Correspondence to Dr Kelly

latter category are of increased infirmity and the diagnostic threshold can be challenging.

Radiology trainees are encouraged not to begin a report with reference to 'PA' or 'AP' but to vocalise the following introductory statement: "This is a frontal chest radiograph of an adult patient." (I am assuming of course that it is an adult!). Secondly, and if appropriate, one adds a second line, "Both breast shadows are present." In any examination context, in particular, this tactic has several advantages. Discussion about the orientation of the chest radiograph is often of limited value diagnostically, but also may represent an uncomfortable detour for a student who does not wish to be interrogated on archaic techniques of radiography. Secondly, there is good evidence to show that most abnormalities are appreciated on a chest radiograph within five to ten seconds. That is not to say that the diagnosis itself is made but the abnormality is recognised as such. By employing both these phrases the examination candidate has time to quickly review the image and look for any obvious abnormalities. In addition, checking that both breast shadows are present is an important exercise and discipline. Failure to recognise a second breast shadow suggests an underlining diagnosis of mastectomy and, therefore, should prompt a systematic review for evidence of breast cancer and its sequelae.

The Heart Size

The maximum transverse diameter of the heart should not exceed 50% of the maximum transverse diameter of the chest on a standard posteroanterior (PA) radiograph. This measurement is known as the *Cardiothoracic Ratio*. On the AP (anteroposterior) portable film there is a magnification factor of approximately 20% and this can present some difficulty in evaluating the cardiac size. However, it is worth stressing that precisely because there is a magnification factor involved, if the heart size is identified as normal on a non PA study, then there can be no cardiomegaly. Gross cardiomegaly should be easily distinguishable from a slightly magnified normal heart. It is, therefore, not correct to infer that the heart size cannot be assessed using an AP study. Difficulties do exist but there are sound principles allowing a logical diagnosis to be made.

Pulmonary Vasculature

When radiologists describe 'pulmonary vascularity' on our reports, we are discussing pulmonary *venous* vascularity. In other words, this is shorthand for the absence or presence of cardiac failure. Enlarged pulmonary arteries, as for example, in a left to right cardiac shunt, is given a specific designation: *Pulmonary Plethora*.

How does the reviewer ascertain that the pulmonary vascularity is normal? There are elementary rules to assist the reviewer:

1. Pulmonary venous vessels should not be discretely visible in the outer third of the lung fields.

2. Approximately 90% of the pulmonary vascular structures are appreciated at the mid and lower zones. This is an effect of gravity.
3. When pulmonary vascularity increases, for example, with heart failure, increased vascular conspicuity is apparent at the apices. This is known as *Equivalence* or *Upper Zone Diversion*. Evaluation of this is qualitative, and requires experience. Consequently, it is often helpful to view the image in a radically different form. If one is not sure whether the vessels are, in fact, more prominent in the upper zones than the lower zones, it is often helpful to flip the image vertically on the PACS system or turn the radiograph upside down. The reviewer's higher cortical and optic pathways will then have to consider the same question, but he or she has been presented with the data in a different way. Try it for yourself. Does the apex now look as you would expect it or not? Often this manoeuvre can be of great diagnostic help.
4. Kerley B lines, please see above.
5. Angel or Bat Wings. These are seen in the most severe form of cardiac failure, pulmonary oedema, and are very rare.

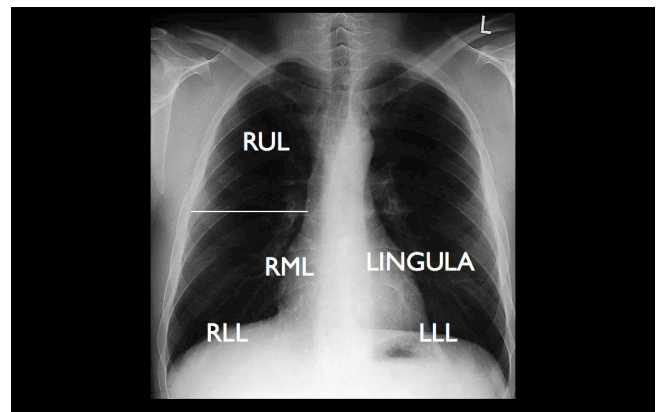


Fig 1. The Silhouette Sign. The diaphragm and heart borders are adjacent to lung lobes.

The Lung Fields

An American Radiologist named Benjamin Felson described *The Silhouette Sign*. He posited out that only three densities are visible on any radiograph. These are bone, air and soft tissue. The reason that we can appreciate one density, for example the heart shadow, is because it abuts a different density, and consequently, we see a silhouette. If that normal silhouette disappears, it implies that the adjoining area has now transmuted into the *same density* as its neighbouring structure, usually indicating lobar consolidation caused by infection. Therefore, all one needs to appreciate the location of the consolidation, is to know which lobe of each lung lies adjacent to the heart and hemidiaphragms. (Please see figure 1)

Review Areas

There are several review areas that a reviewer should consider in every chest radiograph, and it is useful to adopt an order for evaluating these, and then stick to it!

1. Sub diaphragmatic region

Pneumoperitoneum, in the absence of recent surgery, often denotes a life-threatening pathology and therefore its confident diagnosis is of crucial importance. On the erect chest radiograph there should be no free gas present under the diaphragm. On the left side, a gastric air bubble is frequently seen. On the right, interposed small or large bowel may occasionally be seen. This is known as *Chilaiditi's Sign* and usually presents little diagnostic difficulty, as the small bowel's valvulae conniventes or colonic haustra are easily distinguishable. Even very small quantities of free gas can be confidently seen under the right hemidiaphragm and this should represent an essential review area (fig 2).

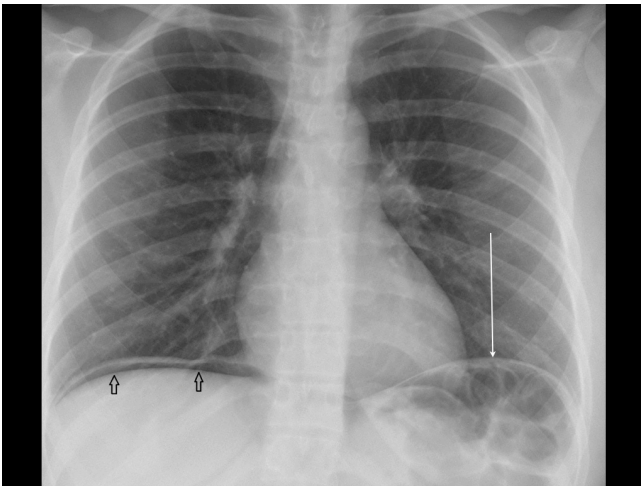


Fig 2. Right-sided pneumoperitoneum and on the left, Chilaiditi's sign.

2. The Lung Apices.

Evaluating the lung apices can be difficult. This is particularly the case in the older patient where there is asymmetrical calcification of the costochondral junctions. This age-related calcification can mimic a neoplasm. If there is diagnostic uncertainty, or an asymmetry in the apical appearances, the simplest solution is to request a supplementary *apical view* (figs 3,4). Technically, this allows visualisation of the lung apices without the complication of overlapping bony structures. The apical view is almost always performed to reassure a patient (or his clinician) that the index of suspicion is low, but occasionally it will confirm quite a sizable mass lesion.

3. Trachea

The trachea is often deviated by pathology within the neck or chest and ascertainment that it is midline is essential. The commonest neck mass to displace the trachea is a thyroid mass, which will displace it to the contralateral side. Within the chest, a tension pneumothorax will displace the trachea to the contralateral side, while collapse or atelectasis of a lobe will draw the trachea towards the side of the abnormality.

4. The Hilum

The *hilar point* on either side of the heart represent the intersection of the pulmonary arteries and veins. The left hilar point normally lies higher than the right. Aside from this, the hila should always be equal in size and density.

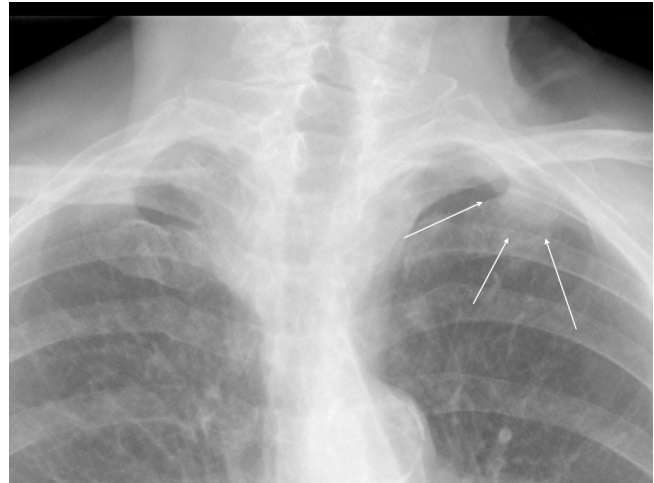


Fig 3. Subtle left apical mass on chest radiograph (arrows).

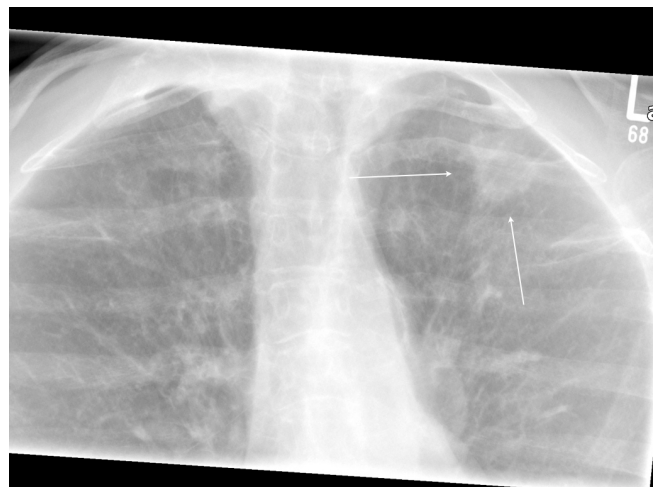

Fig 4. Apical view reveals a distinct neoplasm at the left apex (arrows).

5. The Aorto-pulmonary Window

As the reviewer follows the left edge of the mediastinum from its superior aspect, the first convexity seen is that of the aortic knuckle. If one traces the edge of the aortic knuckle inferiorly, the next convexity is that of the pulmonary artery. Between the two there is a concavity. There should be nothing within this aorto-pulmonary bay or window. It is very important that review of this window is performed in every chest radiograph. It is well recognised that malignant lymphadenopathy associated with a neoplasm can manifest itself within this window. This may potentially be the only opportunity for the clinician to affect curative therapy. However, it does require the reviewer to understand the fundamental importance, of confirming the emptiness of the normal window.

6. Bones

I would suggest that this is the last review area. Contemporary chest radiographs use a technique known as 'high kilovoltage' (kV). This technique was developed to permit improved evaluation of the chest organs. The cost was that conspicuity of bone decreases. This can be unfortunate, particularly, when looking for rib fractures (which, incidentally, typically occur along the lateral margins of the lower chest). The identification of any rib fracture should prompt the immediate radiological exclusion of pneumothorax.

Bone review effectively is performed for two reasons:

- Trauma: to exclude fractures or dislocations, particularly at shoulder level.
- Neoplasia: to exclude infiltration and destruction particularly in metastatic disease and myeloma.

Commenting on bone patterns viewed through the lung parenchyma can be difficult. The highest diagnostic yield is to review bones that are not seen through a haze of lung tissue and pulmonary vessels. Therefore, the shoulder joints, lateral clavicles and lower ribs (that overlie the liver and spleen) provide better diagnostic accuracy for infiltrative bone disease.

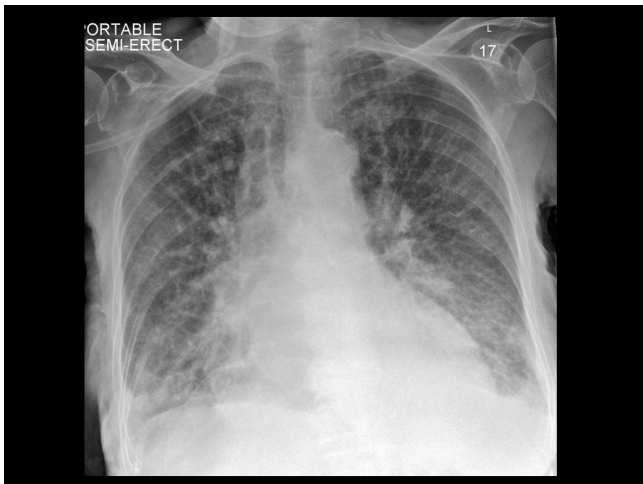


Fig 5. Cardiac Failure.

COMMON PATHOLOGIES

CARDIAC FAILURE

Using our schematic method, the following criteria will help formulate a diagnosis of cardiac failure (Fig 5).

- Increased cardiothoracic ratio
- Increased (venous) pulmonary vascularity
- Kerley B lines
- Pleural Effusions
- Bat or Angel Wings

LOBAR CONSOLIDATION

The confident and accurate diagnosis of lobar consolidation rests on an understanding of the silhouette principle as described by Felson. In the annotated chest radiograph (fig 1) all one must do is confirm which silhouette is missing. The appropriate pulmonary lobe can then be identified (fig. 6). These are:

Left lower lobe: Left hemidiaphragm

Right lower lobe: Right hemidiaphragm

Right heart border: Right middle lobe

Left heart border: Lingula.

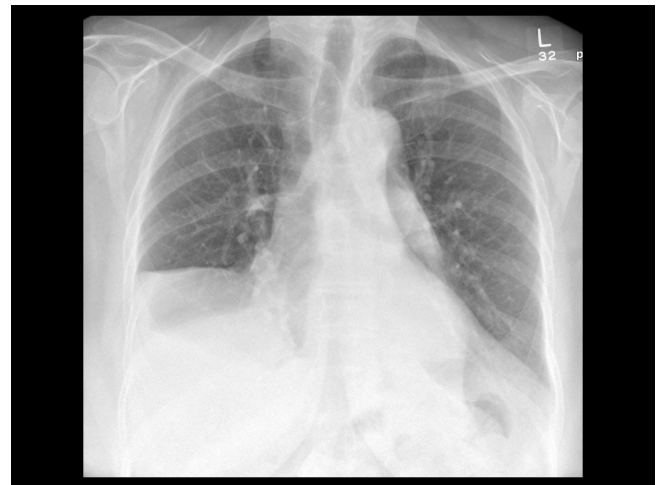


Fig 6. Lobar consolidation involving the right middle lobe, right lower lobe and left lower lobe.

Consolidation in the upper lobes follows the same principle but is slightly different. On the right hand side, the lung is demarcated by the transverse or minor fissure. Consolidation above, and terminating at, the minor fissure indicates right upper lobe consolidation. Consolidation below, and terminating at, the transverse fissure, delineates the right middle lobe. Consolidation of the left upper lobe tends to produce a fuzzy 'veiling' effect with consequent reduced conspicuity of the aortic knuckle's silhouette.

PNEUMOTHORAX

Pneumothorax is divided into the *simple* and *tension* pneumothorax. The tension pneumothorax is diagnosed radiologically when the mediastinum is displaced to the contralateral side and there is inferior displacement of the ipsilateral hemidiaphragm (fig 7). Accompanying clinical distress is of course also present.

In an otherwise fit and conscious patient, a pneumothorax is seen as the separation of lung edge from the chest wall. This is maximal on expiration because of the relatively increased interpleural pressure, and therefore if there is a clinical suspicion of pneumothorax it is worth requesting an expiratory view.

At this point it is worth discussing an artifact or mimic that

may occur in both infant chest radiographs and adult non-PA chest studies. This is the *skin fold* and represents the interposition of redundant skin between the patient's back and the X-ray cassette. The appearances can look dramatically like a pneumothorax but careful evaluation will reveal the fact that the pulmonary vessels are seen to cross the 'lung edge' indicating that there is no pneumothorax. Clearly it is also vital to place such a diagnosis within its clinical context.

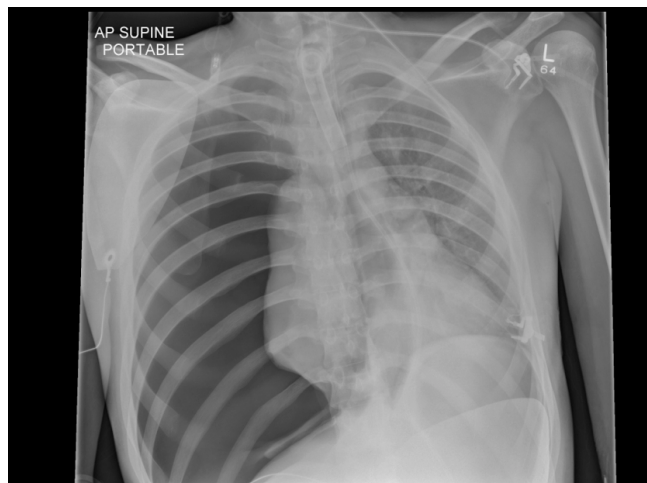


Fig 7. Right-sided tension pneumothorax.

Diagnosis of pneumothorax in the supine patient can be problematic. The lung edge may not be appreciable. However in these patients, the normal costophrenic angle may disappear and be replaced with a 'sausage-shaped' *Deep Sulcus* sign. Identification of this sign (fig 8) in such a patient should raise the possibility of a pneumothorax.

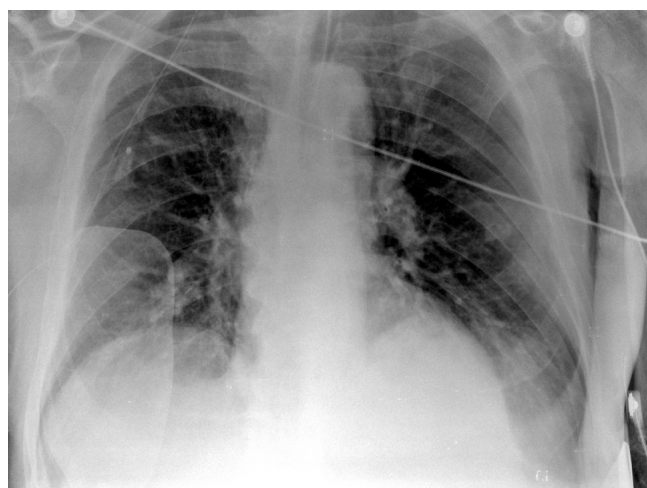


Fig 8. Supine radiograph: Deep Sulcus Sign indicating a left pneumothorax.

PLEURAL EFFUSIONS

Because the chest radiograph is relatively insensitive and can discriminate only air, soft tissue and bone, it is not possible to separate in terms of density, transudates and exudates. The typical appearances of pleural effusion on an erect radiograph are those of an area of increased density with a meniscus rising up the lateral chest wall. This meniscus reflects the

negative intrapleural pressure of fluid within the pleural space (fig 9). A horizontal fluid level within the chest, however, suggests a hydropneumothorax with air in the pleural space. Remember also that if the mediastinum is not displaced in the presence of a pleural effusion, this indicates underlying collapse of the ipsilateral lung segment or lobe.

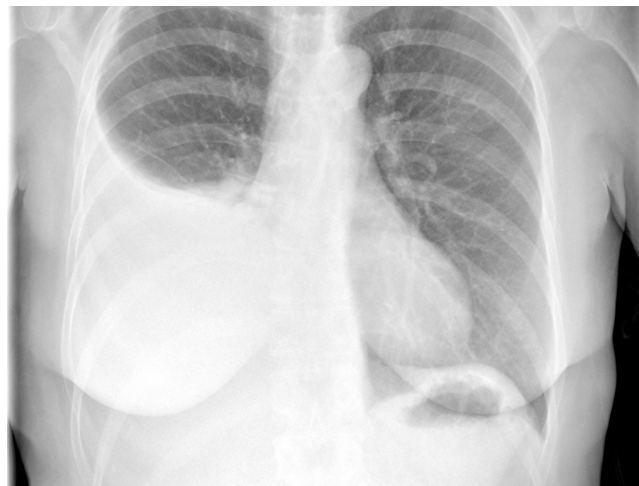

Fig 9. Pleural effusion, right side.

As with the pneumothorax, diagnosis of pleural effusion can be problematic in the supine, unconscious or trauma patient. In these individuals the likely diagnostic sign will be a difference in transradiancy, as previously described. In other words the abnormal lung is lighter than the normal lung. This is because the fluid is now tracking along the posterior pleural space (see figure 10). This emphasises the importance of ensuring that the visualised difference in transradiancy is not the result of a malrotated chest radiograph.

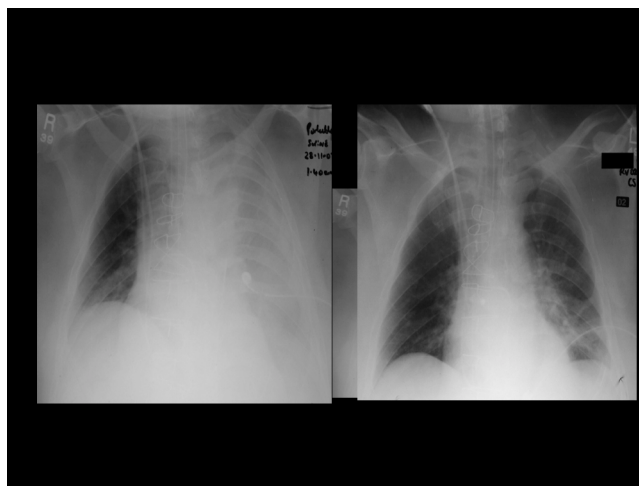

Fig 10. Supine radiograph. Left pleural effusion before and after manipulation of chest drain.

LINES AND TUBES

1. The Nasogastric Tube

Misplaced nasal gastric tubes are a frequent feature of hospital life. The penalty however for commencing nasogastric feeding when the tube is misplaced within the bronchus can be very high. The correctly placed

nasogastric tube should assume a vertical orientation within the chest and pass below the diaphragm. The tube should then be seen projected over the left upper quadrant of the abdomen often crossing the midline to the right, to lie within the gastric atrium. The commonest location for a misplaced nasogastric tube is within the right or left lower lobe bronchus (fig 11).

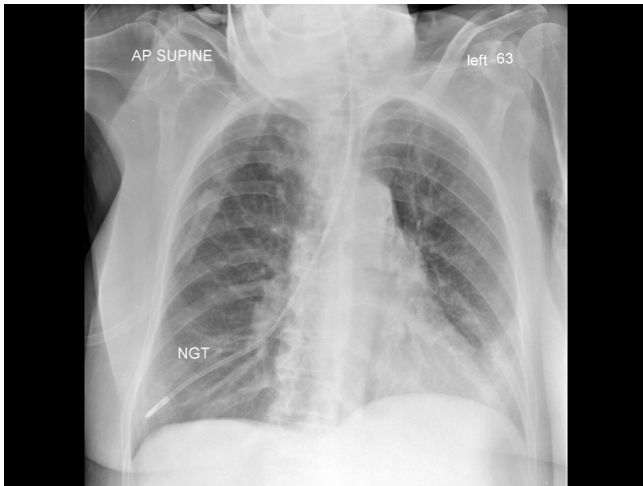


Fig 11. Misplaced nasogastric tube in the right lower lobe bronchus.

2. The Central Venous Line

The tip of the central venous line should lie at the junction of the superior vena cava and the right atrium (fig 12). The reviewer should always ensure there is no associated pneumothorax.

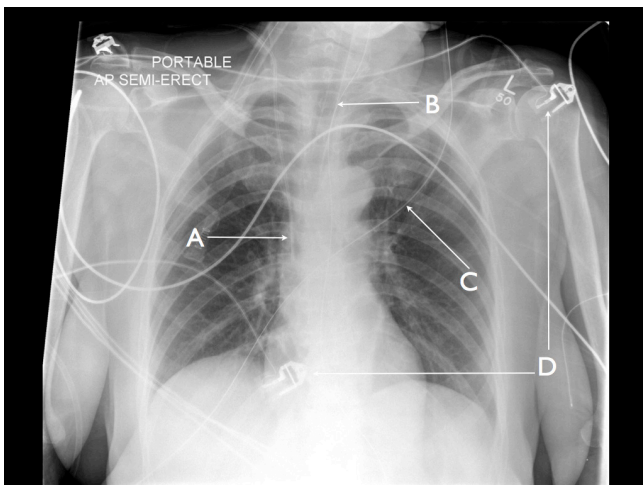


Fig 12. Lines and tubes. (A): central venous line; (B): endotracheal tube; (C): oxygen tubing; (D): ECG electrodes.

3. The Endotracheal Tube

The tip of the endotracheal tube should lie above the level of the tracheal bifurcation or *carina*. Various tests have been suggested; some advocate placement of the

tube tip midway between the sternoclavicular joint and the carina, and others use a qualitative measurement of between two to five centimetres above the carina (figure 12). The problem with a chest tube tip at the carina itself is that with respiration it will slide into the right main bronchus obstructing the left and potentially causing left lung collapse.

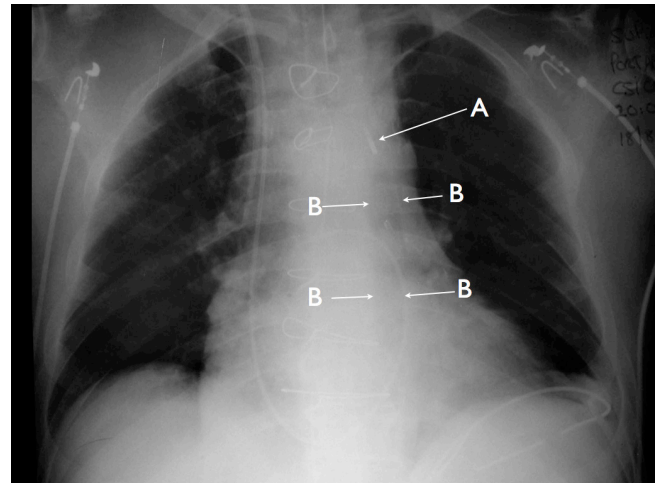


Fig 13. Aortic Balloon Pump: (A): marker indicating cranial end of pump; (B): Inflated balloon.

4. The Aortic Balloon Pump

The aortic balloon pump lies within the descending thoracic aorta. The upper or cranial end of the balloon is marked with a small radio opaque marker (fig 13). Below this marker there is a 10 cm balloon. The balloon should lie *between* the left subclavian artery and the renal arteries, in order not to obstruct either. The reviewer, therefore, should ascertain that the radio opaque marker is not higher than the aortic knuckle (considering it as a clock face, I use the 'three o'clock position' to mark the ostium of the left subclavian artery). In addition, if the marker is identified at the mid thoracic aortic level, it suggests that the balloon may occlude the renal and splanchnic ostia.

CONCLUSIONS

In this overview, I have attempted to guide the examination candidate with an elementary, structured schematic, for reviewing a chest radiograph. For the junior doctor, the commonest lifesaving diagnoses to make are those of cardiac decompensation, lobar consolidation and the pneumothorax. Although there is no substitute for experience and reporting large numbers of chest radiographs, using these tools, I would hope that the reader has one logical framework for the evaluation of basic pathologies.

My sincere thanks to Ms Lyndsey O'Neill for typing the manuscript.

The author has no conflict of interest