



# Successful Treatment of Eosinophilic Enterocolitis in an Adult Patient With Adalimumab

Yichun Fu, MD<sup>1</sup>, David Choi, PharmD<sup>1</sup>, Natali Ronen, MD<sup>2</sup>, and Sushila Dalal, MD<sup>1</sup>

<sup>1</sup>Section of Gastroenterology, Hepatology and Nutrition, Department of Medicine, University of Chicago, Chicago, IL

<sup>2</sup>Department of Pathology, University of Chicago, Chicago, IL

## ABSTRACT

Eosinophilic gastrointestinal diseases are increasing in prevalence, but understanding of their causes and effective treatments remain elusive, especially in adults. We present a case of eosinophilic gastroenteritis and colitis with extraintestinal manifestations that was successfully treated with a tumor necrosis factor  $\alpha$  inhibitor, adalimumab.

**KEYWORDS:** eosinophilic gastroenteritis; eosinophilic colitis; anti-TNF; diarrhea

## INTRODUCTION

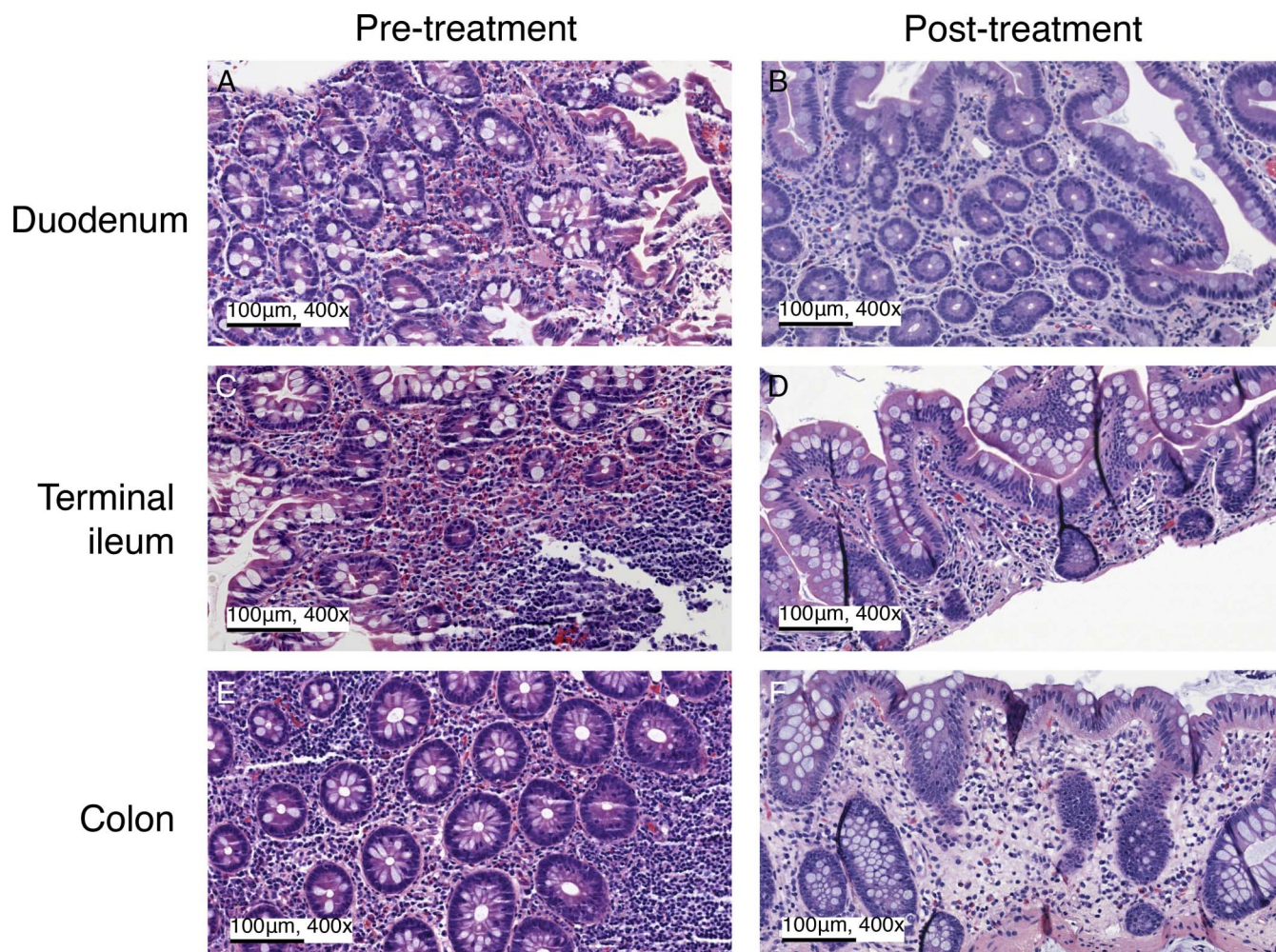
Eosinophilic gastroenteritis (EGE) and eosinophilic colitis (EC) affect 5.1 and 2.1 per 100,000 people, respectively, in the United States.<sup>1,2</sup> Despite eosinophil infiltration in the gastrointestinal (GI) tissue, the peripheral eosinophil count may be normal.<sup>1,3</sup> The pathogenesis of these disorders is poorly understood, although studies, mainly in the pediatric literature, suggest food allergy, atopy, or gut dysbiosis as possible causes.<sup>3-5</sup> Clinical manifestations include acid reflux, dysphagia, abdominal pain, diarrhea, and weight loss.

The proposed histopathologic threshold for eosinophilia is set as  $>30$  eosinophils per high-power field (eos/hpf) on gastric biopsies,  $>50$  eos/hpf on small bowel biopsies, and generally  $>65$  eos/hpf in the colon, with a higher threshold for the right colon.<sup>3,5</sup> Treatment options include corticosteroids and steroid-sparing maintenance therapies.<sup>3,5-7</sup> However, there is no large-scale evidence for the treatment of refractory disease, and the few nonsteroid therapies described are largely in case reports, more in children than adults. Among these, tumor necrosis factor  $\alpha$  (TNF- $\alpha$ ) inhibitors have been successfully used to induce remission in children, as described by Turner et al,<sup>7</sup> but the experience is limited in adults. Straumann et al<sup>8</sup> reported use of infliximab in 3 adults with eosinophilic esophagitis; however, 2 loading doses of infliximab led to only partial clinical and cellular response in 1 of the 3 patients 4 weeks after the second infusion. We describe a case of steroid-dependent EGE and EC in an adult successfully treated with the TNF- $\alpha$  inhibitor adalimumab.

## CASE REPORT

A 35-year-old White woman with hypertension and primary hyperaldosteronism presented with intermittent abdominal pain and chronic diarrhea for the past 6 years. She had a few episodes of small rectal bleeding. Review of systems was notable for heartburn and severe pain in her entire spine. The patient denied vomiting, weight loss, or fevers. Family history was notable for ulcerative colitis in her mother. No environmental or food allergies were identified. Her medications included hydralazine, metoprolol, amiloride, azilsartan, and pantoprazole.

On physical examination, the patient had temperature 37.2°C, pulse rate 75, and blood pressure 140/100 with oxygen saturation 100% on room air. There was mild epigastric tenderness on deep palpation. Initial laboratory examination showed a leukocyte count of  $11.1 \times 10^3/\mu\text{L}$  (70% neutrophils, 1% eosinophils, absolute eosinophil count  $0.07 \times 10^3/\mu\text{L}$ ), hemoglobin  $13.2 \times 10^3/\mu\text{L}$ , platelet



**Figure 1.** Histologic comparison of the biopsies from pre and post-treatment endoscopic evaluation. Before adalimumab treatment, there were 53 eosinophils per high-power field in the duodenum (A), 120 in the terminal ileum (C), and 87 in the colon (E). After treatment, there were 8 eosinophils per high-power field in the duodenum (B), 17 in the terminal ileum (D), and 18 in the colon (F). The insets were obtained on 400 $\times$  magnification.

count  $350 \times 10^3/\mu\text{L}$ , C-reactive protein 10 mg/dL, blood urea nitrogen 14 mg/dL, serum creatinine 0.76 mg/dL, and vitamin D 25 mg/dL.

An esophagogastroduodenoscopy and colonoscopy at an outside clinic 8 months ago appeared normal. Pathology was notable for intramucosal eosinophil at 53 eos/hpf on duodenal biopsy and 68 eos/hpf on gastric antrum biopsy. *Helicobacter pylori* was absent. On terminal ileum biopsy, there were 120 intramucosal eos/hpf. Other random colon biopsies showed increased eosinophils of 87 eos/hpf and occasional non-caseating granulomas. However, there were no crypt abscesses or inflammatory cells in the lamina propria. A diagnosis of EGE and EC was made based on the number of eosinophils (Figure 1).

The patient was started on budesonide 6 mg daily with mild improvement, but her symptoms relapsed with taper to budesonide 3 mg daily. Oral prednisone was contraindicated due to

primary hyperaldosteronism. Given steroid dependence and concomitant arthritis, she underwent induction with adalimumab and was bridged to adalimumab 40 mg every 14 days. Her symptoms markedly improved with adalimumab. However, she had flare-ups of diarrhea and back pain after 3 months, so budesonide 9 mg daily was reinitiated while adalimumab was increased to 40 mg every 7 days. Eventually, the patient had complete resolution of her GI and joint symptoms on an adalimumab 40 mg weekly dose after budesonide was tapered off. Five months after adalimumab initiation, her inflammatory markers were normalized (C-reactive protein 3 mg/dL, leukocyte  $6.7 \times 10^3/\mu\text{L}$ , with 2% eosinophils and absolute eosinophil count  $0.12 \times 10^3/\mu\text{L}$ ). Repeat esophagogastroduodenoscopy and colonoscopy after 6 months of adalimumab showed mild antrum erosions and patchy mild inflammation in the cecum, and the rest of the colon appeared normal. The biopsies showed non-specific antrum erosion and nonspecific mild prominence of eosinophils in the cecum; the rest of the biopsies were normal (Figure 1).



## DISCUSSION

We present a unique case of concurrent EGE with extra-intestinal symptoms successfully treated with adalimumab. The patient's abdominal pain and diarrhea were correlated with elevated inflammatory markers and dense mucosal eosinophilic infiltration in gastric, enteral, and colonic biopsies. Although no infectious workup, that is, stool ova and parasite examination, was performed on her index presentation, it was less likely driven by infection because of response to steroids. She is now well on maintenance adalimumab.

No randomized controlled trials have been performed to evaluate the current EGE treatment options, such as dietary therapies, corticosteroids, or mast-cell stabilizers.<sup>3,5</sup> Few studies shed light on steroid-sparing treatment of EGE and EC in adults. Case studies in pediatric patients suggested a positive effect of mesalamine, azathioprine, anti-TNF- $\alpha$  agents, mast-cell stabilizers, and leukotriene receptor antagonists.<sup>3</sup> A case series by Turner et al<sup>7</sup> described complete clinical remission in 6 (75%) of 8 children on infliximab or adalimumab. Another case series in 22 adults described moderate response to steroids and anti-TNF- $\alpha$  agents and remission in three-fourths of the patients with vedolizumab, an  $\alpha 4\beta 7$  integrin blockade.<sup>9</sup> TNF- $\alpha$  is known to promote cytokine release, important in the pathogenesis of EGE.<sup>3,10</sup> This mechanism may provide insight into the efficacy of anti-TNF- $\alpha$  agents.

One reason for selecting adalimumab therapy in this case was the patient's concurrent joint pain. Adalimumab is a well-established treatment of inflammatory arthritis.<sup>11,12</sup> The relationship of joint symptoms and eosinophilic disorders is not well defined. A registry for eosinophilic GI disorders for both pediatric and adult patients found that people with EGE and EC reported more joint pain than people with eosinophilic esophagitis.<sup>13</sup> Case reports have linked eosinophilic GI disorders with autoimmune diseases, particularly in young and mid-aged women.<sup>14</sup> It is important to recognize these extraintestinal symptoms and take them into consideration when making a therapy selection.

This is the first reported case of EGE and EC in an adult that achieved clinical and histologic remission with adalimumab. We suggest that anti-TNF- $\alpha$  therapy should be considered when treating steroid-refractory eosinophilic GI disorders.

## DISCLOSURES

Author contributions: Y. Fu and D. Choi: drafting of the manuscript and approval of the final draft submitted. N. Ronen: pathology image acquisition and interpretation, manuscript revision, and approval of the final draft submitted. S. Dalal: endoscopy result interpretation, manuscript revision, and approval of the final draft submitted, and is the article guarantor.

Financial disclosure: D. Choi served on the speaker bureau for Janssen Pharmaceuticals and as a consultant to Bristol Myers Squibb, and Boehringer Ingelheim, Abbvie, and Janssen Pharmaceuticals. S. Dalal served on the speaker's bureau for Abbvie and acted as a consultant for Pfizer.

Informed consent was obtained for this case report.

Received August 31, 2023; Accepted January 15, 2024

## REFERENCES

- Mansoor E, Saleh MA, Cooper GS. Prevalence of eosinophilic gastroenteritis and colitis in a population-based study, from 2012 to 2017. *Clin Gastroenterol Hepatol*. 2017;15(11):1733–41.
- Jensen ET, Martin CF, Kappelman MD, Dellon ES. Prevalence of eosinophilic gastritis, gastroenteritis, and colitis: Estimates from a national administrative database. *J Pediatr Gastroenterol Nutr*. 2016; 62(1):36–42.
- Walker MM, Potter M, Talley NJ. Eosinophilic gastroenteritis and other eosinophilic gut diseases distal to the oesophagus. *Lancet Gastroenterol Hepatol*. 2018;3(4):271–80.
- Hogan SP, Mishra A, Brandt EB, et al. A pathological function for eotaxin and eosinophils in eosinophilic gastrointestinal inflammation. *Nat Immunol*. 2001;2(4):353–60.
- Mehta P, Furuta GT. Eosinophils in gastrointestinal disorders: Eosinophilic gastrointestinal diseases, celiac disease, inflammatory bowel diseases, and parasitic infections. *Immunol Allergy Clin North Am*. 2015; 35(3):413–37.
- Uppal V, Kreiger P, Kutsch E. Eosinophilic gastroenteritis and colitis: A comprehensive review. *Clin Rev Allergy Immunol*. 2016;50(2):175–88.
- Turner D, Wolters VM, Russell RK, et al. Anti-TNF, infliximab, and adalimumab can be effective in eosinophilic bowel disease. *J Pediatr Gastroenterol Nutr*. 2013;56(5):492–7.
- Straumann A, Bussmann C, Conus S, Beglinger C, Simon HU. Anti-TNF- $\alpha$  (infliximab) therapy for severe adult eosinophilic esophagitis. *J Allergy Clin Immunol*. 2008;122(2):425–7.
- Grandinetti T, Biedermann L, Bussmann C, Straumann A, Hruz P. Eosinophilic gastroenteritis: Clinical manifestation, natural course, and evaluation of treatment with corticosteroids and vedolizumab. *Dig Dis Sci*. 2019; 64(8):2231–41.
- Ahmad S, Azid NA, Boer JC, et al. The key role of TNF-TNFR2 interactions in the modulation of allergic inflammation: A review. *Frontiers*. (<https://www.frontiersin.org/articles/10.3389/fimmu.2018.02572/full>). Accessed November 2, 2022.
- Fraenkel L, Bathon JM, England BR, et al. 2021 American College of Rheumatology guideline for the treatment of rheumatoid arthritis. *Arthritis Care Res*. 2021;73(7):924–39.
- Vavricka SR, Gubler M, Gantenbein C, et al. Anti-TNF treatment for extraintestinal manifestations of inflammatory bowel disease in the Swiss IBD Cohort Study. *Inflamm Bowel Dis*. 2017;23(7):1174–81.
- Jensen ET, Aceves SS, Bonis PA, et al. High patient disease burden in a cross-sectional, multicenter contact registry study of eosinophilic gastrointestinal diseases. *J Pediatr Gastroenterol Nutr*. 2020;71(4):524–9.
- Lecouffe-Desprets M, Groh M, Bour B, Le Jeunne C, Puéchal X. Eosinophilic gastrointestinal disorders associated with autoimmune connective tissue disease. *Joint Bone Spine*. 2016;83(5):479–84.

**Copyright:** © 2024 The Author(s). Published by Wolters Kluwer Health, Inc. on behalf of The American College of Gastroenterology. This is an open access article distributed under the terms of the Creative Commons Attribution-Non Commercial-No Derivatives License 4.0 (CCBY-NC-ND), where it is permissible to download and share the work provided it is properly cited. The work cannot be changed in any way or used commercially without permission from the journal.