



## Educational Case

### Educational Case: Endometrial carcinoma types I and II

Zachary A. Hemann, MD, Wendy Z. Lim, MD, Walter L. Kemp, MD, PhD \*

University of North Dakota School of Medicine and Health Sciences, 1301 North Columbia Road, Mailstop 9037, Grand Forks, ND, 58202, USA



The following fictional case is intended as a learning tool within the Pathology Competencies for Medical Education (PCME), a set of national standards for teaching pathology. These are divided into three basic competencies: Disease Mechanisms and Processes, Organ System Pathology, and Diagnostic Medicine and Therapeutic Pathology. For additional information, and a full list of learning objectives for all three competencies, see <https://www.journals.elsevier.com/academic-pathology/news/pathology-competencies-for-medical-education-pcme>.<sup>1</sup>

**Keywords:** Pathology competencies, Organ system pathology, Female reproductive-uterus, Uterine neoplasia, Endometrial carcinoma, Endometrial hyperplasia, Endometrial intraepithelial neoplasia

#### Primary objective

FU1.2 Endometrial carcinoma. Compare and contrast the precursors, clinical setting, risk factors, pathologic findings, and prognosis for type I and type II carcinomas of the endometrium.

Competency 2: Organ system pathology; Topic FU: Female reproductive—Uterus; Learning goal 1: Uterine neoplasia

#### Patient presentation

A 57-year-old nulligravid morbidly obese woman presents to the office with abnormal vaginal bleeding for the past three weeks. She denies any other symptoms including pain, constipation, dyspareunia, fatigue, weight change, or any urinary symptoms. The patient's last menstrual period was seven years ago. Her past medical history is negative for sexually transmitted infections and positive for well-controlled hypertension and type II diabetes mellitus. She had a normal Papanicolaou (Pap) smear earlier this year and has no history of any abnormal Pap screenings. She denies tobacco, alcohol, and illicit drug use. She denies surgical history except wisdom teeth extraction at age 18.

#### Diagnostic findings, Part 1

Vital signs are unremarkable and are within normal limits. On pelvic and bimanual examination, there is no uterine or adnexal tenderness or

masses. The vaginal epithelium is age appropriate with mild atrophy present. There are no vaginal lesions noted. No dried or frank blood is observed in the vagina or around the external cervical os.

#### Question/discussion point, Part 1

##### *What is the differential diagnosis for postmenopausal bleeding?*

For postmenopausal bleeding, there are various possible diagnoses that could include vaginal atrophy (most common in elderly female patients), cervical or endometrial polyps, uterine fibroids, adenomyosis, pelvic organ prolapse, or even bleeding from other sources such as the rectum, vulva, and urethra. Other more concerning differentials include endometrial hyperplasia, endometrial carcinoma (EC), cervical carcinoma, trauma, or sexual assault.

#### Diagnostic findings, Part 2

A pelvic ultrasound shows this patient's fallopian tubes and ovaries are normal in size and shape for the patient's age without cysts or masses. There is appropriate blood flow to both ovaries without free fluid in the pelvis. The uterus appears normal in size without overt fibroids. The endometrial lining is thickened, with an endometrial stripe thickness of 7.3 mm (> 4 mm is considered abnormal after menopause). Due to the thickened endometrial stripe on ultrasound, an endometrial biopsy (EMB) is obtained.

\* Corresponding author. Department of Pathology, University of North Dakota School of Medicine and Health Sciences, 1301 North Columbia Road, Mailstop 9037, Grand Forks, ND, 58202, USA.

E-mail address: [walter.kemp@mt.gov](mailto:walter.kemp@mt.gov) (W.L. Kemp).

<https://doi.org/10.1016/j.acpath.2022.100023>

Received 17 August 2020; Received in revised form 17 July 2021; Accepted 25 September 2021, Available online xxxx

eISSN2374-2895/© 2022 The Author(s). Published by Elsevier Inc. on behalf of Association of Pathology Chairs. This is an open access article under the CC BY-NC-ND license (<http://creativecommons.org/licenses/by-nc-nd/4.0/>).

## Questions/discussion points, Part 2

### Why was an endometrial biopsy obtained in this patient after an abnormally thick endometrial stripe was seen on ultrasound?

The use of ultrasound is a noninvasive, safe, and normally pain-free imaging modality for further evaluation of internal pathology. This makes ultrasound an ideal initial imaging test in the patient with presumed uterine pathology. However, it is limited in that multiple differential diagnoses can appear similar, if not the same, on ultrasound. For example, endometrial hyperplasia, uterine polyps, and EC can appear as a thickened endometrial stripe. In order to determine the specific abnormality causing the thickening, further evaluation is required (such as an EMB).

### Describe the histologic features of benign proliferative phase endometrium (Fig. 1)

The glandular epithelial cells of normal endometrium show elongated and oval-shaped nuclei of consistent size throughout the tissue without abnormal variation. The nuclei are not hyperchromatic. The well-defined glands have a smooth apical border, with consistent nuclear polarity (i.e., the nuclei being oriented to the apical end of the cell). (Fig. 1).

### Describe the histologic features of this patient's EMB as seen in Fig. 2). How does the appearance compare to benign proliferative phase endometrium as shown in Fig. 1?

The EMB image shows crowded endometrial type glands with minimal nuclear irregularity and minimal areas of solid architecture. There is an apical border that does not appear as smooth as normal endometrium. Based only upon the image, either a diagnosis of atypical endometrial hyperplasia or EC are possible; however, the image represents only a small portion of the biopsy. Based on the findings in all of the pathology slides (not shown), a diagnosis of EC is made.

### Describe the histologic features of type I and type II EC

Type I and type II ECs have different histologic features, incidence, risk factors, and prognosis. In general, type I is more endometrial-like, so it is aptly named endometrioid. In contrast, type II is less endometrial-like and therefore is named non-endometrioid.

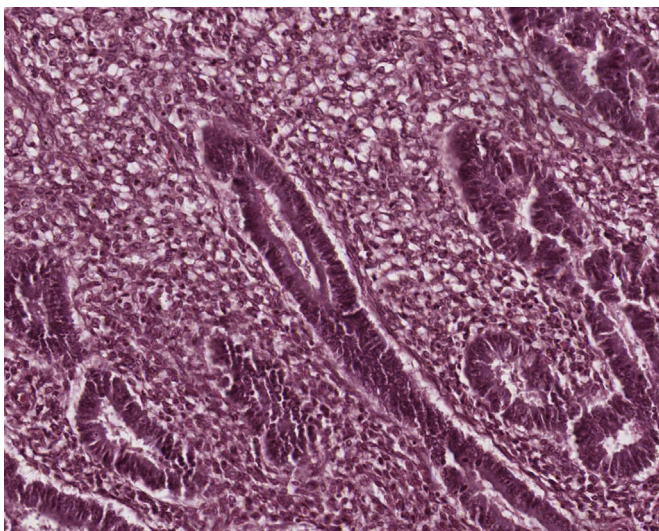


Fig. 1. Normal proliferative phase endometrium. Compared to typical hyperplasia (Fig. 4) and type I endometrioid carcinoma (Fig. 2), the gland to stroma ratio is normal (i.e., the glands are not crowded together). (H&E, 200x).

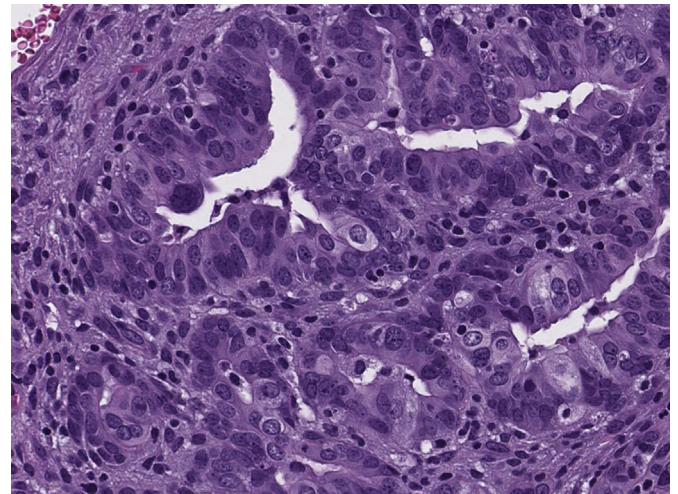


Fig. 2. Type I endometrioid carcinoma, FIGO grade 1. The tissue retains the general appearance of endometrium, with glands forming spaces; however, the nuclei have lost their polarity, are irregular in shape, and are hyperchromatic (H&E, 400x).

Type I EC (Fig. 2), maintains the rough architecture seen in normal endometrium. The number of glands is increased, and these glands begin to crowd each other, making it difficult at times to definitively distinguish one gland from a neighboring one—there is little to no stroma between the glands. The glands maintain their apical borders, though they are not as smooth as that of normal endometrium. The nuclei are more rounded and hyperchromatic and are noted to have a higher N:C ratio. Some cell polarity is maintained but not to the degree as seen in normal endometrium.

Type II non-endometrioid carcinoma (Fig. 3) is typically more anaplastic and less histologically related to normal endometrium as previously mentioned. The glands are still visible and there may be psammoma bodies present. The cells lining the glands have lost their polarity and they no longer share a strong apical border. Their chromatin staining is also hyperchromatic and again, there is a higher N:C ratio. There are also increased cellular size and shape irregularity. The abnormal tissue may also invade deeply or entirely through the myometrium.

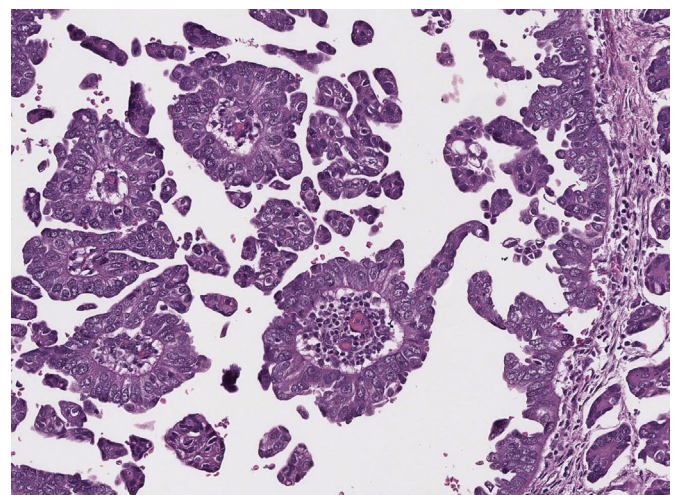


Fig. 3. Type II Non-endometrioid carcinoma, papillary serous. The tissue does not retain any semblance to normal endometrium, with instead the neoplastic cells forming papillae. The nuclei are hyperchromatic and irregular in shape, and there are numerous mitotic figures (H&E, 200x).

### What are the precursor histologic lesions to each type of EC?

Type I EC begins as a proliferative hyperplastic endometrium (Fig. 4). Increasing estrogen exposure leads to non-atypical hyperplasia, which represents a spectrum of alterations encompassing cystic dilation of glands, irregularity of gland dispersion, and increased ratio of glands to stroma. Non-atypical hyperplasia is functionally normal endometrial tissue responding to excessive estrogen. Once these cells mutate into precancerous cells and grow clonally, they are then classified as atypical hyperplasia. However, non-atypical hyperplasia does still contain a small 1–3% risk of cancer progression. Increasing estrogen exposure, paired with ongoing genetic mutations, especially involving the tumor suppressor gene *PTEN*, leads to endometrial intraepithelial neoplasia (EIN, also known as atypical hyperplasia, as stated above). EIN, the archetypal precancerous endometrioid lesion, carries an almost 40% risk of cancer development and as such warrants more aggressive investigation and treatment.<sup>2,3</sup> Of the patients diagnosed with only EIN on preoperative biopsy, 42.6% will still be diagnosed with endometrioid carcinoma after the hysterectomy specimen has been examined postoperatively.<sup>4</sup>

Type II non-endometrioid carcinomas are associated with atrophic endometrium. Following alterations in the tumor suppressor gene *TP53*, the tissue progresses to endometrial intraepithelial carcinoma (EIC). Serous carcinoma is the most common non-endometrioid subtype with over 90% of cases containing *TP53* mutations. This correlates with the fact that 75% of EIC contains a *TP53* mutation. This finding also points toward *TP53* mutations being an early lesion leading to eventual cancer.<sup>5,6</sup>

### Diagnostic findings, Part 3

Following the finalization of the EMB results, the patient is updated and is told the tissue shows she has a type I EC. The patient has multiple questions about her diagnosis and is visibly concerned at the news of her cancer diagnosis.

### Questions/discussion points, Part 3

#### What is the incidence of EC?

EC is the most common gynecologic cancer and fourth most common female cancer in developed countries behind neoplasms of the breast, lung, and colon.<sup>7</sup> Women possess an estimated 3.11% lifetime risk of developing

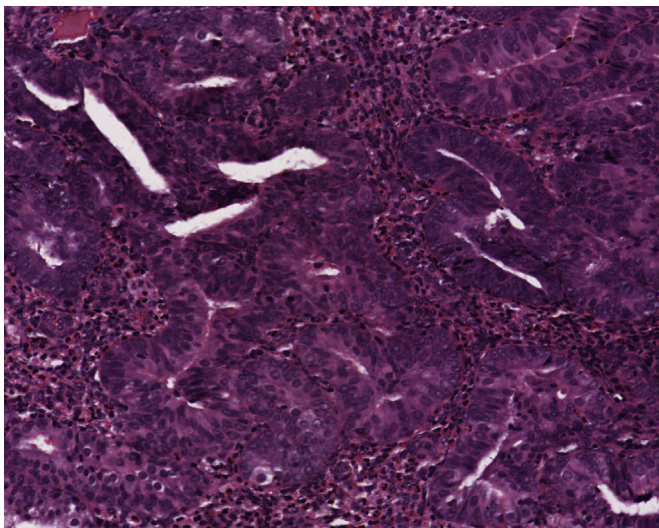


Fig. 4. Typical hyperplastic endometrium. The tissue retains the appearance of endometrium; however, the glands are crowded together, with a higher ratio of glands to stroma than normal. The nuclear abnormalities seen in endometrial carcinoma (Figs. 2 and 3) are not observed (H&E, 400x).

endometrial cancer regardless of other risk factors. According to the Surveillance, Epidemiology, and End Results (SEER) Program, approximately 93.5% of patients diagnosed with endometrial cancer are between the ages of 45–74 years, with approximately 27.8 new cases per 100,000 women reported each year. Most cases occur between the ages 65–69 years with an incidence of 117.4 per 100,000 women. The median age of diagnosis is 63 years, while the median age of cancer-related death is 70 years.<sup>8</sup>

Type I accounts for over 80% of all EC cases. Type II is responsible for a much smaller percentage of total patients with endometrial cancer but constitutes approximately 74% of cancer-related mortality.<sup>9</sup> The mortality rates for both types of EC remain low, however, with an overall combined mortality rate of 2.3% (discussed later in further detail).<sup>8</sup>

### What are the common risk factors for type I and type II EC?

Type I EC are estrogen-dependent cancers and therefore rely heavily on increased estrogen exposure for cancer progression.

This estrogen can be derived from an endogenous or exogenous source. Common endogenous estrogen sources include estrogen-secreting tumors (e.g., granulosa cell, thecoma, teratoma), nulliparity, menstrual irregularities (as occur in polycystic ovarian syndrome (PCOS) or infertility), early menarche (before age 12), and late menopause (after age 51).<sup>10</sup> Obesity additionally increases endogenous estrogen levels by enhancing the peripheral conversion of sex androgens to estrogen via aromatase. Prior studies have shown that as body mass index (BMI) extends beyond 25 kg/m<sup>2</sup>, there is a 200–400% linear increase in the risk of endometrial cancer development.<sup>11</sup>

Medications are responsible for exogenous increases in estrogen. These commonly include selective estrogen receptor modulators (SERMs), such as tamoxifen, and hormone replacement therapy (HRT) for menopausal vasomotor symptoms.<sup>12,13</sup> These medications and estrogen-based vaginal creams will be discussed in more detail below.

Other general risk factors are White race, late adulthood (commonly 55–65 years old), and possible genetic germline mutations. These genetic causes could include syndromes such as hereditary nonpolyposis colorectal cancer (HNPCC) (also known as Lynch syndrome) and Cowden syndrome.<sup>5,7</sup> Hypertension and diabetes have also been demonstrated to increase the risk of EC development. While this may be due to confounding comorbid conditions, some studies have shown that insulin resistance itself may be an independent risk factor.<sup>5,14,15</sup>

Type II non-endometrioid carcinomas are more commonly found in patients without risk factors for hyperestrogenism. Common risk factors for type II non-endometrioid carcinomas include Black race, advanced age (frequently 65–75 years old), and a positive history of tobacco use.<sup>5,7</sup> Tobacco use is a risk factor for type II non-endometrioid carcinoma but has been found to be protective for type I endometrioid carcinoma. This is thought to be due to multiple mechanisms. Patients who smoke normally have a leaner physique leading to less peripheral conversion of sex androgens to estrogen. Tobacco use increases progesterone levels and lowers the age of menopause due to the destruction of oocytes over time. Estrogen is also shunted toward 2-hydroxyesterone, which has been noted to have some anticarcinogenic effects on the endometrium.<sup>16</sup>

### What patient specific risk factors are present in this case?

While we do not have a complete history, we do know some key risk factors. This patient has a history of hypertension, diabetes, increased adipose tissue, and has never been pregnant or had children. She went through menopause seven years ago, meaning she was 50 years old. Her age at menopause would not be considered a risk factor (Table 1).

### How does exogenous estrogen exposure increase a patient's risk of developing EC?

Estrogen and progesterone are tightly intertwined during the menstrual cycle. As the uterus prepares for possible pregnancy, estrogen

**Table 1**  
Characteristics of type I versus type II EC.

	Type I Endometrioid carcinoma	Type II Non-endometrioid carcinoma
Race	White	Black
Tobacco use	Negative	Positive
Average age at diagnosis	55–65 years	Older than endometrioid carcinoma
Body mass index (kg/m <sup>2</sup> )	Elevated, greater than 30	Normal, 18–25
Age of menarche (years)	Younger age, less than 12	Later age, 12–14
Age of menopause (years)	After average age (51) or greater	Before or at average age
Past medical history	Diabetes mellitus, polycystic ovarian syndrome, infertility	Absence of medical problems seen in type I
Past social history	No tobacco use	Tobacco use likely
Parity	0	Multiple, greater than 0
Precursor lesion	Endometrial intraepithelial neoplasia	Endometrial intraepithelial carcinoma
Prominent genetic drivers	<i>PTEN</i>	<i>TP53</i>
Prognosis	Generally good	Generally poor
Brief morphology prior to cancer progression	Proliferative, hyperplastic endometrium	Non-proliferative, atrophic endometrium

levels rise and lead to the proliferation of the endometrial lining. Estrogen peaks twice during the cycle, once at ovulation and then again during the mid-luteal phase (second half of the menstrual cycle). During the mid to late luteal phase, progesterone levels also increase, leading to inhibition of estrogen's normal proliferative effects.<sup>12</sup> The loss of this hormonal balance has been highly associated with progression to EC.<sup>17</sup>

Despite this awareness, as with everything in medicine, one must weigh the risks and benefits of treatment options with patients. Tamoxifen is a SERM with estrogen receptor antagonist activity used for the treatment of breast cancer but possesses agonist activity at the endometrial lining. Raloxifene, while also a SERM, lacks the agonist activity in endometrial tissue but falls short of tamoxifen's effectiveness for breast cancer treatment. Tamoxifen's risk of EC is noted to increase with continued use over time, especially in those patients who are obese and over the age of 50.<sup>18,19</sup>

HRT with estrogen for the treatment of menopausal vasomotor symptoms also increases the risk of endometrial cancer. Even with the addition of progesterone, HRT still carries an increased risk of endometrial proliferation. Unopposed estrogen leads to a 20% risk of endometrial hyperplasia, while progesterone use decreases this risk to 5.4%.<sup>20</sup> It should also be noted that topically applied estrogen for vaginal atrophy is not associated with an increased risk of cancer development.<sup>21</sup>

## Diagnostic findings, Part 4

After answering the patient's questions, and further discussion on risks, benefits, and alternative treatments, she desires surgical management and elects for a total laparoscopic hysterectomy with bilateral salpingo-oophorectomy. During surgery, the uterus is removed and is sent for pathological examination for depth of carcinoma invasion into the myometrium. Examination reveals invasion less than 30% into the myometrium. No sentinel lymph node biopsy is indicated since the depth of invasion is less than 50%. The final pathological examination reveals type I endometrioid carcinoma, Stage 1.

## Questions/discussion points, Part 4

### How are EC graded and staged?

The International Federation of Gynecology and Obstetrics (FIGO) has created three histopathologic grades, which are used to describe the

degree of similarity between abnormal and normal tissue.<sup>22,23</sup> FIGO grades are:

**GX:** Grade cannot be assessed

**G1:** Well-differentiated, less than or equal to 5% solid growth pattern

**G2:** Moderately-differentiated, less than 50% solid growth pattern but greater than 5%

**G3:** Poorly-differentiated, greater than 50% solid growth pattern

A large majority of type I endometrioid carcinomas are grades 1 and 2, with a minority being grade 3. Type II non-endometrioid cancers are always grade 3.<sup>22</sup>

FIGO and the American Joint Committee on Cancer (AJCC) have separate but very similar staging systems, both of which account for uterine and extrauterine tumor involvement. The AJCC and FIGO EC staging ranges from Stage I to Stage IV. Stage I/T1 tumors are confined to the uterine body. Stage II/T2 tumors involve cervical stroma without extending beyond the uterus. Stage III/T3 tumors begin to extend to the adnexa, vagina, and/or local lymph nodes (pelvic and paraaortic). Stage IV/T4 have more distant spread including the bladder, bowel, other intra-abdominal organs, inguinal lymph nodes, etc.<sup>22,23</sup> FIGO remains a more surgical-based staging system due to ECs treatment typically involving surgery. These stages can vary slightly over time, so it is important to compare them to the latest guidelines when determining cancer stage.

### How is EC typically treated?

This is an extremely broad topic as patients with the same staging can have drastically different treatment plans depending on comorbidities, prior surgeries, age, ability to undergo the surgery, desire for children (especially if diagnosed at a young age), etc. However, based on the staging, there are general treatment plans that each stage will follow. Regardless of EC stage, however, surgical management is normally first line treatment with subsequent removal of the uterus and, most likely, the fallopian tubes and ovaries.

For Stage I tumors, total hysterectomy with bilateral salpingo-oophorectomy is usually the only treatment needed with subsequent follow up to monitor for return of the cancer. Stage II expands upon the above surgery and is sometimes paired with removal of the upper part of the vagina as well (radical hysterectomy). This is normally paired with pelvic and para-aortic lymph node dissection or sampling. After recovery from surgery, the patient undergoes post-operative radiation therapy (usually external pelvic radiation and brachytherapy). If too frail for surgery, radiation alone can be the treatment of choice. If the lymph nodes are negative for cancerous cells on sampling/dissection, then the tissue remains at Stage II. If cancerous cells are found within the lymph nodes, the cancer is considered Stage III. For Stage III tumors, if visible, suspicious tissue is seen during surgery, these sections may be removed (debulking procedures), and then paired with those post-operative radiation therapies as recommended for Stage II. During surgery, pelvic washing (an attempt to remove cancer cells dislodged during the procedure) and removal of the omentum can also be performed. At this stage, chemotherapy may also be added to the treatment plan. Stage IV combines all the above treatment options as well as more aggressive debulking procedures and sampling of tissue outside the pelvis. Hormone therapy, especially if detectable progesterone and estrogen receptors are found, can also be initiated. Newer methods might also include immunotherapy and targeted therapy in the future.<sup>24</sup>

What is the prognosis of type I and type II EC? What is the mortality of EC types based on age and race?

The SEER database tracks multiple data points for EC but does not group data based on cancer staging, so there is no direct translation of prognosis to stage—instead, one must look at their data based on the localization of the cancer, regional spread, or distant spread, and then correlate with the AJCC/FIGO staging systems.

Relative five-year survival for all patients regardless of EC type, patient age, race, or stage is 81.2%. This survival rate increases to 95% if the cancer is localized, as was seen in this patient (Stage 1a,

localized), but drops to 69.4% when associated with regional lymph node spread. This rate decreases further to 17.3% if associated with distant spread (i.e. metastasis), and 53.2% with an unknown or unstaged cancer.<sup>8</sup>

With respect to age only: Approximately 86.8% of patients are diagnosed with EC at age 50 or greater with an associated mortality rate of 16.9%. However, the mortality rate drops to only 0.5% if women are diagnosed before age 50. The highest mortality rate for all patients based on age is found in those 85 years or older at 32.6 deaths per 100,000 women. The rate drops to 20.7 deaths per 100,000 women for ages 65–69, which is also the highest incidence age group.<sup>8</sup>

With respect to race only: Black women have an overall five-year survival rate of 62.7%, which supports the fact that they are commonly diagnosed with the more aggressive type II EC. Even when examining those below age 50, the five-year survival rate is still only 79.1%. For patients 85 years and older, the mortality rate is 42.5 per 100,000 and an even higher rate of 44.0 per 100,000 for ages 65–69. Mortality rates for those 50 years and older are much higher at 30.2% though for those under age 50 the rate is 0.61%, which is closer to the 0.5% overall rate as discussed above.<sup>8</sup>

## Teaching points

- Women with postmenopausal vaginal bleeding should be evaluated for EC and possible precancerous lesions, regardless of risk factors.
- Evaluation should include a transvaginal ultrasound to check for endometrial stripe thickness and/or endometrial biopsy for histological evaluation.
- EC is the most common gynecologic cancer and the fourth most common female cancer behind breast, lung, and colon cancers.
- Presentation at an early age should prompt possible evaluation for genetic and/or hereditary causes such as Lynch Syndrome.
- Estrogen-containing drugs increase the risk of EC. HRT's risk, however, can be reduced by concurrently prescribing progesterone.
- Type I EC is more common, estrogen-dependent, indolent, with a good prognosis, and usually remains intrauterine. *PTEN* mutations are common. The associated precursor lesion is endometrial intraepithelial neoplasia (atypical hyperplasia).
- Type II EC is less common, estrogen-independent, aggressive, with a worse prognosis with respect to type I, and commonly spreads outside the uterus. *TP53* mutations are common. The associated precursor lesion is endometrial intraepithelial carcinoma.
- Regardless of cancer staging, almost all treatments will involve surgery, usually in the form of a hysterectomy with bilateral salpingo-oophorectomy.
- As the stage of cancer increases, the prognosis continues to worsen and the associated treatment becomes more complex and invasive.

## Funding

The article processing fee for this article was funded by an Open Access Award given by the Society of '67, which supports the mission of the Association of Pathology Chairs to produce the next generation of outstanding investigators and educational scholars in the field of pathology. This award helps to promote the publication of high-quality original scholarship in *Academic Pathology* by authors at an early stage of academic development.

## Declaration of competing interest

The authors report no conflicts of interest.

## References

1. Knollmann-Ritschel BEC, Regula DP, Borowitz MJ, Conran R, Prystowsky MB. Pathology competencies for medical education and educational cases. *Acad Pathol*. 2017;4. doi:10.1177/2374289517715040
2. Mutter GL, Prat J. The female reproductive system and peritoneum. In: Strayer DS, Rubin E, Saffitz JE, Schiller AL, eds. *Rubin's Pathology: Clinicopathologic Foundations of Medicine*, 7th ed. Wolters Kluwer Health; 2015:995–1053.
3. Endometrial intraepithelial neoplasia. Committee opinion No. 631. *Obstet Gynecol*. 2015;125(5):1272–1278.
4. Trimble CL, Kauderer J, Zaino R, et al. Concurrent endometrial carcinoma in women with a biopsy diagnosis of atypical endometrial hyperplasia: a Gynecologic Oncology Group study. *Cancer*. 2006;106(4):812–819. doi:10.1002/ncr.21650
5. Ellenson LH, Pirog EC. The female genital tract. In: Kumar V, Abbas AK, Aster JC, eds. *Robbins and Cotran Pathologic Basis of Disease*. 9th ed. Elsevier/Saunders; 2015: 992–1041.
6. Lobo FD, Thomas E. Type II endometrial cancers: a case series. *J Midlife Health*. 2016; 7(2):69–72. doi:10.4103/0976-7800.185335
7. Endometrial Cancer. Practice bulletin No. 149. American college of obstetricians and gynecologists. *Obstet Gynecol*. 2015;125(2):1006–1026.
8. Howlander N, Noone AM, Krapcho M, et al. *SEER Cancer Statistics Review*. National Cancer Institute; 1975–2017. Accessed April 27, 2020. [https://seer.cancer.gov/csr/1975\\_2017/](https://seer.cancer.gov/csr/1975_2017/)
9. Black JD, English DP, Roque DM, Santin AD. Targeted therapy in uterine serous carcinoma: an aggressive variant of endometrial cancer. *Wom Health*. 2014;10(1): 45–57. doi:10.2217/whe.13.72
10. Biro FM, Pajak A, Wolff MS, et al. Age of menarche in a longitudinal US cohort. *J Pediatr Adolesc Gynecol*. 2018;31(4):339–345. doi:10.1016/j.jpag.2018.05.002
11. Bianchini F, Kaaks R, Vainio H. Overweight, obesity, and cancer risk. *Lancet Oncol*. 2002;3(9):565–574. doi:10.1016/S1470-2045(02)00849-5
12. Beral V, Bull D, Reeves G. Endometrial cancer and hormone-replacement therapy in the million women study. *Lancet*. 2005;365(9470):1543–1551. doi:10.1016/S0140-6736(05)66455-0
13. Casanova R, Chuang A, Goepfert AR, et al. Cancer of the uterine corpus. In: *Beckmann and Ling's Obstetrics and Gynecology*. 8th ed. Lippincott Williams & Wilkins; 2018: 406–414.
14. Aune D, Sen A, Vatten LJ. Corrigendum: hypertension and the risk of endometrial cancer: a systematic review and meta-analysis of case-control and cohort studies. *Sci Rep*. 2018;8(1):46961. doi:10.1038/srep46961
15. Saed L, Varse F, Baradaran HR. The effect of diabetes on the risk of endometrial Cancer: an updated a systematic review and meta-analysis. *BMC Cancer*. 2019;19(1): 1–10. doi:10.1186/s12885-019-5748-4
16. Felix AS, Yang HP, Gierach GL, Park Y, Brinton LA. Cigarette smoking and endometrial carcinoma risk: the role of effect modification and tumor heterogeneity. *Cancer Causes Control*. 2014;25(4):479–489. doi:10.1007/s10552-014-0350-1
17. Rodriguez AC, Blanchard Z, Maurer KA, Gertz J. Estrogen signaling in endometrial cancer: a key oncogenic pathway with several open questions. *Horm Cancer*. 2019; 10(3):51–63. doi:10.1007/s12672-019-0358-9
18. Magriples U, Naftolin F, Schwartz PE, Carcangiu ML. High-grade endometrial carcinoma in tamoxifen-treated breast cancer patients. *J Clin Oncol*. 1993;11(3): 485–490. doi:10.1200/JCO.1993.11.3.485
19. Hu R, Hilakivi-Clarke L, Clarke R. Molecular mechanisms of tamoxifen-associated endometrial cancer (Review). *Oncol Lett*. 2015;9(4):1495–1501. doi:10.3892/ol.2015.2962
20. Feeley KM, Wells M. Hormone replacement therapy and the endometrium. *J Clin Pathol*. 2001;54(6):435–440. doi:10.1136/jcp.54.6.435
21. Constantine GD, Graham S, Lapane K, et al. Endometrial safety of low-dose vaginal estrogens in menopausal women: a systematic evidence review. *Menopause*. 2019; 26(7):800–807. doi:10.1097/GME.0000000000001315
22. Early Detection, Diagnosis, and Staging: Endometrial Carcinoma Stages. *American Cancer Society*. Updated March 27, 2019. Accessed April 10, 2020. <https://www.cancer.org/cancer/endometrial-cancer/detection-diagnosis-staging/staging.html>
23. Amant F, Mirza MR, Koskas M, Creutzberg CL. Cancer of the corpus uteri. *Int J Gynecol Obstet*. 2018;143:37–50. doi:10.1002/ijgo.12612
24. Treatment choices for endometrial cancer, by stage. American Cancer Society. Updated September 17, 2019. Accessed October 14, 2020. <https://www.cancer.org/cancer/endometrial-cancer/treating/by-stage.html>