

Transvenous embolization in spontaneous direct carotid-cavernous fistula in childhood

Glenna B. Mercado¹, Keiko Irie, Makoto Negoro, Shigeta Moriya, Teppei Tanaka, Masahiro Ohmura, Akiyo Sadato, Motuharu Hayakawa, Hirotochi Sano

Department of Neurosurgery, Fujita Health University Hospital, Endovascular Section, Toyoake, AICHI, Japan, ¹Consultant in Neurosurgery, Angeles University Foundation Medical Center, Angeles City, Pampanga, Philippines

ABSTRACT

Carotid cavernous fistula (CCF) is an abnormal arteriovenous communication in the cavernous sinus. Direct CCF results from a tear in the intracavernous carotid artery. Typically, it has a high flow and usually presents with oculo-orbital venous congestive features such as exophthalmos, chemosis, and sometimes oculomotor or abducens cranial nerve palsy. Indirect CCF generally occurs spontaneously with subtle signs. We report a rare case of spontaneous direct CCF in childhood who did not have the usual history of craniofacial trauma or connective tissue disorder but presented with progressive chemosis and exophthalmos of the right eye. This report aims also to describe the safety and success of transvenous embolization with coils of the superior ophthalmic vein and cavernous sinus through the inferior petrosal sinus.

Key words: Childhood, direct carotid cavernous fistula, transvenous embolization

Introduction

The two main types of fistulas in the region of cavernous sinus are direct arteriovenous (AV) fistula, a true carotid cavernous fistula (CCF), and dural AV fistula. The latter is located in the cavernous sinus which has a gradual onset and usually improves spontaneously. Direct CCF is commonly caused by craniofacial injury and in majority of cases the AV communication is a single hole. Spontaneous CCF may also develop with rupture of an intracavernous aneurysm or where there is vessel fragility in association with atherosclerosis, so-called Ehlers-Danlos syndrome^[1] or fibromuscular dysplasia, which was ruled out in this patient. There have been few reports of the occurrence of CCF in children. Signs and symptoms and natural history though have been observed to be similar in adults.^[2-4] Congenital CCF has been reported to be treated successfully with endovascular occlusion.^[5] However,

two case reports in childhood presented a benign course, which were managed conservatively by ocular control. Doppler examination of the superior ophthalmic vein (SOV) and follow-up angiography showed spontaneous closure of the fistula.^[2,3] Blood flow through the shunt is usually fast, especially when the hole is large and spontaneous closure is rare. The preferred treatment has been endovascular occlusion procedure. Although the mainstay of treatment of the direct cavernous fistula is transarterial detachable balloon embolization of the affected cavernous sinus, transvenous embolization using coils has recently been applied with increasing acceptability because of its safety and high success rates.

Case Report

A 3-year-old male was brought in the outpatient clinic because of hyperemia and progressive proptosis of the right eye for one month. There was no history of head trauma and no family history of connective tissue disease. He has no symptoms of increased intracranial pressure or signs of neurologic or cranial nerve deficits. An initial noncontrast computed tomography scan showed a dilated right SOV and exophthalmos of the right orbit, a finding that prompted a referral to the neuroendovascular service. Initial workup was a right transfemoral arterial angiography under general anesthesia. The right internal carotid angiography showed a direct type of CCF at the level of C₄ and the draining veins are the SOV anteriorly and the inferior petrosal sinus (IPS) posteriorly [Figure 1a and b]. There was no cortical venous reflux. Patient is negative for any connective tissue disorder

Access this article online	
Quick Response Code:	Website: www.asianjns.org
	DOI: 10.4103/1793-5482.85637

Address for correspondence:

Dr. Glenna B. Mercado, Consultant in Neurosurgery, Angeles University Foundation Medical Center, Angeles City, Pampanga, Philippines. E-mail: gbmercado_md@yahoo.com

after a genetic analysis. Due to the progressive ophthalmologic problem, the patient underwent coil embolization through the transvenous approach.

Endovascular procedure was started aseptically with patient under general anesthetics. A 4F sheath was inserted through the right transfemoral artery to the right internal carotid artery (ICA) to obtain a baseline angiography. Road-map images were done during the procedure. Injections into the contralateral ICA and vertebral artery were done to check the retrograde filling of the carotid siphon through the anterior communicating artery and posterior communicating artery and showed a poor collateral flow of the right ICA. Activating clotting time was elevated by intravenously infusing 1000 units heparin. Another 4F catheter was inserted through the left transfemoral vein going to the right internal jugular vein (IJV) into the right IPS, then into the cavernous sinus, and eventually into the right SOV using a Prowler-plus micro catheter (Cordis) with

GT 0.012, 45° angle microguide wire. A total length of 276 cm from 28 coils were detached and densely packed from the right SOV to the cavernous sinus. Post-embolization angiography and plain skull X-rays showed dense coiling and complete disappearance of AV shunts, which signifies total occlusion of the fistula and preservation of the patency of the right ICA [Figures 2a and b, 3a and b]. The vital signs were stable in the entire duration of the procedure. He was monitored in the neurosurgery intensive care unit for 24 hours post-embolization. A gradual improvement of the chemosis on the right eye was noted and was discharged after a week without complication. On one-month follow-up, exophthalmos and chemosis on the right eye have completely resolved.

Discussion

Indeed, there have been few reports of CCF in children. Although the preferred treatment has been endovascular

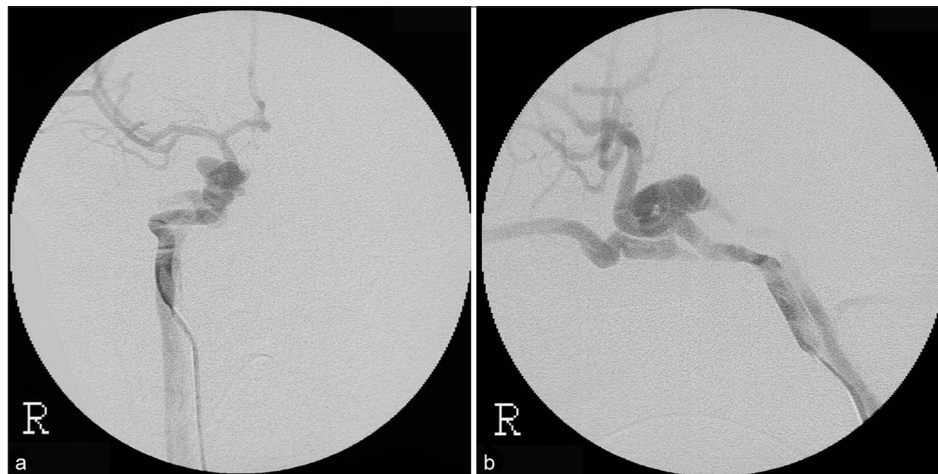

Figure 1: Pre-embolization angiography AP (a) and lateral (b) views showing the fistula at the level of C₄ of the right ICA shunting to the right SOV, right IPS and cavernous sinus

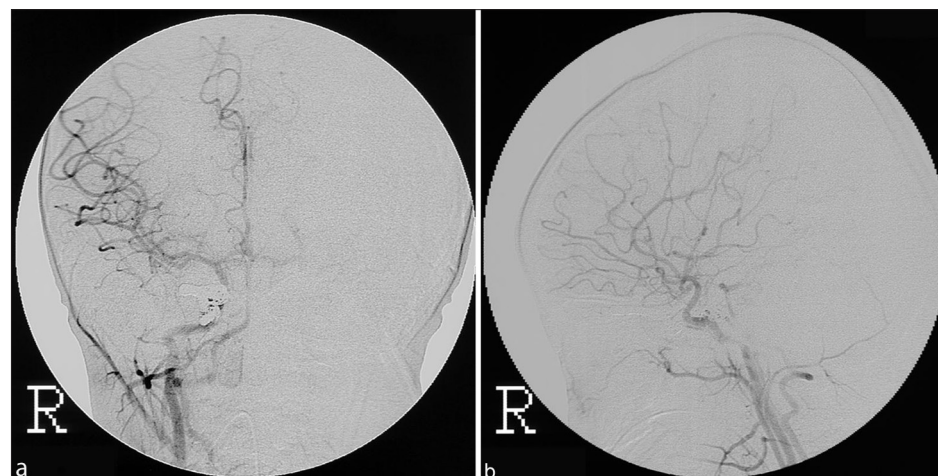


Figure 2: Post-embolization angiography AP (a) and lateral (b) views showing complete disappearance of AV shunts and the preservation of the patency of the right ICA

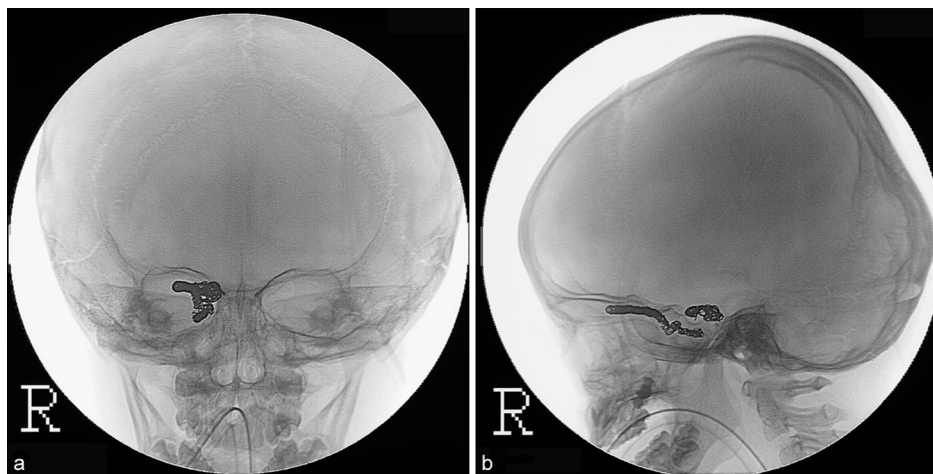


Figure 3: Plain skull X-ray AP (a) and lateral (b) views showing dense coiling of the right SOV and cavernous sinus

occlusion procedure, transvenous embolization using coils has recently been applied with increasing acceptability because of proven safety and high success rates.

It is preferable to wait for 1 to 2 weeks from the clinical onset of the fistula before doing the endovascular closure, because after a recent injury, the carotid artery may have a greater reactivity to endovascular navigation and is more at risk of damage to the wall. However, some fistulas require treatment at the acute phase when they manifest clinical and angiographic features of venous hypertension within the draining leptomeningeal and cortical veins, for these have the higher risk for cerebral hemorrhage. Direct spontaneous CCF in our patient has high flow based on Barrow's classification.^[6] This type of fistula usually presents with ocular-venous congestive features such as exophthalmos and chemosis, and cephalic bruit.

The goal of endovascular treatment is to completely occlude the fistula but preserve the patency of ICA. The agents used for this procedure include detachable coils, liquid embolic agents, and detachable balloons or non-covered or covered stents delivered transarterially^[5,7,8] or transvenously. The traditional approach has been transarterial embolization with detachable balloons which was first reported in 1978,^[9] but this method is currently not being used in Japan. Transvenous embolization, on the other hand, has been accepted as the preferred treatment for CCF.^[10-13] The transvenous route usually involves a retrograde or posterior path through the IJV, and the IPS up to the cavernous sinus.^[11,13] According to one article, the IPS route is the most direct approach and relatively safe,^[13] but excessively tight packing of CCF can result in transient oculomotor or abducens nerve palsy and occlusion of the ICA. Protrusion of coils in the ICA with a large fistula can also occur and may cause occlusion as well, but protrusion may be prevented by placement of a non-detachable balloon along the fistula in the ICA. Other complications include subarachnoid hemorrhage if the IPS is injured. Another option, if the IPS is occluded or absent, is an anterior approach through the

SOV through the facial vein^[12,13] or a direct surgical access to the SOV, but in the authors' opinion, this method is not applicable to a pediatric patient. Occlusion of the arterial segment with fistula that is not amenable to endovascular occlusion was also described in one article.^[10]

In conclusion, this report has described a rare occurrence of spontaneous direct CCF in childhood managed with transvenous approach through the IPS. Most importantly, the endovascular treatment employed has proven to be safe and effective.

References

- Hollands JK, Santarius T, Kirkpatrick PJ, Higgins JN. Treatment of a direct carotid-cavernous fistula in a patient with type IV Ehlers-Danlos syndrome: A novel approach. *Neuroradiology* 2006;48:491-4.
- Kurul S, Cakmakci H, Kovanlikaya A, Dirik E. Case Report: The benign course of carotid-cavernous fistula in a child. *Eur J Radiol* 2001;39:77-9.
- Lau FH, Yuen HK, Rao SK, Lam DS. Spontaneous Carotid Cavernous Fistula in a Pediatric Patient: Case Report and Review of Literature *J AAPOS* 2005;9:292-4.
- Gossman MD, Berlin AJ, Weinstein MA, Hahn J, Price RL. Spontaneous direct Carotid-cavernous fistula in childhood. *Ophthalm Plast Reconstr Surg* 1993;9:62-5.
- Cohen JE, Gomori JM, Grigoriadis S, Rajz G. Endovascular treatment of congenital carotid-cavernous fistula in infancy. *Neurol Res* 2008;30:649-51
- Barrow DL, Spector RH, Braun IF, Landman JA, Tindall SC, Tindall GT. Classification and treatment of spontaneous carotid-cavernous fistulas. *J Neurosurg* 1985;62:248-56.
- Li MH, Tan HQ, Fang C, Zhu YQ, Wang W, Wang J, *et al.* Transarterial embolisation therapy Of dural carotid-cavernous fistulae using low concentration n-butylcyanoacrylate. *Acta Neurochir (Wien)* 2008;150:1149-56.
- Gupta AK, Sukalyan P, Krishnamoorthy T, Bodhey NK, Kapilamoorthy TR, Kesavadas C, *et al.* Endovascular treatment of direct caotid cavernous fistulae: A pictorial review. *Neuroradiology* 2006;48: 831-9.
- Debrun G, Lacour P, Caron JP, Hurth M, Comoy J, Keravel Y. Detachable balloon and calibrated-leak balloon techniques in the treatment of cerebral vascular lesions. *J Neurosurg* 1978;49: 635-49.
- Gemmete JJ, Sameer AA, Gandhi DM. Endovascular techniques for

treatment of carotid-cavernous fistula. J Neuroophthalmol 2009;29:62-71.

11. Klisch J, Huppertz HJ, Spetzger U, Hetzel A, Seeger W, Schumacher M. Transvenous treatment of carotid cavernous and dural arteriovenous fistulae: Results of 31 patients and review of the literature. Neurosurgery 2003;53:836-56.
12. Biondi A, Milea D, Cornard C, Ricciardi GK, Bonneville F, van Effenterre R. Cavernous sinus dural fistulae treated by transvenous approach through the facial vein: Report of seven cases and review of literature. AJNR AM J Neuroradiol 2003;1240-6.
13. Bing F, Albrieux M, Vinh Moreau-Gaudry V, Vasdev A. Cavernous

sinus fistula treated through the transvenous approach: Report of four cases. J Neuroradiol 2009;157:1-5.

How to cite this article: Mercado GB, Irie K, Negoro M, Moriya S, Tanaka T, Ohmura M, *et al.* Transvenous embolization in spontaneous direct carotid-cavernous fistula in childhood. Asian J Neurosurg 2011;6:45-8.

Source of Support: Nil, **Conflict of Interest:** None declared.