



Case Report

Total knee replacement in patients with diffuse villonodular synovitis[☆]



Lucio Flávio Biondi Pinheiro Junior^{a,*}, Marcos Henrique Frauendorf Cenni^a,
Rafael Henriques Soares Leal^b, Luiz Eduardo Moreira Teixeira^c

^a Rede Mater Dei de Saúde, Belo Horizonte, MG, Brazil

^b Hospital da Unimed, Belo Horizonte, MG, Brazil

^c Universidade Federal de Minas Gerais, Hospital das Clínicas, Belo Horizonte, MG, Brazil

ARTICLE INFO

Article history:

Received 8 July 2016

Accepted 16 August 2016

Available online 14 August 2017

Keywords:

Villonodular pigmented synovitis

Arthroscopy

Knee

Giant cell tumors

Palavras-chave:

Sinovite pigmentada vilonodular

Artroscopia

Joelho

Tumores de células gigantes

ABSTRACT

This paper reports a case of diffuse pigmented villonodular synovitis (DPVNS), associated with advanced gonarthrosis, submitted to total knee replacement. The patient had progressive pain and swelling. She had two previous surgeries, firstly arthroscopic synovectomy and subsequently open synovectomy associated with radiotherapy, with recurrence of the disease. Magnetic resonance imaging revealed diffuse synovitis, advanced arthrosis, and bone cysts. The patient was submitted to a total knee replacement and synovectomy. There was a good postoperative clinical course, with improvement of pain, function, and joint edema on examination. The patient will be followed regarding the possibility of disease recurrence and implant survival.

© 2017 Published by Elsevier Editora Ltda. on behalf of Sociedade Brasileira de Ortopedia e Traumatologia. This is an open access article under the CC BY-NC-ND license (<http://creativecommons.org/licenses/by-nc-nd/4.0/>).

Artroplastia total do joelho em paciente com sinovite vilonodular pigmentada forma difusa

RESUMO

Este trabalho relata um caso de sinovite vilonodular pigmentada forma difusa (SVNPD), associada a genoartrose avançada, que foi submetida a artroplastia total do joelho. A paciente apresentava dor e edema em joelho de caráter progressivo, já submetida previamente a duas sinovectomias, uma por via artroscópica e outra por via aberta, além de radioterapia, com recidiva da doença. As radiografias demonstravam obliteração dos espaços

[☆] Paper developed at the network Mater Dei de Saúde, Belo Horizonte, MG, Brazil.

* Corresponding author.

E-mail: lucibiondi@terra.com.br (L.F. Pinheiro Junior).

<http://dx.doi.org/10.1016/j.rboe.2017.08.002>

2255-4971/© 2017 Published by Elsevier Editora Ltda. on behalf of Sociedade Brasileira de Ortopedia e Traumatologia. This is an open access article under the CC BY-NC-ND license (<http://creativecommons.org/licenses/by-nc-nd/4.0/>).

articulares, além de erosões e cistos intraósseos na tíbia e no fêmur. Ressonância magnética evidenciou sinovite difusa extensa, além de artrose avançada e cistos ósseos. A paciente foi submetida a artroplastia total do joelho combinada com sinovectomia ampla. Ela apresentou boa evolução clínica pós-operatória, com melhoria da dor, da função e do edema. A paciente será acompanhada quanto à possibilidade de recorrência da doença e sobrevida do implante.

© 2017 Publicado por Elsevier Editora Ltda. em nome de Sociedade Brasileira de Ortopedia e Traumatologia. Este é um artigo Open Access sob uma licença CC BY-NC-ND (<http://creativecommons.org/licenses/by-nc-nd/4.0/>).

Introduction

Pigmented villonodular synovitis is a rare, benign and proliferative disease of the synovial tissue of uncertain etiology that can determine the destruction of joint cartilage and result in osteoarthritis.¹ Simon described the localized type of the knee and Moser, in 1909, described the diffuse type of the disease. Jaffe et al.² proposed the term pigmented villonodular synovitis for these manifestations, but the nomenclature proposed by Granowitz defined that the term pigmented villonodular synovitis should be used for intra-articular lesions, pigmented villonodular bursitis for lesions located in the bursae and pigmented villonodular tenosynovitis for lesions originating from tendinous sheaths.

This pathology can be divided into two types: localized and diffuse. The most common type is the diffuse one. It is more frequent between 20 and 50 years of age but can reach any age, with a slight prevalence in females. The treatment aims at the resection of the lesion, both arthroscopically and/or via open surgery, with local recurrence between 10% and 56%.³

This work describes a case of diffuse villonodular pigmented synovitis affecting the right knee, that was associated with advanced gonarthrosis and underwent total replacement.

Clinical case

A 65-year-old white female patient, who was a housewife and presented with pain, functional restriction, and right knee edema. Diagnosed with diffuse villonodular synovitis for 20 years, she had undergone arthroscopic synovectomy at the time. After a few years, she progressed with relapse of the disease, and eight years ago she underwent a new synovectomy, via open anterior incision surgery, followed by radiotherapy in the postoperative period. After a few years, there was a new relapse of the disease with pain worsening, presence of edema and functional restriction. On physical examination, she had a varus deformity of the right knee, limping gait, bulky joint effusion, diffuse pain on palpation, full extension, though flexion of this knee was restricted to

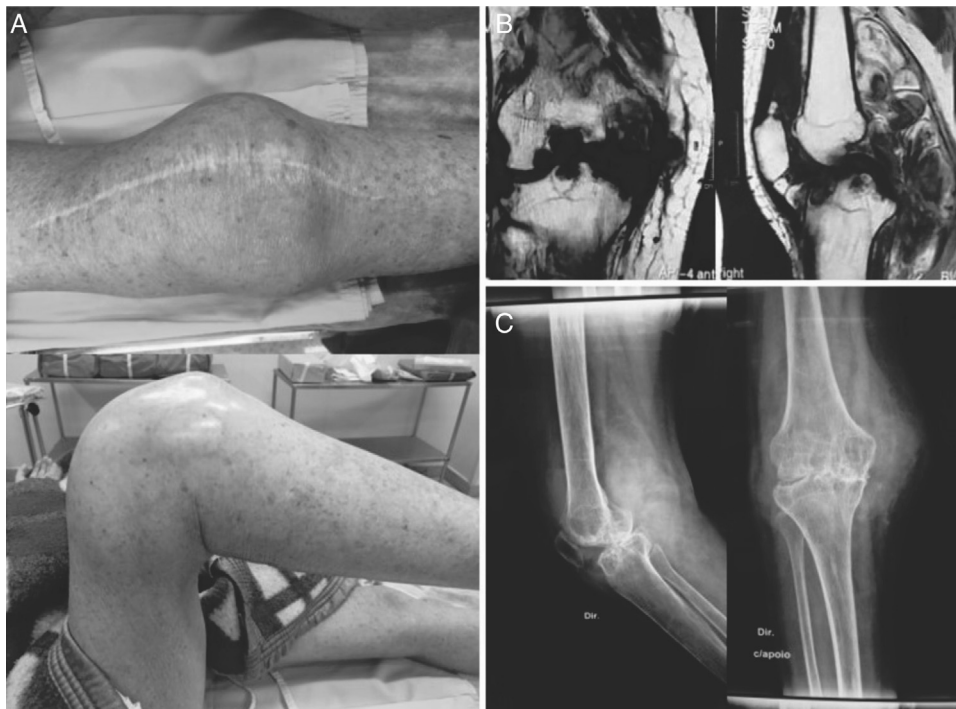

Fig. 1 – Clinical aspect (A), magnetic resonance imaging (B) and radiographs (C), which demonstrate diffuse synovitis, arthrosis, and bone cysts.

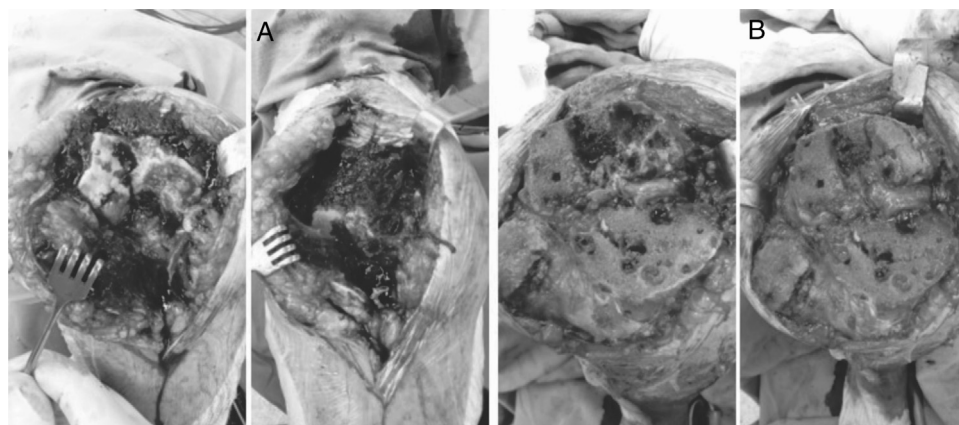


Fig. 2 – Images which demonstrate preoperative aspect – DPVNS, bone flaws and bone sections before (A) and after (B) grafting and wide synovectomy.

110°. The knee radiograph showed advanced tricompartmental arthrosis, grade 4 of Kellgren and Lawrence, a significant loss of joint space and the presence of various epiphyseal bone cysts in the tibia and femur. Magnetic resonance imaging demonstrated advanced tricompartmental arthrosis, as well as exuberant diffuse synovitis throughout the joint, including popliteal fossa and extra-articular extensions in tendinous sheaths, in addition to various bone cysts in the femur and tibia (Fig. 1).

The patient underwent total joint replacement of the knee, associated with a wide perioperative synovectomy. Bone defects resulting from the cysts, which formed contained defects, were found; bone grafts were put in the defects (Fig. 2). The posterior cruciate ligament was sacrificed with a posterior sacrifice femoral component (PS), and, in this case, non-replacement of the patella was chosen. We also used intravenous tranexamic acid in anesthetic induction and 15 min before releasing the tourniquet due to the risk of increased bleeding from surgery. The patient left the operating room in good conditions, and remained in the ICU on the day of surgery, being transferred to the room on the first postoperative day (POD). She was discharged on the second POD.

Non-weightbearing was maintained for 30 days due to bone grafting on the medial femoral condyle. The patient had a good postoperative evolution, despite the short follow-up. She has good limb alignment, full extension and 100° flexion. She also reports improvement of pain and regression of knee edema (Figs. 3 and 4).

Discussion

Pigmented villonodular synovitis is a rare disease, with an incidence of 1.8 cases per million, and should be so named when found in intra-articular locations. This lesion can be found in one in each 2500 arthroscopies.⁴ The most common location is in the knee, about 80%, followed by the ankle. Intra-articular disease may be localized or diffuse, with the first type being almost exclusively found in the knee. DPVNS is characterized by synovial or tendinous sheath hyperplasia, with

marked proliferation of stromal cells, large amounts of intra and extracellular hemosiderin and multinucleated giant cells. The disease is more prevalent in patients between the ages of 20 and 50, but it can affect any age. The localized type represents 6% of the total of this disease and has a mild preference for females.⁵ According to Dines et al.,⁶ Hoffa fat, suprapatellar recess, intercondyle and posterior capsule are the most common locations, the latter the rarer.

DPVNS has unknown etiology, although trauma, inflammatory processes, neoplasms and lipid metabolic diseases have been implicated as the cause of the disease. Recent cytogenetic studies suggest evidence more related to neoplasia.^{3,7}

In diffuse types, repetitive joint effusion, limited range of motion and pain are common symptoms. In the localized types the mechanical symptoms that simulate meniscal lesions and instability, palpable masses and pain are frequent complaints and often make diagnosis difficult. In posterior lesions, pain is often reported with knee flexion.⁸ Pain and tumor are usually progressive. The time from onset of symptoms to diagnosis is on average 19 months in the localized types and 15 months in the diffuse ones. The correlation of symptom onset and trauma is present in 44–53% of patients.⁵

Complementary tests aid in the diagnosis, and magnetic resonance imaging is the most sensitive.^{3,4,7} Radiographs are

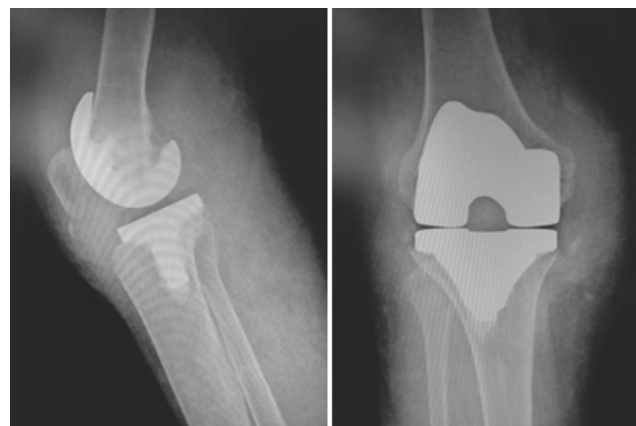


Fig. 3 – Postoperative radiographs.

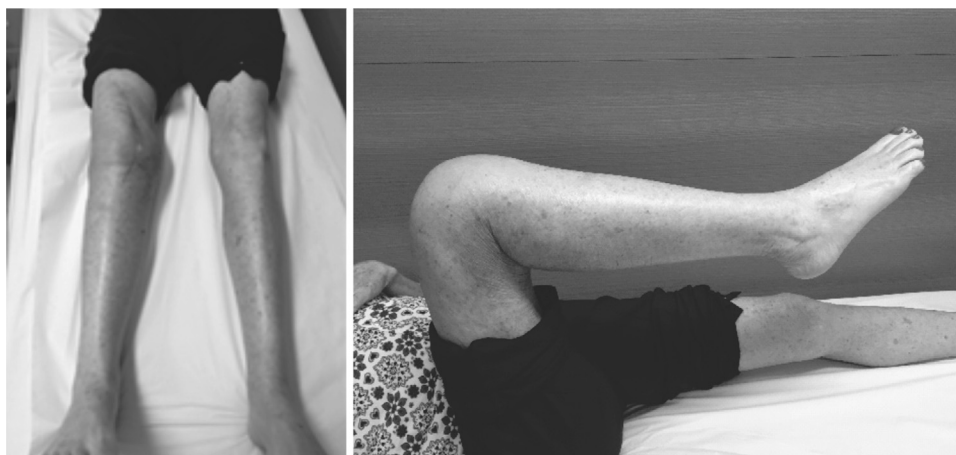

Fig. 4 – Clinical aspect and ROM of the patient with one month after surgery.

usually normal, but degeneration of the joint surface may be present and is more frequent in the hip and shoulder joints. In the knee, these changes are rare, but the narrowing of joint space and osteophytes are findings related to DPVNS, as found in this case. Recent studies suggest that proteolytic enzymes produced by giant cells within the hyperplastic synovial tissue could play a role in this joint degradation.⁴ Magnetic resonance imaging is an important test to establish the diagnosis and direct treatment. Areas of low signal on T1 and T2 are observed in the synovial membrane, which is irregular, and the association with joint effusion is frequent.⁷

The histological findings are of a well-differentiated lesion, with destructive proliferation of synovial-like mononuclear cells, associated with multinucleated giant cells, xanthomatous macrophages, presence of hemosiderin, lipids and lymphoplasmacytic inflammatory cells. In localized lesions there is the presence of a pseudocapsule.^{4,7}

DPVNS is a progressive benign lesion, and malignancy is rare.¹ The recommended treatment for DPVNS is lesion resection. It can be arthroscopic or open. In diffuse type, arthroscopy has a good indication with the use of multiple portals. The use of posterior arthrotomy may be necessary in cases of posterior fossa disease. In the localized type, the partial arthroscopic synovectomy in which the lesion is removed is less invasive, but in tumors well-delimited by a pseudocapsule, open resection is a good option.^{6,7} Relapses range from 10% to 56%, and are more common in diffuse type and may take years to occur.⁵ The recurrence in localized disease is around 3%.⁹ Radiotherapy is used in cases with multiple recurrences. Malignancy occurs in 3% of cases and correlates with multiple recurrences and radiotherapy. Patient follow-up is done with periodic magnetic resonance imaging every six to 12 months.⁷

Hamlin et al.¹⁰ followed 18 patients at Mayo Clinic who were diagnosed with DPVNS, and underwent total knee arthroplasty, 14 with the diffuse type – active in 11 and inactive in three – and four with the localized type. The mean follow-up was 9.9 years. All patients with the diffuse active type also underwent total synovectomy. At the end of the follow-up, in 14 of the 18 patients the replacement was fixed and with a satisfactory function. The four failures occurred in patients with

the diffuse and active type of the disease, as presented in our case. Three failures were due to aseptic loosening and one was due to relapse of the disease. These authors recommend a broad synovectomy, associated with posterior cruciate ligament replacement for better synovial membrane exposure, which was done in this case.

Total knee arthroplasty (TKA) in patients with VNS is not a complication-free procedure. In cases of recurrence of the disease after TKA and depending on functional status, a new synovectomy may be attempted. Other options would be radiotherapy, arthrodesis or even amputation. Many patients also have difficulty in gaining range of motion (ROM) in the initial postoperative period and the authors recommend attention to avoid stiffness.¹⁰

TKA is a viable option for patients with DPVNS when there is associated advanced secondary osteoarthritis. It can provide pain relieve and better limb function.

Conflicts of interest

The authors declare no conflicts of interest.

REFERENCES

- Oda Y, Takahira T, Yokoyama R, Tsuneyoshi M. Diffuse-type giant cell tumor/pigmented villonodular synovitis arising in the sacrum: malignant form. *Pathol Int.* 2007;57(9):627–31.
- Jaffe HL, Lichtenstein L, Sutro CJ. Pigmented villonodular synovitis, bursitis and tenosynovitis. *Arch Pathol.* 1941;31:731–65.
- Kim SJ, Shin SJ, Choi NH, Choo ET. Arthroscopic treatment for localized pigmented villonodular synovitis of the knee. *Clin Orthop Relat Res.* 2000;(379):224–30.
- Muscolo DL, Makino A, Costa-Paz M, Ayerza MA. Localized pigmented villonodular synovitis of the posterior compartment of the knee: diagnosis with magnetic resonance imaging. *Arthroscopy.* 1995;11(4):482–5.
- Murphey MD, Rhee JH, Lewis RB, Fanburg-Smith JC, Flemming DJ, Walker EA. Pigmented villonodular synovitis: radiologic-pathologic correlation. *Radiographics.* 2008;28(5):1493–518.

6. Dines JS, DeBerardino TM, Wells JL, Dodson CC, Shindle M, DiCarlo EF, et al. Long-term follow-up of surgically treated localized pigmented villonodular synovitis of the knee. *Arthroscopy*. 2007;23(9):930-7.
7. Godoy FAC, Faustino CAC, Meneses CS, Nishi ST, Góes CEG, Canto AL. Sinovite vilonodular pigmentada: relato de caso. *Rev Bras Ortop*. 2011;46(4):468-71.
8. Chae DJ, Shetty GM, Kang KH, Kim JH, Nha KW. Localized pigmented villonodular synovitis of the posterior capsule of the knee. *J Knee Surg*. 2009;22(3):267-9.
9. Hernandez AJ, Camanho GL, Laraya MH, Fávoro E, Martinelli Filho M. Sinovite vilonodular pigmentada localizada do joelho: tratamento por via artroscópica. *Acta Ortop Bras*. 2005;13(2):76-8.
10. Hamlin BR, Duffy GP, Trousdale RT, Morrey BF. Total knee arthroplasty in patients who have pigmented villonodular synovitis. *J Bone Joint Surg Am*. 1998;80(1):76-82.