

Arthritis secondary to meningococcal disease

A case series of 7 patients

Vanina Masson-Behar, MD^{a,b}, Hervé Jacquier, MD, PhD^{c,d}, Pascal Richette, MD, PhD^{e,f}, Jean-Marc Ziza, MD^g, Valérie Zeller, MD^g, Christophe Rioux, MD^{h,i}, Baptiste Coustet, MD^{a,b}, Philippe Dieudé, MD, PhD^{a,b}, Sébastien Ottaviani, MD^{a,b,*}

Abstract

Arthritis secondary to invasive meningococemia is rare and has been described as a direct result of bacteremia or as immunoallergic-type arthritis, related to the immune complex. Only a few case series have been reported.

This multicenter study aimed to describe the clinical characteristics and therapeutic outcomes of arthritis secondary to meningococcal infection.

We performed a 5-year retrospective study. We included all patients with inflammatory joint symptoms and proven meningococcal disease defined by the identification of *Neisseria meningitidis* in blood, cerebrospinal fluid, or synovial fluid. Septic arthritis was defined by the identification of *N meningitidis* in joint fluid. Immune-mediated arthritis was considered to be arthritis occurring after at least 1 day of invasive meningococcal disease without positive joint fluid culture.

A total of 7 patients (5 males) with joint symptoms and meningococcal disease were identified. The clinical presentation was mainly oligoarticular and the knee was the most frequent joint site. Five patients had septic arthritis and 4 had immune-mediated arthritis; 2 had septic arthritis followed by immune-mediated arthritis. Immune-mediated arthritis occurred 3 to 7 days after meningococcal meningitis, and treatment with nonsteroidal anti-inflammatory drugs (NSAIDs) led to improvement without complications.

Physicians must be vigilant to the different clinical presentations in patients with arthritis associated with invasive meningococcal disease. If immune-mediated arthritis is suspected, NSAIDs are usually efficient.

Abbreviations: D = day, H = hour, ICs = immune complexes, Mg = milligrammes, *N* = *Neisseria*, NSAIDs = non-steroidal anti-inflammatory drugs.

Keywords: arthritis, *Neisseria meningitidis*

1. Introduction

The clinical spectrum of meningococcal infections can be extremely variable, from asymptomatic carriage to life-threatening meningitis.^[1] The frequency of arthritis secondary to meningococcal disease is variable, but the last series reported a prevalence of 2% to 12.5%.^[2,3]

Editor: Duane R. Hospenhal.

The authors report no conflicts of interest.

^a Université Paris Diderot, Sorbonne Paris Cité, UFR de Médecine, ^b AP-HP, Service de Rhumatologie, Hôpital Bichat, ^c Université Paris Diderot, Sorbonne Paris Cité, UFR de Médecine, ^d AP-HP, Service de Bactériologie-Virologie, Hôpital Lariboisière, ^e Université Paris Diderot, Sorbonne Paris Cité, UFR de Médecine, ^f AP-HP, Service de Rhumatologie, Hôpital Lariboisière, ^g Service de Rhumatologie et Médecine Interne. Centre de Référence des Infections Ostéo-articulaires complexes. Groupe hospitalier Diaconesses Croix St-Simon, ^h Université Paris Diderot, Sorbonne Paris Cité, UFR de Médecine, ⁱ AP-HP, Service de Maladie infectieuses, Hôpital Bichat, Paris, France.

* Correspondence: Dr Sébastien Ottaviani, Service de Rhumatologie, Hôpital Bichat, 46 rue Henri Huchard, 75018 Paris, France (e-mail: sebastien.ottaviani@aphp.fr).

Copyright © 2017 the Author(s). Published by Wolters Kluwer Health, Inc. This is an open access article distributed under the terms of the Creative Commons Attribution-Non Commercial License 4.0 (CCBY-NC), where it is permissible to download, share, remix, transform, and build upon the work provided it is properly cited. The work cannot be used commercially without permission from the journal.

Medicine (2017) 96:29(e7573)

Received: 21 February 2017 / Received in final form: 26 June 2017 / Accepted: 28 June 2017

<http://dx.doi.org/10.1097/MD.0000000000007573>

Several types of meningococcal arthritis have been described. Septic arthritis is related to invasive meningococcal disease, with isolation of *Neisseria meningitidis* in joint fluid or concomitant proven infection in another site. The other type of arthritis is immune-mediated, with no isolation of *N meningitidis* in joint fluid, and occurs later in the course of the meningococcal disease.^[4] Thus, arthritis secondary to invasive meningococemia has been described as a direct result of bacteremia or as immune-mediated-type arthritis, related to the immune complex.^[2,3]

Meningococcal arthritis is rare, and only a few case series have been reported. The objective of this multicenter study was to describe the clinical characteristics and therapeutic outcomes of arthritis secondary to meningococcal infection.

2. Patients and methods

2.1. Study design

We performed a multicenter retrospective study in 3 tertiary-care French hospitals: Bichat Hospital, Lariboisière Hospital, and La Croix Saint-Simon Hospital, France. Data were collected from medical files.

2.2. Patient selection

From 2011 to 2016, we included all patients with joint symptoms and proven meningococcal disease. Meningococcal disease was defined by the identification of *N meningitidis* in blood, cerebrospinal fluid, or synovial fluid. Arthritis or tenosynovitis was defined by high white blood cell count (>1500 cells/mm³),

Table 1
Clinical characteristics of patients with meningococcal-related joint symptoms.

Patient no.	Age/sex	Meningitis	Symptoms delay between meningitis and arthritis, days	Involved joints	Joint fluid culture	<i>Neisseria meningitidis</i> serogroup	Classification of joint symptoms	Treatment of joint symptoms	Dose and duration of therapy	Clinical outcome
1	71/M	Yes	3	Left MCP3, both knees	No articular puncture	B	Immunomediated arthritis	NSAIDs	Ibuprofen 400 mg/12 h, 10 d	Complete resolution
2	18/F	No	NA	Right PIP3, right knee, right hip	<i>N meningitidis</i> C	C	Septic arthritis followed by immune-mediated arthritis	Antibiotics followed by NSAIDs	Cloxacillin 3 g/8 h, 2 d Gentamicin 160 mg/d, 2 d Cefotaxime 3 g/6 h, 7 d Ciprofloxacin 500 mg/12 h, 21 d Ketoprofen LP100 mg/12 h, 23 d	Complete resolution
3	24/M	No	3	Tenosynovitis of fibular tendons	No articular puncture	C	Septic tenosynovitis	Antibiotics	Ceftriaxone 6 g/d, 10 d	Complete resolution
4	47/M	Yes	7	Right knee, right ankle	Sterile	C	Immune-mediated arthritis	Colchicine and NSAIDs	Colchicine 1 mg/12 h, 2 d Naproxen 500 mg/12 h, 5 d	Complete resolution
5	63/M	No	NA	Right knee followed by ankles	<i>N meningitidis</i> B	B	Septic arthritis followed by immune-mediated arthritis	Antibiotics followed by NSAIDs	Ceftriaxone 2 g/d, 10 d Ofloxacin 200 mg/12 h, 7 d Naproxen 500 mg/12 h, 5 d	Complete resolution
6	67/M	Yes	1	Right knee	<i>N meningitidis</i> B	B	Septic arthritis	Antibiotics and joint lavage	Cefotaxime 5 g/6 h, 8 d Ceftriaxone 2 g/6 h, 10 d gentamicin 3 mg/kg/d, 2 d levofloxacin 500 mg/12 h, and rifampicin 600 mg/12 h, 4 w	Complete resolution
7	84/F	No	NA	Wrist, knees	<i>N meningitidis</i> W135	W135	Septic arthritis + pseudogout	Antibiotics + corticosteroids	Ceftriaxone 2 g/12 h, 9 d amoxicillin 2 g/8 h, 8 d 1 g/8 h, 6 d + colchicine, 1 mg/12 h, 2 d prednisone 30 mg/d, and 7 d cortivazol, 1 knee infiltration	Complete resolution

d = days, F = female, h = hour, M = male, MCP = metacarpophalangeal, N = *Neisseria*, NA = not applicable, NSAIDs = nonsteroidal anti-inflammatory drugs, PIP = proximal interphalangeal, w = week.

ultrasonography-proven synovitis, or diagnosis by a rheumatologist (presence of swelling, redness, and warmth). Septic arthritis was defined by the identification of *N meningitidis* in joint fluid (when available) or joint symptoms concomitant to proven meningococcal disease and improved by treatment with antibacterial agents. Microbiological identification and antibiotic susceptibility followed standard methods. Immune-mediated arthritis was defined as arthritis occurring after at least 1 day of invasive meningococcal disease without positive joint fluid culture.

As the study was retrospective, ethical approval and patient consent were not necessary.

2.3. Statistical analysis

A descriptive analysis was performed. Continuous data are expressed as mean ± standard deviation.

3. Results

During a 5-year period, 7 patients with joint symptoms and meningococcal disease were identified. The clinical characteristics of patients are in Table 1. Joint symptoms occurred mainly in male patients (n = 5) and the mean age was 53.4 ± 22.9 years. The serogroups of *N meningitidis* were mainly B and C (n = 3 each) and W135 (n = 1). Three patients had meningitis. The presentation of joint symptoms was monoarticular and oligoarticular in 1 and 6 patients, respectively. The joint arthritis sites were knees (n = 6), ankles (n = 3), fingers (n = 2), wrist (n = 1), and hip (n = 1) (Fig. 1).

Five patients had septic arthritis with the identification of *N meningitidis* in synovial fluid (except 1 with tenosynovitis), and 4 had immune-mediated arthritis. Two patients had septic arthritis followed by immune-mediated arthritis.

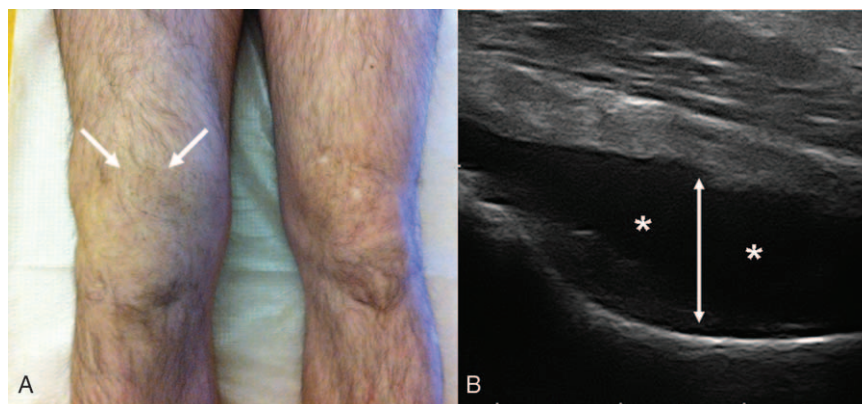


Figure 1. Joint inflammation related to meningococcal disease. (A) Joint effusion (white arrows) of the right knee in a patient with immune-mediated arthritis. (B) Ultrasonography of the hip. Presence of joint effusion (white asterisks) with joint capsule distension (white arrow) in a patient with primary septic meningococcal arthritis.

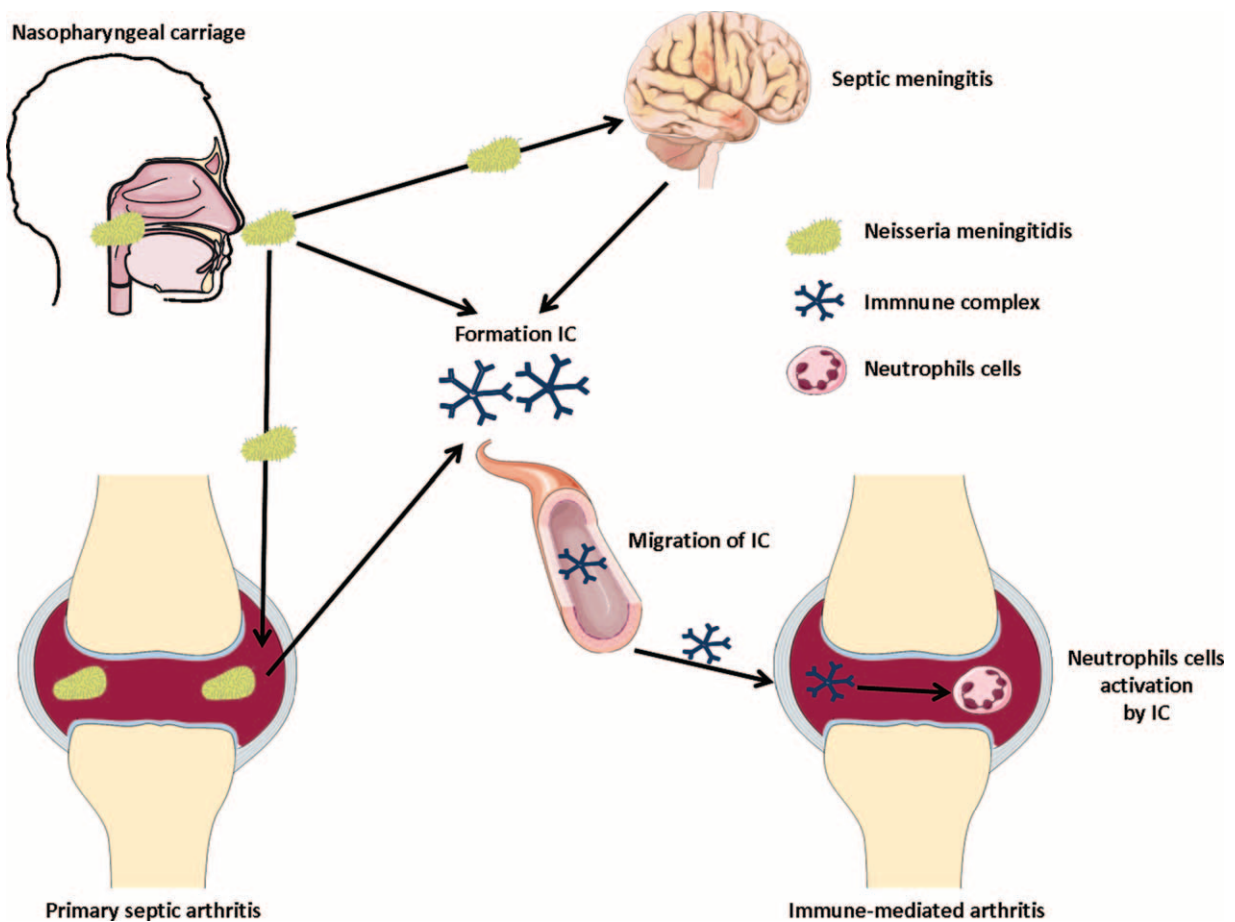


Figure 2. Scheme representing the supposed pathophysiology of meningococcal-related arthritis. Migration of the bacterial agent (*Neisseria meningitidis*) in the central nervous system causes meningitis or in other organs such as joints leads to primary septic arthritis. Production of immune complexes and migration via circulation in other organs such as joints and stimulation of neutrophils leads to inflammation and immune-mediated arthritis.

3.1. Patients with meningococcal septic arthritis

Five patients had a meningococcal septic arthritis (Table 1). All except 1 had isolated septic arthritis without associated meningitis. The knee was the main joint site in 4 cases, and the clinical presentation was mainly oligoarticular. One patient had a tenosynovitis of a fibular tendon. Antibacterial agent treatment led to striking improvement, with complete resolution in a few days. No patient had joint destruction, and only 1 patient required joint lavage.

Patient 7 had concomitant knee pseudogout, which was treated with colchicine (0.5 mg/12 h), without efficacy, followed by oral prednisone (30 mg/day, 7 days) associated with a corticosteroids injection (cortivazol 3.75 mg), which led to complete resolution in 7 days. Two patients (patients 2 and 5) showed new joint symptoms (5 and 7 days after treatment), which suggested secondary immune-mediated arthritis.

3.2. Patients with immune-mediated arthritis

Four patients were considered to have immune-mediated arthritis. As noted previously, 2 patients showed new joint symptoms after septic arthritis. After the initial improvement of clinical symptoms under antibacterial agents, patient 2 experienced an increase in joint pain at the same joint site. For patient 5, a new joint site (ankle) was involved with arthritis. In these 2 patients, treatment with nonsteroidal anti-inflammatory drugs

(NSAIDs) in addition to antibacterial agents led to improvement of symptoms.

Despite antibacterial agent treatment, oligoarticular arthritis developed in the 2 remaining patients 3 to 7 days after meningococcal meningitis. Treatment with NSAIDs led to improvement without complications.

4. Discussion

Despite a high frequency of asymptomatic carriage of *N meningitidis* in the nasopharyngeal mucosae, particularly among young people (24%–37%),^[1] the incidence of meningitis secondary to *N meningitidis* infection varies from 0.5 to 1000 cases/100,000 depending on the geographic area.^[5] In populations with meningitis, the frequency of arthritis is from 2% to 12.5%,^[2,3] representing a rare condition. We report here a case series of 7 patients with arthritis associated with meningococcal disease.

On the basis of capsular polysaccharides, 12 serogroups of *N meningitidis* have been defined. Serogroups A, B, C, W135, and Y are the major types and represent 90% of the invasive meningococcal disease.^[2] In our study, we observed mainly the serogroups B and C. These results agree with the largest case series of 39 patients finding only 1 patient with the serogroup A.

In our study, septic arthritis owing to *N meningitidis* infection occurred mainly in patients without concomitant meningitis,

which represents a challenging diagnosis for the physician. The clinical presentation was mainly oligoarticular and the knee was the most frequent joint site. These data agree with previous reports finding knees (Fig. 1A) and ankles as the most frequently involved joint sites.

Arthritis secondary to meningococcal disease was reported to be septic and/or immune-mediated.^[4] As in our study, septic arthritis related to invasive meningococcal disease usually occurs at the onset of the meningococcal disease, with rapid (<7 days) improvement after a few days of an antibacterial agent. As in our study, the prognosis is usually good and joint complications are rare.^[2,3] Five of our patients had a septic arthritis and 4 had immune-mediated arthritis. The combination of septic and immune-mediated meningococcal arthritis in 2 of our patients is uncommon and has rarely been reported.^[6]

Immune-mediated arthritis seems to be related to immune complexes (ICs).^[7] The pathophysiology is unclear, but *N meningitidis* may promote the formation of ICs. These ICs can migrate to other organs such as the pericardium or joint, thereby leading to immune-mediated pericarditis or arthritis (Fig. 2). As in our patients, joint symptoms usually occur 4 to 10 days after the beginning of meningitis symptoms or antibacterial treatment.^[2-4] Oligoarticular or polyarticular involvement of large joints is the most common presentation,^[2-4] with no difference from the septic arthritis presentation in our study. Immune-mediated arthritis can involve the same joint site or a joint site other than that initially involved by septic arthritis, as seen in our patients.

The delay of appearance, the absence of improvement with antibacterial agent treatment, and the negative synovial fluid cultures are helpful for the diagnosis of immune-mediated arthritis. As in our patients, treatment with NSAIDs usually leads to complete resolution of symptoms. In contrast to our study, some previous patients required prolonged NSAID therapy to achieve resolution, especially those older than 50 years.^[2]

Our study contains some limitations. First, it was retrospective, without detailed analysis of patients, and the number of patients was relatively low. However, meningococcal-related arthritis is rare, especially in adults, and previous studies also reported low numbers of patients.

In conclusion, arthritis secondary to meningococcal disease is rare, but the physician must be aware of this etiology of arthritis that can occur without associated neurological or skin symptoms. Oligoarticular involvement of knees and ankles is the main joint presentation. With proven meningococcal disease, joint fluid analysis, the delay in appearance, and outcomes with antibacterial agent treatment could be useful to diagnose septic and/or immune-mediated arthritis.

Acknowledgements

The authors thank Laura Smales for copyediting.

References

- [1] Pizza M, Rappuoli R. *Neisseria meningitidis*: pathogenesis and immunity. *Curr Opin Microbiol* 2015;23:68–72.
- [2] Cabellos C, Nolla JM, Verdaguier R, et al. Arthritis related to systemic meningococcal disease: 34 years' experience. *Eur J Clin Microbiol Infect Dis* 2012;31:2661–6.
- [3] Weisfelt M, van de Beek D, Spanjaard L, et al. Arthritis in adults with community-acquired bacterial meningitis: a prospective cohort study. *BMC Infect Dis* 2006;6:64.
- [4] Schaad UB. Arthritis in disease due to *Neisseria meningitidis*. *Rev Infect Dis* 1980;2:880–8.
- [5] Caugant DA, Maiden MC. Meningococcal carriage and disease—population biology and evolution. *Vaccine* 2009;27(suppl 2):B64–70.
- [6] Ibrahim KY, Carvalho NB, Moura ML, et al. Infection and immune-mediated meningococcal-associated arthritis: combination features in the same patient. *Revista do Instituto de Medicina Tropical de Sao Paulo* 2012;54:109–11.
- [7] Goedvolk CA, von Rosenstiel IA, Bos AP. Immune complex associated complications in the subacute phase of meningococcal disease: incidence and literature review. *Arch Dis Childhood* 2003;88:927–30.