

Laparoscopic Splenic Total Cystectomy in a Patient With Elevated CA 19–9

Melih Paksoy, Ilhan Karabicak, Ramazan Kusal, Suleyman Demiryas, Fadil Ayan, Metin Ertem

ABSTRACT

True nonparasitic splenic cysts are rare. Reports of approximately 30 cases of benign true splenic cysts producing elevated CA 19–9 serum levels have been published. The traditional treatment of splenic epidermoid cysts is splenectomy. However, with all the advances in laparoscopic surgery, conservative laparoscopic approaches are accepted as the most preferred techniques for this benign disease. Laparoscopic cystectomy with its minimal invasiveness and low morbidity is the ideal technique for properly selected patients. So far, only one case report of laparoscopic cystectomy for splenic epidermoid cyst with elevated CA 19–9 levels has been published. This is the second known report of this procedure being performed to remove a splenic epidermoid cyst in a patient with elevated CA 19–9 levels.

Key Words: Splenic epidermoid cyst, Laparoscopy, Cystectomy, CA 19–9.

INTRODUCTION

Cystic changes of the spleen are very rare. Based on the presence or absence of cellular lining of the cystic wall, splenic cysts are classified as primary (true) and secondary (pseudo) cysts.^{1,2}

Although carbohydrate antigen 19–9 (CA 19–9) is a well-known marker for pancreatic adenocarcinoma, high levels of CA 19–9 may be seen in patients with benign gastrointestinal, hepatobiliary, and splenic diseases.^{3–5}

So far, elevated CA 19–9 serum levels accompanying splenic cysts have been reported in approximately 30 cases, most of which are of epithelial origin.^{6–22}

Because the spleen has an important immunologic role, splenic conservation techniques, such as partial splenectomy, cystectomy, marsupialization, and cyst decompression, for the treatment of benign splenic cysts are more favorable. With all the advances in laparoscopic surgery, all conservative approaches can be done laparoscopically.^{23–26}

Among these techniques, laparoscopic cystectomy is less invasive and has the lowest morbidity. It also has the benefit of reducing postoperative patient discomfort and offers a shorter hospital stay than other surgical laparoscopic techniques.^{27–31}

So far, only one case of laparoscopic cystectomy for splenic epidermoid cyst with elevated CA 19–9 cyst has been published.¹⁷ This is the second known report of this procedure being used to remove a splenic epidermoid cyst in a patient with elevated CA 19–9.

CASE REPORT

A 28-year-old woman, in otherwise excellent health, was admitted to our general surgery department with a chief complaint of left upper quadrant pain. Her physical examination was normal and history was negative for trauma.

Biochemical investigations showed an elevated CA 19–9 level (56.9 U/mL; normal: 0–27 U/mL). The indirect hemagglutination test and the enzyme-linked immunosorbent assay (ELISA) for hydatid disease were negative.

Department of General Surgery, Cerrahpasa Medical School of Istanbul University, Istanbul, Turkey (all authors).

Address reprint requests to: Ilhan Karabicak, MD, Pediatric Liver Transplantation, Mount Sinai School of Medicine, Box 1104, New York, NY 10029, USA. E-mail: Ilhan.Karabicak@mssm.edu

© 2006 by JLS, Journal of the Society of Laparoendoscopic Surgeons. Published by the Society of Laparoendoscopic Surgeons, Inc.

Computerized tomography (CT) and magnetic resonance imaging (MRI) of the abdomen demonstrated a cyst, 71x56 mm in diameter, between the upper pole of the spleen and the stomach (**Figure 1**).

Before surgery, an ultrasound-guided splenic cyst puncture was conducted for diagnosis. The aspirated cystic contents showed epithelial fragments with no evidence of malignancy; however, the CA 19-9 level of the content was high. This finding confirmed the diagnosis of a splenic epidermoid cyst (**Figures 2 and 3**).

A laparoscopic approach for the treatment of the cyst was planned. The patient was placed in the right decubitus position under general anesthesia. On exploration, a 70x60-mm cystic lesion at the upper pole of the spleen, which was pushing the stomach to the left, was seen. The cyst content was aspirated to facilitate dissection. The short gastric vessels and tissues between the spleen and the cyst were divided using the LigaSure (Valleylab, CO, USA). To complete the laparoscopic cystectomy, adhesiolysis was carried out between the cyst and surrounding tissue and spleen. The cyst was completely excised and delivered out of the abdominal cavity.

The postoperative course was uneventful. The patient was discharged on postoperative day 3. Follow-up CT of the abdomen after 6 months showed no recurrence of the cyst.

CA 19-9 level progressively decreased and became normal 3 months after surgery. The patient is doing well with normal CA 19-9 levels and no recurrence for 16 months.

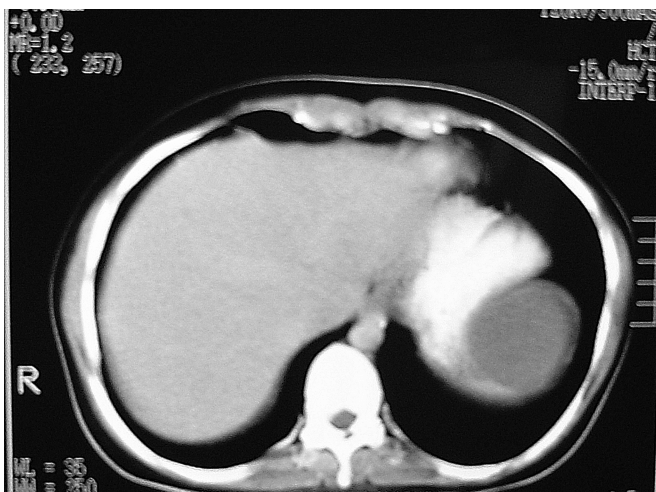


Figure 1. Computed tomographic scan of abdomen demonstrating splenic cyst.

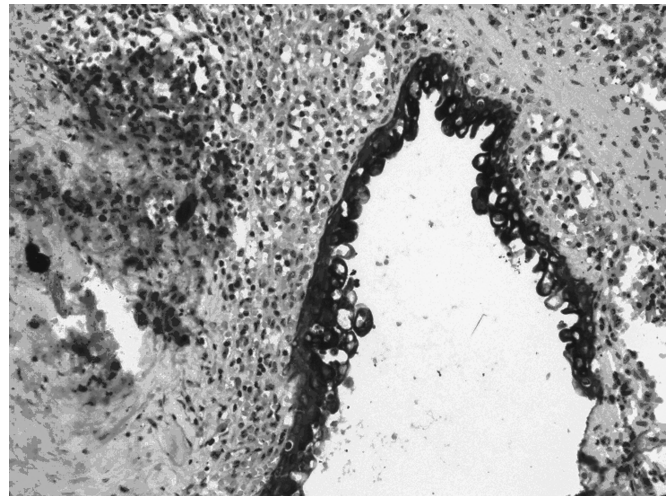


Figure 2. The cyst wall is covered by prismatic and squamous epithelium.

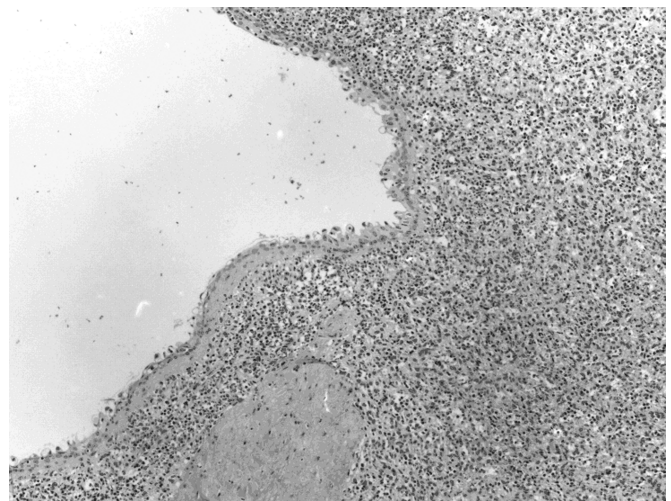


Figure 3. The squamous epithelium shows strong positivity for cytokeratin.

DISCUSSION

Splenic cysts may be primary (true) or secondary (pseudocyst), depending on the presence or absence of an inner cellular lining.^{1,2} Most of the true splenic cysts are epithelial in origin and accepted as having embryonic inclusion of epithelial cells from adjacent structures.^{3,13}

Although CA 19-9 is a reliable marker for pancreatic adenocarcinoma, both normal and tumoral human epithelial cells may produce it. High serum levels of CA 19-9 may accompany benign gastrointestinal diseases, such as liver cirrhosis, acute cholangitis, obstructive jaundice, and benign pancreatic conditions.³⁻⁵

A patient with splenic cysts can present with abdominal pain, splenomegaly, atelectasis, and left shoulder pain, and occasionally infection or abscess formation even rupture or hemorrhage.^{12,23,32}

The first case of a splenic cyst producing elevated serum CA 19-9 was reported by Terada et al²¹ in 1994. Since then, elevated CA 19-9 serum levels have been reported in about 30 cases of splenic cysts, most of epithelial origin.⁶⁻²²

Surgery is the only treatment for the splenic cyst with increased CA 19-9 levels. Complete removal of the cyst is needed to prevent recurrence.⁵

Because the spleen has an important immunologic role, especially in the body's defense against encapsulated bacteria, splenic conservation techniques for the treatment of benign splenic cysts is the aim of surgical treatment.^{23,24} Thus, treatment options for splenic epidermoid cysts, especially in young patients, because it marks the beginning of a disease, may include partial splenectomy, total cystectomy or fenestration, accessed either by laparotomy or laparoscopy.^{23,25,26} Conservative treatment is not possible when the spleen is almost totally occupied by the cyst, and total splenectomy is required for eradication.^{24,33}

Different laparoscopic approaches, such as splenectomy, partial splenectomy, cystectomy, marsupialization, and cyst decompression, have been reported for splenic true and pseudo cysts.^{17, 27-31,34-36}

Robert et al³⁶ reported the first case of successful laparoscopic complete excision of a splenic epidermoid cyst, and Sardi et al¹⁷ reported in 1998 the first case of laparoscopic cystectomy of a splenic epidermoid cyst producing high levels of CA 19-9.

Complete removal of the splenic cyst is curative and remains a good choice for safe treatment in cases with epidermoid splenic cyst.³⁷ Laparoscopic splenic cystectomy is the surgical approach of choice for the splenic epidermoid cyst due to its minimal invasiveness, low morbidity, reduced postoperative pain and discomfort and shortened hospitalization while achieving the same technical success as an open approach.

This is the second reported case of laparoscopic cystectomy of a splenic epidermoid cyst in a patient with elevated CA 19-9. The use of LigaSure made the laparoscopic cyst excision safe, expeditious, with minimal blood loss.

References:

1. Seshadri PA, Poulin EC, Mamazza J, et al. Needlescopic decapsulation of a splenic epithelial cyst. *Canadian J Surg.* 2000;43:303-305.
2. Gianom D, Alesandro Wildisen A, et al. Open and laparoscopic treatment of nonparasitic cysts. *Dig Surg.* 2003;20:74-78.
3. Lieto E, Castellano P, Ferraraccio F, et al. Normal interleukin-10 serum level opposed to high serum levels of carbohydrate antigen 19-9 and cancer antigens 125 and 50 in a case of true splenic cyst. *Arch Med Res.* 2003;34:145-148.
4. Osswald BR, Klee FE, Wysocki S. The reliability of highly elevated CA 19-9 levels. *Dis Markers.* 1993;11:275-278.
5. Ito S, Gejyo F. Elevation of serum CA19-9 levels in benign diseases. *Intern Med.* 1999;38:840-841.
6. Palmieri I, Natale E, Crafa F, Cavallaro A, Mingazzini PL. Epithelial splenic cysts *Anticancer Res.* 25:515-521, 2005.
7. Hashimoto T, Sugino T, Fukuda T, et al. Multiple epithelial cysts of the spleen and on the splenic capsule, and high serum levels of CA19-9, CA125 and soluble IL-2 receptor. *Pathol Int.* 2004;54:349-354.
8. Mori M, Ishii T, Iida T, Tanaka F, Takikawa H, Okinaga K. Giant epithelial cyst of the accessory spleen. *J Hepatobiliary Pancreat Surg.* 2003;10:118-120.
9. Madia C, Lumachi F, Veroux M, et al. Giant splenic epithelial cyst with elevated serum markers CEA and CA 19-9 levels: an incidental association? *Anticancer Res.* 2003;23:773-776.
10. Galizia G, Lieto E, Ferraraccio F, et al. A true splenic cyst producing carbohydrate antigen 19-9 and cancer antigens 50 and 125, but not interleukin 10. *Dig Surg.* 2003;20:71-74.
11. Matsubayashi H, Kuraoka K, Kobayashi Y, et al. Ruptured epidermoid cyst and haematoma of spleen: a diagnostic clue of high levels of serum carcinoembryonic antigen, carbohydrate antigen 19-9 and Sialyl Lewis x. *Dig Liver Dis.* 2001;33:595-599.
12. Trompetas V, Panagopoulos E, Priovolou-Papaevangelou M, Ramantanis G. Giant benign true cyst of the spleen with high serum level of CA 19-9. *Eur J Gastroenterol Hepatol.* 2002;14:85-88.
13. Soudack M, Ben-Nun A, Toledano C. Elevated carbohydrate antigen 19-9 in patients with true (epithelial) splenic cysts—rare or undiscovered? *Can J Gastroenterol.* 2001;15:125-126.
14. Van Lacum MW, Hessels RA, Kremer GD, Jaspers CA. A splenic cyst and a high serum CA 19-9: a case report. *Eur J Intern Med.* 2000;11:104-107.
15. Sakamoto Y, Yunotani S, Edakuni G, Mori M, Iyama A, Miyazaki K. Laparoscopic splenectomy for a giant splenic epidermoid cyst: report of a case. *Surg Today.* 1999;29:1268-1272.

16. Ishibashi R, Sakai T, Yamashita Y, Maekawa T, Hideshima T, Shirakusa T. Benign epithelial cyst of the spleen with a high production of carbohydrate antigen 19-9. *Int Surg*. 1999;84:151-154.
17. Sardi A, Ojeda HF, King D Jr. Laparoscopic resection of a benign true cyst of the spleen with the harmonic scalpel producing high levels of CA 19-9 and carcinoembryonic antigen. *Am Surg*. 1998;64:1149-1154.
18. Decker D, Bollmann R, Hirner A, Stratmann H. Increased CA-19-9 caused by a splenic cyst: a rare differential diagnosis. *Zentralbl Chir*. 1998;123:855-857.
19. Higaki K, Jimi A, Watanabe J, Kusaba A, Kojiro M. Epidermoid cyst of the spleen with CA19-9 or carcinoembryonic antigen productions: report of three cases. *Am J Surg Pathol*. 1998;22:704-708.
20. Yoshikane H, Suzuki T, Yoshioka N, et al. Giant splenic cyst with high serum concentration of CA 19-9. Failure of treatment with percutaneous transcatheter drainage and injection of tetracycline. *Scand J Gastroenterol*. 1996;31:524-526.
21. Walz MK, Metz KA, Sastry M, Eigler FW, Leder LD. Benign mesothelial splenic cyst may cause high serum concentration of CA 19-9. *Eur J Surg*. 1994;160:389-391.
22. Terada T, Yasoshima M, Yoshimitsu Y, Nakanuma Y. Carbohydrate antigen 19-9 producing giant epithelial cyst of the spleen in a young woman. *J Clin Gastroenterol*. 1994;18:57-61.
23. Sellers GJ, Starker PM. Laparoscopic treatment of a benign splenic cyst. *Surg Endosc*. 1997;11:766-768.
24. Musy PA, Roche B, Belli D, Bugmann P, Nussle D, Le Coultre C. Splenic cysts in pediatric patients—a report on 8 cases and review of the literature. *Eur J Pediatr Surg*. 1992;2:137-140.
25. Touloukian RJ, Maharaj A, Ghossoub R, Reyes M. Partial decapsulation of splenic epithelial cysts: studies on etiology and outcome. *J Pediatr Surg*. 1997;32:272-274.
26. Kimber C, Pierro A, Drake D, Kiely E, Spitz L. Hemisplenectomy for giant splenic cysts in children. *Pediatr Surg Int*. 1998;14:116-118.
27. Seshadri PA, Poenaru D, Park A. Laparoscopic splenic cystectomy: a case report. *J Pediatr Surg*. 1998;33:1439-1440.
28. Trias M, Targarona EM, Espert JJ, Balague C. Laparoscopic surgery for splenic disorders. Lessons learned from a series of 64 cases. *Surg Endosc*. 1998;12:66-72.
29. Kiriakopoulos A, Tsakayannis D, Papadopoulos S, Linos D. Laparoscopic management of a ruptured giant epidermoid splenic cyst. *JLS*. 2005;9:349-351.
30. Targarona EM, Martinez J, Ramos C, Becerra JA, Trias M. Conservative laparoscopic treatment of a posttraumatic splenic cyst. *Surg Endosc*. 1995;9:71-72.
30. Sierra R, Brunner WC, Murphy JT, Dunne JB, Scott DJ. Laparoscopic marsupialization of a giant posttraumatic splenic cyst. *JLS*. 2004;8:384-388.
32. Panossian DH, Wang N, Reeves CD, Weeks DA. Epidermoid cyst of the spleen presenting as a generalized peritonitis. *Am Surg*. 1990;56:295-298.
33. Di Carlo I, Fasone MA, Toro A. Epidermoid cyst of the spleen in the laparoscopic era. *Dig Surg*. 2005;22:53-54.
34. Salky B, Zimmerman M, Bauer J, Gelernt I, KreeI I. Splenic cyst-definitive treatment by laparoscopy. *Gastrointest Endosc*. 1985;31:213-215.
35. Delaitre B, Maignien B, Icard P. Laparoscopic splenectomy. *Br J Surg*. 1992;79:1334.
36. Soares RL, Balder DA, Migliori SJ. Laparoscopic complete excision of a splenic epidermoid cyst. *J Laparoendosc Adv Surg Tech A*. 1998;8:237-240.
37. Yagi S, Isaji S, Iida T, Mizuno S, et al. Laparoscopic splenectomy for a huge splenic cyst without preoperative drainage: report of a case. *Surg Laparosc Endosc Percutan Tech*. 2003;13:397-400.