



Contents lists available at ScienceDirect

International Journal of Surgery Case Reports

journal homepage: www.casereports.com

Primary ovarian leiomyoma: A case report



Mine Islimye Taskin^{a,*}, Emine Ozturk^a, Fatma Yildirim^b,
Necmettin Ozdemir^b, Umit Inceboz^a

^a Balikesir University School of Medicine, Department of Obstetrics and Gynecology, Turkey

^b Ege University School of Medicine, Department of Pathology, Turkey

ARTICLE INFO

Article history:

Received 4 July 2014

Accepted 24 July 2014

Available online 4 August 2014

Keywords:

Ovary

Leiomyoma

Immunohistochemistry

ABSTRACT

INTRODUCTION: Primary ovarian leiomyoma is a rare benign tumour of the ovary seen in women between 20 and 65 years old. It is usually diagnosed incidentally during pelvic examination or pathologic examination after surgery.

PRESENTATION OF CASE: We describe a case of unilateral, ovarian leiomyoma. Transvaginal ultrasonography and magnetic resonance imaging (MRI) revealed a right adnexial mass. Unilateral salpingo-oophorectomy was performed, and histological examination revealed a leiomyoma arising primarily in the ovary. The diagnosis was confirmed immunohistochemically.

DISCUSSION: The tumour may be asymptomatic or may manifest with lower abdominal pain like in our case. The definitive diagnosis of these lesions is difficult prior to surgical removal. Because there is no pathognomonic symptoms or characteristic imaging findings. The correct diagnosis of an ovarian leiomyoma requires identification of the smooth muscle nature of the tumour.

CONCLUSION: This rare tumour of the ovary should be considered in the differential diagnosis of solid ovarian masses. An immunohistochemical analysis is recommended for definitive diagnosis.

© 2014 The Authors. Published by Elsevier Ltd. on behalf of Surgical Associates Ltd. This is an open access article under the CC BY-NC-SA license (<http://creativecommons.org/licenses/by-nc-sa/3.0/>).

1. Introduction

Leiomyoma is one of the rarest solid tumours of the ovary; it accounts for 0.5–1% of all the benign ovarian tumours.¹ Approximately 70 cases have been reported in the literature. Ovarian leiomyomas are particularly unilateral and small, and they most commonly occur in women aged 20–65. The majority of these tumours are discovered incidentally, with about 80% of the cases occurring in premenopausal women.² Patients are usually asymptomatic, and the tumour is most commonly diagnosed unintentionally by histological examination of ovarian tissue after an ovariectomy for solid ovarian mass. Ovarian leiomyomas probably arise from smooth muscle cells in the ovarian hilar blood vessels, but other possible origins are cells in the ovarian ligament, smooth muscle cells or multipotential cells in the ovarian stroma, undifferentiated germ cells, and cortical smooth muscle metaplasia.³ In this study, we report a case of a primary ovarian leiomyoma in a 42-year-old woman.

2. Case report

A 42-year-old gravida 1 para 0 woman was admitted to our university hospital (Balikesir, Turkey) with a history of lower abdominal pain and desire for pregnancy. Her history was unremarkable with the exception of three in vitro fertilisation cycles for male-factor infertility and one pregnancy that was aborted in the sixth week of gestation. Physical and abdominal examination findings were normal. On vaginal examination, a mobile mass approximately 4 cm in diameter was detected in the right lower abdomen. Her CA 125, CA 15-3, CA 19-9, CEA, and AFP values were within normal limits. Transvaginal ultrasonography revealed a right adnexial mass 38.9 mm × 36 mm in diameter that showed a homogeneously isoechoic pattern (Fig. 1). The mass was solid and well circumscribed, and pathologic blood flow was not detected in Doppler ultrasonography. Pelvic MRI showed a 4 cm × 3 cm, well-circumscribed solid tumour in the right adnex that exhibited low-intensity signals on both T1- and T2-weighted images. A laparotomy was performed under general anaesthesia. During laparotomy, inspection of the uterus and adnexes revealed a solid, firm, oval, right-sided ovarian tumour with a smooth surface, approximately 4 cm in diameter. The tumour was distinctly separated from the uterus and exhibited no adhesion to or infiltration of the surrounding structures. There was no accompanying uterine mass. The left salpinx, ovary were normal on inspection and

* Corresponding author at: Balikesir University School of Medicine, Department of Obstetrics and Gynecology, 10145 Çağış Kampüsü, Balikesir, Turkey. Tel.: +90 266 612 14 54/1289; fax: +90 266 612 12 94.

E-mail addresses: minetaskin1302@yahoo.com.tr, minetaskin@balikesir.edu.tr (M.I. Taskin).

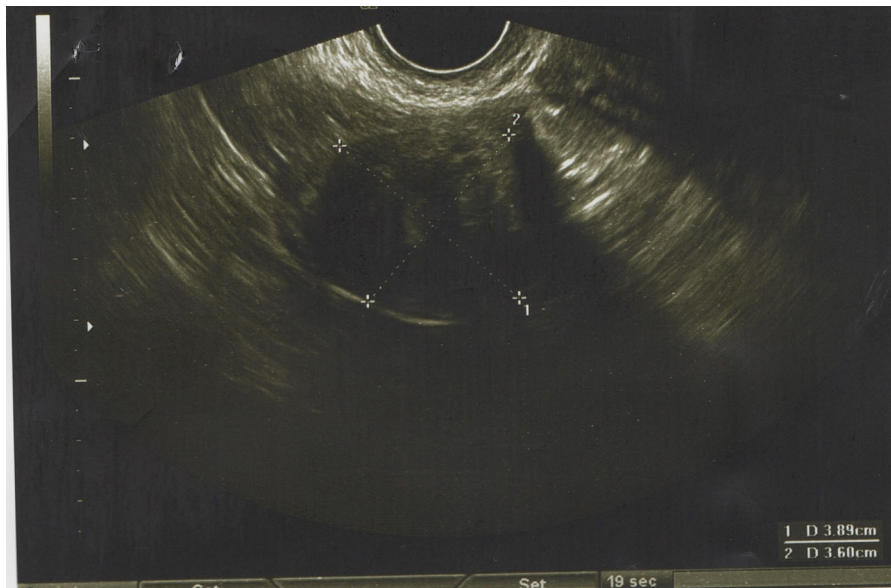


Fig. 1. Right ovarian solid mass.

were left intact. Right unilateral salpingo-oophorectomy was performed, and frozen sectioning revealed a benign tumour suggesting thecoma or fibroma. After surgery, histological and immunohistochemical examination resulted in a diagnosis of primary ovarian leiomyoma. Pathologic examination revealed a tumour composed of interlacing bundles of fusiform cells, resembling a leiomyoma (Fig. 2). There was no atypia or pleomorphism, and mitotic count and necrosis were absent (Fig. 3). Immunohistochemical staining showed strong and diffuse positive staining for smooth muscle actin (SMA) (Fig. 4). Ki-67 proliferation index was low (Fig. 5). The postoperative period was uneventful.

3. Discussion

Primary leiomyoma of the ovary is a very rare benign tumour, usually detected incidentally during routine pelvic examination, during surgery, or after surgical removal of the ovary. Most leiomyomas of the ovary are small, usually less than 3 cm in diameter.⁶ Most of the patients are asymptomatic or, as in our case,

have only complaints of lower abdominal pain. In contrast, giant ovarian leiomyomas can be presented with ascite, hydrothorax, hydronephrosis, or slightly elevated levels of tumour marker, CA 125.^{1,4,5}

Case reports have demonstrated a predominance of unilateral leiomyomas, but bilateral ovarian leiomyomas have been reported in paediatric and young adult patients. Bilateral cases have not been reported in patients over the age of 35.⁷ In line with the literature, our patient was 42 years old and had unilateral ovarian leiomyoma. Ovarian leiomyomas often coexist with uterine leiomyomas, but sometimes they can be a secondary origin. That is, subserosal pedunculated uterine leiomyoma can lose its attachment to the uterus and connect to the ovary. This had obviously not occurred in the present case, because the uterus was normal and did not exhibit any signs of leiomyoma.

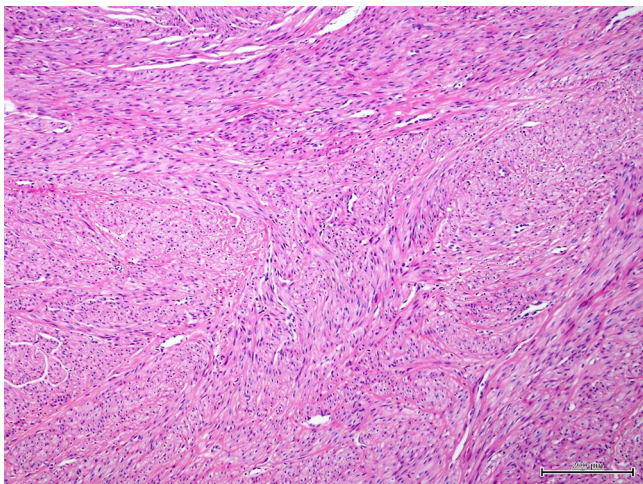


Fig. 2. Fascicles of smooth muscle cells (H&E, ×100).

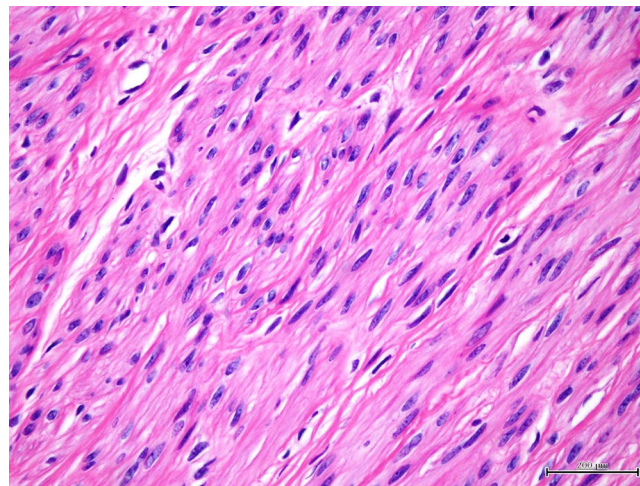


Fig. 3. The smooth muscle cells are uniformly spindle shaped or elongated with blunt-ended or cigar-shaped nuclei. Mitotic activity is absent or very low, and cellular and nuclear pleomorphisms are absent.

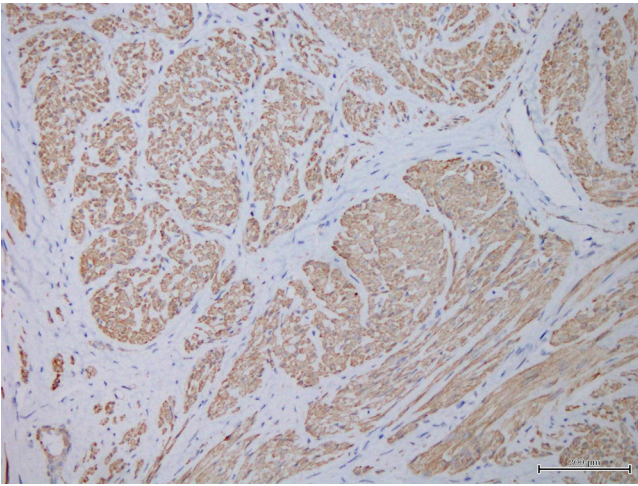


Fig. 4. Marked immunoreactivity for smooth muscle actin ($\times 200$).

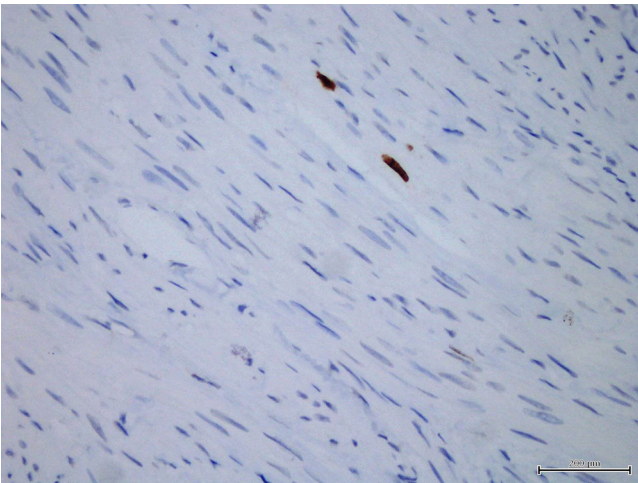


Fig. 5. Very low Ki-67 proliferation index ($\times 400$).

The literature has reported that many patients with ovarian leiomyomas are nulligravidas. This suggests that oestrogen may play a role in the development of ovarian leiomyomas. Another possible mechanism suggests that tumour may arise in developmentally abnormal ovaries.⁸ In our case, normal ovarian tissue was present histologically. This suggests that the tumour can originate from the smooth muscle cells in the walls of blood vessels, in the cortical stroma, in the hilus, in the corpus luteum, or in the ovarian ligament.

In the preoperative period, differential diagnosis can be difficult from ovarian thecoma and/or fibromas of the ovary. Because ultrasonography visualises ovarian leiomyomas as intrapelvic solid tumours, isoechoic with the myometrium, it is difficult to distinguish them from pedunculated uterine leiomyomas and other solid ovarian tumours. MRI is often a useful adjunct to ultrasonography for the purpose of diagnosing indistinct pelvic masses.⁹ In the present case, MRI revealed a well-circumscribed solid tumour in the pelvis that demonstrated low-intensity signals on T1- and T2-weighted images. When such a solid ovarian tumour with the similar findings of uterine leiomyoma detected in MRI, ovarian leiomyoma can be considered.

The correct diagnosis of an ovarian leiomyoma requires identification of the smooth muscle nature of the tumour. In the present case, an immunohistochemical analysis confirmed our diagnosis, although frozen sectioning revealed fibrothecoma. The diffuse strong positive staining for SMA is characteristic of leiomyoma. Thecoma could also be considered in differential diagnosis, but it does not express SMA.^{1,3,6} Ovarian leiomyomas must also be differentiated from leiomyosarcomas. For this aim, pathologists use criteria such as mitotic count, cytological atypia, and tumour necrosis.³ In our case, none of these criteria were detected. Ki-67 is an index protein that affects growth control in leiomyoma monoclonal cells and is helpful in the evaluation of characteristics of uterine leiomyoma neoplastic processes.¹⁰ In the present case, the Ki-67 proliferation index was assessed and found to be very low.

A common surgical approach to ovarian leiomyomas in middle-aged to elderly patients is hysterectomy in conjunction with bilateral salpingo-oophorectomy. For bilateral ovarian leiomyomas, bilateral oophorectomy is often required. Wei et al. reported a case in which pedunculated unilateral ovarian leiomyoma and ovarian preservation were possible.⁷ In the present case, we performed unilateral salpingo-oophorectomy. Because the tumour was indistinguishable from the ovary, the tumour was also unilateral and benign.

4. Conclusion

The present study presents a rare case of primary ovarian leiomyoma. Preoperative diagnosis can be difficult with solid ovarian tumours, an immunohistochemical analysis is recommended for definitive diagnosis.

Conflict of interest

Authors declare that there is no conflict of interest.

Funding

None.

Ethical approval

Written informed consent was obtained from the patient for publication of this case report and accompanying images

Authors contribution

Mine Islimye Taskin and Umit Inceboz contributed to study design and writing. Emine Ozturk contributed to data collection. Necmettin Ozdemir and Fatma Yilmaz contributed to histologic analysis.

References

1. Agrawal R, Kumar M, Agrawal L, Agrawal KK. A huge primary ovarian leiomyoma with degenerative changes: an unusual. *J Clin Diagn Res* 2013;7(6):1152–4.
2. Blue NR, Felix JC, Jaque J. Primary ovarian leiomyoma in a premenarchal adolescent: first reported case. *J Pediatr Adolesc Gynecol* 2013. pii:S1083-3188(13)00242-8.
3. Tomas D, Lenicek T, Tucker N, Puljiz Z, Ledinsky M, Kruslin B. Primary ovarian leiomyoma associated with endometriotic cyst presenting with symptoms of acute appendicitis: a case report. *Diagn Pathol* 2009;4:25.
4. Khaffaf N, Khaffaf H, Wuketich S. Giant ovarian leiomyoma as a rare cause of acute abdomen and hydronephrosis. *J Obstet Gynecol* 1996;87:872–3.
5. Erdemoglu E, Kamaci M, Bayram I, Güler A, Güler Sahin H. Primary giant leiomyoma of the ovary: case report. *Eur J Gynaecol Oncol* 2006;27(6):634–5.

6. Güney M, Ozsoy M, Oral B, Mungan T, Kapucuoğlu N. Unilateral primary ovarian leiomyoma in adolescent: a case report. *Arch Gynecol Obstet* 2007;**275**(June (6)):507–10.
7. Wei C, Lilic N, Shorter N, Garrow E. Primary ovarian leiomyoma: a rare cause of ovarian tumor in adolescence. *J Pediatr Adolesc Gynecol* 2008;**21**(1):33–6.
8. Lim SC, Jeon HJ. Bilateral primary ovarian leiomyoma in a young woman: case report and literature review. *Gynecol Oncol* 2004;**95**(3):733–5.
9. Yasushi K, Noriyuki T, Masako S, Kaei N, Isao M. Magnetic resonance imaging findings in leiomyoma of the ovary: a case report. *Arch Gynecol Obstet* 2005;**273**:298–300.
10. Plewka A, Plewka D, Madej P, Nowaczyk G, Sieron-Stoltny K, Jakubiec-Bartnik B. Processes of apoptosis and cell proliferation in uterine myomas originating from reproductive and perimenopausal women. *Folia Histochem Cytobiol* 2011;**49**(3):398–404.

Open Access

This article is published Open Access at sciedirect.com. It is distributed under the [IJSCR Supplemental terms and conditions](#), which permits unrestricted non commercial use, distribution, and reproduction in any medium, provided the original authors and source are credited.