

# IL-17: a novel player in the pathogenesis of vulvar lichen sclerosis

Wojciech Baran<sup>1</sup>, Zdzisław Woźniak<sup>2</sup>, Aleksandra Batycka-Baran<sup>1</sup>

<sup>1</sup>Department of Dermatology, Venereology and Allergology, Wrocław Medical University, Wrocław, Poland

<sup>2</sup>Department of Clinical and Experimental Pathology, Wrocław Medical University, Wrocław, Poland

Adv Dermatol Allergol 2024; XLI (2): 220–225

DOI: <https://doi.org/10.5114/ada.2024.139142>

## Abstract

**Introduction:** Vulvar lichen sclerosis (VLS) is a chronic progressive, lymphocyte-mediated inflammatory disease whose pathogenesis is complex and not fully elucidated.

**Aim:** In the current study we have investigated for the first time the expression of interleukin-17 (IL-17) and S100A7 in lesional skin obtained from female individuals with histologically confirmed VLS.

**Material and methods:** In our study we used skin biopsies obtained from female patients with histologically confirmed VLS ( $n = 20$ ) and skin samples from healthy age- and gender-matched individuals (plastic surgery procedures) ( $n = 10$ ) serving as controls. The tissue expressions of IL-17 and S100A7 were assessed with an immunohistochemical method.

**Results:** The number of cells showing IL-17 expression was significantly higher in VLS lesional skin as compared to normal skin of healthy controls ( $p < 0.0001$ ). In VLS lesional skin, IL-17 was expressed in the epidermis and by cells within the inflammatory infiltrate in the upper dermis. The number of cells showing S100A7 expression was significantly higher in VLS lesional skin as compared to normal skin of healthy controls ( $p < 0.0001$ ). In VLS lesional skin, S100A7 was expressed by suprabasal keratinocytes in epidermis. S100A7 was also expressed by cells within the inflammatory infiltrate in the dermis.

**Conclusions:** The results of our study may suggest the involvement of IL-17 and S100A7 in the pathogenesis of VLS. The better understanding of this disease may lead to the development of novel, effective therapeutic strategies e.g. using well-known biologics IL-17 inhibitors class.

**Key words:** lichen sclerosis, interleukin-17, S100A7.

## Introduction

Lichen sclerosis (LS) is a chronic, progressive, immune-mediated inflammatory and sclerotic skin disease that commonly affects the anogenital area (anogenital LS). LS is more common in females than in males with reported a female-to-male ratio ranging from 3 : 1 to 10 : 1 [1–3]. The vulvar LS (VLS) involves female genital skin, mostly labia minora, labia majora, interlabial sulci and clitoral hood but the disease may extend to the entire vulva, perineal and perianal region in a “figure of eight” configuration. The vaginal mucosa is not involved [2, 4, 5]. VLS may appear at any age and its prevalence is estimated to range between 0.1% in the pre-pubertal period to 3% in postmenopausal women [1, 2, 6]. It is clinically characterized by white, ivory-coloured lesions,

patches and plaques with partially atrophic skin, follicular plugging, hyperkeratosis, sclerosis, fissures and ulceration, often associated with pruritus and soreness [1–5]. VLS may progress to destructive scarring with the increased risk of transition to squamous cell carcinoma, estimated at 4–5% over a lifetime [1, 2, 7–9]. The disease is distressing, significantly affects quality of life and often causes sexual dysfunction. Early treatment may prevent scarring and cancer transformation. The pathogenesis of VLS is not well defined [1–4].

VLS seems to be a complex and multifactorial disease in which genetic susceptibility, some endogenous and exogenous factors may play a role [1–3]. Several lines of evidence suggest a pivotal role of immunological dysregulation that leads to a chronic inflammatory process and a progressive formation of sclerotic dermal

---

**Address for correspondence:** Prof. Wojciech Baran, MD, PhD, Department of Dermatology, Venereology and Allergology, Wrocław Medical University, 1 Chałubińskiego St, 50-368 Wrocław, Poland, phone: +48 71 327 09 41, fax: +48 71 327 09 42, e-mail: [wojciech.baran@umw.edu.pl](mailto:wojciech.baran@umw.edu.pl)

**Received:** 10.03.2024, **accepted:** 5.04.2024, **online publication:** 24.04.2024.

tissue in VLS [2, 3, 10]. The link with other autoimmune diseases have been reported in LS [2, 11]. The histological features of VLS comprise an inflammatory, mainly lymphocytic infiltrate around dilated capillaries and homogenized collagen in an upper, papillary dermis as well as basement membrane thickening and epidermal changes [1–3, 12]. Although the histological picture of epidermis in VLS may vary, early lesions often show: vacuolar degeneration of the epidermal basal layer; hyperkeratosis; mild, irregular, occasionally psoriasiform acanthosis and epidermal oedema or thinning [1, 13]. The hallmarks of late-stage VLS lesions are superficial dermal sclerosis with an inflammatory infiltrate and atrophic epidermis. The inflammatory infiltrate in VLS is composed mainly of lymphocytes, but some other cells may be present including mast cells and macrophages [1–3, 12–14]. Genital LS has been shown to have a higher number of macrophages as compared to the extragenital variant [12]. An abnormal activation of Th1 cells and overexpression of some Th1-type proinflammatory cytokines such as tumor necrosis factor- $\alpha$  (TNF- $\alpha$ ), interleukin-1 $\alpha$  (IL-1 $\alpha$ ), IL-2 and interferon- $\gamma$  (INF- $\gamma$ ) have been found in LS [2, 3, 10, 15]. However the expression of IL-17 has not been elucidated in VLS lesions. IL-17 is a pleiotropic proinflammatory cytokine that plays a crucial role in the development of autoimmunity. Up-regulated in the skin, IL-17 is involved in the pathogenesis of several chronic inflammatory skin diseases such as psoriasis, hidradenitis suppurativa and lichen planus. Its potent proinflammatory action is related to the recruitment and stimulation of other immune cells in the skin including keratinocytes. Although it is a signature cytokine of T-helper (Th) 17 cells, it is also produced by other immune cells including mast cells, neutrophils, natural killer (NK) cells,  $\gamma\delta$  T-cells. IL-17 play a central role in physiological immune response against extracellular bacteria and fungi and protects the epithelial barrier by inducing the secretion of some antimicrobial proteins (AMPs) [16–19].

S100 proteins constitute a family of small (9–13 kDa), calcium-binding, EF-hand proteins, involved in the regulation of cell proliferation and differentiation [20–23]. A member of S100 protein family, S100A7 is an antimicrobial protein that was first identified as overexpressed by keratinocytes in epidermis of psoriatic lesions, therefore was named psoriasin [24, 25]. S100A7 shows antimicrobial activity against *Escherichia coli* [24–26]. It has been identified as an endogenous damage (danger)-associated molecular pattern (DAMP) – ‘alarmin’ with proinflammatory properties. It stimulates keratinocytes for enhanced production of proinflammatory mediators and acts as a chemoattractant for leukocytes [25–28]. S100A7 has been shown to be involved in the pathogenesis of some chronic inflammatory skin diseases such as psoriasis, atopic dermatitis, lichen planus, hidradenitis suppurativa [25, 29–31].

## Aim

The aim of the study was to investigate the expression of IL-17 and S100A7 in lesional skin obtained from individuals suffering from VLS as compared to normal skin taken from healthy controls.

## Material and methods

### Study group

The study group consisted of 20 female individuals with histologically confirmed VLS, aged from 52 to 78 years (mean  $\pm$  SD = 62.8  $\pm$  6.26 years). The duration of the disease, reported by patients was several months (mean 12.35  $\pm$  8.16 months). The biopsy specimens were obtained from lesional VLS skin. The patients did not receive any topical treatment at least 4 weeks before biopsy and any systemic treatment. Exclusion criteria included other skin diseases, other chronic immune-mediated inflammatory diseases, chronic or acute uncontrolled conditions and neoplasms. Biopsy specimens of normal skin taken from healthy age- and gender-matched individuals during plastic surgery procedures served as controls ( $n$  = 10). The mean age of healthy controls was 59.6  $\pm$  3.34 years. The study was performed in accordance with the Declaration of Helsinki and was approved by the local Bioethics Committee (KB-727/22).

### Tissue expressions of S100A7 and IL-17

The tissue expressions of IL-17 and S100A7 were assessed with an immunohistochemical method. The immunohistochemical reactions were performed on 4  $\mu$ m-formalin-fixed and paraffin-embedded (FFPE) biopsy specimens according to the manufacturer's protocol, using mouse anti-human IL-17 polyclonal antibodies (catalogue number PA1-84183; Invitrogen, USA), mouse anti-human psoriasin (S100A7) monoclonal antibodies (catalogue number ab13680; Abcam, UK), with positive and negative control stainings. Detection was performed on the Dako platform using the Dako RDS AP kit (Dako Real Detection System Alkaline Phosphatase Real Rabbit/Mouse, catalogue number K5005). The preparations were assessed using Zeiss Axio Imager A2 light microscope with video track and Zeiss AxioVision software. The expression was considered as positive when membrane or cell cytoplasmic immunoreactivity was observed. Positively stained cells were counted in 10 fields of view for each specimen preparation at 200x magnification, and the mean value for each preparation was calculated.

### Statistical analysis

The obtained results were subjected to statistical analysis. The differences between the groups were determined using Student's *t*-test (for continuous variables

showing normal distribution) or the Mann-Whitney *U* test (for continuous variables not showing normal distribution). To determine the normality of the variable distribution, the Shapiro-Wilk normality test and the Kolmogorov-Smirnov normality test were used. The  $\chi^2$  test with the Yates' correction and the Fisher's exact test were used to compare categorical variables. *P*-value < 0.05 was considered statistically significant. All statistical calculations were made using Graph Pad Prism version 5.01 software.

## Results

### Expression of IL-17

The quantitative evaluation of IL-17 expression in histological sections was presented as the mean number of positively stained cells in the field of view  $\pm$  SD (Table 1). The number of cells showing IL-17 expression was significantly higher in VLS lesional skin as compared to normal skin of healthy controls ( $p < 0.0001$ ). In VLS lesional skin, IL-17 was expressed in the epidermis and by cells within the inflammatory infiltrate in the upper dermis (Figure 1). The number of cells showing expression of IL-17 in the normal skin was relatively low. Representative immuno-

histochemical stainings of IL-17 in VLS lesional skin and in normal skin is presented in Figure 1.

### Expression of S100A7

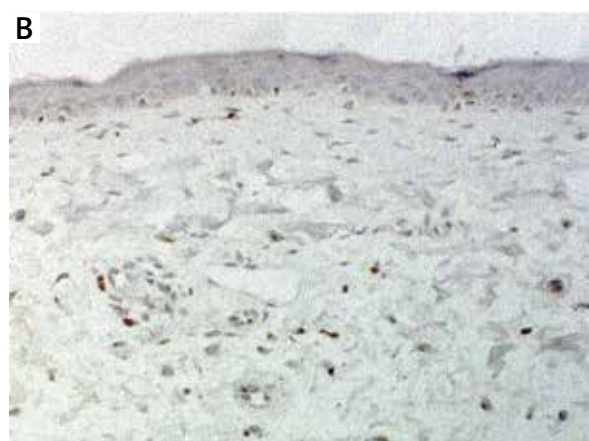
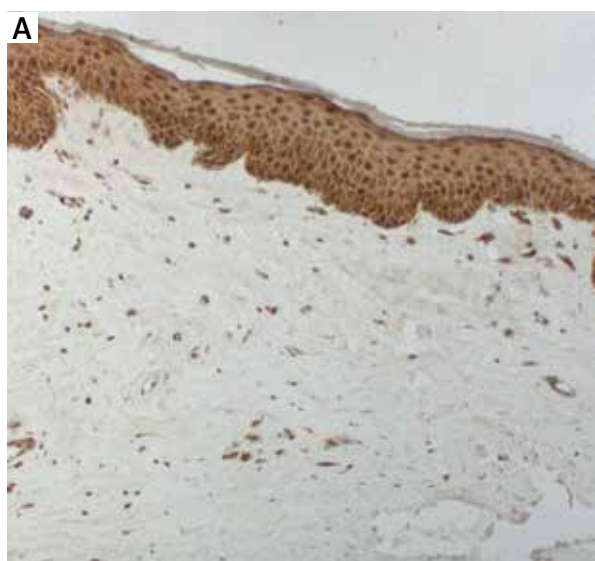
The quantitative evaluation of S100A7 expression in histological sections was presented as the mean number of positively stained cells in the field of view  $\pm$  SD (Table 1). The number of cells showing S100A7 expression was significantly higher in VLS lesional skin as compared to normal skin of healthy controls ( $p < 0.0001$ ) (Table 1). In VLS lesional skin, S100A7 was expressed by suprabasal keratinocytes in epidermis. S100A7 was also expressed by cells within the inflammatory infiltrate in the dermis (Figure 2). Representative immunohistochemical stainings of S100A7 in VLS lesional skin and in normal skin of healthy controls is presented in Figure 2.

## Discussion

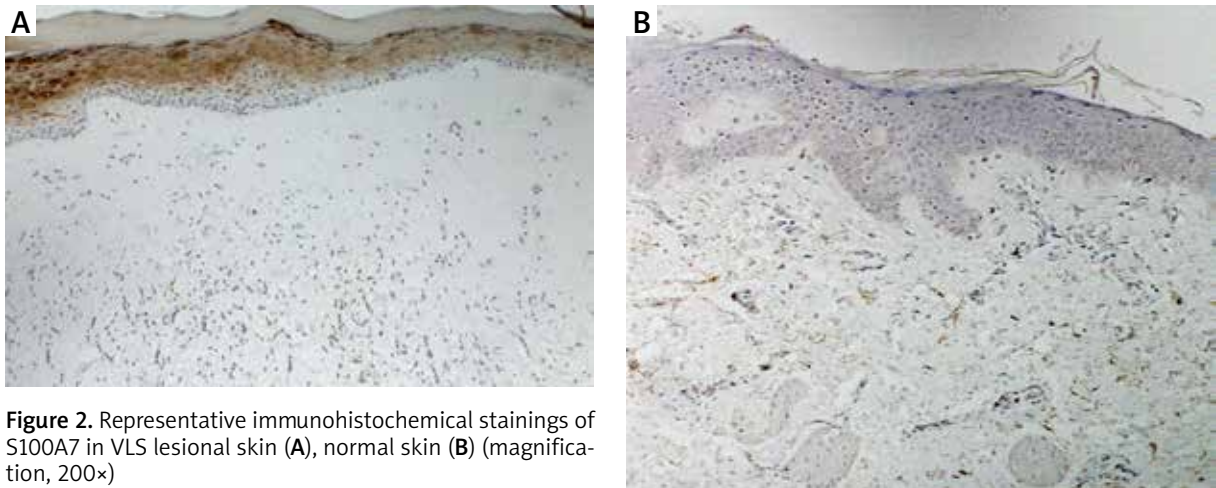
VLS/genital LS is a chronic progressive, lymphocyte-mediated inflammatory disease whose pathogenesis is complex and not fully elucidated. Various studies suggest a pivotal role of an autoimmune response and an immunological dysregulation in the development of LS. Both the primary and acquired immune response appear to be involved in the pathogenesis of this disease [1–3, 10]. The histological features of VLS comprise a dermal inflammatory infiltrate around the dilated capillaries composed mostly of lymphocytes (CD8+ T cells and to a lesser extent, CD4+ T cells) [2, 3, 12, 14]. In the inflammatory infiltrate in VLS, some other cells may be present e.g. mast cells distributed in the superficial dermis and macrophages present in the superficial and deeper part of the dermis (H1). The chronic inflammatory process is likely to induce the production of reactive oxygen species (ROS) which contribute to the skin damage and sclerosis

**Table 1.** The quantitative evaluation of S100A7, IL-17 expression in lesional VLS skin, and normal skin of healthy controls (values expressed as the mean number of positively stained cells  $\pm$  SD)

Parameter	VLS (n = 21)	Normal skin (n = 10)	<i>P</i> -value
IL-17 mean $\pm$ SD	88.97 $\pm$ 20.08	30.14 $\pm$ 14.17	< 0.0001
S100A7 mean $\pm$ SD	67.04 $\pm$ 16.16	14.49 $\pm$ 18.31	< 0.0001



**Figure 1.** Representative immunohistochemical stainings of IL-17 in VLS lesional skin (A), normal skin (B) (magnification, 200 $\times$ )



**Figure 2.** Representative immunohistochemical stainings of S100A7 in VLS lesional skin (A), normal skin (B) (magnification, 200×)

[2, 32]. An overexpression of some proinflammatory cytokines such as TNF- $\alpha$ , IL-1 $\alpha$ , IL-2 have been demonstrated in LS [2, 3, 10, 15]. In the present study we have investigated the expression of IL-17 in lesional skin obtained from female individuals with histologically confirmed genital LS (VLS). We found an increased expression of IL-17 in lesional skin of patients with VLS as compared to normal skin from healthy controls. IL-17 was overexpressed both in the epidermis and in the dermis, by cells within the inflammatory infiltrate. IL-17 is a potent proinflammatory cytokine that plays an important role in the development of the autoimmune inflammatory response. IL-17 is produced by multiple innate and adaptive immune cells including: Th-17 cells, NK cells, CD8+ T cells, innate lymphoid cells,  $\gamma\delta$  T-cells, and mast cells. Within the skin, IL-17 acts on cellular targets including keratinocytes, fibroblasts, neutrophils and endothelial cells and stimulate these cells for production of proinflammatory cytokines and chemokines e.g. TNF- $\alpha$ , IL-1, and IL-8 [16–18]. To the best of our knowledge, the expression of IL-17 has not been elucidated in the lesional skin of VLS. Our group [19] has indicated previously a significantly higher number of cells showing IL-17 expression in patients with cutaneous lichen planus compared to normal skin. The results of this study point toward the involvement of IL-17 in the pathogenesis of VLS. Overexpressed in lesional VLS skin, IL-17 may act on keratinocytes and activate these cells for increased production of proinflammatory mediators enhancing an inflammatory process in the skin. Moreover, IL-17 has been shown to act synergistically with other proinflammatory cytokines e.g. TNF- $\alpha$  to induce the expression of some antimicrobial proteins and to potentiate an inflammatory process [16, 17, 28].

S100A7 is an antimicrobial protein expressed by epidermal keratinocytes, in the inner root sheath of the pilosebaceous gland and in leukocytes: lymphocytes, neutrophils, and monocytes. S100A7 is encoded by the gene located in the epidermal differentiation complex

(EDC) on chromosome 1q21 and is linked to the epidermal differentiation and inflammatory process. It regulates keratinocyte proliferation and differentiation and has proinflammatory activity, therefore may play a role in the pathogenesis of some chronic inflammatory skin diseases with epidermal abnormalities [24–26, 29, 31]. In the current study we have found an increased expression of S100A7 in lesional VLS skin as compared to normal skin. S100A7 was overexpressed in keratinocytes in the suprabasal compartment of epidermis as well as in the dermal inflammatory infiltrate. To the best of our knowledge, the expression of S100A7 has not been much investigated in VLS/genital LS. Our results are consistent with one previously published study. Gambichler *et al.* [33] found an increased expression of S100A7 and human  $\beta$ -defensin (hBD)-2 in lesional LS skin, whereas the expression of other antimicrobial proteins: hBD-1, hBD-3, cathelicidin (LL-37) and RNase 7 was not significantly different than in normal skin. Some exogenous factors e.g. chronic irritation, trauma or alteration in skin microbiota are thought to trigger immune activation and inflammation in VLS. Koebner phenomenon was described in LS [2, 5, 33]. S100A7 has been identified as DAMP – ‘alarmin’. Upon mechanical and microbial stimuli, S100A7 may be released from keratinocytes and induce an inflammatory response. Moreover, IL-17 has been shown to act synergistically with TNF- $\alpha$  to induce expression of S100A7 in keratinocytes [25, 27–29]. Overexpressed in lesional VLS skin, S100A7 may promote epidermal abnormalities and potentiate an inflammatory process in the skin. S100A7 has been shown to stimulate keratinocytes for enhanced production of proinflammatory cytokines, such as TNF- $\alpha$  and IL-8 [28]. Further, S100A7 acts as a chemoattractant for leukocytes (e.g. lymphocytes, monocytes/macrophages and neutrophils) and its chemotactic activity is mediated by the multiligand receptor for advanced glycosylated end products (RAGE). S100A7 – RAGE interactions activate multiple intracellular signalling pathways, in-

cluding nuclear factor  $\kappa$ -light-chain-enhancer of activated B cells (NF- $\kappa$ B) resulting in increased expressions of cellular adhesion molecules and proinflammatory cytokines [25, 27, 29, 31]. The results of our study may point toward the involvement of S100A7 in the pathogenesis of VLS.

## Conclusions

VLS is a chronic, progressive debilitating disease whose pathogenesis is not completely known and has limited therapeutic options [1-3]. The results of our study may suggest the involvement of IL-17 and S100A7 in the pathogenesis of VLS. The better understanding of this disease may lead to the development of novel, effective therapeutic strategies.

## Funding sources

Grant from Wrocław Medical University  
SUBK.C260.22.069.

## Conflict of interest

The authors declare no conflict of interest.

## References

- Kirtschig G, Becker K, Günthert A, et al. Evidence-based (S3) Guideline on (anogenital) Lichen sclerosus. *J EADV* 2015; 29: e1-43.
- Corazza M, Schettini N, Zedde P, et al. Vulvar lichen sclerosus from pathophysiology to therapeutic approaches: evidence and prospects. *Biomedicines* 2021; 9: 950.
- De Luca DA, Papara C, Vorobyev A, et al. Lichen sclerosus: the 2023 update. *Front Med* 2023; 10: 1106318.
- Kraus C. Vulvar lichen sclerosus. *JAMA Dermatol* 2022; 158: 1088.
- Kirtschig G. Lichen sclerosus-presentation, diagnosis and management. *Dtsch Arztebl Int* 2016; 113: 337-43.
- Goldstein A, Marinoff SC, Christopher K, Srodon M. Prevalence of vulvar lichen sclerosus in a general gynecology practice. *J Reprod Med* 2005; 50: 477-80.
- Halonon P, Jakobsson M, Heikinheimo O, et al. Lichen sclerosus and risk of cancer. *Int J Cancer* 2017; 140: 1998-2002.
- Corazza M, Borghi A, Gafà R, et al. Risk of vulvar carcinoma in women affected with lichen sclerosus: results of a cohort study. *J Dtsch Dermatol Ges* 2019; 17: 1069-71.
- Spekreijse JJ, Streng BMM, Vermeulen RFM, et al. The risk of developing squamous cell carcinoma in patients with anogenital lichen sclerosus: a systematic review. *Gynecol Oncol* 2020; 157: 671-7.
- Tran DA, Tan X, Macri CJ, et al. Lichen sclerosus: an auto-immunopathogenic and genomic enigma with emerging genetic and immune targets. *Int J Biol Sci* 2019; 15: 1429-39.
- Cooper SM, Ali I, Baldo M, Wojnarowska F. The association of lichen sclerosus and erosive lichen planus of the vulva with autoimmune disease: a case-control study. *Arch Dermatol* 2008; 144: 1432-5.
- Vuković D, Ogorevc M, Tripković I, et al. The distribution of innervation and immune cell infiltration is different in genital and extragenital variants of lichen sclerosus. *Biomolecules* 2022; 12: 1767.
- Regauer S, Liegl B, Reich O. Early vulvar lichen sclerosus: a histopathological challenge. *Histopathology* 2005; 47: 340-7.
- Terlou, A, Santegoets, LA, van der Meijden WI, et al. An autoimmune phenotype in vulvar lichen sclerosus and lichen planus: a Th1 response and high levels of microRNA-155. *J Invest Dermatol* 2012; 132: 658-66.
- Farrell AM, Dean D, Millard PR, et al. Cytokine alterations in lichen sclerosus: an immunohistochemical study. *Br J Dermatol* 2006; 155: 931-40.
- Ruiz de Morales JM, Puig L, Daudén E, et al. Critical role of interleukin (IL)-17 in inflammatory and immune disorders: an updated review of the evidence focusing in controversies. *Autoimmun Rev* 2020; 19: 102429.
- Blauvelt A, Chiricozzi A. The immunologic role of IL-17 in psoriasis and psoriatic arthritis pathogenesis. *Clin Rev Allergy Immunol* 2018; 55: 379-90.
- Schinocca C, Rizzo C, Fasano S, et al. Role of the IL-23/IL-17 pathway in rheumatic diseases: an overview. *Front Immunol* 2021; 22: 637829.
- Żychowska M, Batycka-Baran A, Baran W. Increased serum level and high tissue immunoreexpression of interleukin 17 in cutaneous lichen planus: a novel therapeutic target for recalcitrant cases? *Dis Markers* 2020; 24: 2020:6521274.
- Eckert RL, Broome AM, Ruse M, et al. S100 proteins in the epidermis. *J Invest Dermatol* 2004; 123: 23-33.
- Donato R. Intracellular and extracellular roles of S100 proteins. *Microsc Res Tech* 2003; 60: 540-51.
- Gonzalez LL, Garrie K, Turner MD. Role of S100 proteins in health and disease. *Biochim Biophys Acta Mol Cell Res* 2020; 1867: 118677.
- Xia C, Braunstein Z, Toomey AC, et al. S100 proteins as an important regulator of macrophage inflammation. *Front Immunol* 2018; 8: 1908.
- Watson PH, Leygue ER, Murphy LC. Psoriasin (S100A7). *Int J Biochem Cell Biol* 1998; 30: 567-71.
- Wolf R, Ruzicka T, Yuspa SH. Novel S100A7 (psoriasin)/S100A15 (koebnerisin) subfamily: highly homologous but distinct in regulation and function. *Amino Acids* 2011; 41: 789-96.
- Gläser R, Harder J, Lange H, et al. Antimicrobial psoriasin (S100A7) protects human skin from *Escherichia coli* infection. *Nat Immunol* 2005; 6: 57-64.
- Wolf R, Howard OM, Dong HF, et al. Chemotactic activity of S100A7 (Psoriasin) is mediated by the receptor for advanced glycation end products and potentiates inflammation with highly homologous but functionally distinct S100A15. *J Immunol* 2008; 181: 1499-506.
- Hegyí Z, Zwicker S, Bureik D, et al. Vitamin D analog calcipotriol suppresses the Th17 cytokine-induced proinflammatory S100 "alarmins" psoriasin (S100A7) and koebnerisin (S100A15) in psoriasis. *J Invest Dermatol* 2012; 132: 1416-24.
- Batycka-Baran A, Hattinger E, Zwicker S, et al. Leukocyte-derived koebnerisin (S100A15) and psoriasin (S100A7) are systemic mediators of inflammation in psoriasis. *J Dermatol Sci* 2015; 79: 214-21.
- Batycka-Baran A, Baran W, Nowicka-Suszko D, et al. Serum concentration and skin expression of S100A7 (psoriasin) in patients suffering from hidradenitis suppurativa. *Dermatology* 2021; 237: 733-9.
- Gläser R, Meyer-Hoffert U, Harder J, et al. The antimicrobial protein psoriasin (S100A7) is upregulated in atopic derma-

- titis and after experimental skin barrier disruption. *J Invest Dermatol* 2009; 129: 641-9.
32. Sander CS, Ali I, Dean D, et al. Oxidative stress is implicated in the pathogenesis of lichen sclerosis. *Br J Dermatol* 2004; 151: 627-35.
33. Gambichler T, Skryganm M, Tigges C, et al. Significant up-regulation of antimicrobial peptides and proteins in lichen sclerosis. *Br J Dermatol* 2009; 161: 1136-42.