



Idiopathic De Novo Arteriovenous Malformation: A Rare Acquired Intracranial Lesion

Tritan Plute¹ Prateek Agarwal² Aneek Patel³ Arka N. Mallela²  L. Dade Lunsford²
Hussam Abou-Al-Shaar²

¹University of Pittsburgh School of Medicine, Pittsburgh, Pennsylvania, United States

²Department of Neurological Surgery, University of Pittsburgh Medical Center, Pittsburgh, Pennsylvania, United States

³Department of Neurological Surgery, New York University Langone Health, New York, New York, United States

Address for correspondence Hussam Abou-Al-Shaar, MD, University of Pittsburgh Medical Center, 200 Lothrop Street, Suite B-200, Pittsburgh, PA 15213, United States
(e-mail: aboualshaar@upmc.edu).

AJNS 2023;18:400–403.

Abstract

The de novo development of cerebral arteriovenous malformations (AVMs) in adults is an exceedingly rare event that has prompted the theory that a “second hit” is required to induce AVM formation. The authors document development of an occipital AVM in an adult a decade and a half after a brain magnetic resonance imaging (MRI) disclosed no abnormality. A 31-year-old male with a family history of AVMs and a 14-year history of migraines with visual auras and seizures presented to our service. Because of the onset of a first seizure and migraine headaches at age 17, the patient underwent high-resolution MRI that showed no intracranial lesion. After 14 years of progressively worsening symptoms, he underwent a repeat MRI that demonstrated a new de novo Spetzler-Martin grade 3 left occipital AVM. The patient received anticonvulsants and underwent Gamma Knife radiosurgery for his AVM. This case suggests that patients with seizures or persistent migraine headaches should have periodic repeat neuroimaging to exclude the development of a vascular cause despite an initial negative MRI.

Keywords

- ▶ arteriovenous malformations
- ▶ Gamma Knife radiosurgery
- ▶ de novo
- ▶ genetic
- ▶ seizures

Introduction

Cerebral arteriovenous malformations (AVMs) are rare, complex vascular lesions of uncertain pathogenesis involving dysplastic vessel formation.¹ Originally thought to be exclusively congenital,² intracerebral AVMs are now known to also arise de novo^{3–5} in those with genetically predisposed disorders (e.g., ataxia telangiectasia).⁶ Some authors suggest that AVMs arise when individuals with genetic predispositions experience one

or more “second hits.”⁷ Such “second hits” include events that promote dysplastic angiogenesis such as brain hemorrhage, trauma, or venous sinus thrombosis.⁵ To the best of our knowledge, distinct “second hits” preceded all reported intracranial AVMs but one.^{5,8} Here, the authors present a rare case of a patient with a family history of AVMs presenting with an idiopathic de novo occipital AVM with no identifiable antecedent “second hit” and absence of any intracranial lesion on adolescence high-resolution imaging.

article published online
June 16, 2023

DOI <https://doi.org/10.1055/s-0043-1769893>.
ISSN 2248-9614.

© 2023. Asian Congress of Neurological Surgeons. All rights reserved.

This is an open access article published by Thieme under the terms of the Creative Commons Attribution-NonDerivative-NonCommercial-License, permitting copying and reproduction so long as the original work is given appropriate credit. Contents may not be used for commercial purposes, or adapted, remixed, transformed or built upon. (<https://creativecommons.org/licenses/by-nc-nd/4.0/>)

Thieme Medical and Scientific Publishers Pvt. Ltd., A-12, 2nd Floor, Sector 2, Noida-201301 UP, India

Case History

A 17-year-old male with a family history of AVM (including a brother with an AVM of the corpus callosum) presented to the emergency room due to migraines accompanied by visual auras and generalized seizure. The patient underwent high-resolution magnetic resonance imaging (MRI), which failed to demonstrate any intracranial pathology (►Fig. 1A–C). The patient continued to have rare repeat seizures, but antiepileptic drugs were not initiated at any point due to the patient's and parents' preference. The patient had a history of prior intravenous drug use, hepatitis C infection, and pre-diabetes.

Fourteen years after his initial presentation, the 31-year-old patient reported to the emergency department for a head injury sustained during a seizure. Computed tomography angiography of the head revealed a 1.9×1.4 cm hyperattenuating vascular mass within the left occipital lobe (►Fig. 2) with no evidence of hemorrhage. Cerebral angiography confirmed the presence of an unruptured 2.9 cm Spetzler-Martin grade 3 left occipital AVM (►Fig. 3). The AVM was supplied by the calcarine and posterior temporal branches of the posterior cerebral artery and had both superficial and deep venous drainage. This occipital AVM was also demonstrated on MR imaging performed at that time (►Fig. 1D–F).

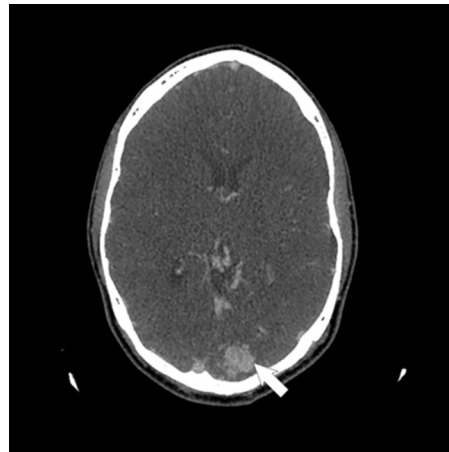


Fig. 2 Computed tomography angiography imaging from second presentation (age 31) demonstrating a left occipital hyperdensity (white arrow) suggestive of a left occipital arteriovenous malformation with no evidence of intracranial hemorrhage.

Following diagnosis, the patient was started on levetiracetam and referred to our service for further evaluation. The patient subsequently underwent Gamma Knife radiosurgery, during which the margin dose of the AVM was 20 Gy, with 85% of the AVM receiving over 22 Gy, and the 12 Gy volume

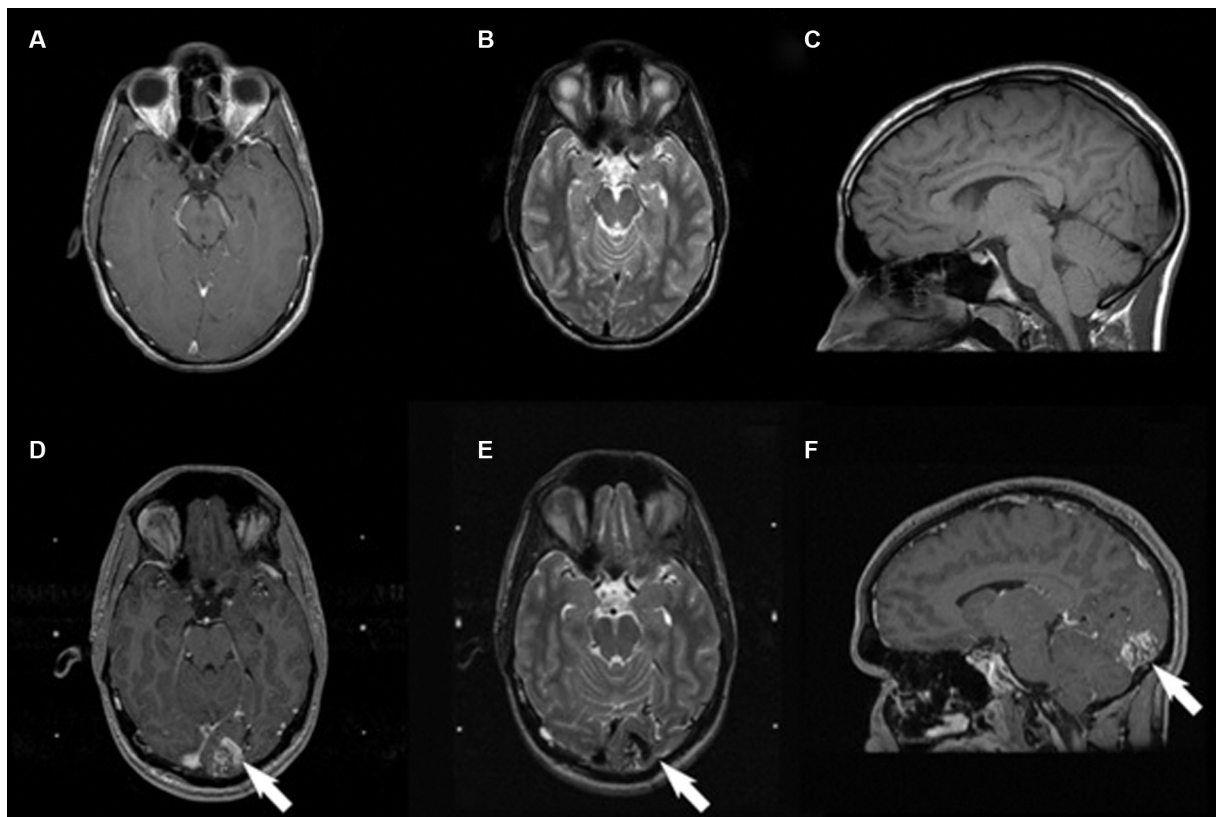


Fig. 1 Magnetic resonance imaging findings from initial presentation to second presentation showing de novo formation of a Spetzler-Martin grade 3 left occipital arteriovenous malformation (AVM). Axial T1-weighted image with contrast (A), axial T2-weighted image (B), and sagittal noncontrast T1-weighted image (C) from age 17 demonstrating no evidence of vascular pathology. Axial contrasted T1-weighted image (D), axial T2-weighted image (E), and sagittal contrasted T1-weighted image (F) at age 31 demonstrating a new left occipital AVM (white arrow) denoted by hypointense signal.

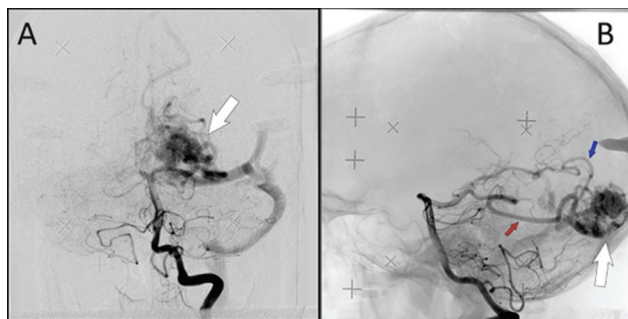

Fig. 3 Left vertebral digital subtraction angiography demonstrating a Spetzler-Martin grade 3 arteriovenous malformation (AVM; white arrows). Anteroposterior projection (A) revealing posterior cerebral artery branch supply and both superficial and deep venous drainage. Lateral projection (B) of AVM nidus demonstrating calcarine (blue arrow) and posterior temporal (red arrow) branches of the posterior cerebral artery supplying the AVM.

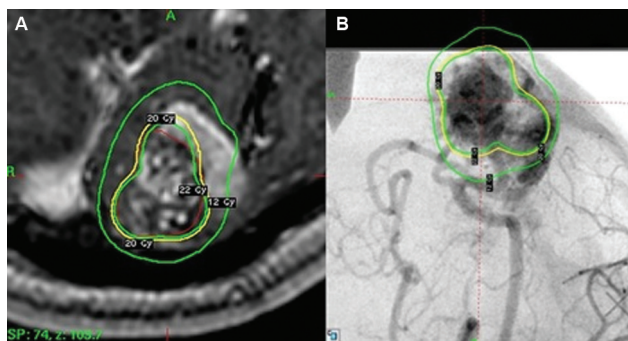


Fig. 4 Gamma Knife radiosurgery operative plan. (A) Axial contrasted T1-weighted image and (B) digital subtraction angiography demonstrating the treatment plan to the lesion receiving a marginal dose of 20 Gy (yellow).

was 9 mL (→ Fig. 4). The patient was discharged on a continued dose of levetiracetam with plans for follow-up MRIs at 6 months then 1, 2, and 3 years to monitor his response to treatment. Repeat cerebral angiography is planned 3 years after stereotactic radiosurgery.

Discussion

The rare development of an AVM in adulthood is thought by some to require a “second hit” to initiate AVM formation.⁸ To the best of our knowledge, all but one documented case of de novo AVMs has been attributed to subsequent neurological trauma, hemorrhage, or venous sinus thrombosis in cases of dural arteriovenous fistulas. Cavernous malformation development is seen in patients with a family history related to defects in endoglin and activin-receptor-like kinase (ALK) genes and in some patients, they are delayed after childhood radiation therapy.⁵ Nagai et al reported a 69-year-old male who presented 12 years prior to the discovery of their AVM with transient dizziness; yet, similar to our patient, earlier imaging revealed no obvious vascular malformation. Likewise, our case, similar to Nagai’s, presented with no antecedent trauma, intracranial bleeding, or lesion on imaging.

The patient’s initial imaging was completely devoid of any vascular pathology, and yet he spent over a decade experiencing symptoms commonly caused by AVMs. These included persistent seizures and complex migraines, which are common among AVMs patients.⁹ In this case, however, no focal lesion was noted on initial high-resolution MRI. Similar lack of findings has occasionally been attributed to inadequate imaging modalities; however, it has been shown that modern MRI technology seldom fails to detect AVMs of any size or type.¹⁰ Therefore, we cannot exclude that the patient in this report had a “second hit” related to lifestyle events that included drug use and resultant hepatitis infection.

Numerous genes, growth factors, and enzymes have been hypothesized to facilitate AVM formation,¹¹ with two of the more commonly-cited biomolecules, vascular endothelial growth factor and ALK, affecting angiogenesis and pathogenesis, respectively.³ Dysregulation of these molecules can lead to small, weak vessel formation and AVM development in genetically predisposed patients.^{12,13} In the aftermath of hemorrhage or traumatic injury, activation of these pathways could initiate aberrant vessel repair, thus acting as a “second hit” for AVM formation.

Chronic diseases such as diabetes and congestive heart disease are known to place immense physiological stress on many organs, including the vasculature. Chronic conditions could induce intracranial hypertension or other forms of cerebral vascular damage, thus providing the “second hit” needed to spur AVM generation.¹⁴ Additionally, over 100 medical and illicit pharmacological agents, including heroin, have been shown to cause drug-induced intracranial hypertension.^{15,16} Our patient had a history of prior drug use, hepatitis C infection, and prediabetes, all of which could have provided potential “second hits” and contributed to AVM formation. In the case presented by Nagai et al,⁵ their patient also had chronic medical conditions including hypertension, chronic renal failure, and diabetes mellitus, which may have contributed to the development of a de novo Spetzler-Martin grade 2 AVM of the left posterior parietal lobe.⁵ While their patient was of a more advanced age and presented with differing comorbidities than the case presented, both cases represent unique instances in which “second hits” seemingly arose from chronic rather than acute conditions and progressed along a similar timeline (12 and 14 years, respectively).

Conclusion

Documented de novo intracranial AVM formation is an exceedingly rare entity. We suggest that additional longstanding chronic conditions could act as comorbidity facilitators of AVM formation. In the context of persistent clinical symptoms such as migraine and seizures, repeat brain imaging is important to exclude delayed development of a treatable and high-risk AVM.

Authors’ Contributions

Tritan Plute was responsible for data collection, writing and primary generation of the manuscript. Prateek

Agarwal was the primary resident involved with the case and provided insight into the case and assisted with writing. Aneek Patel was involved with the case write-up and provided neurosurgical insight. Arka Mallela provided key insight into the research process and assisted with manuscript writing. Lunsford was responsible for identifying the case as novel, obtaining patient consent, writing, and providing expert opinion regarding the case. Abou-Al-Shaar was responsible for the design of the report and advising Plute during the research process; he was also responsible for writing manuscript generation.

Ethical Approval

All procedures performed in studies involving human participants were in accordance with the ethical standards of the institutional and/or national research committee of University of Pittsburgh Medical Center and with the 1964 Helsinki declaration and its later amendments. Informed consent was obtained from the patient included in the study.

Funding

None.

Conflict of Interest

None declared.

References

- Rutledge C, Cooke DL, Hetts SW, Abla AA. Brain arteriovenous malformations. *Handb Clin Neurol* 2021;176:171–178
- Hamada J, Yonekawa Y. Spontaneous disappearance of a cerebral arteriovenous malformation: case report. *Neurosurgery* 1994;34(01):171–173
- Mahajan A, Manchandia TC, Gould G, Bulsara KR. De novo arteriovenous malformations: case report and review of the literature. *Neurosurg Rev* 2010;33(01):115–119
- Park H, Koh EJ, Lee EJ, Cheon JE, Kim SK. An acquired cerebral arteriovenous malformation after brain abscess treatment: case report and a review of the literature. *Childs Nerv Syst* 2021;37(09):2923–2926
- Nagai Y, Anan M, Fujiki M. Cerebral arteriovenous malformations as acquired lesions: case reports and review of the literature. *J Stroke Cerebrovasc Dis* 2020;29(10):105157. Doi: 10.1016/j.jstrokecerebrovasdis.2020.105157
- Karlsson B, Johansson AV, Yang HC, et al. A novel method to determine the natural course of unruptured brain arteriovenous malformations without the need for follow-up information. *J Neurosurg* 2018;129(Suppl 1):10–16
- Park SO, Wankhede M, Lee YJ, et al. Real-time imaging of de novo arteriovenous malformation in a mouse model of hereditary hemorrhagic telangiectasia. *J Clin Invest* 2009;119(11):3487–3496
- Tasiou A, Tzerefos C, Alleyne CH Jr, et al. Arteriovenous malformations: congenital or acquired lesions? *World Neurosurg* 2020;134:e799–e807
- Yan L, Tao W, Zhan Q, Huang Z, Chen F, Li S. Angioarchitectural features of brain arteriovenous malformation presented with seizures. *Neurosurg Rev* 2022;45(04):2909–2918
- Gross BA, Frerichs KU, Du R. Sensitivity of CT angiography, T2-weighted MRI, and magnetic resonance angiography in detecting cerebral arteriovenous malformations and associated aneurysms. *J Clin Neurosci* 2012;19(08):1093–1095
- Sweeney M, Foldes G. It takes two: endothelial-perivascular cell cross-talk in vascular development and disease. *Front Cardiovasc Med* 2018;5:154. Doi: 10.3389/fcvm.2018.00154
- Park SO, Lee YJ, Seki T, et al. ALK5- and TGFBR2-independent role of ALK1 in the pathogenesis of hereditary hemorrhagic telangiectasia type 2. *Blood* 2008;111(02):633–642
- Tual-Chalot S, Garcia-Collado M, Redgrave RE, et al. Loss of endothelial endoglin promotes high-output heart failure through peripheral arteriovenous shunting driven by VEGF signaling. *Circ Res* 2020;126(02):243–257
- Grossen AA, Shi HH, O'Neal CM, Bauer AM. Impact of obesity and diabetes on postoperative outcomes following surgical treatment of nontraumatic subarachnoid hemorrhage: analysis of the ACS-NSQIP database. *World Neurosurg* 2022;163:e290–e300
- Tan MG, Worley B, Kim WB, Ten Hove M, Beecker J. Drug-induced intracranial hypertension: a systematic review and critical assessment of drug-induced causes. *Am J Clin Dermatol* 2020;21(02):163–172
- Yin R, Lu C, Chen Q, Fan J, Lu J. Microvascular damage is involved in the pathogenesis of heroin induced spongiform leukoencephalopathy. *Int J Med Sci* 2013;10(03):299–306