

Renal hemorrhagic actinomycotic abscess in pregnancy

Marcela C. Smid,^{1,2} Neha R. Bhardwaj,²
Laura M. Di Giovanni,² Scott Eggener,³
Micaela Della Torre²

¹Department of Obstetrics and Gynecology, Division of Maternal Fetal Medicine, University of North Carolina at Chapel Hill School of Medicine, NC; ²Department of Obstetrics and Gynecology, Chicago Lying in Hospital, University of Chicago Medicine, IL; ³Section of Urology, University of Chicago Medicine, IL, USA

Abstract

Actinomyces israelii is a gram-positive, filamentous anaerobic bacteria colonizing the oral and gastrointestinal tracts. Retroperitoneal actinomycotic abscess is uncommon and its rare presentation as a hemorrhagic mass may be confused with malignancy. We present a case of this unusual infection complicating pregnancy. Increased awareness of actinomycotic abscess in the differential diagnosis of renal mass concerning for malignancy is critical to early recognition and treatment of this rare infection and most importantly, avoidance of unnecessary surgical intervention.

Case Report

A 20-year-old Puerto Rican woman, G2P0101, was referred to us at 24 weeks gestation for evaluation of an 11 cm right upper quadrant mass and anemia. She reported a history of cholelithiasis, childhood seizure disorder, left upper extremity embolectomy and a laparoscopic appendectomy in prior pregnancy at six weeks gestation, although operative and imaging records were unavailable. Her previous delivery was a Cesarean section. She had no history of poor dentition or intrauterine device (IUD) use. One month before admission to our hospital, she reported fatigue, 25 pound weight loss over six months, and severe right-sided pain. At another hospital, she underwent right upper quadrant and renal ultrasound revealing stones and sludge in the gallbladder. Ultrasound noted an 8×9×11 cm hemorrhagic mass in the right renal subcapsular area extending to the right diaphragm. At this time, differential diagnosis included angiomyolipoma with hemorrhagic rupture, renal carcinoma, lymphoma, metanephric adenoma and renal/pelvic tuberculosis. Chest radiograph was within normal limits. Her hemoglobin was initially 7 g/dL and

increased to 12 g/dL after 2 units packed red blood cells. Creatinine was 0.6 mg/dL. Tuberculin skin test was negative. Urology and medical oncology consultations were obtained. She was managed with *nil per os* (NPO) status, analgesics, and additional two units of packed red blood cells after her hemoglobin decreased to 8.8 g/dL over four days.

A non-contrast magnetic resonance imaging (MRI) of the abdomen and pelvis was obtained to further characterize the mass and to identify any possible renal vasculature anomalies. MRI showed an 11.2×7.7 cm right renal mass (Figure 1). She developed preterm contractions and received nifedipine and a betamethasone course for fetal lung maturity. Her cervical exam remained unchanged. An ultrasound-guided right kidney biopsy of medulla and cortex revealed mild to moderate patchy interstitial inflammation with no evidence of malignancy. Immunochemical staining for kappa and lambda light chain and periodic acid Schiff staining demonstrated lymphoplasmacytic infiltrate, indicating acute interstitial nephritis, however renal function was normal. Differential diagnosis based on pathological studies included angiomyolipoma and interstitial inflammation secondary to unbiopsied renal mass with less likely possibility of renal carcinoma, lymphoma and metanephric adenoma. Given the inconclusive biopsy with no indication of malignancy, stable hemodynamic status and advanced gestation, the multi-disciplinary team recommended expectant management with close monitoring for mass size change and hemodynamic status. On hospital day 19, patient was discharged home. Interval MRIs showed stable size of the mass throughout her pregnancy. At 35 weeks gestation, the patient was admitted for preterm labor. She underwent a vacuum assisted vaginal delivery of a 2595-gram male infant. Placenta pathology showed mature third trimester placenta without evidence of inflammation or infection. The presumptive diagnosis of the mass was angiomyolipoma with hematoma as there are many reports of ruptured angiomyolipoma with hemorrhage in the obstetric literature;¹⁻⁴ the plan was to repeat the MRI study six weeks post-partum.

Twelve days after delivery, the patient returned with fever, right flank pain and leukocytosis of 19.7 K/UL. She was taken to the operating room where she underwent a right renal exploration, resection of retroperitoneal mass and partial nephrectomy. The pathology report revealed xanthogranulomatous pyelonephritis with occasional clusters of actinomyces infection (Figure 2). Her operation was complicated by an unsuspected duodenal injury necessitating exploratory laparotomy and repair two days later. Pathology from resection of duodenal mass showed abscess, granulation tissue and xanthogranulomatous inflammation without evidence of actinomycotic infection. Multiple pelvic

Correspondence: Marcela C. Smid, Department of Obstetrics and Gynecology, Division of Maternal Fetal Medicine, University of North Carolina at Chapel Hill School of Medicine, 3010 Old Clinic Building, CB #7516, Chapel Hill, NC 27599-7516, USA.

Tel.+1.919.966.4103 - Fax: +1.919.966.6377.

E-mail: marcela_smid@med.unc.edu

Key words: actinomyces, abscess, pregnancy complication, kidney.

Acknowledgments: we would thank Dr. David Grimes for his assistance in the preparation of this manuscript.

Contributions: the authors contributed equally.

Conflict of interests: the authors declare no potential conflict of interests.

Received for publication: 5 November 2013.

Revision received: 29 January 2014.

Accepted for publication: 4 February 2014.

This work is licensed under a Creative Commons Attribution NonCommercial 3.0 License (CC BY-NC 3.0).

©Copyright M.C. Smid et al., 2014
Licensee PAGEPress, Italy
Infectious Disease Reports 2014; 6:5157
doi:10.4081/idr.2014.5157

fluid collections were treated with percutaneous drains inserted by interventional radiology. She was started on piperacillin/ tazobactam then switched to amoxicillin/clavulanate for six months. Subsequent computerized tomography (CT) imaging showed complete resolution of mass.

Discussion

Actinomyces israelii as the cause of renal mass is rare and can be associated with severe sequelae.⁵ We are aware of one published case of retroperitoneal bleeding associated with this type of abscess.⁶ The source of actinomycotic infection is often unknown. In the gynecological literature, cases of IUD associated with pelvic actinomyces infections mimicking malignancy have been reported and in one case with renal failure.^{7,8} However, our patient did not have any history of IUD use. Neither pelvic nor renal actinomycosis has been reported in the obstetric literature. It is unlikely that the actinomycotic infection played a role in her preterm delivery as the placenta and membranes showed now evidence of infection. Her strongest risk factor for preterm delivery was her previous preterm delivery.⁹ Interestingly, the patient did have a laparoscopic appendectomy in her pregnancy two years

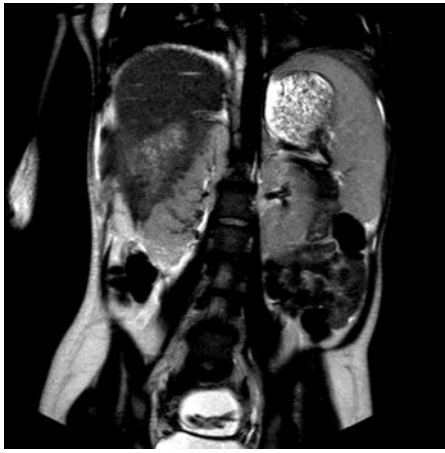

Figure 1. Non-contrast magnetic resonance imaging of abdomen and pelvis: heterogeneous mass 11.2×7.7 cm arising from right kidney extending to liver edge, splenomegaly with spleen measuring 15.2 cm and mild right hydronephrosis.

prior to presentation. Actinomyces has been associated with appendicitis in case reports and may have been the initial source of peri-nephric infection.¹⁰⁻¹² Splenomegaly, which was present in our case, and actinomycotic infection has been associated with splenic rupture.¹³ Dental caries may be a possible source of spread to perinephric structures,¹⁴ however our patient had no known dental disease.

The initial diagnosis of actinomycotic abscess is difficult and presentation as pelvic or renal mass is often confused with renal or gynecological malignancy.^{5,14-16} We recognize that pre-operative diagnosis is difficult given non-specific findings and low index of suspicion. On initial biopsy, we found only dense fibrotic tissue without sulfur granules. Clinicians should be aware that actinomycotic abscesses are characterized by slow growth, abscess formation ignoring normal tissue planes and dense fibrosis.¹⁷ The absence of sulfur granules on biopsy does not exclude actinomycotic infection as these abscesses form centrally with surrounding neutrophils. The presence of dense fibrotic tissue on biopsy may be the only clue to the true diagnosis. Even intra-operatively, multiple biopsies of the abscess may be necessary to obtain a sample showing sulfur granules and increased vigilance should be taken as normal tissues planes may be distorted.¹⁸ When accurately diagnosed, actinomyces infection has an excellent response with intravenous penicillin for 4-6 weeks followed by oral penicillin for or amoxicillin for 6-12 months. Erythromycin or clindamycin are acceptable alternatives for penicillin allergic patient. Tetracylin is also acceptable for the non-pregnant patient.

Due to low index of suspicion for actinomycotic infection and patient's clinical instability at post-partum presentation, definitive diagnosis was not obtained prior to surgical procedure. However, we hope that other clinicians will be

cautioned by our experience and include actinomycosis on the differential of hemorrhagic renal mass in the pregnant and non-pregnant patient.

Conclusions

Consideration of actinomycotic infection in the differential diagnosis of renal or pelvic mass with fevers and weight loss is important as recognition may avoid laparotomy, hasten treatment with antibiotics, and decrease intraoperative complication from distorted tissue planes.¹⁶ We hope that our experience increases awareness of actinomycotic renal infection in the obstetric and general population.

References

1. Wang HB, Yeh CL, Hsu KF. Spontaneous rupture renal angiomyolipoma with hemorrhagic shock. *Intern Med* 2009;48:1111-2.
2. Lopater J, Hartung O, Bretelle F, Bastide C. Management of angiomyolipoma vena cava thrombus during pregnancy. *Obstet Gynecol.* 2011;117:440-3.
3. Kontos S, Politis V, Fokitis I, et al. Rapture of renal angiomyolipoma during pregnancy: a case report. *Cases J* 2008;1:245.
4. Koh JL, Lee YH, Kang CY, Lin CN. Simultaneous cesarean section and radical nephrectomy for angiomyolipoma with spontaneous bleeding during pregnancy: a case report. *J Reprod Med* 2007;52:338-40.
5. Horino T, Yamamoto M, Morita M, et al. Renal actinomycosis mimicking renal tumor: case report. *South Med J* 2004;97:316-8.
6. Monzón A, Alvarez Múgica M, Seco Navedo

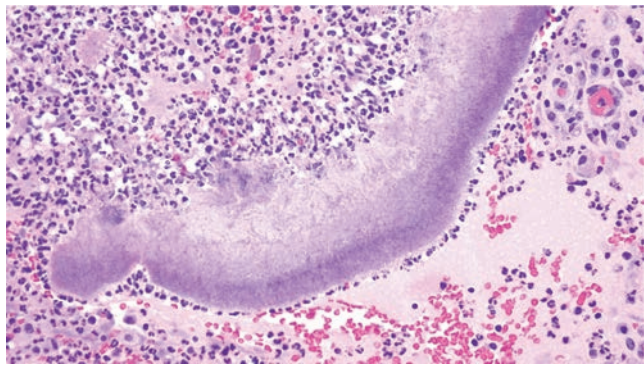


Figure 2. High power view Hematoxylin and Eosin stain of abscess: sulfur granules of actinomyces colonies with dense lymphocytic infiltrate.

MA, et al. A new form of presentation of renal actinomycosis: renal tumor with retroperitoneal bleeding. *Arch Esp Urol* 2006;59:756-9.

7. Marret H, Wagner N, Ouldamer L, et al. Pelvic actinomycosis: just think of it. *Gynecol Obstet Fertil* 2010;38:307-12.
8. Ugezu CH, Kelly I, Walker F, Stratton JF. A case of pelvic actinomycosis with bilateral hydronephrosis and renal failure associated with prolonged intrauterine contraceptive systems use. *J Obstet Gynaecol* 2012;32:403-4.
9. Goldenberg RL, Culhane JF, Iams JD, Romero R. Epidemiology and causes of PTB. *Lancet* 2008;371:75-84.
10. Mumme T, Peiper C, Biesterfeld S, Schumpelick V. Acute retrocecal appendicitis caused by an *Actinomyces israelii* mixed infection. *Zentralbl Chir* 2001;126:632-10.
11. Yiğiter M, Kiyici H, Arda IS, Hiçsönmez A. Actinomycosis: a differential diagnosis for appendicitis. A case report and review of the literature. *J Pediatr Surg* 2007;42:E23-6.
12. Lee SY, Kwon HJ, Cho JH, et al. Actinomycosis of the appendix mimicking appendiceal tumor: a case report. *World J Gastroenterol* 2010;16:395-7.
13. Sperling, RL, R Heredia, WJ Gillesby, et al. Rupture of the spleen secondary to Actinomycosis. *Arch Surg* 1967;94:344-8.
14. Akhan SE, Dogan Y, Akhan S, et al. Pelvic actinomycosis mimicking ovarian malignancy: three cases. *Eur J Gynaecol Oncol* 2008;29:294-7.
15. Pusiol T, Morichetti D, Pedrazzani C, Ricci F. Abdominal-pelvic actinomycosis mimicking malignant neoplasm. *Infect Dis Obstet Gynecol* 2011;2011:747059.
16. Dieckmann KP, Henke RP, Ovenbeck R. Renal actinomycosis mimicking renal carcinoma. *Eur Urol* 2001;39:357-9.
17. Smego RA Jr, Foglia G. Actinomycosis. *Clin Infect Dis* 1998;26:1255-61.
18. Khalaff H, Srigley JR, Klotz LH. Recognition of renal actinomycosis: nephrectomy can be avoided. Report of a case. *Can J Surg* 1995;38:77-9.