



Original Article

Immediate and long-term outcomes of balloon mitral valvotomy in pregnancy



Krishnarpan Chatterjee, Roopali Khanna, Ankit Sahu, Sudeep Kumar, Naveen Garg, Satyendra Tewari, Aditya Kapoor, Pravin K. Goel*

Department of Cardiology, Sanjay Gandhi Post Graduate Institute of Medical Sciences, Lucknow, India

ARTICLE INFO

Article history:

Received 6 November 2019

Accepted 19 May 2020

Available online 30 May 2020

Keywords:

Mitral stenosis

Pregnancy

Balloon mitral valvotomy

ABSTRACT

Objectives: To study the immediate maternal and fetal outcomes and long term maternal outcomes in pregnant women undergoing balloon mitral valvotomy.

Methods: We retrospectively analyzed balloon mitral valvotomy during pregnancy performed between January 2008 and July 2018.

Results: BMV was carried out in 97 pregnant women with mean age of 26.1 ± 4.5 years, at mean gestational age of 23.1 ± 4.6 weeks. The procedure was successful in 95 patients (97.9%). There was one maternal death post procedure due to intra-uterine death and disseminated intravascular coagulation. Adverse immediate fetal outcome was seen in 2 cases with one intra-uterine fetal demise and one preterm labour. Mitral valve area increased from mean of 0.82 ± 0.12 cm to 1.66 ± 0.14 cm ($p < 0.001$). Mean trans-mitral diastolic gradient decreased from 19.7 ± 5.6 mm Hg to 7.5 ± 2 mm Hg. Right ventricular systolic pressure decreased significantly from mean of 56.7 ± 16.2 mm Hg to mean of 35.6 ± 11 mm Hg. Survival analysis showed cumulative event free survival of 89% at 5 years and 65% at 10 years, considering a composite endpoint of clinical restenosis, repeat BMV or MVR or cardiovascular death.

Conclusions: Balloon mitral valvotomy is a safe and effective treatment for severe mitral stenosis during pregnancy. Long term maternal outcomes after BMV done during pregnancy are good and comparable to that of BMV done in non-pregnant patients.

© 2020 Published by Elsevier B.V. on behalf of Cardiological Society of India. This is an open access article under the CC BY-NC-ND license (<http://creativecommons.org/licenses/by-nc-nd/4.0/>).

1. Introduction

Rheumatic heart disease complicates pregnancy in a high number of women in countries like India with high endemicity of rheumatic fever. Mitral stenosis remains the commonest valvular heart disease encountered during pregnancy in India.¹

Mitral stenosis is poorly tolerated in pregnancy because of increased hemodynamic burden. There is a physiological increase in heart rate, blood volume during pregnancy which cannot be accommodated in the heart with mitral stenosis. This leads to increase in mean left atrial pressure, and pulmonary venous pressure which may precipitate heart failure and pulmonary edema especially during the third trimester and peri-partum period.^{2,3} The risk

of maternal death is greatest during labor and the immediate postpartum period. There is auto transfusion from the uterus during this time, which reaches the central circulation. This suddenly increases the pre-load immediately after delivery, leading to decompensation. This auto transfusion continues upto 24–72 h after delivery and thus the chance of decompensation continues until that time. A significant number of patients remain symptomatic in spite of optimum medical therapy, necessitating mechanical relief of mitral stenosis. Surgical mitral valvotomy was a therapeutic option for mitral stenosis in pregnancy before percutaneous balloon mitral valvotomy (BMV) during pregnancy was demonstrated to be safe and effective. But surgical valvotomy has adverse fetal outcomes.^{4–7} Surgical mitral valve replacement during pregnancy is often viewed as a challenge by surgeons due to unpredictable hemodynamics during and after cardio pulmonary bypass (CPB). The long term fetal safety of percutaneous balloon mitral valvotomy has been shown.^{8–10}

* Corresponding author. Head Department of Cardiology Department of cardiology, Sanjay Gandhi PostGraduate Institute of Medical Sciences, Rae Bareilly Road, Lucknow, 226014, India.

E-mail address: golf_pgi@yahoo.co.in (P.K. Goel).

We conducted this retrospective study of percutaneous balloon mitral valvotomy during pregnancy to assess the immediate and long term maternal outcomes as well as the immediate fetal outcomes.

2. Methods

A retrospective analysis of all percutaneous balloon mitral valvotomy during pregnancy performed between January 2008 and July 2018 was carried out. Both online hospital information system based and offline register based search was carried out.

Percutaneous balloon mitral valvotomy was done in pregnant patients with severe symptomatic mitral stenosis with:

(i) Two-dimensional echocardiography mitral valve area $< 1 \text{ cm}^2$ by planimetry (ii) valve morphology suitable for percutaneous balloon mitral valvotomy (iii) mean trans-mitral diastolic gradient $> 10 \text{ mm Hg}$ (iv) mitral regurgitation not more than mild (v) absence of left atrial or left atrial appendage thrombus.

Detailed clinical and echocardiographic evaluation was done before the procedure with emphasis on functional class, rhythm, mitral valve area, mitral valve suitability for BMV, mitral regurgitation, mean trans-mitral diastolic gradient, right ventricular systolic pressure. All patients underwent obstetric evaluation before the procedure and intra-procedural fetal monitoring was done at the discretion of the obstetric team.

Balloon mitral valvotomy was done using Inoue dual lumen balloon (Toray) or Accura single lumen through trans-femoral route with abdominal shielding using a lead apron. Local or general anesthesia was used as per preference of anesthesiologist. A partial left lateral decubitus position was maintained by keeping a rolled-up towel under right hip to relieve compression of inferior vena cava by the pregnant uterus. The balloon was sized according to patient's height by the $(\text{height in cm}/10) + 10$ formula. Balloon was undersized by -1 to -2 mm from the calculated measurement as per the operator's discretion. Right heart catheterization and hemodynamic measurements were done before and after balloon dilation.

Procedure was considered successful when (i) there was more than 50% increase in 2D MVA from baseline with an absolute 2D MVA greater than 1.5 cm^2 (ii) no post-procedural increase in mitral regurgitation by more than one grade with final mitral regurgitation not more than mild. Post procedural obstetric evaluation was done to check for immediate complications including rupture of membranes, preterm labour and fetal demise.

Clinical and echocardiographic follow up was done after BMV at one month, 6 months and then yearly thereafter. Follow up period was recorded with a composite endpoint of restenosis (clinical, echocardiographic, repeat BMV and MVR) and failed BMV (non-responding valve or severe mitral regurgitation), as the event of interest.

2.1. Statistical analysis

Categorical data were expressed as counts and percentages. Continuous variables were expressed as mean \pm standard deviation. Comparison of means was done with paired *t*-test. Wilcoxon matched-pair signed-rank test was done for paired ordinal data. Survival analysis was done using life tables and Kaplan–Meier method. *P* values < 0.05 were considered significant. All statistical analysis was performed with SPSS software, Version 23.0 (IBM Corporation, Armonk, NY, USA).

3. Results

During the study period, BMV was carried out in 97 pregnant women. Baseline clinical characteristics of the patients are shown in Table 1. Mean age at the time of procedure was 26.1 ± 4.5 years (range = 18–40 years). Mean gestational age was 23.1 ± 4.6 weeks, (range = 14–34 weeks). Majority of the patients (83.5%) underwent the procedure in the second trimester, but 16 patients (16.5%) had the procedure in the third trimester as all these patients had presented to our centre for the first time in the third trimester. Thirteen patients (13.4) had prior history of valvotomy (12 had history of BMV, 1 had undergone CMV) and presented with restenosis during pregnancy. Atrial fibrillation was present in 7 (7.2%) women. Majority of patients were in NYHA functional class II (81 out of 97; 83.5%) while 14 (14.2%) and 2 (2.1%) patients were in functional class III and IV respectively. Pre-procedural trans-esophageal echocardiography (TEE) was done in 2 patients with suspicion of left atrial appendage thrombus. TEE did not show thrombus in either patient.

The procedure was successful in 95 patients (97.9%). Functional class was significantly improved post BMV ($p < 0.001$) with 92 (94.8%) patients in NYHA class I. One patient undergoing BMV at 32 weeks period of gestation had a non-responding mitral valve and developed coronary embolism with anterior wall ST elevation myocardial infarction after the first balloon dilation. Coronary angiogram and manual thrombus aspiration was done with restoration of TIMI III flow. Patient subsequently had intrauterine fetal demise. As per obstetric protocol labour was induced and fetus evacuated. Subsequently patient developed disseminated intravascular coagulation and postpartum hemorrhage with refractory shock from which patient could not be resuscitated. Patient expired 48 h after BMV. Another patient developed severe mitral regurgitation. But patient had no worsening of functional class and no immediate adverse fetal outcome. Patient was able to complete the pregnancy and later referred for elective mitral valve replacement.

Adverse fetal outcome in the immediate post-procedure period was seen in two patients. Apart from the above mentioned patient who had intra-uterine fetal demise in the third trimester, another patient went into pre-term labour at 33 weeks period of gestation after BMV and delivered a preterm neonate on the same day as the BMV procedure. There were no immediate fetal complications in women undergoing BMV during the second trimester.

Echocardiographic data are summarized in Table 2. Mitral valve area increased from mean of $0.82 \pm 0.12 \text{ cm}^2$ to $1.66 \pm 0.14 \text{ cm}^2$ ($p < 0.001$). Mean transmitral diastolic gradient decreased from $19.7 \pm 5.6 \text{ mm of Hg}$ to $7.5 \pm 2 \text{ mm of Hg}$. Right ventricular systolic

Table 1

Clinical characteristics of pregnant females underwent Balloon Mitral Valvotomy from 2008 to 2018. (N = 97).

| Clinical Characteristics | Values (n = 97) |
|-----------------------------|-----------------|
| Age (years) | 26.1 \pm 4.5 |
| Period of gestation (weeks) | 23.1 \pm 4.6 |
| Trimester | |
| ^a First | 0 (0) |
| ^a Second | 81 (83.5) |
| ^a Third | 16 (16.5) |
| Prior BMV/CMV | 13 (13.4) |
| Atrial fibrillation | 7 (7.2) |
| Baseline functional class | |
| ^a Class II | 81 (83.5) |
| ^a Class III | 14 (14.4) |
| ^a Class IV | 2 (2.1) |

Abbreviations: BMV- Balloon mitral valvotomy, CMV-closed mitral valvotomy.

^a Data as mean \pm SD or N (%).

Table 2
Echocardiographic characteristics of patients (N = 97).

| Echocardiographic parameters ^a | Pre BMV | Post BMV | p value |
|---|-------------|-----------|---------|
| Mitral valve area (cm ²) | 0.8 ± 0.1 | 1.6 ± 0.1 | <0.001 |
| RVSP (mm of Hg) | 56.7 ± 16.2 | 35.6 ± 11 | <0.001 |
| Mean gradient (mm of Hg) | 19.6 ± 2 | 7.5 ± 2 | <0.001 |

Abbreviations: BMV- Balloon mitral valvotomy, RVSP- right ventricular systolic pressure.

^a Data as mean ± SD or N (%).

pressure decreased significantly from mean of 56.7 ± 16.2 mm Hg to mean of 35.6 ± 11 mm Hg. There was worsening of mitral regurgitation by one grade in 24 patients (24.7%) and by two grades in only 2 patients, while 70 patients (72.1%) had no change in mitral regurgitation. Mean fluoroscopic time for the procedure was 6.2 ± 2.8 min.

Patients were followed up for a mean duration of 36.7 months and median duration of 15 months. Survival analysis showed cumulative event free survival of 89% at 5 years and 65% at 10 years, considering a composite endpoint of restenosis, failed BMV (non-responding valve or severe mitral regurgitation), repeat BMV or MVR (Fig. 1). A total of 10 events occurred during the study period with one failed BMV, one echocardiographic restenosis, 5 repeat balloon valvotomies and 3 mitral valve replacement surgeries.

4. Discussion

Our study primarily shows that balloon mitral valvotomy is a safe and effective treatment of mitral stenosis during pregnancy. Patients who underwent the procedure in the third trimester (16.5% of our total group) due to late first presentation also had good immediate and long term outcomes. There have been small

studies in the past with similar outcomes but experience with BMV in the third trimester was limited.¹¹

Mean age of 26.1 ± 4.5 years in our patients was similar to that in previous studies.^{10,11} Atrial fibrillation was present in 7.2% of women in our study. Previous studies have reported atrial fibrillation in 25%–28.5%.^{10,11} Our absolute number of patients with atrial fibrillation was small and hence it may not be possible to make specific inferences regarding this special subset. However, we did not note any immediate adverse outcomes. Prior valvotomy had been done in 13.4% of patients in our study who had presented with restenosis during pregnancy.

In our study, BMV done at mean gestational age of 23.1 weeks had a success rate of 97.9% with improvement in mean mitral valve area from 0.82 cm² to 1.66 cm² and reduction of mean trans-mitral diastolic gradient from 19.7 mm of Hg to 7.5 mm of Hg. Majority of our patients were in NYHA class II and III at baseline which improved significantly after BMV. Vinayakumar et al. showed successful BMV in 95.9% of pregnant patients (N = 49) where majority of patients were in NYHA class II and III.¹¹ Mishra et al. have reported a success rate of 94.1% (N = 85) in BMV performed in patients of NYHA class III–IV, at a mean gestational age of 24.84 ± 4 weeks.¹² Singh et al. showed a success rate of 91% and increase in mean 2D MVA from 0.87 ± 0.14 cm² to 1.82 ± 0.25 cm² in 58 pregnant patients with mean gestational age of 26.53 ± 5.2 weeks.¹³

We had a maternal mortality in a patient with a non-responding valve with coronary embolism, intra-procedure leading to anterior wall myocardial infarction. This patient had intra-uterine fetal demise, disseminated intra-vascular coagulation and developed post-partum hemorrhage and finally died. The patient had been diagnosed as severe mitral stenosis in the third trimester only and had presented with NYHA class III symptoms. Most prior studies have not reported any maternal mortality.^{10–14} However, mortality

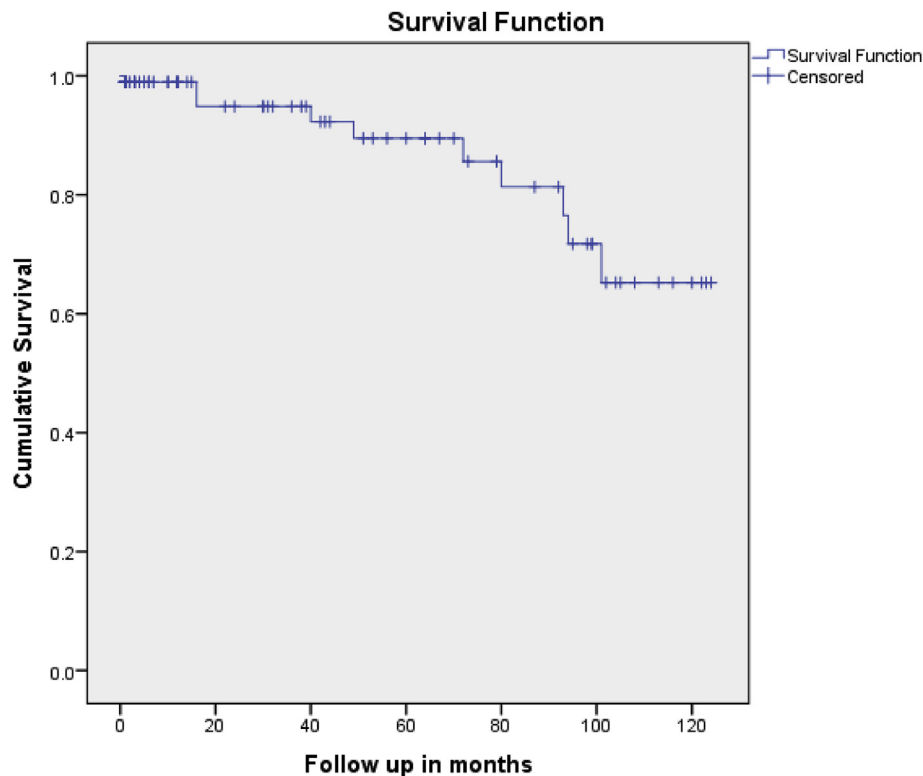


Fig. 1. Cumulative survival curve after BMV with composite endpoint of restenosis, repeat BMV or MVR.

of 11.4% after BMV has been shown in a high risk cohort of patients who presented with decompensated heart failure during pregnancy.¹⁵ The author in this study found a high Wilkin's score, hypoxia and pulmonary hypertension to be predictors of mortality in these patients.

There was worsening of mitral regurgitation by one grade in 24.7% of our patients but none of them had final mitral regurgitation more than mild. Only two patients (2.1%) developed moderate regurgitation. Mitral regurgitation >2+ developed in 5.2% of pregnant patients undergoing BMV by Pillai et al. and between 3.3% and 7% patients in previously published studies of non-pregnant population.^{15–18}

We had immediate adverse fetal outcome in two patients with one intra-uterine death and one preterm birth. Gupta et al. performed BMV in 40 pregnant women out of which one patient developed preterm labor and one had a stillbirth.¹⁴ More recently, Vinayakumar et al. had documented one spontaneous abortion after BMV in 49 pregnant women.¹¹ Thus our immediate fetal outcomes were similar to previously published data.

Mean fluoroscopic times of 5.5 ± 3.8 min, 6.44 ± 1.16 min and 7.8 ± 1.9 min have been seen previously.^{10,11,14} Our fluoroscopy times were similar and combined with abdominal shielding ensured minimal radiation exposure of the fetus.

We studied a composite endpoint for long term outcomes taking into consideration restenosis as assessed clinically which included all restenosis patients including those who underwent repeat BMV or MVR and also those who did not undergo intervention and stayed on medical follow up. Failed BMV's procedures were also included as a part of the total events. Considering this combination an event free survival of 89% at the end of 5 years and 65% at 10 years was observed. Fawzy et al. have reported an event-free survival rate of 79% at 10 years in non-pregnant patients undergoing BMV.¹⁹ Another study in pregnant women showed a restenosis rate of 16% out of 19 patients with a mean follow up of 5.1 ± 2.8 years, which is similar to that seen in our study.⁹ A survival analysis as done by us has not been shown before in pregnant patients undergoing BMV.

4.1. Limitations

Our study was a retrospective analysis conducted in a single tertiary care centre. Long term obstetric and fetal outcomes were not available. Survival analysis done was susceptible to right censoring bias inherent to the Kaplan–Meier method. Patients lost to follow-up and censored could have had an adverse event.

5. Conclusions

Balloon mitral valvotomy is a safe and effective treatment for severe mitral stenosis during pregnancy with significant symptomatic and hemodynamic improvement noted. Long term maternal outcomes after BMV done during pregnancy are good and

comparable to that of BMV done in non-pregnant patients. Immediate fetal complications are uncommon. Balloon mitral valvotomy should be the treatment of choice during pregnancy in patients of severe symptomatic mitral stenosis and even during late presentation.

Conflicts of interest

We declare that we do not have any conflicts of interest.

References

- Vijaykumar M, Narula J, Aeddy KS, Kaplan EL. Incidence of rheumatic fever and prevalence of rheumatic heart disease in India. *Int J Cardiol.* 1994;43:221–228.
- Metcalfe J, Ueland K. Maternal cardiovascular adjustments to pregnancy. *Prog Cardiovasc Dis.* 1974;16:363–374.
- Elkayam U, Bitar F. Valvular heart disease and pregnancy part I: native valves. *J Am Coll Cardiol.* 2005;46(2).
- de Souza JA, Martinez EE, Ambrose JA, et al. Percutaneous balloon mitral valvuloplasty in comparison with open mitral valve commissurotomy for mitral stenosis during pregnancy. *J Am Coll Cardiol.* 2001;37(1).
- Turi ZG, Reyes VP, Raju BS, et al. Percutaneous balloon versus surgical closed commissurotomy for mitral stenosis. A prospective, randomized trial. *Circulation.* 1991;1179–1185.
- Zitnik RS, Braundenburg RO, Sheldon R, et al. Pregnancy and open heart surgery. *Circulation.* 1969;39:1257–1262.
- Hameed A, Karaalp IS, Tummala PP, et al. The effect of valvular heart disease on maternal and fetal outcome of pregnancy. *J Am Coll Cardiol.* 2001;37(3).
- Mangione JA, Lourenco AM, dos Santos ES, et al. Long term followup of pregnant women after percutaneous mitral valvuloplasty. *Cathet Cardiovasc Interv.* 2000;50:413–417.
- Fawzy ME, Kinsara AJ, Stefadouros M, et al. Long term outcome of mitral balloon valvotomy in pregnant women. *J Heart Valve Dis.* 2001;10:153–157.
- Routray SN, Mishra TK, Swain S, Patnaik UK, Behera M. Balloon mitral valvuloplasty during pregnancy. *Int J Gynaecol Obstet.* 2004;85(1):18–23.
- Vinayakumar D, Vinod GV, Madhavan S, Krishnan MN. Maternal and fetal outcomes in pregnant women undergoing balloon mitral valvotomy for rheumatic mitral stenosis. *Indian Heart J.* 2016;68(6):780–782.
- Mishra S, Narang R, Sharma M, et al. Percutaneous transseptal mitral commissurotomy in pregnant women with critical mitral stenosis. *Indian Heart J.* 2001;53:192–196.
- Manjunath CN, Singh Y, Khandanahally RS, et al. Immediate and intermediate-term outcomes of percutaneous transvenous mitral commissurotomy during pregnancy: our experience with accura balloon at a high-volume center. *Indian Heart J.* 2013;65:533–539.
- Gupta A, Lokhandwala YY, Satoskar PR, Salvi VS. Balloon mitral valvotomy in pregnancy: maternal and fetal outcomes. *Am Coll Surg.* 1998;187(October 4):409–415.
- Pillai AA, Ramasamy C, Gousy SV, Kottyath H. Outcomes following balloon mitral valvuloplasty in pregnant females with mitral stenosis and significant sub valve disease with severe decompensated heart failure. *J Intervent Cardiol.* 2018;31:525–531.
- Padial LR, Abascal VM, Moreno PR. Echocardiography can predict the development of severe mitral regurgitation after percutaneous mitral valvuloplasty by the Inoue technique. *Am J Cardiol.* 1999;83:1210–1213.
- Vahanian A, Michel PL, Cormier B, et al. Results of percutaneous mitral commissurotomy in 200 patients. *Am J Cardiol.* 1989;63:847–83852.
- Kaul UA, Singh S, Kalra GS, et al. Mitral regurgitation following percutaneous transvenous mitral commissurotomy: a single center experience. *J Heart Valve Dis.* 2000;9:262–266.
- Fawzy ME, Shoukri M, Al Buraiki J, et al. Seventeen years' clinical and echocardiographic follow up of mitral balloon valvuloplasty in 520 patients, and predictors of long-term outcome. *J Heart Valve Dis.* 2007;16:454–460.