

Original Article

Efficacy of silver nanoparticle gel on healing of traumatic oral ulcers compared with triamcinolone oral paste: An experimental study on rats

Fahimeh Rezazadeh¹, Ali Dehghani Nazhvani², Samira Sadat Abolmaali³, Fatemeh Dehghani Nazhvani⁴, Alireza Bonyani⁵

¹Oral and Dental Disease Research Center, Department of Oral and Maxillofacial Medicine, School of Dentistry, Shiraz University of Medical Sciences, ²Department of Oral and Maxillofacial Pathology, Biomaterials Research Center, School of Dentistry, Shiraz University of Medical Sciences, ³Department of Pharmaceutical Nanotechnology, School of Pharmacy, Shiraz University of Medical Sciences, ⁴Bone and Joint Diseases Research Center, Shiraz University of Medical Sciences, ⁵Students Research Committee, School of Dentistry, Shiraz University of Medical Sciences, Shiraz, Iran

ABSTRACT

Background: There are many treatment protocols for relieving pain and accelerating oral ulcer healing. The purpose was to evaluate the anti-inflammatory and antimicrobial effect of silver nanoparticle (AgNP) gel on oral ulcers compared with the traditional treatment in animal model.

Materials and Methods: In this experimental study, 72 adult male rats were randomly allocated into four groups, after ulcer induction: control (receive no treatment), placebo (placebo gel was applied on ulcers once daily), triamcinolone (ulcers were treated with triamcinolone paste once daily), and AgNPs (ulcers were treated with AgNP gel once daily). The animals were sacrificed at three successive periods of 3, 7, and 14 days after ulcer induction. Histopathological scores of re-epithelialization and degree of inflammation were assessed. The wound size was measured clinically. For parametric data, the analysis of variance, and for ordinal histopathological data, the Kruskal–Wallis test using SPSS was done. A $P < 0.05$ was considered statically significant.

Results: Control and placebo groups had no case of complete healing. Improvement of wound size by triamcinolone paste was not significant in different days but showed significant differences in degree of inflammation ($P < 0.001$) and re-epithelialization ($P = 0.012$). Reduction of wound size by AgNPs gel had significant difference at 14th day ($P < 0.001$); further, by this gel, significant differences in degree of inflammation and re-epithelialization were seen in long-term medication.

Conclusion: AgNP gel could be effective in oral ulcer healing clinically and histopathologically. Although this gel showed delayed effect, it had better healing effect according to the cases with complete healing. Hence, the application of AgNP oral gel can be considered as an alternative approach for oral ulcers.

Key Words: Inflammation, nanoparticle, oral ulcer, re-epithelialization, silver, triamcinolone acetamide, wound healing

Received: 08-Sep-2019
Revised: 22-Mar-2020
Accepted: 19-Sep-2020
Published: 24-May-2021

Address for correspondence:

Dr. Fatemeh Dehghani Nazhvani,
Bone and Joint Diseases Research Center, Chamran Hospital, Shiraz University of Medical Sciences, Shiraz, Iran.
E-mail: fd_nazhvani@sums.ac.ir

Access this article online



Website: www.drj.ir
www.drjjournal.net
www.ncbi.nlm.nih.gov/pmc/journals/1480

This is an open access journal, and articles are distributed under the terms of the Creative Commons Attribution-NonCommercial-ShareAlike 4.0 License, which allows others to remix, tweak, and build upon the work non-commercially, as long as appropriate credit is given and the new creations are licensed under the identical terms.

For reprints contact: WKHLRPMedknow_reprints@wolterskluwer.com

How to cite this article: Rezazadeh F, Nazhvani AD, Abolmaali SS, Nazhvani FD, Bonyani A. Efficacy of silver nanoparticle gel on healing of traumatic oral ulcers compared with triamcinolone oral paste: An experimental study on rats. *Dent Res J* 2021;18:33.

INTRODUCTION

In recent years, nanotechnology has been emerging as a rapidly growing field with various applications in science and technology for the purpose of new material production; it is defined as the utilization of structures with at least 1 nm size dimension in the construction of materials, devices, or systems with improved properties.^[1] Since the 1980s, nanotechnology has been attending much attention and has been adapted into many engineering fields, such as electronics and mechanics, as well as significant progress in the biomedical fields.^[2] Nanomedicine is referred to the application of nanotechnology for achieving breakthrough in healthcare and improving physical, chemical, and biological properties of materials at the nanometer scale.^[2] Silver nanoparticles (AgNPs) are useful prophylactic and therapeutic agents for the prevention of wound colonization by organisms that impede the healing.^[3] The main rationale for using AgNPs on open wounds is the prevention and treatment of infection to increase the healing rate.^[4] An ulcer is a breakdown in the continuity of the skin or mucous membrane, disintegration, and necrosis of the epithelial tissue. Oral ulcers usually are accompanied by pain and discomfort during eating, drinking, or talking.^[5,6] There are many treatment protocols for relieving pain and accelerating oral ulcer healing; however, the most usual treatment is triamcinolone acetonide paste.^[7] This medication is a medium-strength corticosteroid and is used to relieve symptoms of mouth sores and to reduce the swelling and pain of the ulcers.^[8,9] Thus, this study was designed to evaluate the therapeutic effect of AgNPs gel on oral ulcers in comparison with triamcinolone as the traditional treatment of these cases.

MATERIALS AND METHODS

Animals

Seventy-two adult male Sprague–Dawley rats (weighing 250 ± 50 g) were used in this experimental study. The rats maintained under standard condition ($22^{\circ}\text{C} \pm 3^{\circ}\text{C}$ temperature, $50\% \pm 5\%$ relative humidity, and 12/12 h light-dark cycles) and had free access to standard diet of soft food stuff and water.

Silver nanoparticle gel preparation

AgNPs embedded topical gel were prepared in Pharmacy Faculty of SUMS by the polyol process.

Briefly, ethylene glycol was heated in an oil bath to 100°C . After 1 h, a solution of silver nitrate (3 ml, 2.5 mM) and a solution of polyvinyl pyrrolidone in ethylene glycol (3 ml, 25 mM) were added gradually under vigorous stirring. The mixture was precipitated by adding acetone. The final silver concentration in the dispersion was determined by ICP-AES (Inductively coupled plasma-atomic emission spectrometry). The average particle size and zeta potential were studied by dynamic light scattering. For gel preparation, 200 mg of Carbopol® 934 was dissolved in 20 ml of AgNP dispersion in distilled water (200 ppm). Then, 200 μl of triethylamine was added gradually while stirring to reach the neutral point. Gel containing AgNPs was stored in a sealed container.

Surgical procedure

After an adaptation period of 10 days, oral traumatic ulcers were induced according to Alsadat Hashemipour *et al.*'s procedure.^[10] All the 72 animals were anesthetized by intraperitoneal (IP) injection of a mixture of xylazine (5 mg/kg) and ketamine hydrochloride (40 mg/kg); then, a buckle-shaped clamp was fastened on the upper and lower incisor teeth to keep the mouth open [Figure 1a and b]. Punch biopsy tools of 4 mm in diameter were used to create a standard size circular wound, outlined posterior to second transverse palatine fold of mucoperiosteum of the hard palate midline [Figure 1c]. Soft tissues were removed by sharp dissection to expose the underlying bone. Hemostasis was done by pressure

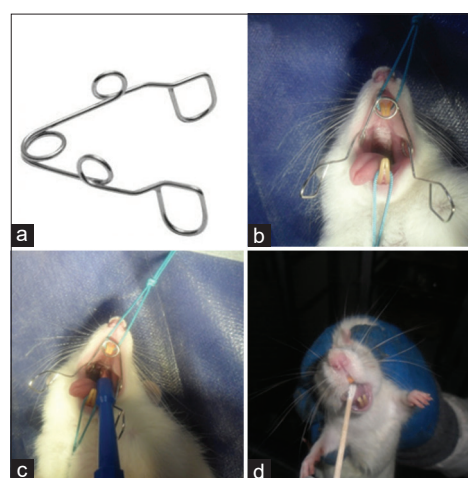


Figure 1: (a) Handmade buckle shape clamp made by stainless steel wire. (b) Keeping rat mouth open during surgery by buckle clamp. (c) Surgical procedure and hard plate punching posterior to second transverse palatine fold of mucoperiosteum. (d) Medicine application by rotational movement of sterile swap at days after ulcer induction.

of sterile cotton gauze on the wound. Analgesia was provided by the administration of a single dose of flunixin meglumine (1 mg/kg, intramuscular (IM)) postoperatively. The dead rats were replaced by new rats.

Medications

The day after the surgery was considered as the 1st day of medications. The rats were randomly categorized by block randomization into four groups as bellow ($N = 18/\text{group}$); categorization and medications were blinded:

1. Control group: Rats received no treatment
2. Placebo gel group: Rats received placebo gel without AgNPs, once a day for 14 days
3. Triamcinolone oral paste group: Rats received triamcinolone acetonide oral paste, once a day for 14 days (Trident, Raha[®]; Isfahan, Iran)
4. AgNPs gel group: Rats received AgNP gel, once a day for 14 days.

To application of medications, a volume of 1 cc of the ointment paste and gels were rubbed on the oral ulcers by rotational movement of clean sterile swabs [Figure 1d]. Rats were not allowed to eat or drink for 1 h after the medication, to make sure that the coverage was not swallowed.

The rats of each group were also divided randomly into three subgroups of six, based on the duration of follow-ups as bellow:

1. Three days after the start of medication, the rats were euthanized for further studies
2. Seven days after the start of medication, the rats were euthanized for further studies
3. Fourteen days after the start of medications, the rats were euthanized for further studies.

Clinical evaluation

The wounds contraction was evaluated macroscopically for the measurements of diameter of the injured area (mm) by a caliper (INSIZE[®], Germany). The measurements were done at the end of follow-up in each subgroup. Gross wound healing was considered as the reduction of wound size (mm) resulted by re-epithelialization.

Histopathological study

After euthanasia, each wound was removed by a periosteal elevator and a scalpel blade, consisting of adjacent muscles and the healthy peripheral tissues. The samples were kept in 10% buffered formalin solution and sent to the Pathology Laboratory of School of Dentistry; then, they were embedded in

paraffin, sectioned, and stained by hematoxylin and eosin.^[11] The sections were studied by Olympus microscope BX41 in a single-blind manner by a pathologist, and the details of bellow have been surveyed. The degree of re-epithelialization was scored as follows:^[12]

1. Grade 1: Re-epithelialization at the edge of the wound
2. Grade 2: Re-epithelialization covering less than half of the wound
3. Grade 3: Re-epithelialization covering more than half of the wound
4. Grade 4: Re-epithelialization covering the entire wound, irregular thickness
5. Grade 5: Re-epithelialization covering the entire wound/normal epithelialization.

The degree of inflammation was also graded as follows:^[12]

1. Grade 0: No acute inflammation
2. Grade 1: Perivascular-scattered acute inflammatory cells
3. Grade 2: Perivascular and submucosal-scattered acute inflammatory cells
4. Grade 3: Submucosal band-like inflammatory infiltrate, less than $\frac{1}{4}$ of one power field
5. Grade 4: Submucosal band-like inflammatory infiltrate, between $\frac{1}{4}$ and $\frac{1}{2}$ of one power field without tissue necrosis
6. Grade 5: Submucosal band-like inflammatory infiltrate, more than $\frac{1}{2}$ of one power field with tissue necrosis.

Statistical analysis

For parametric data of wound size, the analysis of variance (followed by Duncan's multiple range as *post hoc* test) was performed. For ordinal histopathological data, the Kruskal–Wallis test (followed by Mann–Whitney as *post hoc* test) was done. The analyses were performed using SPSS package (Version 24, SPSS Inc., Chicago, IL, USA). A $P < 0.05$ was considered statistically significant.

RESULTS

Wound size

Although the effect of different medications on wound size varies in each group, the wound size alterations in all groups had nearly a same trend of reduction [Figure 2]. No significant differences were detected between the groups at different

days ($P > 0.05$); except the AgNPs group at 14th day, which had significantly the smallest wound size than other groups and days. In control group at 14th day, the wound size was significantly smaller than the other days ($P = 0.002$); however, this size reduction was not significant between 3rd and 7th days. In placebo group, the wound size was significantly smaller at 7th day than 3rd day ($P = 0.004$); however, the reduction was not significant between 7th and 14th days. In triamcinolone group, the trend of wound size reduction was not significant at different days ($P > 0.05$). Moreover, in AgNPs group, the wound size was significantly smaller at 14th day than the other days ($P < 0.001$); however, the difference between 3rd and 7th days was not significant.

Inflammation

Degree of inflammation showed a reductive trend by time in all groups [Figure 3]. No significant differences were detected between the groups at different days ($P > 0.05$); except the triamcinolone group at 7th day ($P < 0.001$). In details, all groups revealed high degree of inflammation at 3rd day; The degree of inflammation remained unchanged, except the triamcinolone group with a significant reduction at this day than the other groups. The AgNPs group showed a slight nonsignificant increase at 7th day. At 14th day, inflammation has been reduced significantly in all groups than the other days ($P < 0.05$) but with no significant differences between groups ($P > 0.05$); whereas triamcinolone and AgNPs groups showed lower inflammation than control and placebo groups.

Re-epithelialization

Degree of re-epithelialization demonstrated an ascending trend by time in all groups, except the AgNPs group with a slight nonsignificant fall at 7th day than the 3rd day [Figure 4]. No significant differences were detected between the groups at different days ($P > 0.05$), except the triamcinolone and control groups at 7th day, which showed a significant increase than other groups ($P = 0.004$ and $P = 0.022$, respectively). In control, placebo, and AgNPs groups, the degree of re-epithelialization at 14th day was significantly higher than the other days ($P < 0.05$); however, this increase was not significant between 3rd and 7th days ($P > 0.05$). In triamcinolone group, the difference between 3rd and 14th days was statistically significant ($P = 0.012$); however, the 7th day had no significant difference with other days ($P > 0.05$). The highest degree of re-epithelialization was observed in AgNPs group at 14th day.

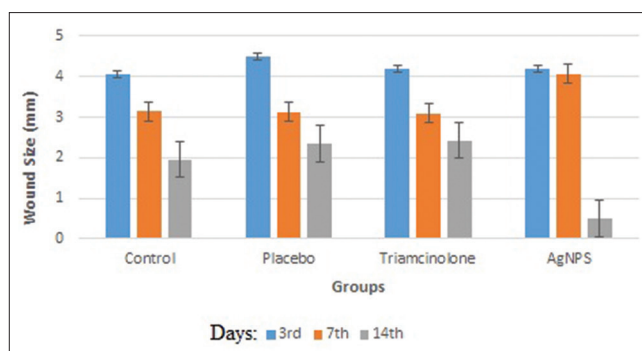


Figure 2: The bar chart showing the mean \pm standard deviation of wound size (mm) of different groups at different days.

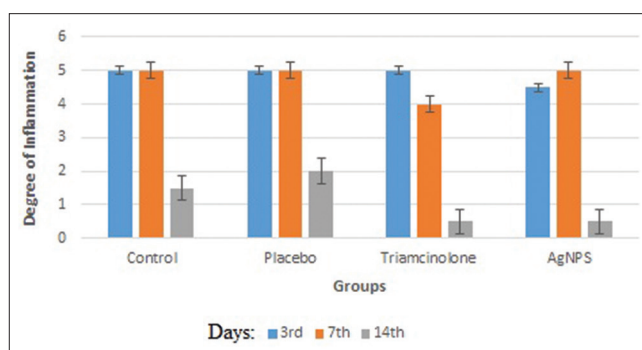


Figure 3: The bar chart showing the mean \pm standard deviation of degree of inflammation of different groups at different days.

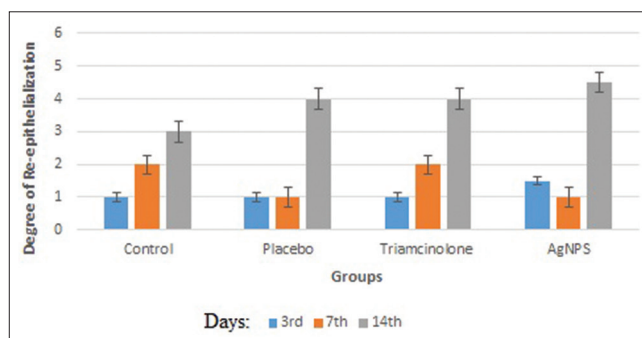


Figure 4: The bar chart showing the mean \pm standard deviation of degree of re-epithelialization of different groups at different days.

Complete healing rate was 50% in AgNPs group, while it was 30% in triamcinolone group and zero (0%) in control and placebo groups.

DISCUSSION

Healing of ulcers and surgical wounds is the most desirable procedure in all types of surgeries. During the healing phase, several factors are needed to inhibit the infections and suppress inflammation to induce cellular proliferation.^[13,14] The use of antimicrobial agents at these sites may benefit the healing process as they prevent

microorganisms to be colonized.^[15] The antibacterial and antifungal activities of AgNPs have been reported in the literature.^[16-19] This study was designed to evaluate the therapeutic effect of AgNPs gel on oral ulcers and wounds in comparison with triamcinolone as the traditional treatment of these situations.

The finding of this study may indicate that although AgNPs had delayed effect, they showed a better healing rate according to the number of cases with complete healing. Indeed, daily application of AgNPs gel could be more effective than triamcinolone paste on healing of oral ulcers. Furthermore, their therapeutic effects were almost the same and AgNPs have the option of microbiocidal activity. Both agents had no side effects, too.

At the 3rd day after induction of the ulcer, clinical and histological examination of the specimens of AgNPs group revealed the highest healing rate among other groups. Although it was nonsignificant, AgNPs group had higher degree of re-epithelialization compared to triamcinolone group at 3rd day, despite the equal degree of inflammation. In addition, it was better than control and placebo groups in all the criteria. In this group, histopathology showed submucosal band-like inflammatory infiltrate (approximately ½ of power field) and re-epithelialization more than edges of the wound and less than half of it. However, in control group, histopathology revealed submucosal band-like inflammatory infiltrate (more than ½ of one power field) with tissue necrosis and re-epithelialization at the edges of the wound. These findings were in agreement with Aziza *et al.*, who reported the healing response in nanosilver group,^[3] which was enhanced by rapid proliferation and migration of the epithelial basal cells over the ulcerated area and decreased number of inflammatory cells in the connective tissue beneath the ulcer. In control group, they observed infiltration of many inflammatory cells to subepithelial connective tissues, and thinner appearance and loose arrangement of collagen fibers.^{3]} Moreover, Sibbald *et al.* stated that 3 days after ulcer induction and treatment with nanocrystalline silver, it had lessened the number of inflammatory cells, in return reduced the wound inflammation, and enhanced the healing process of chronic venous leg ulcer patients.^[20]

At the 7th day in this study, triamcinolone group showed a superior healing effect than all the other groups. In this group, the degree of re-epithelialization and inflammation increased with a steady slope

that was not significant. Further, it had a significant difference in wound size compared with the 3rd day. It seems that triamcinolone causes constant trend in healing process. However, at 7th day, AgNPs had the lowest healing rate among the other groups. At this day, clinical study of AgNPs specimens showed only a little decrease in wound size and histopathology demonstrated a deterioration in ulcer condition as mild increase in degree of inflammation and low reduction in re-epithelialization, although these changes was not statistically significant. In addition, at 7th day, the control and placebo groups had mild nonsignificant improvement in clinical and histopathological scores compared with AgNPs group. These results were in contrast with the result of Aziza *et al.* in 2015 that reported significant decrease in inflammation and re-epithelialization on 7th day.^[3] This variation might be related to the type of wound (chemical burn), deepness of ulcer, medication type (nanosilver solution), or methods of evaluation in their study.^[3]

At the 14th day, this study demonstrated that AgNPs group had the most cases of complete healing and also showed the highest improvement of inflammation, re-epithelialization, and wound size compared with other groups although it was not significant. AgNPs caused healing by a more sloping than triamcinolone. This steady slope trend of improvement was seen especially in re-epithelialization of triamcinolone group that was not significant between 3rd and 7th days and between 7th and 14th days. These findings were in agreement with previous studies that stated nanosilver is an effective treatment.^[3,13] The main rationale for applying AgNPs on open wounds is the prevention and treatment of infection and increasing the healing rate.^[13,21] The accelerated healing rate also recorded in the AgNPs group of the present study; this could be related to the extremely large surface area of nanosilver crystals that led to increase contact with bacteria and inhibit their replication.^[17] Khorshidi *et al.* reported that proper concentration of nanosilver increases the contact with large number of bacteria in inflamed wound, leading to adverse effects on cell metabolism and transport of substances through the microbial cell membrane, which inhibits multiplication and growth of bacteria.^[17] Other studies also evaluated the toxicity of similar product but not in topical form. They had shown dose-dependent accumulation of silver content in all the tissues.^[22]

Overall, AgNPs gel had a good healing effect on oral ulcers, similar to previous studies in all the body

skin wounds.^[23] It also reported by similar study in rats that their results on the excision wounds using nanoparticles which could be a novel therapeutic way of improving wound healing in clinical practice.^[24] It seems that AgNPs have delayed effect on oral ulcer healing. It might be due to its antibacterial effect or its slow absorption to the tissue.

Here, the gel was produced in mucoadhesive form, hence evaluating the effect of other type of AgNPs (such as mucoadhesive pill and oil-based gel), in addition to more advanced methods of immunohistochemistry, and also, clinical trials on humans are suggested.

CONCLUSION

The results showed that AgNP oral gel was effective on wound healing both clinically and histopathologically. Although it had delayed effect, it showed a better healing rate. Hence, daily application of AgNP oral gel on mouth sores may be more effective than triamcinolone acetonide paste and can be an alternative treatment in these cases.

Acknowledgments

We thank the Vice Chancellor of Research, Shiraz University of Medical Sciences for financial support of this work (Grant No. 15988). This manuscript is based on the thesis written by Alireza Bonyani (DMD).

Financial support and sponsorship

This work was supported financially by the Vice Chancellor of Research, Shiraz University of Medical Sciences (Grant No. 15988).

Conflicts of interest

The authors of this manuscript declare that they have no conflicts of interest, real or perceived, financial or non-financial in this article.

REFERENCES

- Chen J, Han CM, Lin XW, Tang ZJ, Su SJ. Effect of silver nanoparticle dressing on second degree burn wound. *Zhonghua Wai Ke Za Zhi* 2006;44:50-2.
- El-Batal AI, Ahmed SF. Therapeutic effect of *Aloe vera* and silver nanoparticles on acid-induced oral ulcer in gamma-irradiated mice. *Braz Oral Res* 2018;32:e004.
- Aziza E-S, Maha B, Elbaz D. A comparative study on the healing potential of induced labial ulcerative defects treated with nanosilver and chlorhexidine. *Nat Sci* 2015;13:59-73.
- Dogan E, Yanmaz L, Gedikli S, Ersoz U, Okumus Z. The effect of pycnogenol on wound healing in diabetic rats. *Ostomy Wound Manage* 2017;63:41-7.
- Nadworny PL, Wang J, Tredget EE, Burrell RE. Anti-inflammatory activity of nanocrystalline silver-derived solutions in porcine contact dermatitis. *J Inflamm (Lond)* 2010;7:13.
- Rezazadeh F, Sokhakian M. Plasma level of trace elements in patients with oral lichen planus. *Iran J Dermatol* 2018;21:54-8.
- Rezazadeh F, Shahbazi F, Andisheh-Tadmir A. Evaluation of salivary level of IL-10 in patients with oral lichen planus, a preliminary investigation. *Comp Clin Pathol* 2017;26:531-4.
- González-Moles MA, Scully C. Vesiculo-erosive oral mucosal disease--management with topical corticosteroids: (1) Fundamental principles and specific agents available. *J Dent Res* 2005;84:294-301.
- Fahimeh R, Neshat A, Jannan G. Oral Lichen planus resistency to topical corticosteroid therapy. *Middle East J Sci Res* 2013;16:1245-8.
- Alsadat Hashemipour M, Lotfi S, Torabi M, Sharifi F, Ansari Dogaheh M, Ghassemi A, *et al.* Evaluation of the effects of three plant species (*Myrtus communis* L., *Camellia sinensis* L., *Zataria multiflora* Boiss.) on the healing process of intraoral ulcers in rats. *J Dentistry* 2017;18:127-35.
- Luna LG; Armed Forces Institute of P, Manual of Histologic Staining Methods of the Armed Forces Institute of Pathology. 3rd ed. New York: Blakiston Division, McGraw-Hill; 1968.
- Sinha UK, Gallagher LA. Effects of steel scalpel, ultrasonic scalpel, CO2 laser, and monopolar and bipolar electrosurgery on wound healing in guinea pig oral mucosa. *Laryngoscope* 2003;113:228-36.
- Nazhvani FD, Naeini AT, Nazhvani SD, Nazhvani AD, Koohepyma F. Does platelet-rich plasma improve the tendon gap healing? *Shiraz E Med J* 2019;20:e82620.
- Rezazadeh F, Salehi S, Rezaee M. Salivary level of trace element in oral lichen planus, a premalignant condition. *Asian Pac J Cancer Prev* 2019;20:2009-13.
- Vahabi S, Salman BN, Rezazadeh F, Namdari M. Effects of cyclosporine and phenytoin on biomarker expressions in gingival fibroblasts of children and adults: An *in vitro* study. *J Basic Clin Physiol Pharmacol* 2014;25:167-73.
- Haddadi P, Khorshidi H, Raoofi S, Nazhvani AD, Badiiee P. Comparative evaluation of conventional and nanosilver-containing leucocyte and platelet-rich fibrin/biomaterial in the anti-biofilm formation of standard species of *Candida* and *Streptococcus*. *Jundishapur J Microbiol* 2018;11:e68423.
- Khorshidi H, Haddadi P, Raoofi S, Badiiee P, Dehghani Nazhvani A. Does adding silver nanoparticles to leukocyte- and platelet-rich fibrin improve its properties? *Biomed Res Int* 2018;2018:8515829.
- Kim JS, Kuk E, Yu KN, Kim JH, Park SJ, Lee HJ, *et al.* Antimicrobial effects of silver nanoparticles. *Nanomedicine* 2007;3:95-101.
- Zhang XF, Liu ZG, Shen W, Gurunathan S. Silver nanoparticles: Synthesis, characterization, properties, applications, and therapeutic approaches. *Int J Mol Sci* 2016;17:1534.
- Sibbald RG, Contreras-Ruiz J, Coutts P, Fierheller M, Rothman A, Woo K. Bacteriology, inflammation, and healing: A study of nanocrystalline silver dressings in chronic venous leg ulcers. *Adv Skin Wound Care* 2007;20:549-58.
- Salas Campos L, Fernández Mansilla M, Martínez de la Chica AM.

- Topical chemotherapy for the treatment of burns. *Rev Enferm* 2005;28:67-70.
22. Kim YS, Kim JS, Cho HS, Rha DS, Kim JM, Park JD, *et al.* Twenty-eight-day oral toxicity, genotoxicity, and gender-related tissue distribution of silver nanoparticles in Sprague-Dawley rats. *Inhal Toxicol* 2008;20:575-83.
23. Sharma R, Kumar R, Mittal S, Kaur A. Study of effect of topical nano silver gel on wound healing. *J Adv Med Dent Sci Res* 2016;4:59.
24. Naraginti S, Kumari PL, Das RK, Sivakumar A, Patil SH, Andhalkar VV. Amelioration of excision wounds by topical application of green synthesized, formulated silver and gold nanoparticles in albino Wistar rats. *Mater Sci Eng C Mater Biol Appl* 2016;62:293-300.