

# Successful total hip arthroplasty for autosomal dominant osteopetrosis complicated by hip osteoarthritis: A case report and review of the literature

XIAOMING GAO<sup>1</sup>, QIAN CHENG<sup>2</sup>, XIAOFEI ZHANG<sup>3</sup> and GUOYANG ZHAO<sup>1</sup>

<sup>1</sup>Department of Orthopedics, Affiliated Hospital of Jiangsu University, Zhenjiang, Jiangsu 212000;

<sup>2</sup>Department of Orthopedics, Tong Ren Hospital Affiliated to Shanghai Jiao Tong University School of Medicine, Shanghai 200336; <sup>3</sup>Department of Gynecology and Obstetrics, Shanghai First Maternal and Infant Healthcare Hospital Affiliated to Shanghai Tongji University, Shanghai 200040, P.R. China

Received June 30, 2019; Accepted January 16, 2020

DOI: 10.3892/etm.2020.8503

**Abstract.** Osteopetrosis is a rare congenital bone disorder, characterized by systemic osteosclerosis due to a deficiency of or functional defect in osteoclasts. Autosomal dominant osteopetrosis (ADOP) is the most common form with a late onset, a stable condition, relatively few symptoms and a good prognosis. Few studies to date have reported successful total hip arthroplasty (THA) in patients with ADOP and its operative difficulties. We herein describe a case of left hip osteoarthritis in a patient with OP via THA in order to share our experience during the treatment process. The patient was a 52-years-old female with osteopetrosis who was referred to our department due to a history of left hip pain with activity limitation for 20 years. The patient reported no history of fracture or family history. The patient underwent THA in the left hip. At the 6-month, 1- and 2-year follow-up, the components were in a good position and the patient remained asymptomatic and pain-free. Therefore, THA may be a feasible treatment option when patients with ADOP suffer from painful hip osteoarthritis.

## Introduction

Osteopetrosis (OP) is a rare congenital bone disorder (1) that is characterized by systemic osteosclerosis due to a deficiency of or functional defect in osteoclasts (2,3). As a result,

fractures, anemia and nerve compression, which may lead to deafness and/or blindness (4,5). However, little is known on the complications and operative difficulties associated with total hip arthroplasty (THA) in OP patients. The present study presents a case of osteoarthritis of the left hip joint in a patient with OP who was treated successfully with THA at the Affiliated Hospital of Jiangsu University (Zhenjiang, China). Additionally, a review of the literature was performed to summarize our current knowledge of clinical and imaging manifestations, pathogenesis, clinical classification and treatment of OP, aiming to improve the diagnosis and treatment of this disease.

## Case report

In September 2015, A 52-year-old female patient with OP presented to the Affiliated Hospital of Jiangsu University (Zhenjiang, China) with a history of left hip pain and a limp, with progressive activity limitation over the past 20 years. The patient reported no previous history of fracture and had declined any treatment during those two decades. There was no family history of OP. X-ray examination of skull, chest, spine and pelvis performed 8 years ago in another hospital revealed manifestations of OP, including systemic osteosclerosis and hyperplasia, obliteration of the medullary cavity and the left hip space, and necrosis of the femoral head. Although the left hip pain gradually subsided after a conservative therapy such as reducing activity and taking pain killers, there was no significant improvement in the disability. One week before admission, the left hip pain worsened significantly, and the patient was only able to walk for a maximum of 50 m, beyond which the pain became unbearable.

At the time of admission, the patient's condition was carefully evaluated based on physical examination, laboratory tests and imaging studies. The physical examination revealed tenderness and pain on percussion in the left hip. A test for the range of hip motion showed 90° forward flexion, 0° backward extension, 10° adduction and 10° abduction. In addition, the lower extremities appeared to be of unequal length, and the left leg was shown to be 2 cm shorter than the right. On

---

*Correspondence to:* Dr Qian Cheng, Department of Orthopedics, Tong Ren Hospital Affiliated to Shanghai Jiao Tong University School of Medicine, 1111 Xianxia Road, Shanghai 200336, P.R. China  
E-mail: zggkcq@sina.com

Dr Xiaofei Zhang, Department of Gynecology and Obstetrics, Shanghai First Maternal and Infant Healthcare Hospital Affiliated to Shanghai Tongji University, 536 Changyue Road, Shanghai 200040, P.R. China  
E-mail: fayfaye@126.com

**Key words:** total hip arthroplasty (THA), osteopetrosis, osteoarthritis, hip pain, operative difficulties, osteoclast

neurological examination, the patient had full motor strength in her lower extremities with no obvious abnormality in skin sensation. The findings of other examinations, including head and chest condition, tapping pain in the liver and kidney areas, hearing and visual acuity, peripheral blood supply, spinal activity and curvature and tenderness in the spine area, were normal. The laboratory results were notable for a platelet count of  $1.69 \times 10^{11}$  cells/l (normal levels:  $1.0\text{--}3.0 \times 10^{11}$  cells/l), a reduced white blood cell count of  $3 \times 10^9$  cells/l (normal levels:  $3.5\text{--}9.5 \times 10^9$  cells/l), a reduced red blood cell count of  $3.78 \times 10^{12}$  cells/l (normal levels:  $3.8\text{--}5.1 \times 10^{12}$  cells/l), a serum calcium concentration of 1.21 mmol/l (normal levels: 1.13–1.35 mmol/l) and a serum alkaline phosphatase concentration of 91.5 U/l (normal levels: 50–135 U/l).

A radiological examination was performed. X-ray imaging of the bilateral femora and pelvis revealed markedly increased bone density with reduced left hip joint space, enlarged left femoral head, marked left acetabular proliferation and proximal migration of the left femoral head. In addition, the left iliac bone and left femoral shaft were smaller compared with those on the opposite side (Fig. 1A). An X-ray of the spine and upper limbs revealed thickened and compact superior and inferior endplates with loose and transparent vertebral midbodies, thickened cortex of the bilateral upper humeri and narrowed medullary cavity (Fig. 1B). Thus, the patient was diagnosed with OP complicated with osteoarthritis of the left hip joint.

Given the history of OP and presumed poor bone quality, THA was performed under epidural anesthesia via a posterolateral approach. However, the surgery did not go smoothly, as the femoral head was found to be deformed and articular cartilage was destroyed by acetabular osteophyte proliferation (Fig. 2). It was also difficult to realign their position due to the bone stiffness and fragility. Considering these factors, a biological total hip prosthesis was selected. However, a fracture of the proximal femur occurred during intramedullary reaming and the operation was terminated. During surgery, the patient lost 300 ml of blood and was treated with suspended red blood cells (300 ml) and plasma (225 ml). At the end of the surgery, a drainage tube was inserted into the joint cavity from the proximal 10-cm incision after confirming that bleeding had ceased. On the first postoperative day, ~300 ml blood was observed in the drainage tube.

The patient developed certain unexpected symptoms postoperatively, including decreased muscle strength of the left lower extremity, reduced skin sensation below the knee joint and limited dorsal extension of the foot. At that time, it was considered that the symptoms may be due to sciatic nerve traction, and the patient was treated with methylcobalamin for neuronutrition, fluid replacement, mannitol for detumescence, acupuncture and moxibustion. The symptoms were relieved after treatment. X-ray imaging 2 weeks after surgery revealed satisfactory positioning of the components, and the left femur was 2 cm longer compared with the preoperative length. In addition, a radiolucent line was observed (Fig. 3). Postoperative pathology revealed that histological changes in the left hip were consistent with chronic synovitis (Fig. 4). According to previous reports, the pathological changes of OP may be summarized as follows (6,7): Cortical hyperplasia and thickening; dense cancellous bone; abnormal trabecular bone structure; decrease of intraosseous blood vessels, fat and

medullary substance; markedly sclerotic cortical bone; and cancellous bone with unclear demarcation.

At 18 days after the surgery, the symptoms of sciatic nerve injury in the left lower extremity of the patient had significantly improved. The patient was able to perform walking exercises using sticks without experiencing any pain in the left hip joint, except for some numbness. On follow-up examinations at 6 months, 1 year and 2 years after surgery, the patient remained asymptomatic and pain-free. Repeat X-ray imaging at these time points revealed complete recovery from the fracture of the upper left femur (Fig. 5A–C).

## Discussion

Bone tissue is dynamically active, and under physiological states, bone homeostasis is maintained by a balanced formation of bone by osteoblasts, and bone resorption by osteoclasts. OP, also referred to as ‘marble bone disease’, generalized brittle osteosclerosis, ‘chalk bone’ or congenital osteosclerosis, is a hereditary osteogenesis disease (6,8). Previous studies suggested that osteosclerotic changes with increased bone mass were observed due to a deficiency of or functional defect in osteoclasts (4). The characteristic findings include bone hyperplasia, disappearance of bone trabeculae, reduction or absence of the medullary spaces, bony fragility and a high risk of fracture (4). Bone resorption and remodeling can be impaired as a result of the lack of osteoclasts. The bone tissues become dense, where the bone appears as chalk-like or marble-like. As a result, the weight-bearing ability is impaired and fracture susceptibility increases. According to Stattin *et al* (5), individuals with OP were 30 times more likely to suffer from recurrent fractures. When the marrow cavity and skull are involved, hematopoietic disorders and reflux of blood and cerebrospinal fluid may occur. Subsequent manifestations may include bone marrow anemia, leukocytopenia, thrombocytopenia, decreased haptoglobin, hydrocephalus, cerebellar tonsil hernia and cranial nerve compression (9,10).

Generally, OP may be divided into two types: Autosomal recessive OP (AROP) and autosomal dominant OP (ADOP). AROP can be further subdivided into 3 types according to the time of onset and the progression rate of the disease. Type 1 is malignant OP, which presents soon after birth and is characterized by rapid progression, high mortality and low survival rates (1). Type 2 is intermediate autosomal recessive OP, and it is usually diagnosed within the first decade of life due to incidental fractures. Patients with this type are usually short, with a history of repeated fractures, and it may be accompanied by osteomyelitis of the jaw (11). The characteristics of type 3, carbonic anhydrase deficiency syndrome, include osteosclerosis with near-medium, far-medium or complex renal tubular acidosis. The majority of patients with ADOP, which is also known as benign osteoporosis, are adults with a late onset, a stable condition, relatively few symptoms and a good prognosis. Of patients with ADOP, 50% are asymptomatic and 25% may suffer from backache. In ADOP, compression of cranial nerves, coxa varus, lateral femoral arch and other deformities; low incidence of anemia and hepatosplenomegaly may also be found (12). The patient in the present case was 52 years old with mild symptoms and was admitted to the hospital due to aggravated pain in the left hip. The patient's

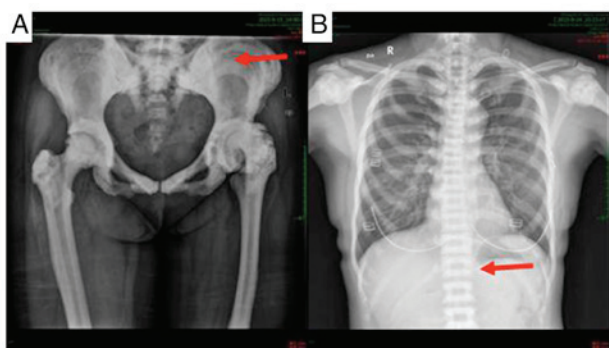


Figure 1. (A) Pelvic orthography: The bone density of ilium and femur increased, and the iliac wings showed a 'ring-like' change (arrow); (B) chest orthography: The superior and inferior endplates were thickened and compact, the midbodies were loose and transparent, exhibiting a 'sandwich-like' vertebral change (arrow).



Figure 2. Appearance of the left femoral head, where the left femoral head appeared deformed because of osteophyte proliferation.

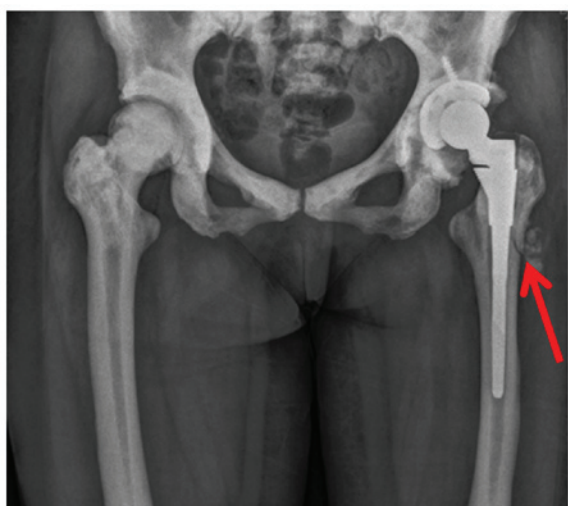


Figure 3. Two weeks after surgery, the artificial hip joint was in position, and a radiolucent line was observed (red arrow).

prognosis was good following THA. Taking all the findings into consideration, the diagnosis was benign OP.

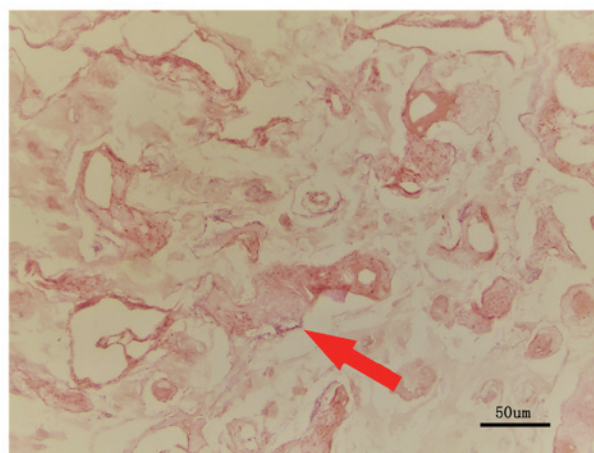


Figure 4. Pathological examination with HE staining and x10 magnification: The histological changes in the left hip were consistent with chronic synovitis. As indicated by the arrow, the normal trabecular structure had disappeared, the bone was dense and the original structure was attenuated.

The following classical radiographical characteristics of OP are the minimum requirement to make the diagnosis (13-15): i) Parallel bands of dense bone giving the appearance of 'bone-within-bone' or 'endobones', which is often prominent in the pelvis, long bones, phalanges and vertebrae; ii) vertebrae appear as 'sandwich vertebrae' or 'rugger-jersey', where the superior and inferior endplates exhibit high density, while the vertebral midbodies appear to be normal; iii) diffuse sclerosis, affecting the skull, spine, pelvis and appendicular bones; iv) skull changes, including calvarial and basilar thickening, as well as poor sinus development; v) bone modeling defects at the metaphyses of long bones, such as the funnel-like appearance of the 'Erlenmeyer flask' deformity and characteristic lucent bands; and vi) ring-like changes of the iliac wing. The X-ray manifestations of the disease in the patient in the present case were consistent with these characteristic findings.

OP is a genetic disease for which there is no specific effective medical treatment (16). However, for patients affected by the lethal autosomal recessive form of the disease, hematopoietic stem cell transplantation (HSCT) is curative (17,18). Successful HSCT leads to engraftment of macrophage-derived osteoclasts of donor origin, resulting in remodeling of bone structure and establishment of normal hematopoiesis (17). Early HSCT is considered to be associated with favorable prognosis, which can relieve progressive optic canal stenosis and control the deterioration of visual function (19). However, this remains controversial. According to a study by Overholt *et al* (20), early HSCT in patients without clinical or global neurological signs does not prevent the onset or progression of neurological deterioration. Recently, HSCT for AROP with a reduced-intensity conditioning regimen was proven to be safe and effective, providing us with the ability to performed HSCT on young patients with significant comorbidities soon after diagnosis, with a lower risk of severe side effects (21).

However, given that the transplant procedure itself has a high risk of failure due to complications that may be life-threatening, HSCT is not considered as an option for ADOP, which rarely reduces life expectancy (22). Considering the high incidence of fractures in patients with ADOP, surgical



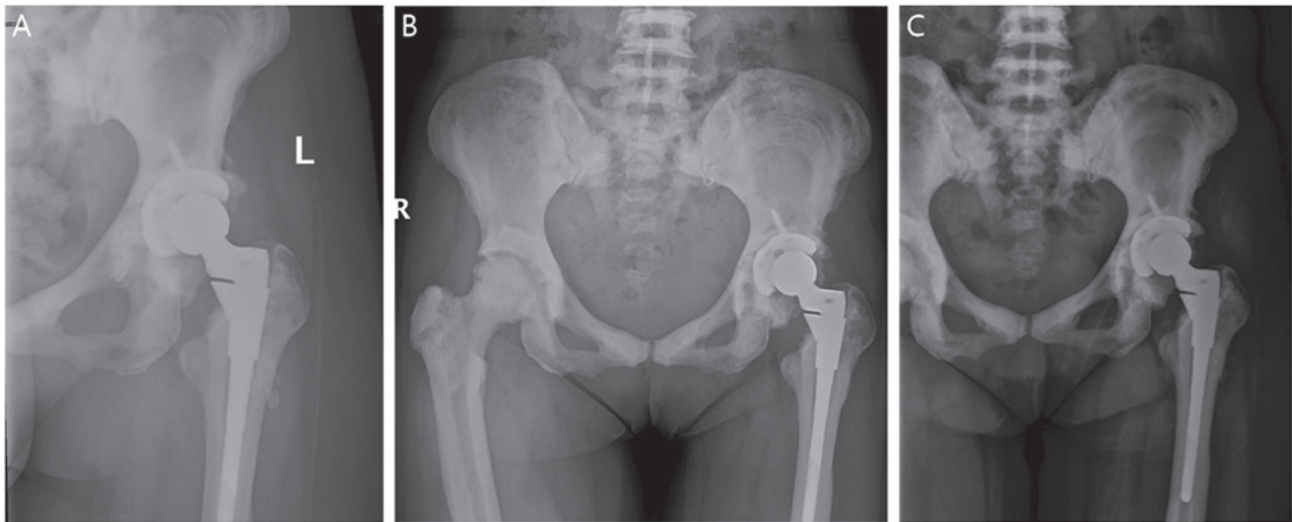


Figure 5. (A) Six months after surgery, (B) one year after surgery and (C) two years after surgery. All three images showed that the artificial hip joint was in position, the structure was intact, and the fracture of the upper part of the left femur had healed with no obvious fracture line.

treatment is usually required; however, this is complicated by the difficulty of working with the extremely hard bones (23). Plate osteosynthesis, intramedullary nailing and total joint arthroplasty are all suitable options. Hasan *et al* (24) provided a summary of the difficulties in treating OP fractures, including broken/bent drill bits, infection, hard bone, bone overheating, periprosthetic fracture, slow healing of fracture and narrow medullary canal, and concluded that plate osteosynthesis may be preferred.

In addition to those specific treatments, for the majority of patients with OP, supportive treatment is the most important (25), including painkillers and antibiotics for osteomyelitis (7). According to a study by Dunphy *et al* (18), antibiotic therapy combined with complete debridement of necrotic tissue, bacterial culture and sensitivity testing, followed by suturing of soft tissue, is the main therapeutic approach to patients with OP that is complicated with osteomyelitis of the mandible. A sequence of treatments, progressing from drainage, antibiotic therapy, sequestrectomy, tooth extraction, saucerization, decortication, to bone resection and oxygen therapy, has been proven to be valuable in the management of osteomyelitis (26). For patients with benign OP, non-operative treatment options include hip spica plaster cast, traction, splint and avoidance of weight bearing (24). A low-calcium diet can create a calcium-absorptive state and calcitriol can stimulate bone resorption, which may delay the process of bone sclerosis (27).

The patient in the present case was diagnosed with ADOP. The presence of anemia suggested the involvement of the bone marrow cavity. As the case was complicated with osteoarthritis and the patient had limited mobility, THA was selected as a suitable treatment. Difficulty was experienced in reaming the femoral medullary cavity due to the rigid, brittle bone and narrowed medullary cavity in OP. Thus, it is strongly recommended that surgeons performing this type of surgery prepare small reaming tools and small prostheses prior to surgery. The patient developed symptoms of sciatic nerve injury after the operation. The potential reasons for this were as follows: i) Limb lengthening and sciatic nerve traction; ii) compression

by the retractors during prolonged surgery; or iii) irrigation with iodine. In order to avoid complications such as fracture and excessive stretching of the sciatic nerve, gentle handling by surgeons is recommended. As regards postoperative checks, routine blood tests, blood biochemistry and pelvic X-ray should be reviewed regularly, and the patient should be closely observed. Postoperative functional exercises for patients with OP ought to be carried out as usual.

In conclusion, our patient was diagnosed with ADOP and hip osteoarthritis according to the clinical symptoms and imaging examinations. THA in this case may not be completely curative, but it was deemed as a useful method for reducing hip pain and improving the quality of the patient's life. As the previous literature on patients with OP complicated with hip osteoarthritis who required THA is limited, the treatment approach in the present case may represent a feasible option for such patients. There were certain limitations to the present study: Only one case was included, the follow-up was only 2 years, and genetic examinations and information on the bone growth of the prosthesis were lacking. Additional case reports with successful treatment are required in the future to help reach a consensus on the optimal treatment for such patients.

#### Acknowledgements

Not applicable.

#### Funding

This study was supported by the National Fund Cultivation Program of Tong Ren Hospital Affiliated to Shanghai Jiao Tong University School of Medicine(Shanghai, China, TRYJ(JC)03 ) and Maternal and Child Health Care Project in Jiangsu Province (F201656).

#### Availability of data and materials

The datasets used and/or analyzed during the current study are available from the corresponding author on reasonable request.

### Authors' contributions

XG collected and analyzed the data, participated in the discussion, conducted the literature search, and wrote the initial draft of the manuscript. QC performed the surgery, analyzed and discussed the data, finalized the manuscript. XZ conceptualized and oversaw the project, discussed and analyzed the data, critically revised and finalized the manuscript. GZ participated in the surgery and data discussion. All authors approved the final manuscript.

### Ethics approval and consent to participate

Not applicable.

### Patient consent for publication

Written consent was obtained from the patient for the publication of this case report and all accompanying images.

### Competing interests

The authors declare that they have no competing interests.

### References

- Palagano E, Menale C, Sobacchi C and Villa A: Genetics of Osteopetrosis. *Curr Osteoporos Rep* 16: 13-25, 2018.
- Moreno Garcia MS and Del Río-Martínez PS: Osteopetrosis type II: Albers-Schonberg disease. *Joint Bone Spine* 83: 231, 2016.
- Pang Q, Chi Y, Zhao Z, Xing X, Li M, Wang O, Jiang Y, Liao R, Sun Y, Dong J and Xia W: Novel mutations of CLCN7 cause autosomal dominant Osteopetrosis type II (ADO-II) and intermediate autosomal recessive Osteopetrosis (IARO) in Chinese patients. *Osteoporos Int* 27: 1047-1055, 2016.
- Machado Cde V, da Rocha MC and Telles PD: Infantile Osteopetrosis associated with osteomyelitis. *BMJ Case Rep* 2015: pii: bcr2014208085, 2015.
- Stattin EL, Henning P, Klar J, McDermott E, Stecksén-Blicks C, Sandström PE, Kellgren TG, Rydén P, Hallmans G, Lönnerholm T, *et al*: SNX10 gene mutation leading to Osteopetrosis with dysfunctional osteoclasts. *Sci Rep* 7: 3012, 2017.
- Nour M: Infantile malignant Osteopetrosis. *J Pediatrics* 163: 1230-1230.e1, 2013.
- Saigal A, Gopal M, Mohanty N and Misra SR: Recurrent osteomyelitis of the mandible in Osteopetrosis: A common complication of an uncommon disease. *BMJ Case Rep* 2015: pii: bcr2014208974, 2015.
- Alsahlawi A, Ekhzaimy A, Alshowair D and Ajlan A: Decompressive cranioplasty in a patient with osteopetrosis. *World Neurosurg* 108: 991.e1-991.e5, 2017.
- Stella I, Vinchon M, Guerreschi P, De Berranger E and Bouacha I: Case update on cranial Osteopetrosis: Which is the role of the neurosurgeon? *Childs Nerv Syst* 33: 2181-2186, 2017.
- Akutsu N, Koyama J, Kawamura A, Nagashima T, Taniguchi M and Kohmura E: Endoscopic third ventriculostomy for hydrocephalus in Osteopetrosis: A case report and review of the literature. *Childs Nerv Syst* 34: 991-994, 2018.
- Mosayebi Z, Mirfazaelian H, Khademi B, Bagheri N and Daneshbod Y: Osteopetrosis in siblings. *Intern Emerg Med* 11: 615-616, 2016.
- Butscheidt S, Rolvien T, Kornak U, Schmidt FN, Schinke T, Amling M and Oheim R: Clinical significance of DXA and HR-pQCT in autosomal dominant Osteopetrosis (ADO II). *Calcif Tissue Int* 102: 41-52, 2018.
- Wu CC, Econs MJ, DiMeglio LA, Insogna KL, Levine MA, Orchard PJ, Miller WP, Petryk A, Rush ET, Shoback DM, *et al*: Diagnosis and management of Osteopetrosis: Consensus guidelines from the Osteopetrosis working group. *J Clin Endocrinol Metab* 102: 3111-3123, 2017.
- Stark Z: Osteopetrosis. *Orphanet J Rare Dis* 4: 5, 2009.
- Hashemi Taheri AP, Radmard AR, Kooraki S, Behfar M, Pak N, Hamidieh AA and Ghavamzadeh A: Radiologic resolution of malignant infantile Osteopetrosis skeletal changes following hematopoietic stem cell transplantation. *Pediatric Blood Cancer* 62: 1645-1649, 2015.
- Erkus S, Turgut A, Kose O and Kalenderer Ö: Management of early-onset hip osteoarthritis in an adolescent patient with OP tarda: A case report. *J Pediatr Orthop B* 28: 487-490, 2019.
- Stepensky P, Grisariu S, Avni B, Zaidman I, Shadur B, Elpeleg O, Sirin M, Hoenig M, Schuetz C, Furlan I, *et al*: Stem cell transplantation for Osteopetrosis in patients beyond the age of 5 years. *Blood Adv* 3: 862-868, 2019.
- Dunphy L, Warfield A and Williams R: Osteomyelitis of the mandible secondary to malignant infantile Osteopetrosis in an adult. *BMJ Case Rep* 12: pii: e224452, 2019.
- Cao W, Wei W, Yu G, Wu Q and Qin M: Comparison of optic canal diameter in children with malignant infantile Osteopetrosis and normal children and the effects of hematopoietic stem cell transplantation on the optic canal diameter. *J Pediatr Ophthalmol Strabismus* 56: 35-42, 2019.
- Overholt KM, Rose MJ, Joshi S, Herman GE, Bajwa R, Abu-Arja R, Rangarajan HG and Horwitz EM: Hematopoietic cell transplantation for a child with OSTM1 Osteopetrosis. *Blood Adv* 1: 279-281, 2017.
- Shadur B, Zaidman I, NaserEddin A, Lokshin E, Hussein F, Oron HC, Avni B, Grisariu S and Stepensky P: Successful hematopoietic stem cell transplantation for Osteopetrosis using reduced intensity conditioning. *Pediatr Blood Cancer* 65: e27010, 2018.
- Maurizi A, Capulli M, Patel R, Curle A, Rucci N and Teti A: RNA interference therapy for autosomal dominant Osteopetrosis type 2 towards the preclinical development. *Bone* 110: 343-354, 2018.
- Yamane K and Kai N: Anterior cervical arthrodesis for chronic hangman's fracture in a patient with Osteopetrosis: A case report. *Arch Orthop Trauma Surg* 138: 783-789, 2018.
- Hasan O, Pathan AZ, Naqi H, Aqueel T, Hashmi P and Lakdawala RH: Inheritance patterns, challenges, and outcomes of fracture management in Osteopetrosis patients. *CASE series and review of pertinent literature. Ann Med Surg (Lond)* 36: 191-198, 2018.
- Teti A and Econs MJ: Osteopetroses, emphasizing potential approaches to treatment. *Bone* 102: 50-59, 2017.
- Carvalho PHA, Moura LB, Real Gabrielli MF, Cabrini Gabrielli MA and Antonio Pereira Filho V: Maxillary osteomyelitis associated with Osteopetrosis: Systematic review. *J Craniomaxillofac Surg* 46: 1905-1910, 2018.
- Wang J, Liang Y, Zhang Q, Jiao J and Kan W: Total joint arthroplasty in a patient with Osteopetrosis: 10-year follow-up. *Orthopedics* 33, 2010. doi: 10.3928/01477447-20100225-23.



This work is licensed under a Creative Commons Attribution-NonCommercial-NoDerivatives 4.0 International (CC BY-NC-ND 4.0) License.