

Therapeutic response to ramucirumab + folfiri in patients with metastatic gastric cancer

Hamid Rezvani¹, Shirin Haghighi¹, Mehdi Ghobakhlou², Elnaz Ataei³

¹Department of Hematology and Oncology, Taleghani Hospital, Shahid Beheshti University of Medical Sciences, Tehran,

²Department of Endoscopy, Bou-Ali Hospital, Hamadan, ³Clinical Research Development Center, Shahid Modarres Educational Hospital, Shahid Beheshti University of Medical Sciences, Tehran, Iran

ABSTRACT

Background: Gastric tumors are important gastrointestinal malignancies, and the prediction of therapeutic responses and related factors are important to improve the prognosis. Hence the aim of this study was to determine the therapeutic response to ramucirumab + folfiri in patients with metastatic gastric cancer. **Methods and Materials:** In this prospective cohort, 13 consecutive patients with metastatic gastric cancer attending Taleghani Hospital that underwent ramucirumab + folfiri therapy were enrolled, and the therapeutic response among them was determined. **Results:** The results in this study demonstrated that initial therapeutic response was 92.3% and the Progression-free Survival (PFS) was 16.2 months (84.6%) (CI95%:13.2-19.3). The nine-month PFS was 69.2%. Total survival was 16.7 months (CI95%:13.5-19.9). **Conclusion:** Ultimately, according to the obtained results, it may be concluded that the therapeutic response to ramucirumab + folfiri in a patient with metastatic gastric cancer is good, and the use of this regimen is recommended.

Keywords: Folfiri, gastric cancer, ramucirumab, treatment

Introduction

Gastric cancer is a common alimentary malignancy responsible for the second cancer-related mortality worldwide. Despite the decreased rate of gastric cancer in western countries, the prevalence of adenocarcinoma in the junction of cardia and esophagus-cardia has risen with a low five-year survival rate and mean length of six to ten months with chemotherapy.^[1,2] There is no standard chemotherapy regimen for gastric cancer patients.^[3,4] Despite good efficacy in the initial stages, it is usually diagnosed in the late stages.^[5,6] Gastric cancer is the most common cancer in men and the second one after breast malignancy in women in Iran and some other countries.^[7,8] It may result in distant

metastasis if not treated.^[9,10] In advanced stages, the therapeutic outcomes are poor even after the use of optimal treatment.^[11,12] Various clinical symptoms in patients demonstrate the possibility of various therapeutic regimens for treatment.^[13-15] Without the treatment, the survival in advanced stages is 3–4 months.^[5] VEGF, VEGFR-1 and VEGFR-2 are integrated in angiogenesis and growth and metastasis of tumors.^[3] Inactivation of signaling pathways by antibodies against VEGF and VEGFR and via small molecular tyrosine-kinase inhibitors may result in decreased vascular and tumoral growth.^[3] The current therapeutic protocol I based on oxaliplatin or vitamin action plus fluoropyrimidine.^[2] In phase II and III studies, chemotherapy regimens including oxaliplatin or irinotecan plus bevacizumab (IgG1 against VEGF) are the main therapeutic targets to improve the survival in metastatic cases.^[11-14] Ramucirumab is a monoclonal antibody attaching to VEGFR-2 and blocking the VEGF legends leading to inhibitory effects on proliferation and movement of endothelial cells.^[15] In some phase-II studies, Ramucirumab plus Folfiri was the first-line therapy with good efficacy.^[16] Regarding

Address for correspondence: Dr. Elnaz Ataei, Internal Ward, Shahid Modarres Educational Hospital, Sa'adat Abad, Tehran, Iran.
E-mail: elnaz.ataie.us@gmail.com

Received: 21-08-2021

Revised: 22-01-2022

Accepted: 31-01-2022

Published: 14-10-2022

Access this article online

Quick Response Code:



Website:
www.jfmipc.com

DOI:
10.4103/jfmipc.jfmipc_1678_21

This is an open access journal, and articles are distributed under the terms of the Creative Commons Attribution-NonCommercial-ShareAlike 4.0 License, which allows others to remix, tweak, and build upon the work non-commercially, as long as appropriate credit is given and the new creations are licensed under the identical terms.

For reprints contact: WKHLRPMedknow_reprints@wolterskluwer.com

How to cite this article: Rezvani H, Haghighi S, Ghobakhlou M, Ataei E. Therapeutic response to ramucirumab + folfiri in patients with metastatic gastric cancer. J Family Med Prim Care 2022;11:5166-9.

some controversies in this era and the high prevalence rate of advanced gastric cancer,^[17-19] this study was carried out to determine the therapeutic response to ramucirumab + folfiri in patients with metastatic gastric cancer.

Materials and Methods

In this prospective cohort, 13 consecutive patients with metastatic gastric cancer attending Taleghani Hospital I 2018 and 2019 were enrolled, including those that underwent ramucirumab + folfiri therapy, and the therapeutic response among them was determined. Inclusion criteria were gastric adenocarcinoma, metastasis, optimal functional status, and appropriate renal and hepatic function. The exclusion criteria were inappropriate functional status, loss to follow-up, previous treatment, severe background disease or infection, brain metastasis, and neuropathy. The study was approved by the local ethical committee in Shahid-Beheshti University of Medical Sciences.

The patients with established gastric adenocarcinoma with metastasis (approved by physical examination beside spiral CT scan and bone scan) with optimal functional status (FIGO score of 0 to 2) were enrolled. An informed consent form was received from patients. Ramucirumab was prescribed biweekly, and after the first three doses, the patients were assessed by clinical and imaging modalities. In responsive/stable cases, maximally six and occasionally eight courses were used. In cases experiencing adverse effects or disease progression, the treatment was discontinued earlier than six months. Patients that received minimally two treatment cycles were enrolled. Total response rate, Progression Free Survival (PFS), Overall Survival (OS), and adverse drug effects were recorded. After the third cycle, the response was assessed by RECIST criteria. Complete response, defined as the absence of all tumoral lesions, was assessed by endoscopy, biopsy, and CT scan. Partial response was defined as a minimal 30% reduction in tumoral lesions as compared to the initial size. The stable disease in patients was defined as a lack of the change in the size of the tumor in comparison with the smallest size at initiation or after 1–2 new lesions are present.

Data analysis was carried out by SPSS version 13.0 software among 13 patients. The utilized tests were ANOVA, Independent-Sample-T, and Kaplan-Meier tests, and the *P* values under 0.05 were considered statistically significant.

Results

Initial therapeutic response was seen in 12 out of 13 patients (92.3%). PFS was 84.6%, and nine-month PFS was also calculated as 69.2%. As shown in Figure 1, the mean duration of PFS was 16.2 months (CI: 95%: 13.2–19.3 months).

As shown in Figure 2, the mean duration of overall survival was 16.7 months (CI: 95%: 13.5–19.9 months).

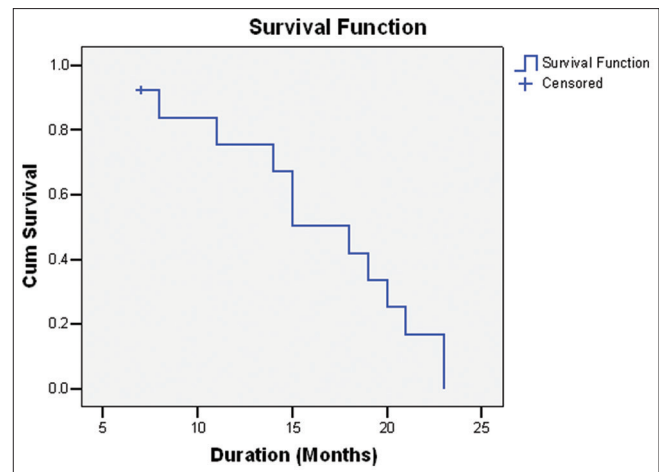


Figure 1: Progression-free survival in patients

Duration of PFS was 17 and 15.3 months in female and male patients, respectively, showing a significant difference ($P = 0.001$). Duration of overall survival was 19 and 15.3 months in female and male patients, respectively, showing a significant difference ($P = 0.001$). The age was not related to survival ($P = 0.676$; $r = 0.128$). As shown in Tables 1 and 2, the PFS and OS were not differed according to the metastasis location ($P > 0.05$).

Discussion

Chemotherapy is the main therapeutic method in gastric cancer patients.^[3] Further efficacy and a lower rate of adverse effects develop a good prognosis and quality of life in the patients. In this study, the efficacy and safety of a regimen including ramucirumab plus folfiri was assessed in patients with metastatic gastric cancer. The overall and progression-free survival rates of 92 and 85 percent were encouraging outcomes with a mean duration of 16 and 17 months, respectively. Lorenzen S *et al.*^[16] demonstrated good efficacy for Ramucirumab plus Folfiri regimen as well as our study.

Moore *et al.*^[17] also compared the efficacy of Folfox-6 plus ramucirumab versus icrucumab. They reversely reported no optimal efficacy for both regimens. Taberbero J *et al.*^[18] compared efficacy of Folfiri plus ramucirumab versus placebo in colorectal cancer patients. The overall survival was 13.3 versus 7.7 months in intervention and placebo groups, respectively. Neutropenia was seen in 38 and 23 percent of the cases, respectively. But the side effects had a lower rate in our study.

Al-Batran *et al.*^[11] compared the quality of life and survival after the use of Folfiri plus ramucirumab versus placebo. They reported better quality of life and longer survival in the intervention group. It is congruent with our findings. Attarian *et al.*^[19] reported mortality rate of 65 percent in 19-month follow-up by various chemotherapy regimens, including cisplatin and docetaxel plus Folfiri. The mean overall survival was ten months. However, the efficacy and outcomes were better in our study.

Table 1: Overall survival according to the location of metastasis

loc	Time	Status	Cumulative Proportion Surviving at the Time		n of Cumulative Events	n of Remaining Cases
			Estimate	Std. Error		
Liver						
1	7.000	Pos	0.833	0.152	1	5
2	11.000	Pos	0.667	0.192	2	4
3	14.000	Pos	0.500	0.204	3	3
4	15.000	Pos	0.333	0.192	4	2
5	18.000	Pos	0.167	0.152	5	1
6	21.000	Pos	0.000	0.000	6	0
Lung						
1	8.000	Pos	0.500	0.354	1	1
2	15.000	Pos	0.000	0.000	2	0
Bone Marrow						
1	23.000	Pos	0.000	0.000	1	0
Peritoneum						
1	7.000	Neg	.	.	0	0
Ovary						
1	23.000	Pos	0.000	0.000	1	0
Locally Advanced						
1	19.000	Pos	0.500	0.354	1	1
2	20.000	Pos	0.000	0.000	2	0

Table 2: Progression-free survival according to the location of metastasis

loc	Time	Status	Cumulative Proportion Surviving at the Time		n of Cumulative Events	n of Remaining Cases
			Estimate	Std. Error		
Liver						
1	7.000	Pos	0.833	0.152	1	5
2	11.000	Pos	0.667	0.192	2	4
3	14.000	Pos	0.500	0.204	3	3
4	15.000	Pos	0.333	0.192	4	2
5	18.000	Pos	0.167	0.152	5	1
6	21.000	Pos	0.000	0.000	6	0
Lung						
1	8.000	Pos	0.500	0.354	1	1
2	15.000	Neg	.	.	1	0
Bone Marrow						
1	23.000	Pos	0.000	0.000	1	0
Peritoneum						
1	7.000	Neg	.	.	0	0
Ovary						
1	23.000	Pos	0.000	0.000	1	0
Locally advanced						
1	19.000	Pos	0.500	0.354	1	1
2	20.000	Pos	0.000	0.000	2	0

It has been demonstrated that both the incidence of cancer and cancer mortality are growing rapidly worldwide. Malignancies of the gastrointestinal (GI) tract such as the esophagus, pancreas, stomach, colon, rectum, anus, liver, biliary system, and small intestine are among the five most common cancers in both men and women worldwide. GI cancers are overall the most common causes of cancer-related death in men.^[20] A recent study showed that FOLFIRI is an active and well-tolerated regimen after the failure of a fluoropyrimidine/platinum regimen in patients with advanced gastroesophageal adenocarcinoma. Population with

poor prognostic features was well represented. Efficacy outcomes were similar to the ones reported for the paclitaxel/ramucirumab combination RAINBOW trial.^[21] Previous studies reported that the use of ramucirumab in combination with FOLFIRI showed favourable progression-free survival and overall survival in patients with prior treatments with platinum and/or taxane-based agents and allowed further treatment lines after progression. In patients with taxane pretreatment or persistent high-grade PNP, the combination of FOLFIRI-R might be promising.^[22] Finally, according to the obtained results, it may be concluded that therapeutic response to

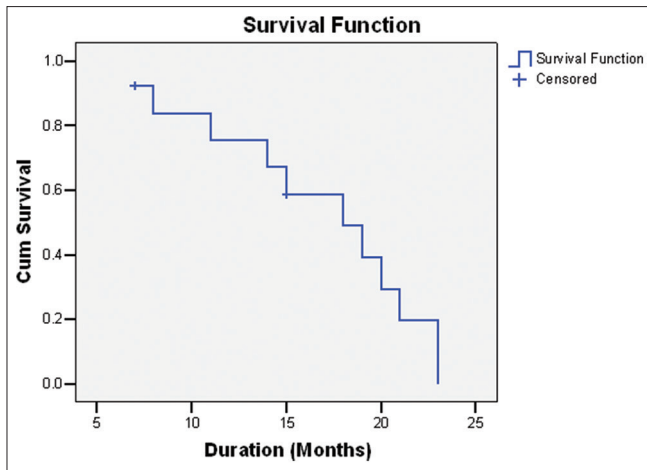


Figure 2: Overall survival in patients

ramucirumab + folfiri in a patient with metastatic gastric cancer is good, and the use of this regimen is recommended. However, further studies with a larger sample size and longer follow-up in multiple centers are required for more definite results.

Financial support and sponsorship

Nil.

Conflicts of interest

There are no conflicts of interest.

References

- Al-Batran S-E, Van Cutsem E, Oh S, Bodoky G, Shimada Y, Hironaka S, *et al.* Quality-of-life and performance status results from the phase III RAINBOW study of ramucirumab plus paclitaxel versus placebo plus paclitaxel in patients with previously treated gastric or gastroesophageal junction adenocarcinoma. *Ann Oncol* 2016;27:673-9.
- Butler T, Maravent S, Boisselle J, Valdes J, Felner C. A review of 2014 cancer drug approvals, with a look at 2015 and beyond. *Pharm Ther* 2015;40:191-205.
- Casak SJ, Fashoyin-Aje I, Lemery SJ, Zhang L, Jin R, Li H, *et al.* FDA approval summary: Ramucirumab for gastric cancer. *Clin Cancer Res* 2015;21:3372-6.
- Winawer SJ. Gastric cancer: Worldwide burden and prevention opportunities. *Chin J Dig Dis* 2005;6:107-9.
- Sotoudeh M, Mirsamadi MM, Sedghi M. Comparison of the type of intera-cellular mucin in patients with H. pylori gastritis and normal population. *Tehran Uni Med J* 2002;29:245.
- Fauci AS, Braunwald E, Kasper DL, Hauser SL, Longo DL, Jameson JL, *et al.* Harrison's Principles of Internal Medicine. 17th ed. McGraw-Hill; 2008.
- Farhood B, Geraily G, Alizadeh A. Incidence and mortality of various cancers in Iran and compare to other countries: a review article. *Iranian Journal of Public Health* 2018;47:309.
- Mousavi SK, Janbabai G, Kouchaki B, Borhani H, Rashidi M, Salehifar E. Demographic and clinical characteristics of gastric cancer patients in north of Iran, Mazandaran province, 2008-2014. *Pharmaceutical and Biomedical Research* 2015;1:32-6.
- de Martel C, Ferlay J, Franceschi S, Vignat J, Bray F, Forman D, *et al.* Global burden of cancers attributable to infections in 2008: A review and synthetic analysis. *Lancet Oncol* 2012;13:607-15.
- Roder DM. The epidemiology of gastric cancer. *Gastric Cancer* 2002;5(Suppl 1):5-11.
- Fala L. Ramucirumab (ramucirumab) approved for the treatment of advanced gastric cancer and metastatic non-small-cell lung cancer. *Am Health Drug Benefits* 2015;8:49-53.
- Ahmadzadeh A, Seyedian SS, Valizadeh A, Soleimani M, Nazari P, Hamidi H. The Efficacy and Safety of Modified Docetaxel, Cisplatin, and 5-Fluorouracil Vs. Epirubicin, Oxaliplatin, and Capecitabine Regimen in the Advanced Gastric Cancer: A Randomized Controlled Clinical Trial. *Asian Pac J Cancer Prev* 2020;21:727-32.
- Fuchs CS, Muro K, Tomasek J, Van Cutsem E, Cho JY, Oh S-C, *et al.* Prognostic factor analysis of overall survival in gastric cancer from two phase III studies of second-line ramucirumab (REGARD and RAINBOW) using pooled patient data. *J Gastric Cancer* 2017;17:132-44.
- Greig SL, Keating GM. Ramucirumab: A review in advanced gastric cancer. *BioDrugs* 2015;29:341-51.
- Javle M, Smyth EC, Chau I. Ramucirumab: Successfully targeting angiogenesis in gastric cancer. *Clin Cancer Res* 2014;20:5875-81.
- Lorenzen S, Thuss-Patience PC, Pauligk C, Goekkurt E, Ettrich TJ, Lordick F, *et al.* FOLFIRI plus ramucirumab versus paclitaxel plus ramucirumab for patients with advanced or metastatic adenocarcinoma of the stomach or gastroesophageal junction as second-line therapy: The RAMIRIS study. *Am Soc Clin Oncol* 2018;36:4023.
- Moore M, Gill S, Asmis T, Berry S, Burkes R, Zbuk K, *et al.* Randomized phase II study of modified FOLFOX-6 in combination with ramucirumab or icrucumab as second-line therapy in patients with metastatic colorectal cancer after disease progression on first-line irinotecan-based therapy. *Ann Oncol* 2016;27:2216-24.
- Tabernero J, Yoshino T, Cohn AL, Obermannova R, Bodoky G, Garcia-Carbonero R, *et al.* Ramucirumab versus placebo in combination with second-line FOLFIRI in patients with metastatic colorectal carcinoma that progressed during or after first-line therapy with bevacizumab, oxaliplatin, and a fluoropyrimidine (RAISE): A randomised, double-blind, multicentre, phase 3 study. *Lancet Oncol* 2015;16:499-508.
- Atarian H, Ghadyani M, Rezvani H, Abasahl AAGH. The Effective Chemotherapy Regimen For Advanced Unresectable Gastric Cancer. *Iranian Journal of Surgery* 2007;15:80-6.
- Chen MH, Lu SN, Chen CH, Lin PC, Jiang JK, D'yachkova Y, *et al.* How may ramucirumab help improve treatment outcome for patients with gastrointestinal cancers?. *Cancers (Basel)* 2021;13:3536.
- Leão I, Marinho JCL, Neto ES, Guedes H, Joaquim A, Moreira Pinto A, *et al.* Clinical experience: FOLFIRI/XELIRI after failure of a fluoropyrimidine/platinum combination regimen in advanced gastroesophageal adenocarcinoma. *Journal of Clinical Oncology* 2021;39.
- Vogl UM, Vormittag L, Winkler T, Kafka A, Weiser-Jasch O, Heinrich B, *et al.* Ramucirumab plus paclitaxel or FOLFIRI in platinum-refractory advanced or metastatic gastric or gastroesophageal junction adenocarcinoma—experience at two centres. *J Gastrointest Oncol* 2020;11:366-75.