

Available online at www.sciencedirect.com

ScienceDirect

journal homepage: www.elsevier.com/locate/radcr

Case report

Spontaneous pneumomediastinum, pneumothorax and subcutaneous emphysema: Radiological aspects of rare COVID-19 complications in 3 patients ☆

Maša Radeljak Protrka, MD^{a,*}, Gordana Ivanac, assoc. prof^{a,c}, Luka Đudarić, MD, PhD^{a,b}, Filip Vujević, MD^a, Boris Brkljačić, prof^{a,c}

^a Department of Diagnostic and Interventional Radiology, University Hospital Dubrava, Avenija Gojka Šuška 6b, Zagreb 10000, Croatia

^b Department of Radiology, General Hospital Pula/Dipartimento di Radiologia, Ospedale Generale di Pola, Pula/Pola, Croatia

^c School of Medicine, University of Zagreb, Zagreb, Croatia

ARTICLE INFO

Article history:

Received 4 July 2021

Revised 31 July 2021

Accepted 31 July 2021

Available online 6 August 2021

Keywords:

Pneumomediastinum

Pneumothorax

COVID-19

Computed tomography

x-ray

ABSTRACT

Spontaneous pneumomediastinum (SPM), pneumothorax (PNX) and subcutaneous emphysema are rare complications of COVID-19 pneumonia. In this paper we describe 3 cases of COVID-19 pneumonia complicated by SPM with or without PNX. Patient 1 was a 56-year-old woman whose medical history was significant for chronic leukemia. She presented with typical clinical signs of COVID-19 pneumonia and after 2 weeks of hospitalization she developed SPM and subcutaneous emphysema. The management of pneumomediastinum (PNM) was conservative and follow-up computed tomography showed resolution of PNM. Patient 2 was a 67-year-old man presenting with fever, cough and dyspnea. Computed tomography pulmonary angiography was performed after 2 weeks of hospitalization and showed bilateral peripheral consolidations together with massive PNM and right-sided PNX. Thoracic drainage catheter was inserted in his right chest. Despite all supportive care, the patient succumbed to illness. Patient 3 was a 74-year-old man who was admitted to our hospital with COVID-19 pneumonia and spontaneous right-sided PNX. A thoracic drainage catheter was inserted immediately and then removed after ten days which has led to progression of subcutaneous emphysema, PNX and newly diagnosed PNM. Patient was carefully monitored for the next 2 weeks. Follow-up chest x-ray showed regression of PNM and PNX. SPM, PNX and subcutaneous emphysema are rare complications of COVID-19 pneumonia. Increased alveolar pressure and diffuse alveolar injury in severe COVID-19 pneumonia may make the alveoli more prone to rupturing which leads to gas dissemination along the peribronchovas-

☆ Competing interests: The authors declare that they have no known competing financial interests or personal relationships that could have appeared to influence the work reported in this paper.

* Corresponding author.

E-mail address: masharadeljak@hotmail.com (M.R. Protrka).

<https://doi.org/10.1016/j.radcr.2021.07.089>

1930-0433/© 2021 The Authors. Published by Elsevier Inc. on behalf of University of Washington. This is an open access article under the CC BY-NC-ND license (<http://creativecommons.org/licenses/by-nc-nd/4.0/>)

cular sheath to the mediastinum. Most cases of SPM and PNx resolve with conservative management.

© 2021 The Authors. Published by Elsevier Inc. on behalf of University of Washington.

This is an open access article under the CC BY-NC-ND license

(<http://creativecommons.org/licenses/by-nc-nd/4.0/>)

Introduction

A new coronavirus identified on samples of the airways named severe acute respiratory syndrome coronavirus 2 (SARS-CoV-2) first appeared in Wuhan in China in December 2019 and is quickly spreading worldwide. World Health Organization officially named this disease Coronavirus Disease 2019 (COVID-19) in February 2020 [1]. COVID-19 pneumonia represents a major challenge for intensive care units mainly because of the high number of admission to intensive care units, the prolonged time of hospitalization and increased mortality often due to comorbidities [2].

The main clinical signs during COVID-19 pneumonia are fever, cough, sputum and dyspnea occurring on the first day of infection [3]. Other symptoms such as myalgia, diarrhea and nausea are frequently reported [4,5]. Some patients presenting with severe dyspnea and hypoxemia may rapidly develop acute respiratory distress syndrome, respiratory failure and consequently multiple organ failure [6].

The primary findings of COVID-19 on chest radiographs and computed tomography (CT) are those of atypical or organising pneumonia. The most frequent findings are airspace opacities, described as consolidation or ground glass [7]. The distribution is most often multifocal, predominantly peripheral and basal [8]. Other CT findings are crazy paving appearance, inter/intralobular septal thickening, airspace consolidation, bronchovascular thickening in the lesion and traction bronchiectasis [9]. Pleural effusion is rare [10]. Chest CT is not used to diagnose COVID-19 but plays an important role in assessing complications.

Commonly reported pulmonary complications in patients with COVID-19 viral pneumonia are acute respiratory distress syndrome, pulmonary embolism, spontaneous pneumomediastinum (SPM) and pneumothorax (PNx) [11–13]. Although SPM and PNx are rare in viral pneumonia such as SARS-CoV-2 lung infection [14], until this day these rare pulmonary complications have been increasingly reported in literature [6,8,13,15]. The development of acute or worsening dyspnea is suspicious for the presence of SPM or PNx [16].

In the terms of COVID-19 pandemic our hospital was re-organized to care for patients who developed severe COVID-19 pneumonia. In this report we present 3 clinical cases of SPM with or without PNx associated with COVID-19 pneumonia.

Case presentation 1

A 56-year-old woman presented to the emergency room with 7 days of fever at 39.2°C, increasing cough and shortness of breath. She complained of headache and nausea. The patient

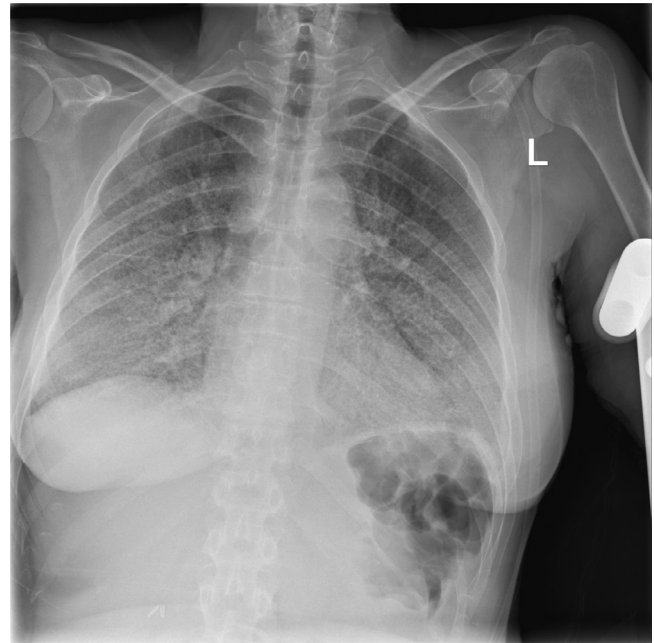


Fig. 1 – (Patient 1): Admission chest x-ray showing bilateral patchy infiltrates consistent with COVID-19 infection.

was diagnosed with COVID-19 on the basis of RT-PCR analysis of sputum samples.

Her medical history was significant for chronic lymphocytic leukemia which has been managed by a hematologist. She denied tobacco or alcohol use. Her physical exam revealed a middle-aged woman who appeared short of breath. She had a low grade fever of 37°C, blood pressure was 120/70 mmHg and pulse was 85 beats per minute (bpm). Her oxygen saturation was 75 % on room air, improving to 94 % on 15L/min non rebreather mask. The rest of her physical exam was within normal limits. Her labs were remarkable for white cell count of $14.8 \times 10^9/L$, low blood sodium levels with 124 mmol/L, elevated levels for aspartate aminotransferase (55 U/L, normal range 8–30 U/L) and slightly elevated levels for C-reactive protein (13.9 mg/L, normal range less of 5 mg/L). Her hemoglobin rate was low at 110 g/L. She had normal kidney function with urea at 7.7 mmol/L and creatinine at 52 mmol/L.

At admission her chest x-ray was remarkable for bilateral patchy infiltrates with basal predominance (Fig. 1). She was started on azithromycin, corticosteroids, low molecular weight heparin and intravenous paracetamol for short-term treatment of fever. She remained stable on non-invasive supplemental oxygen requiring 12–15 L/min. On hospital day 14, the computed tomography pulmonary angiogram (CTPA) was performed to exclude pulmonary embolism. CTPA was negative for pulmonary embolism but revealed bilateral ground-

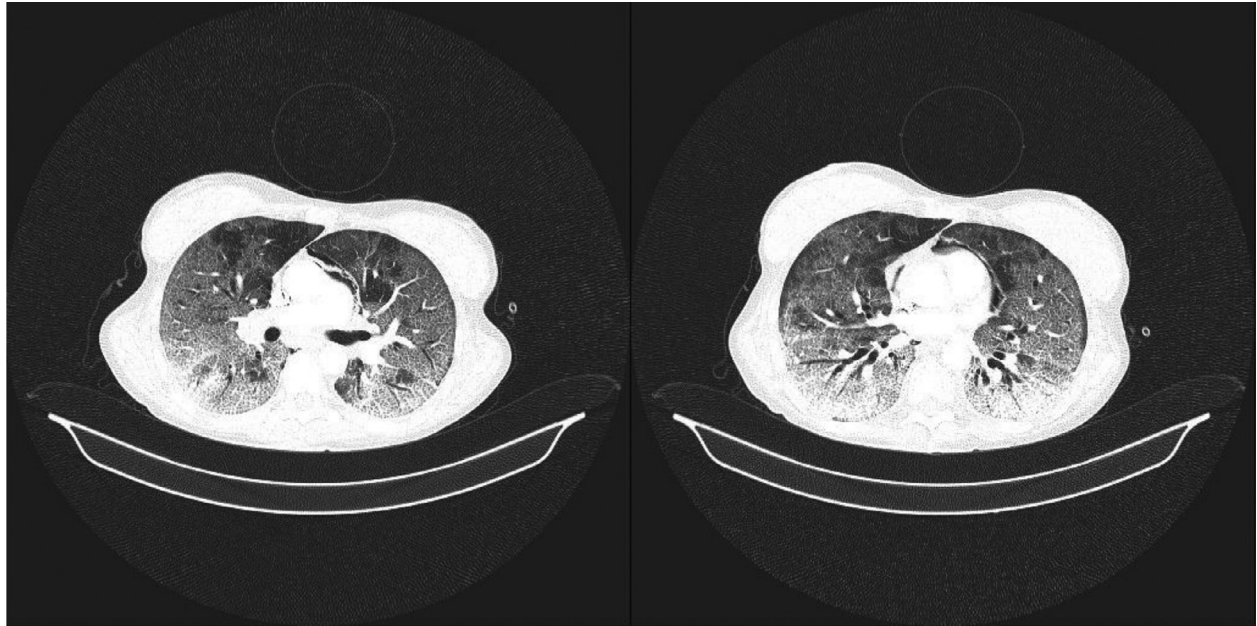


Fig. 2 – (Patient 1): Chest CT showing diffuse ground-glass opacities with interlobular and intralobular septal thickening producing a crazy-paving appearance characteristic of typical COVID-19 pneumonia. Low-to-medium abundant pneumomediastinum.

glass opacities with interlobular and intralobular septal thickening. In posterobasal segments of both lungs peripheral consolidations were described together with bronchiectasis. Besides bilateral infiltrates suggestive of COVID-19 infection, we found pneumomediastinum (PNM) with a small subcutaneous emphysema in the right axillary region of lateral thoracic wall (Fig. 2). No PNX was observed, the patient was considered to have SPM because no other sources of mediastinal air could be identified. Thoracic surgeon suggested conservative management of this rare complication which included monitoring of respiratory rate, oxygen saturation and blood pressure. Next day repeated chest x-ray demonstrated the bilateral infiltrates, PNM and subcutaneous emphysema in the neck (Fig. 3). By day 37 the patient's temperature had recovered to normal and her cough had improved. Follow-up chest x-ray and CT revealed resolution of previous PNM and reduction of parenchymal consolidation and the patient was discharged for outpatient follow-up (Fig. 4).

Case presentation 2

A 67-year-old man was transferred from another hospital to our emergency room with high fever, cough and dyspnea. RT-PCR analysis of COVID-19 was positive a week ago before the admission. His medical history was significant for hypertension. Clinical examination found a mildly tachypneic patient with oxygen saturation at 81 % in ambient air, a heart rate of 80 bpm and blood pressure at 185/110 mm Hg. After antipyretic treatment in the previous hospital, on presentation his temperature was 36,2°C. The rest of his physical exam was with no abnormalities. Laboratory studies showed white blood cells

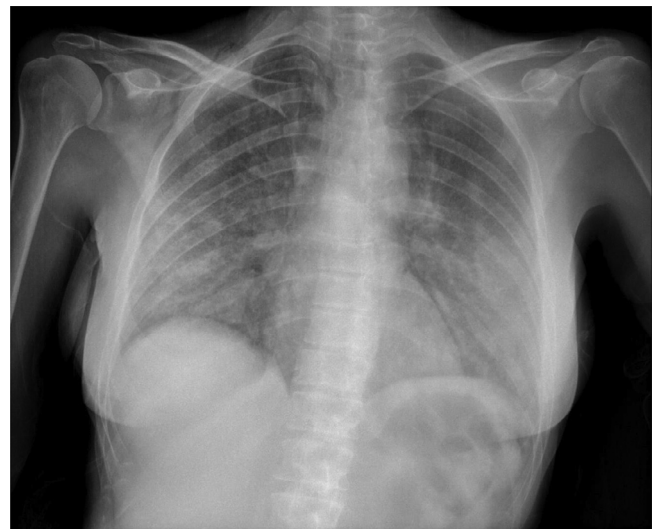


Fig. 3 – (Patient 1): Chest x-ray showing bilateral infiltrates, left-sided pneumomediastinum and subcutaneous emphysema in the neck.

level of $13,7 \times 10^9/L$, C- reactive protein at 101,9 mg/L, high levels of all liver enzymes and low sodium levels at 135 mmol/L.

He was started on low molecular weight heparin, corticosteroids, antibiotics and antihypertensive therapy. His oxygen saturation improved to 93 % after applying an oxygen mask. On the 14th day of hospitalization CTPA was performed. Bilateral peripheral consolidations comprising about 40 % of lung parenchyma were described together with massive PNM

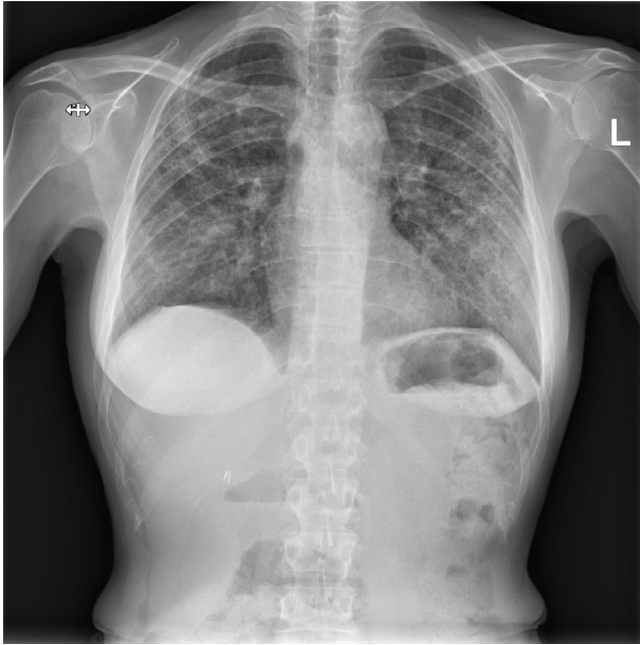


Fig. 4 – (Patient 1): Follow-up chest x-ray demonstrating complete resolution of pneumomediastinum and subcutaneous emphysema.

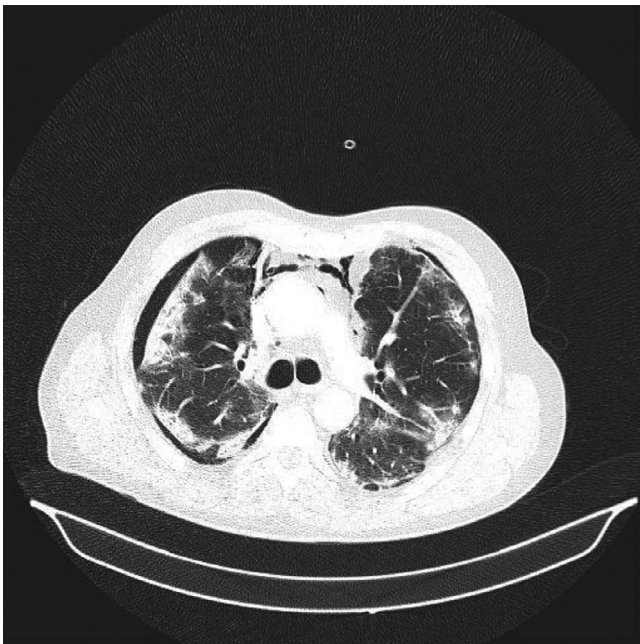


Fig. 5 – (Patient 2): Right-sided pneumothorax, pneumomediastinum and bilateral infiltrates.

from the level of aortic arch to heart base and right-sided PNX (Fig. 5).

Thoracic drainage catheter was inserted in the right chest and follow-up chest x-ray was performed showing a stationary aspect of the lesions especially in peripheral distribution, right-sided PNX and left PNM (Fig. 6). Despite combined an-

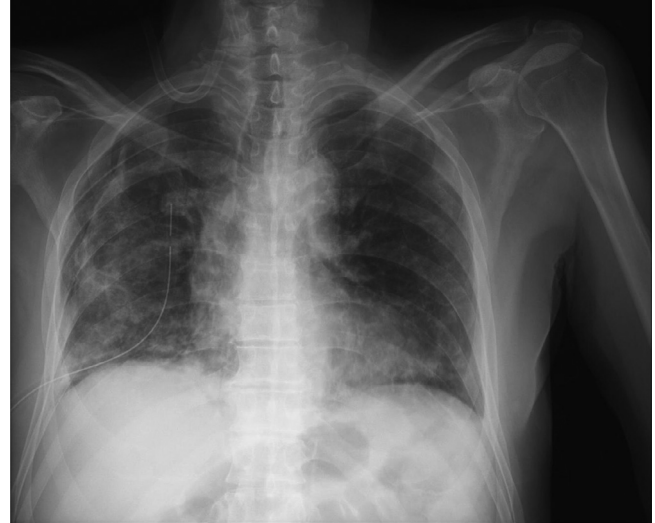

Fig. 6 – (Patient 2): Pneumomediastinum along the left heart border and right-sided pneumothorax. Diffuse patchy infiltrates consistent with COVID-19 pneumonia.

tiinflammatory drugs and supportive care unfortunately the patient succumbed to illness 2 weeks after the admission.

Case presentation 3

A 74-year-old man was admitted to our hospital after being previously diagnosed with COVID-19 pneumonia and spontaneous right-sided PNX in another local hospital. He complained of high fever (40°C), shortness of breath and cough for the last ten days. His medical history was positive for arterial hypertension. He was diagnosed with prostate and bladder cancer and treated with chemotherapy and radiotherapy. He had no history of cigarette smoking and alcohol use. On admission, clinical examination found a tachypneic patient with oxygen saturation at 86 % before applying an oxygen mask, the blood pressure of 160/90 mm Hg and a pulse rate of 102 bpm. His laboratory studies were remarkable for white cell count of $13,4 \times 10^9/L$. His D-dimer was 3,91 mg/LFEU and C-reactive protein was 81,2 mg/L.

His initial chest x-ray was remarkable for bilateral infiltrates and right-sided PNX (Fig. 7). A thoracic drainage catheter was inserted immediately and the patient was admitted to intensive care unit where he was started on corticosteroids, antibiotics, low molecular weight heparin, antihypertensive therapy and high flow nasal oxygen therapy. After ten days the thoracic drainage catheter was removed which has led to severe progression of subcutaneous emphysema and the patient was referred to chest CT scan. Chest CT showed bilateral peribronchovascular and peripheral zones of ground-glass opacification and consolidations, severe PNM, subcutaneous emphysema and right-sided PNX (Fig. 8). According to the thoracic surgeon there was no need for surgical treatment of PNX. Patient was carefully monitored for the next 2 weeks. His respiratory status improved over time and his supple-

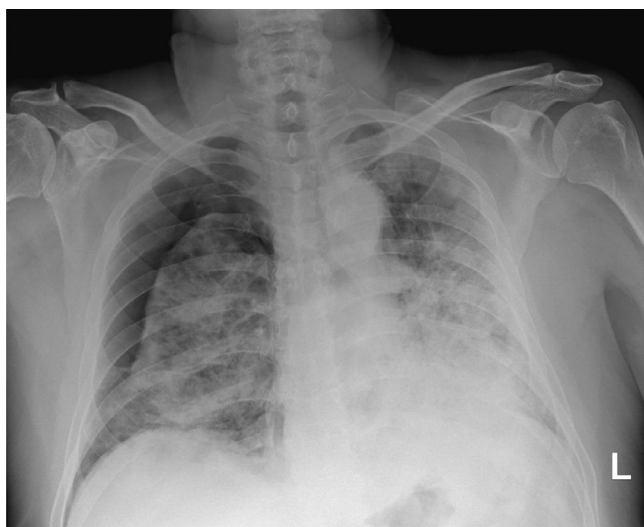


Fig. 7 – (Patient 3): Admission chest x-ray demonstrating extensive bilateral patchy infiltrates and right-sided pneumothorax.

mental oxygen requirements gradually decreased. His follow-up chest x-ray showed regression of PNM and PNx (Fig. 9). He was discharged after a month of hospitalization in stable condition.

Discussion

SPM, PNx and subcutaneous emphysema are rare complications of SARS-CoV-2 lung infection.

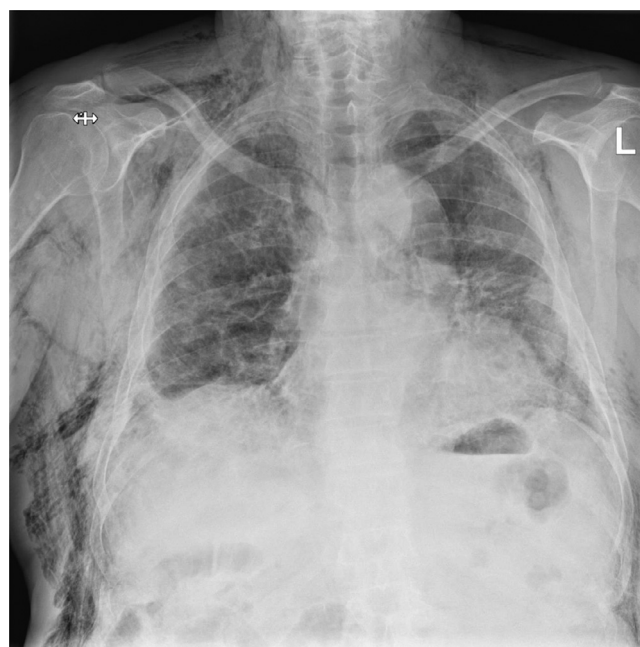

Fig. 9 – (Patient 3): Resolution of pneumothorax and pneumomediastinum. Partial regression of subcutaneous emphysema.

PNM is the presence of extraluminal gas within the mediastinum. It can be spontaneous or traumatic. Traumatic PNM is primarily caused by chest trauma, mechanical ventilation, cardiothoracic surgery and esophageal perforation [17,18]. SPM can be primary where no underlying lung disease is present or secondary in which an underlying lung or air-

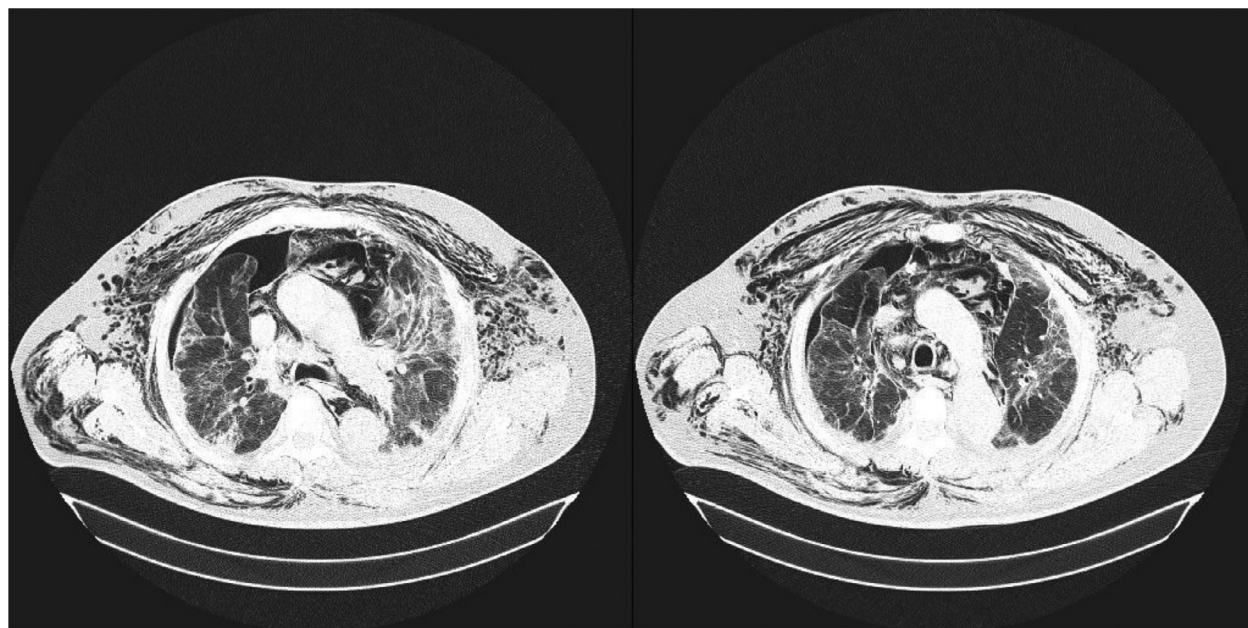


Fig. 8 – (Patient 3): Extensive subcutaneous emphysema, pneumomediastinum and right-sided pneumothorax. Bilateral ground-glass opacities and consolidations.

way disease that predisposes to air leak is present. Asthma or cystic fibrosis are examples of secondary spontaneous pneumomediastinum [16]. Spontaneous alveolar leakage is rare in viral pneumonia. An incidence of 11,6 % had been previously reported in terms of SARS outbreak, but a lower incidence of 0,72 % has been reported in patients with COVID-19 pneumonia [6].

Although the exact mechanism of SPM is still the object of many research, it is hypothesized to be a result of diffuse alveolar damage together with an increased intra-alveolar pressure [6]. Increased alveolar pressure and diffuse alveolar injury are common in patients with severe COVID-19 pneumonia which may make the alveoli more prone to rupturing, especially as patients often have a pronounced cough [14]. This pathophysiological process of alveolar rupture is known as Macklin effect [19]. Alveolar rupture leads to gas dissemination in the peribronchovascular space up to pulmonary hilum and the mediastinum. As the pressure in the mediastinum rises, the gas escapes to the neck resulting in subcutaneous emphysema or into the pleural cavities causing pneumothorax. Occasionally the air may escape through the thoracic inlet and cause subcutaneous emphysema [6], described in 2 of our patients. Subcutaneous emphysema in supraclavicular fossa may be the first clinical sign of PNM leading to the importance of careful review of this region on chest radiographs [13].

Recent studies showed that PNM is more likely to occur in patients with advanced stage of disease and extensive pulmonary lesions, leading to worse outcome [15]. However, SPM can also occur without the presence of extensive lung involvement with good clinical outcome and recovery [20].

In conclusion, SPM is usually a self-limiting disease with no specific treatment necessary, as described in 2 out of 3 of our patients. However, it can potentially cause severe circulatory and respiratory pathology and should be monitored closely as a possible aggravating factor in the prognosis of patients with COVID-19 pneumonia [16].

Patient consent

Approved by the local institutional review board (IRB). Because of the retrospective nature of the data analysis, the IRB waived the need for a signed informed consent.

REFERENCES

- [1] Available from: World Health Organization. WHO Director-General's remarks at the media briefing on 2019-nCoV on 11 February 2020. 2020. at <https://www.who.int/dg/speeches/detail/whodirector-general-s-remarks-at-the-media-briefing-on-2019-ncov-on-11-february-2020>. Published February 11, 2020.
- [2] Mimouni H, Diyas S, Ouachaou J, Laaribi I, Oujidi Y, Merbouh M, Bkiyer H, Housni B, et al. Spontaneous pneumomediastinum associated with COVID-19 pneumonia. *Case Rep Med* 2020;2020:4969486.
- [3] Alimohamadi Y, Sepandi M, Taghdir M, Hosamirudsari H. Determine the most common clinical symptoms in COVID-19 patients: a systematic review and meta-analysis. *J Prev Med Hyg* 2020;61(3):E304–E312 PMID: 33150219; PMCID: PMC7595075. doi:10.15167/2421-4248/jpmh2020.61.3.1530.
- [4] Abdullahi A, Candan SA, Abba MA, Bello AH, Alshehri MA, Afamefuna Victor E, et al. Neurological and musculoskeletal features of COVID-19: a systematic review and meta-analysis. *Front Neurol* 2020;11:687 PMID: 32676052; PMCID: PMC7333777. doi:10.3389/fneur.2020.00687.
- [5] D'Amico F, Baumgart DC, Danese S, Peyrin-Biroulet L. Diarrhea during COVID-19 infection: pathogenesis, epidemiology, prevention, and management. *Clin Gastroenterol Hepatol* 2020;18(8):1663–72 Epub 2020 Apr 8. PMID: 32278065; PMCID: PMC7141637. doi:10.1016/j.cgh.2020.04.001.
- [6] Rashedi S, Mardani M, Fooladgar M, Aliannejad R. Spontaneous pneumomediastinum, pneumopericardium, pneumothorax, and subcutaneous emphysema in a patient with COVID-19. *Radiol Case Rep* 2021;16(5):1158–61 Epub 2021 Mar 3. PMID: 33686352; PMCID: PMC7927643. doi:10.1016/j.radcr.2021.02.069.
- [7] Shirani F, Shayganfar A, Hajiahmadi S. COVID-19 pneumonia: a pictorial review of CT findings and differential diagnosis. *Egypt J Radiol Nucl Med* 2021;52:38. doi:10.1186/s43055-021-00415-2.
- [8] Rafiee MJ, Babaki Fard F, Samimi K, Rasti H, Pressacco J. Spontaneous pneumothorax and pneumomediastinum as a rare complication of COVID-19 pneumonia: report of 6 cases. *Radiol Case Rep*. 2021;16(3):687–92 Epub 2021 Jan 7. PMID: 33437348; PMCID: PMC7790462. doi:10.1016/j.radcr.2021.01.011.
- [9] Salehi S, Abedi A, Balakrishnan S, Gholamrezaezhad A. Coronavirus disease 2019 (COVID-19): a systematic review of imaging findings in 919 patients. *Am J Roentgenol* 2020;215:87–93.
- [10] Hussein Mousa, Haq Irfan Ul, Hameed Mansoor, Thomas Merlin, Elarabi Anam, Allingawi Mona, et al. Pleural effusion as an isolated finding in COVID-19 infection, 2021. *Respir Med Case Rep* 2020;Volume 31:101269 ISSN 2213-0071. doi:10.1016/j.rmcr.2020.101269.
- [11] Gibson PG, Qin L, Puah SH. COVID-19 acute respiratory distress syndrome (ARDS): clinical features and differences from typical pre-COVID-19 ARDS. *Med J Aust* 2020;213:54–6. doi:10.5694/mja2.50674.
- [12] Gill I, Chan S, Fitzpatrick D. COVID-19-associated pulmonary and cerebral thromboembolic disease. *Radiol Case Rep* 2020;15:1242–9.
- [13] Urigo C, Soin S, Sahu A. Spontaneous pneumomediastinum as a complication of a COVID-19 related pneumonia: case report and review of literature. *Radiol Case Rep* 2020;15(12):2577–81. doi:10.1016/j.radcr.2020.09.052.
- [14] Mohan V, Tauseen RA. Spontaneous pneumomediastinum in COVID-19. *BMJ Case Rep* 2020;13:1–2.
- [15] Kalpaxi A, Kalokairinou M, Katseli P, Savvopoulou V, Ioannidi P, Triantafyllou E, et al. Spontaneous pneumomediastinum and COVID-19 pneumonia: report of three cases with emphasis on CT imaging. *Radiol Case Rep* 2021;16(9):2586–92 Epub 2021 Jun 23. PMID: 34178187; PMCID: PMC8220909. doi:10.1016/j.radcr.2021.06.040.
- [16] Elhakim TS, Abdul HS, Pelaez Romero C, Rodriguez-Fuentes Y, et al. Spontaneous pneumomediastinum, pneumothorax and subcutaneous emphysema in COVID-19 pneumonia: a rare case and literature review. *BMJ Case Reports CP* 2020;13:e239489.
- [17] Vanzo V, Bugin S, Snijders D, Bottecchia L, Storer V, Barbato A. Pneumomediastinum and pneumopericardium in an 11-year-old rugby player: a case report. *J Athl Train* 2013;48(2):277–81 Epub 2013 Feb 20. PMID: 23672393; PMCID: PMC3600931. doi:10.4085/1062-6050-48.1.11.

-
- [18] Hazariwala V, Hadid H, Kirsch D, Big C. Spontaneous pneumomediastinum, pneumopericardium, pneumothorax and subcutaneous emphysema in patients with COVID-19 pneumonia, a case report. *J Cardiothorac Surg* 2020;15(1):301.
- [19] Macklin MT, Macklin CC. Malignant interstitial emphysema of the lungs and mediastinum as an important occult complication in many respiratory diseases and other conditions: an interpretation of the clinical literature in the light of laboratory experiment. *Medicine* 1944;23(4):281–358.
- [20] Kolani S, Houari N, Haloua M, Alaoui Lamrani Y, Boubbou M, Serraj M, Aamara B, et al. Spontaneous pneumomediastinum occurring in the SARS-COV-2 infection. *IDCases* 2020;21:e00806 PMID: 32395425; PMCID: PMC7212974. doi:10.1016/j.idcr.2020.e00806.